

Accepted Manuscript

Longitudinal morphometric analysis of dental arch of children with cleft lip and palate: 3D stereophotogrammetry study

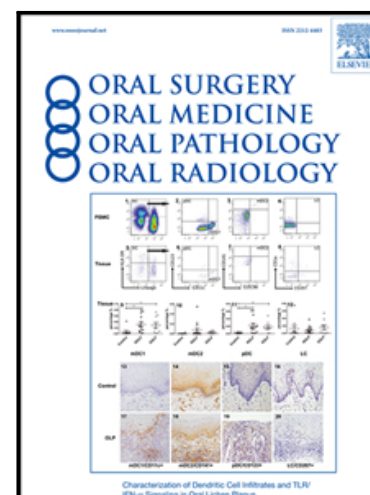
Eloá Cristina Passucci Ambrosio , Chiarella Sforza ,
Márcio De Menezes , Daniele Gibelli , Marina Codari ,
Cleide Felício Carvalho Carrara ,
Maria Aparecida Andrade Moreira Machado ,
Thais Marchini Oliveira

PII: S2212-4403(18)31156-8
DOI: <https://doi.org/10.1016/j.oooo.2018.08.012>
Reference: OOOO 2072

To appear in: *Oral Surg Oral Med Oral Pathol Oral Radiol*

Received date: 21 January 2018
Revised date: 7 June 2018
Accepted date: 22 August 2018

Please cite this article as: Eloá Cristina Passucci Ambrosio , Chiarella Sforza , Márcio De Menezes , Daniele Gibelli , Marina Codari , Cleide Felício Carvalho Carrara , Maria Aparecida Andrade Moreira Machado , Thais Marchini Oliveira , Longitudinal morphometric analysis of dental arch of children with cleft lip and palate: 3D stereophotogrammetry study, *Oral Surg Oral Med Oral Pathol Oral Radiol* (2018), doi: <https://doi.org/10.1016/j.oooo.2018.08.012>



This is a PDF file of an unedited manuscript that has been accepted for publication. As a service to our customers we are providing this early version of the manuscript. The manuscript will undergo copyediting, typesetting, and review of the resulting proof before it is published in its final form. Please note that during the production process errors may be discovered which could affect the content, and all legal disclaimers that apply to the journal pertain.

Title: Longitudinal morphometric analysis of dental arch of children with cleft lip and palate: 3D stereophotogrammetry study.

Authors: Eloá Cristina Passucci Ambrosio ¹, Chiarella Sforza ², Márcio De Menezes ³, Daniele Gibelli ², Marina Codari ⁴, Cleide Felício Carvalho Carrara ^{1,5}, Maria Aparecida Andrade Moreira Machado ^{1,5}, Thais Marchini Oliveira ^{1,5}.

Affiliation: (1) PhD Student Department of Pediatric Dentistry, Orthodontics and Public Health, Bauru School of Dentistry – Bauru School of Dentistry, University of São Paulo, Bauru, São Paulo, Brazil. (2) PhD, Human Anatomy, Department of Biomedical Sciences for Health, Functional Anatomy Research Center (FARC), Faculty of Medicine and Surgery, University of Milan, Milan, Italy. (3) PhD, School of Health Science, State University of Amazonas, Manaus, Brazil. (4) PhD, Unit of Radiology, IRCCS Policlinico San Donato, Milan, Italy. (5) PhD, Department of Pediatric Dentistry, Orthodontics and Public Health, Bauru School of Dentistry – Bauru School of Dentistry, University of São Paulo, Bauru, São Paulo, Brazil, and Pediatric Dentistry, Hospital for Rehabilitation of Craniofacial Anomalies, University of São Paulo, Bauru, SP, Brazil.

Short Title: 3D analysis of dental arch of children with CLP.

Corresponding Author:

Thais Marchini Oliveira

Bauru School of Dentistry, University of São Paulo

Alameda Dr. Octávio Pinheiro Brisolla, 9-75

Bauru, São Paulo, 17012-901- Brazil

Telephone: 55 14 32358224

E-mail: marchini@usp.br

Conflict of interest:

The authors declare that there are no conflicts of interest.

Abstract words count: 204

Manuscript words count: 2358

References count: 23

Figures count: 2

Tables count: 4

ACCEPTED MANUSCRIPT

Longitudinal morphometric analysis of dental arch of children with cleft lip and palate: 3D stereophotogrammetry study.

Abstract

Purpose: This study aimed to perform a longitudinal morphometric analysis of the alterations of the maxillary dental arches of children with cleft lip and palate before and after the primary lip and/or palate surgeries using three-dimensional stereophotogrammetry system.

Methods: The sample consisted of dental casts of 60 children with unilateral complete cleft lip (UCL) and unilateral complete cleft lip and palate (UCLP). Dental arches were evaluated at pre-cheiloplasty (T1), post-cheiloplasty (T2), and 1 year after palatoplasty (T3). Independent t test and Mann-Whitney test were used for intergroup comparisons, and Paired T test, Wilcoxon test, and Repeated-measures ANOVA followed by Tukey test were used for intragroup comparisons.

Results: At T1, the intercanine and intertuberosity distances of group UCLP were statistically greater than those of group UCL. At T2, the maxillary dimensions significantly increased, except for the intertuberosity distance in UCL. Between T1 and T3, the intercanine distance and the anterior length decreased significantly, while the intertuberosity distance and the total length of the palate increased significantly. **Conclusion:** According to our results, the primary lip surgery changed the development of the dental arches, evidently in children with UCLP. The primary palate surgery interfered in the growth of the anterior palatal region in group UCLP. The children with UCLP had more restricted development of the maxillary dental arch than children with UCL.

Key words: Cleft lip. Cleft palate. Dental arch. Imaging, Three-Dimensional. Maxillofacial development.

Introduction

The cleft lip and palate (CLP) is the most prevalent craniofacial anomaly in humans¹, leading to an enormous public health problem. CLP required numerous surgical interventions to rehabilitate the individual, among them, the cheiloplasty and palatoplasty are performed months after the child's birth². Although these primary lip and/or palate surgeries promote the anatomical-functional reconstruction, they may restrict the growth and the three-dimensional development of the dental arches³. However, the literature lacks consensus on which surgery would cause the most significant negative effects⁴.

The anthropometric study on the dental arches of CLP children provides essential information for understanding the etiology of the maxillary growth and development, which can be useful to improve the rehabilitation protocol of each type of orofacial cleft. Thus, this study aimed to perform a longitudinal morphometric analysis of the alterations of the maxillary dental arches with unilateral complete cleft lip (UCL) and unilateral complete cleft lip and palate (UCLP) before and after the primary lip and palate surgeries using 3D stereophotogrammetry system.

Material and Methods

Experimental design

This study was approved by the Institutional Review Board regarding the ethical aspects (protocol CAAE #48123315.4.0000.5441). The inclusion criteria were children of both genders, with UCLP and UCL, born between 2010 and 2012. All children with unilateral cleft lip and alveolus were included in the group unilateral complete cleft lip (UCL). Children with CLP associated to malformation or syndrome and those with incomplete documentation were excluded from this present study⁵.

The sample size was calculated using the study of Lo et al.⁶ with a standard deviation for the intertuberosity distance of 2.12 mm, significance level of 5%, test power of

80%, and a minimum difference to be clinically detected of 1.6 mm. The minimum sample size calculated was of 29 children per group. Thus, the sample comprised 30 individuals per group.

All children were treated at the Specialized Hospital. **The surgical lip repair was performed using the Millard's technique in both groups at 3 months of age. One-stage Von Langenbeck's technique was used for palatoplasty at 12 months of age^{2,5}.** Presurgical orthopedic was not part of the institution's protocol. The dental casts were obtained in the following periods: pre-cheiloplasty (T1), post-cheiloplasty (T2), and 1 year after palatoplasty (T3).

3D evaluation of dental casts

The dental casts were scanned through a commercially available laser scanner (3Shape's R700TM Scanner)⁷⁻⁹. Next, the stereophotogrammetry system software (Mirror imaging software, Canfield Scientific Inc., Fairfield, NJ, USA) was used to perform the maxillary dental arch measurements at the University of Milan (UniMi), Italy^{10,11}. All measurements were performed by a trained and calibrated examiner as previous studies^{5,7-9,12-15}.

The following linear measurements were obtained^{3,7}: the intercanine distance (C - C'); intertuberosity distance (T - T'); anterior length of palate (I-CC'); and the total length of palate (I-TT') (Figure 1). In addition, the palatal segment area (Area S) and cleft area (Area C) were considered. At all stages of the group UCL and at T3 (Figure 2A), the Area S was delimited from the alveolar ridge to the intertuberosity distance - posterior limit⁶. At T1 and T2 (UCLP group), the Area S was the sum of the major and minor palatal segments which was determined by outlining all palatal segment adjacent to the cleft starting from the alveolar ridge. Furthermore, the Area C was also calculated through outlining the medial border of the cleft with the anterior (the width between left and right anterior cleft ridges) and the posterior limits (the width between left and right posterior cleft ridges) (Figure 2B).

Statistical analysis

All statistical analyses were performed in GraphPad Prism software (Prism 5 for Windows - Version 5.0 – GraphPad software., Inc.)¹⁶, adopting the level of significance of 5%. The Shapiro-Wilk normality test was applied for testing the normality measurements. Descriptive statistics (mean and standard deviation, or median and interquartile amplitude, depending on data distribution) were calculated for all measurements.

To analyze the intraexaminer error, dental casts of 1/3 of the children were measured again 2 weeks after the first measurement¹². Paired t test and Wilcoxon test were applied to determine the systematic error. The random error was determined by Dahlberg's formula. Paired t test and repeated measures ANOVA followed by Tukey test were used in the intragroup analysis of children with UCLP. Paired t test and Wilcoxon test compared the different phases of the group UCL. Intergroup comparison was performed with independent t test and Mann-Whitney test.

Results

The intraexaminer reproducibility showed no statistically significant differences in the repeated measurements ($p > 0.05$). According to the inclusion and exclusion criteria, the group UCL was composed by 12 boys and 18 girls and the group UCLP by 17 boys and 13 girls. The median age (in years) of group UCL was 0.295 (T1) and 1.749 (T2). In group UCLP, the median age was 0.291 (T1); 1.083 (T2); and 2.25 years (T3). Statistically significant differences in age occurred between groups at T2 ($p < 0.001$).

The maxillary dimensions of group UCL from pre- to post-cheiloplasty are reported in Table 1. The intercanine (C - C') and intertuberosity (T - T') distances, and the Area S increased during the evaluated stages. There was no statistically significant difference in sagittal lengths (I - CC' and I - TT').

The maxillary dimensions of UCLP group from pre-cheiloplasty to 1 year after palatoplasty are shown in Table 2. The C - C' distance had a significant reduction from T1 to T3.

The T - T' distance and I - TT' length increased in all evaluated phases. The I - CC' length and Area C exhibited a significant reduction from T1 to T2.

The intergroup comparison is displayed in Table 3 (T1 and T2) and Table 4 (T2 - T1). Statistically significant differences occurred in all measurements at T1; but at T2, T - T' did not show statistically significant differences between groups (Table 3). The changes in C - C' and T - T' distances were statistically different between groups UCL and UCLP (Table 4).

Discussion

The linear and surface (area) measurements of the palate of children with UCLP and UCL were analyzed from 3 months of life to the last primary lip or palate surgery. Area S and T-T' distance increased after lip repair in both groups. At T2, the C-C' distance remained stable in the group UCLP but increased in the group UCL. After palatal repair (T3), C-C' distance, I-CC' length, and Area S were stable (compared to T2), while T-T' distance and I-TT' length continued growing.

The measurements obtained from this study have a notable relevance in the clinical environment and scientific research for individuals with CLP because of the innovation in diagnosis, preoperative planning, execution of procedures, and monitoring of the rehabilitation protocol in the different areas of health. The anthropometric analyses on dental casts through the stereophotogrammetry system software have their accuracy proven by the studies of Sforza et al. and De Menezes et al^{10,11}. The linear measures of the present study were used in other studies that had the intention to make an intercenter comparative analysis¹², evaluation of the rehabilitation protocol^{7,14}, and analysis with other types of craniofacial anomalies^{3,5-9,17}. Previous studies indicate that linear measures are good indicators in the qualitative and quantitative analyses of palatal development^{3,5,7,11,12,14,15}. The delimitations of the areas of the palatal segments (Area S) and of the cleft (Area C) in the pre- and post-surgical phases is the differential of this study.

The data showed that the severity of the anatomical defect interfered in the postoperative results, because a wider cleft would consequently lead to more cicatricial tissue¹³ capable of inhibiting the development of the maxillary dental arch. This fact was evidenced in the intragroup analysis of children with UCL, in which significant growth was observed in Area S, C - C', and T - T' distances, although the sagittal lengths remained stable. In the group UCLP, the C - C' distance decreased from pre-cheiloplasty to 1 year after palatoplasty. The I - CC' length decreased after lip repair. However, after palate repair, this length did not show significant changes. The T - T' distance and I - TT' length increased in all evaluated phases. The Area S increased after cheiloplasty but remained stable from post-cheiloplasty to post-palatoplasty. The Area C decreased significantly after lip repair. The intragroup analysis of children with UCLP reinforces the concept that the pressure exerted by the surgical repair of the lip over the palatal segments provide continuous muscle pressure in the anterior region of the palate capable of reducing the overjet of the major bone segment reflecting in the decrease of these measurements¹⁸. The cheiloplasty did not interfere in the results of the posterior palate as another study¹⁷. At T3, the anterior palate measurements (C - C' and I - CC') continued to decrease in relation to T1. The palatoplasty technique may have influenced this result. With regards to cheiloplasty, several surgical protocols have been used, such as Millard's technique or modified Millard technique. In our study, we used Millard's technique, as previous studies^{5,7,12}. Lip closure with advancement of lateral flap - cleft side - and rotation of the flap of the medial, resulting in a vertical scar in the form of the letter Z. The medial flap traction aligns the columella and the nasal septum. The lateral flap contributes to the tubercle filling of the vermilion of the lip. Von Langenback was the surgical technique of choice for palatoplasty, in which the relaxing incisions start from the retromolar region to the deciduous canine to approach the mucoperiosteal flaps towards the medial direction, closing the cleft palate¹⁹. The growth of T - T' distance at all stages is a consolidated

finding in the literature, indicating that palatoplasty does not interfere in the transverse distance of the posterior palate^{3,5}.

The intergroup analysis at T1, C - C' and T - T' distances were significantly higher in children with UCLP, fact that corroborates previous studies^{6,9,13}. The presence of the cleft palate justifies smaller means of Area S in the group UCLP. In addition, at T2, all analyzed measurements were higher in the group UCL. Similar data were reported by Honda et al., that is, at T2 - T1, negative changes of C - C' distance in the group UCLP and positive changes in group UCL¹⁷.

In the anthropometric studies, the authors report the possible factors that may inhibit maxillofacial development in individuals with CLP¹⁷⁻²³. Honda et al., 1995¹⁷ conclude that changes in growth are variable in each individual, however the degree of the congenital tissue defect together with the intrinsic growth potential are capable of influencing maxillofacial development. Sapersetein et al., 2012¹⁸ believe that the presence of the anatomical defect in the secondary palate or its closure are responsible for the inhibition of the maxillofacial development. Dadáková et al. 2016²⁰ confirm that the inhibition of facial growth may be due to the sum of factors: anatomical defect and palatoplasty. Carrara et al., 2016⁷ suggest that the results of the different surgical techniques may alter the growth and development of the dental arches of neonates with cleft lip and palate. Sakoda et al., 2017⁵ affirm that the maxillary arches of children with unilateral complete cleft lip and palate and isolated cleft palate changed due to primary surgeries. Lip repair showed greater influence on the anterior arch region in group unilateral complete cleft lip and palate. Palate repair inhibited growth transversally in both groups, but this inhibition seemed to be greater in group unilateral complete cleft lip and palate. Regardless of the methodology used to evaluate post-surgical development, the authors agree that the intrinsic characteristics of each type of cleft lip and palate are capable of significantly influencing on the craniofacial growth^{17,18,20-23}.

The present study has some limitations. The group UCL could not be evaluated at T3. This occurred because the rehabilitation protocol of the institution comprises the dental arch impression before and after each primary lip and/or palate surgery. After the last impression, the children return to the institution at 5 years of age. Thus, based on the analysis of the data resulting from this research, further digital anthropometric studies of dental arches are necessary, such as the superimposition of the palate to indicate areas of bone growth and retrusion, intersegmental angulations, and palate depth²⁴.

Conclusion

According to our results, the primary lip surgery modified the development of the dental arches, evidently in children with UCLP. The primary palate surgery interfered in the growth of the anterior palatal region in the UCLP group. The children with UCLP have more restricted development of the maxillary dental arch than children with UCL.

Statement of clinical relevance

The evaluation of dental arches enables improving the technique and quality of the surgical interventions. Understanding the growth of the dental arches of individuals with cleft lip and palate contributes to the best therapeutic approach in order to favor rehabilitation.

References

- 1. M. Yakob, H.Y. Rafidah, M. Gu, Y. Yang, Comparing Modified Huddart-Bodenham Scoring System and GOSLON Yardstick to Assess Dental Arch Relationships in Unilateral Cleft Lip and Palate Patients. *Cleft Palate Craniofac J*, (2018). doi: 10.1597/16-191.**
- 2. J.A. Freitas, D.G. Garib, M. Oliveira, R.C. Lauris, A.L. Almeida, L.T. Neves, I.K. Trindade-Suedam, R.Y. Yaedú, S. Soares, J.H. Pinto, Rehabilitative treatment of cleft lip**

and palate: experience of the Hospital for Rehabilitation of Craniofacial Anomalies-USP (HRAC-USP) -Part 2: pediatric dentistry and orthodontics, *J Appl Oral Sci.* 20 (2012b) 268-281.

3. E. Reiser, V. Skoog, A. Andlin-Sobocki, Early dimensional changes in maxillary cleft size and arch dimensions of children with cleft lip and palate and cleft palate, *Cleft Palate Craniofac J.* 50 (2013) 481-490.

4.T. Fuchigami, N. Nakamura, K. Nishihara, K. Matsunaga, H. Hasegawa, Short-term molding effects on the upper alveolar arch following unilateral cleft lip repair with/without nasal vestibular expansion, *Cleft Palate Craniofac J.* 51 (2014) 557-568.

5. K.L. Sakoda, P.K. Jorge, C.F.C. Carrara, M.A.A.M. Machado, F.P. Valarelli, A. Pinzan, T.M. Oliveira, 3D analysis of effects of primary surgeries in cleft lip/palate children during the first two years of life, *Braz Oral Res.* 31 (2017) e46.

6.L.J. Lo, F.H. Wong, Y.R. Chen, W.Y. Lin, E.W. Ko, Palatal surface area measurement: comparisons among different cleft types, *Ann Plast Surg.* 50 (2003) 18-23.

7.C.F.C. Carrara, E.C.P. Ambrosio, B.Z.F. Mello, P.K. Jorge, S. Soares, M.A.A.M. Machado, T.M. Oliveira, Three-dimensional evaluation of surgical techniques in neonates with orofacial cleft, *Ann Maxillofac Surg.* 6 (2016) 246-250.

8.M.M.M. Falzoni, P.K. Jorge, K.V. Laskos, C.F.C. Carrara, M.A.A.M. Machado, F.P. Valarelli, T.M. Oliveira, Three-dimensional dental arch evaluation of children with unilateral complete cleft lip and palate, *Dent Oral Craniofac Res.* 2 (2016) 238-241.

9.V.M. Fernandes, P.K. Jorge, C.F.C. Carrara, M.R. Gomide, M.A.A.M. Machado, T.M. Oliveira, Three-dimensional digital evaluation of dental arches in infants with cleft lip and/or palate. *Braz Dent J.* 26 (2015) 297-302.

10.C. Sforza, M. De Menezes, E. Bresciani, A.M. Ceron-Zapata, A.M. Lopez-Palacio, M.J. Rodriguez-Ardila, L.M. Berrio-Gutierrez, Evaluation of a 3D stereophotogrammetric technique to measure the stone casts of patients with unilateral cleft lip and palate, *Cleft Palate Craniofac J.* 49 (2012) 477-483.

11.M. De Menezes, A.M. Ceron-Zapata, A.M. Lopez-Palacio, A. Mapelli, L. Pisoni, C. Sforza, Evaluation of a 3D Stereophotogrammetric Method to Identify and Measure the Palatal Surface Area in Children With Unilateral Cleft Lip and Palate, *Cleft Palate Craniofac J.* 53 (2016) 16-21.

12.P.K. Jorge, W. Gnoinski, K.V. Laskos, C.F.C. Carrara, D.G. Garib, T.O. Ozawa, M.A.A.M. Machado, F.P. Valarelli, T.M. Oliveira, Comparison of two treatment protocols

in children with unilateral complete cleft lip and palate: Tridimensional evaluation of the maxillary dental arch, *J Craniomaxillofac Surg.* 44 (2016) 1117-1122.

13.V. Harila, L.P. Ylikontiola, R. Palola, G.K. Sandor, Maxillary arch dimensions in cleft infants in Northern Finland, *Acta Odontol Scand.* 71 (2013) 930-936.

14.V. Shetty, R.K. Agrawal, H.F. Sailer, Long-term effect of presurgical nasoalveolar molding on growth of maxillary arch in unilateral cleft lip and palate: randomized controlled trial, *Int J Oral Maxillofac Surg.* 46 (2017) 977-987.

15.C.S. Huang, W.I. Wang, E.J. Liou, Y.R. Chen, P.K. Chen, M.S. Noordhoff, Effects of cheiloplasty on maxillary dental arch development in infants with unilateral complete cleft lip and palate, *Cleft Palate Craniofac J.* 39 (2002) 513-516.

16.J. Wu, Y. Chen, J. Pei, J. Pan, MTHFD1 gene polymorphisms as risk factors involved in orofacial cleft: an independent case-control study and a meta-analysis, *Int J Clin Exp Med.* 15 (2015) 7737-7745.

17.Y. Honda, A. Suzuki, M. Ohishi, H. Tashiro, Longitudinal study on the changes of maxillary arch dimensions in Japanese children with cleft lip and/or palate: infancy to 4 years of age, *Cleft Palate Craniofac J.* 32 (1995) 149-155.

18. E.L. Saperstein, D.L. Kennedy, J.B. Mulliken, B.L. Padwa, Facial growth in children with complete cleft of the primary palate and intact secondary palate, *J Oral Maxillofac Surg.* 70 (2012) e66-71.

19. M. Hortis-Dzierzbicka, E. Radkowska, E. Stecko, L. Dudzinski, P.S. Fudalej. Speech outcome in complete unilateral cleft lip and palate - a comparison of three methods of the hard palate closure. *J Oral Rehabil.* 44 (2014) 809–815.

20. M. Dadáková, V. Cagáňová, J. Dupej, E. Hoffmannová, J. Borský, J. Velemínská, Three-dimensional evaluation of facial morphology in pre-school cleft patients following neonatal cheiloplasty, *Craniomaxillofac Surg J.* 44 (2016) 1109-1116.

21. K. Bonanthaya, D.D. Rao, P. Shetty, C. Uguru, Correlation of vermilion symmetry to alveolar cleft defect in unilateral cleft lip repair. *Int J Oral Maxillofac Surg.* 45 (2016) 688-691.

22. P. Rossell-Perry, A 20-year experience in unilateral cleft lip repair: From Millard to the triple unilimb Z-plasty technique. *Indian J Plast Surg.* 49 (2016) 340-349.

23. L.O. Roussel, R.P. Myers, J.A. Giroto, The Millard Rotation-Advancement Cleft Lip Repair: 50 Years of Modification. *Cleft Palate Craniofac J.* 52 (2015) e188-195.

24. C. Generali, J. Primožic, S. Richmond, M. Bizzarro, C. Flores-Mir, Ovsenik M, Perillo L, Three-dimensional evaluation of the maxillary arch and palate in unilateral cleft lip and palate subjects using digital dental casts. *Eur J Orthod.* 39(2017) 641–645.

ACCEPTED MANUSCRIPT

Figure legends

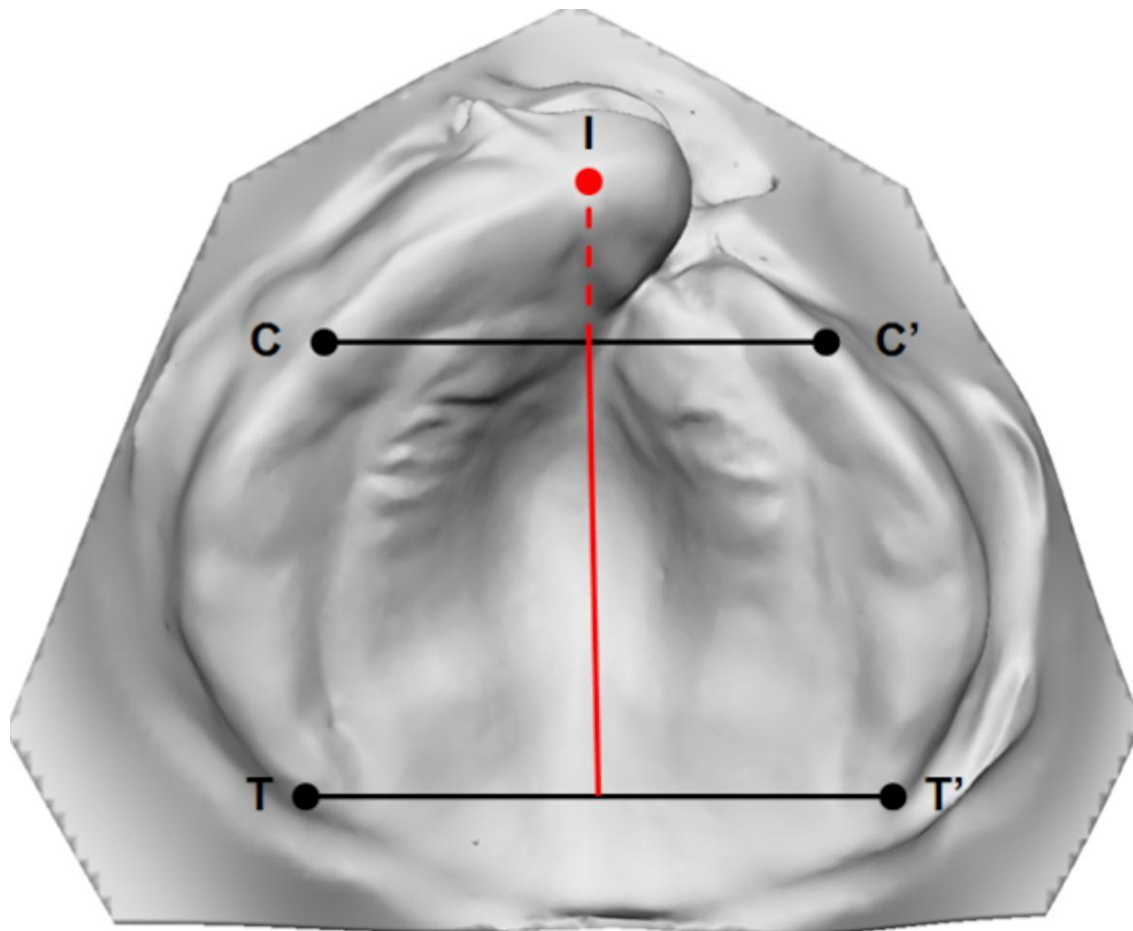


Figure 1 – Anatomic landmarks and linear measurements: the intercanine distance (C - C'), anterior transversal line on the dental arch from the point of eruption of right primary canine teeth to the point of eruption of left primary canine teeth on the alveolar ridge; the intertuberosity distance (T - T'), posterior transversal line on the dental arch between points on the posterior extremity - junction of the alveolar ridge crest with the tuberosity contour; the anterior length of dental arch (I-CC'), sagittal line from interincisal point perpendicular to C - C'; and the total length of palate (I-TT'), sagittal line from interincisal point perpendicular to T - T'.

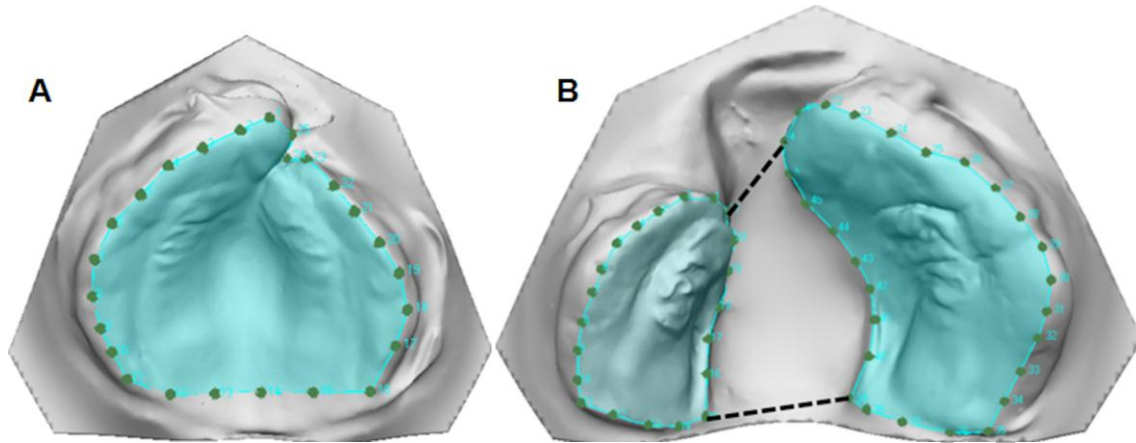


Figure 2 – Delimitation of the area of the palatal segments and cleft in children with UCL (A) and UCLP (B) by the software of the stereophotogrammetry system.

Table legends

Table 1 – Analysis of the maxillary linear (mm) and surface dimensions (mm²) in UCL group, at T1 and T2 (Paired t test and Wilcoxon test)..

Variables	T1		T2		<i>P</i>
	Mean (Median)	SD (IA)	Mean (Median)	SD (IA)	
C - C'	25.86	1.63	29.25	1.75	< 0.0001*
T - T'	31.07	2.14	37.63	3.69	< 0.0001*
I - CC'	8.28	1.68	7.99	1.65	0.515
I - TT'	31.18	2.66	31.62	2.97	0.526
Area S	1080 ^A	94.25 ^A	1264 ^A	160.5 ^A	< 0.0001*

*Statistically significant difference. ^A Median and IA (interquartile amplitude), Wilcoxon test.

Table 2 - Analysis of the maxillary linear (mm) and surface dimensions (mm²) in UCLP group at T1, T2 and T3 (Paired T test, ANOVA followed by Tukey test).

Variables	T1		T2		T3		P
	Mean	SD	Mean	SD	Mean	SD	
C - C'	28 ^a	3.22	27.29 ^{ab}	2.77	26.63 ^b	2.68	0.001*
T - T'	35.05 ^a	4.28	36.85 ^b	3.23	38.82 ^c	3.14	< 0.0001*
I - CC'	7.26 ^a	1.29	6.51 ^b	1.12	5.96 ^b	1.28	< 0.0001*
I - TT'	27.44 ^a	2.48	28.62 ^b	2.65	29.96 ^c	2.67	< 0.0001*
Area S	965.58 ^a	168.58	1100.2 ^b	128.17	1082.7 ^b	147.9	< 0.0001*
Area C	309.4	73.74	212.66	83.39	-	-	< 0.0001*

* Statistically significant difference.

Equal lowercase letters in line means no statistically significant difference.

Table 3 – Analysis of the maxillary linear (mm) and surface dimensions (mm²) of UCL and UCLP groups, at T1 and T2 (Independent t test and Mann Whitney test).

Variables	T1	T2
	<i>P</i>	<i>P</i>
C - C'	0.0020*	0.0018*
T - T'	< 0.0001*	0.3925
I - CC'	0.0108*	< 0.0001*
I - TT'	< 0.0001*	< 0.0001*
Area S	0.0003*	0.0001* ^A

* Statistically significant difference. ^A Mann Whitney test.

Table 4 – Comparison of the changes in the maxillary linear (mm) and surface dimensions (mm²) between T2-T1, in groups UCL and UCLP (Independent t test).

Variables	UCL		UCLP		P
	Mean	SD	Mean	SD	
C - C'	3.39	1.84	- 0.7	1.91	< 0.0001*
T - T'	6.55	3.8	1.8	2.75	< 0.0001*
I - CC'	- 0.28	2.4	- 0.74	1.2	0.3540
I - TT'	0.43	3.74	1.17	2.68	0.3827
Area S	165.6	125.34	134.53	148.23	0.3844

* Statistically significant difference.