

Keywords

Feline diffuse iris melanoma, Cat, Immunohistochemistry, MMP9, Tumor-matrix interactions.

CORRESPONDING AUTHOR

Laura Nordio

laura.nordio@unimi.it

JOURNAL HOME PAGE

riviste.unimi.it/index.php/haf



UNIVERSITÀ DEGLI STUDI DI MILANO
DIPARTIMENTO DI SCIENZE VETERINARIE
PER LA SALUTE, LA PRODUZIONE ANIMALE
E LA SICUREZZA ALIMENTARE



MMP-9 immunohistochemical expression is correlated with histologic grade in feline diffuse iris melanoma.

L. Nordio^{1,*}, V. Stornelli², C. Giudice¹

¹ Department of Veterinary Medicine, Università degli Studi di Milano, via Celoria 10, Milano, Italy.

² Private veterinary practitioner, Italy.

Short communication

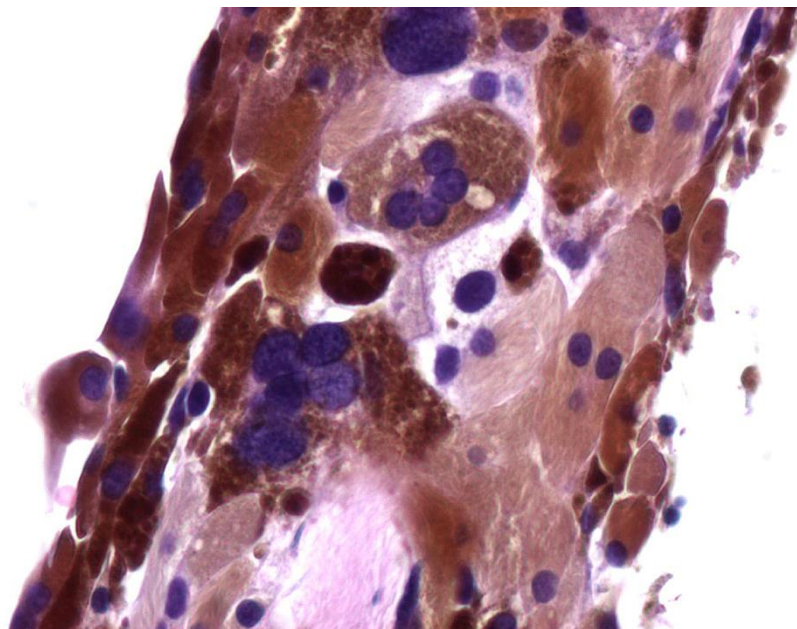
Feline diffuse iris melanoma (FDIM) is the most common primary intraocular neoplasm in cats (Dubielzig, 2017). It is usually a malignant tumor, even if slowly progressive, thus representing an unique spontaneous model of the aggressive, although rare, human iris melanoma (Demirci et al., 2002). In cats, the extent of the tumor within the eye, expressed as histological grade, is considered a good predictor of survival (Kalishman et al., 1998). In the context of the neoplastic cells-tumor microenvironment interaction, Matrix Metalloproteinase-9 (MMP-9) is an endopeptidase able to digest the extracellular matrix with involvement in tumor invasion (Nagase et al., 2006). MMP-9 expression has been positively correlated with metastasizing behavior in human posterior uveal melanoma (El-Shabrawi et al., 2001).

The present study investigates the expression of MMP-9 in a caseload of formalin-fixed paraffin-embedded FDIMs in relation to the histological grade (Kalishman et al., 1998) and mitotic index (MI) (threshold=7/10 hpf) (Wiggans et al., 2016). Sixty-one samples of FDIM evaluated on light microscopy (Figure 1) were selected (grade I n=22, grade II n=20, grade III n=19). Immunohistochemical staining with standard ABC method was performed using a mouse anti-MMP-9 antibody (Porcellato et al., 2014). Results were semi-quantitatively scored and compared by Mann-Whitney U test.

MMP-9 was expressed in 59,1% grade I FDIM, 90,0% grade II and 80,0% grade III. Tumors with MMP-9 expression in more than 50% of neoplastic cells were 13,6% in grade I cases, 40,0% in grade II and 36,8% in grade III. MMP-9 was expressed in 71,4% of FDIM with MI≤7 and 92,3% of FDIM with MI>7. MMP-9 expression differed significantly between grade I and the other two grades,

and between groups with low and high MI. In conclusion, intense expression of MMP-9 seems to correlate with the histological aggressiveness of FDIM.

Figure 1: Feline diffuse iris melanoma, neoplastic melanocytes. Hematoxylin and eosin, 40x .



References

- Demirci, H., Shields, C.L., Shields, J.A., Eagle, R.C. Jr, Honavar, S.G., 2002. Diffuse iris melanoma: a report of 25 cases. *Ophthalmology*. 109, 1553-1560.
- Dubielzig R.R. Tumors of the Eye. In *Tumors in Domestic Animals*. V ed. Wiley Blackwell, 2017.
- El-Shabrawi, Y., Ardjomand, N., Radner, H., Ardjomand, N., 2001. MMP-9 is predominantly expressed in epithelioid and not spindle cell uveal melanoma, *Journal of Pathology*. 194, 201-206.
- Kalishman, J.B., Chappell, R., Flood, L.A., Dubielzig, R.R., 1998. A matched observational study of survival in cats with enucleation due to diffuse iris melanoma. *Veterinary Ophthalmology*. 1, 25-29.
- Nagase, H., Visse, R., Murphy, G., 2006. Structure and function of matrix metalloproteinases and TIMPs. *Cardiovascular Research*. 69, 562-573.
- Porcellato, I., Giontella, A., Mechelli, L., Del Rossi, E., Brachelente, C., 2014. Feline eosinophilic dermatoses: a retrospective immunohistochemical and ultrastructural study of extracellular matrix remodelling. *Veterinary Dermatology*. 25, 86-94.
- Wiggins, K.T., Reilly, C.M., Kass, P.H., Maggs, D.J., 2016. Histologic and immunohistochemical predictors of clinical behavior for feline diffuse iris melanoma, *Veterinary Ophthalmology*. Suppl 1, 44-55.