

## PHONiatrics

# Outcomes of structural fat grafting for paralytic and non-paralytic dysphonia

## *Risultati della lipostruttura nel trattamento della disfonia paralitica e non paralitica*

G. CANTARELLA<sup>1</sup>, G. BARACCA<sup>1</sup>, S. FORTI<sup>2</sup>, M. GAFFURI<sup>1</sup>, R.F. MAZZOLA<sup>1,3</sup><sup>1</sup>Otolaryngology Department; <sup>2</sup>Audiology Unit, Fondazione IRCCS Ca' Granda Maggiore Policlinico Hospital, Milan;<sup>3</sup>Department of Surgical Sciences, University of Milan, Italy

## SUMMARY

Aims of this prospective study were to evaluate the results of vocal fold structural fat grafting for glottic insufficiency and to compare the outcomes obtained in unilateral vocal fold paralysis (UVFP) and congenital or acquired soft tissue defects in vocal folds. Sixty-six consecutive patients with breathy dysphonia, in 43 cases (aged 16-79 years) related to UVFP and in 23 cases (aged 16-67 years) related to vocal fold iatrogenic scar or *sulcus vocalis*, underwent autologous structural fat grafting into vocal folds. Lipoaspirates were centrifuged at 1200 g for 3 min to separate and remove blood, cell debris and the oily layer. The refined fat was injected under direct microlaryngoscopy in a multilayered way. The main outcome measures were grade, roughness, breathiness, asthenicity and strain (GRBAS) perceptual evaluation, maximum phonation time (MPT), self-assessed Voice Handicap Index (VHI), and voice acoustic analysis, considered pre-operatively and at 3 and 6 months after fat grafting. After surgery, MPT, VHI, G and B improved in both groups ( $p < 0.05$ ). In particular, G and VHI functional subscales showed a significantly greater decrease in patients with UVFP ( $p < 0.05$ ). The acoustic variables improved significantly only in the UVFP group ( $p < 0.005$ ). From 3 to 6 months postoperatively, most variables showed a trend with further improvement. Vocal fold structural fat grafting was significantly effective in treating glottic insufficiency due to UVFP or soft tissue defects. Perceptual, acoustic and subjective assessments confirmed that patients with UVFP had better outcomes than those with soft tissue defects.

KEY WORDS: Structural fat grafting • Vocal fold unilateral paralysis • Glottic insufficiency • Vocal fold scar • *Sulcus vocalis*

## RIASSUNTO

*Gli scopi di questo studio prospettico sono stati la valutazione multidimensionale dei risultati ottenuti con il trapianto di grasso autologo nelle corde vocali applicando la tecnica della lipostruttura, ed il confronto tra pazienti affetti da paralisi laringea monolaterale e difetti dei tessuti molli cordali, di natura congenita o acquisita. Sono stati studiati 66 pazienti consecutivi con insufficienza glottica dovuta in 43 casi (età 16-79 anni) a paralisi laringea monolaterale e in 23 (età 16-67 anni) a lesioni cicatriziali iatrogene delle corde vocali o a sulcus glottidis. Il tessuto adiposo è stato prelevato mediante aspirazione a bassa pressione negativa ed il lipoaspirato è stato centrifugato a 1200 g per 3 minuti per separare e rimuovere sangue, detriti cellulari e strato oleoso. I pazienti sono stati sottoposti all'iniezione di grasso purificato in una o in entrambe le corde vocali in microlaringoscopia diretta cercando di ottenere la diffusione in tutto lo spessore cordale. La valutazione dei risultati è stata eseguita mediante la scala percettiva (GRBAS), la misurazione del tempo massimo fonatorio (TMF), la somministrazione del questionario Voice Handicap Index (VHI) e l'analisi acustica della voce con MDVP. Per l'analisi statistica abbiamo considerato la valutazione pre-operatoria e quelle eseguite 3 e 6 mesi dopo l'intervento. Dopo l'intervento in entrambi i gruppi di pazienti è stato ottenuto un miglioramento significativo di TMF, VHI, e dei parametri G e B della scala GRBAS ( $p < 0,05$ ). In particolare, G e la scala funzionale del VHI sono migliorati in modo più significativo nei pazienti con disfonia paralitica ( $p < 0,05$ ). Le variabili acustiche sono migliorate solo nel gruppo delle disfonie paralitiche. Dai 3 ai 6 mesi dopo l'intervento è stato riscontrato un trend al miglioramento ulteriore in entrambi i gruppi di pazienti. In conclusione, l'iniezione di grasso autologo secondo il metodo della lipostruttura è significativamente efficace nel trattamento dell'insufficienza glottica sia in caso di paralisi laringea monolaterale che di alterazione della struttura cordale di tipo congenito o acquisito. Tuttavia le valutazioni soggettiva, acustica e percettiva evidenziano risultati migliori nei pazienti affetti da disfonia paralitica.*

PAROLE CHIAVE: Lipostruttura • Paralisi laringea monolaterale • Incompetenza glottica • Cicatrice cordale • *Sulcus glottidis*

Acta Otorhinolaryngol Ital 2011;31:154-160

## Introduction

Breathy dysphonia can be a disabling condition that has an immense impact on the quality of life and negatively influences social and professional relationships. Unilateral vocal fold paralysis (UVFP) is a frequent cause of

severe breathy dysphonia resulting from insufficient vocal fold adduction. The glottic air leak causes a poorly audible voice, respiratory fatigue on phonation and, in some cases, a swallowing impairment due to glottic sphincter dysfunction. Congenital or acquired tissue defects in the vocal folds may also severely alter voice production when

the rigidity in the superficial layers of the vocal fold causes an impairment of the mucosal wave and consequent glottic insufficiency.

Over the years, glottic insufficiency has been treated with vocal fold augmentation by injecting either non-reabsorbable implants, such as Teflon<sup>1</sup> or hydroxyapatite<sup>2</sup>, or absorbable materials, such as collagen<sup>3</sup> or hyaluronan derivatives<sup>4</sup>. Fat grafting in the vocal folds was first described in the early 1990s. Independently, Mikaelian et al.<sup>5</sup> reported successful treatment of 3 patients while Brandenburg et al.<sup>6</sup> reported on 11 patients with laryngeal paralyses. Subsequently, several others reported their experience in using fat grafting to treat paralytic glottic incompetence, with inconsistent results<sup>7-11</sup> that were mainly due to resorption.

The advent of the liposuction technique made autologous fat a readily available material to be harvested with a minimally invasive technique, and there has been a renewed interest in fat injections as a means of augmenting soft tissue defects. Clinical studies have shown that the key to improve grafted fat survival is to maximize the surface area of contact between fat parcels and recipient tissues<sup>12</sup>.

Basic research over the past few years has shown that fat should no longer be considered as just an energy reservoir, but as a vital organ, the stromal vascular fraction of which contains a cell population with the typical features of mesenchymal stem cells<sup>13</sup>. Intense international research is investigating the potential of adipose-derived stem cells (ADSCs) to differentiate and regenerate<sup>14 15</sup>, which are processes that might play a role in the effectiveness of vocal fold lipoinjection<sup>16</sup>.

Although autologous fat grafting is a straightforward procedure for vocal fold augmentation, consensus is lacking on the indications and choice of techniques. Whereas numerous reports refer to lipoinjection applied in clinical practice for vocal fold paralysis or paresis<sup>5-9 17 18</sup>, fewer investigators have reported the results obtained in treating soft tissue defects<sup>10 11 19-21</sup>.

The present study was designed to analyze the outcomes of fat grafting in the treatment of breathy dysphonia and vocal fatigue due to glottic insufficiency and results obtained were then compared with those in patients with UVFP and those with soft tissue defects in the vocal folds by means of perceptual, acoustic and patient self-assessment.

## Patients and methods

### Patients

A series of 66 consecutive patients with breathy dysphonia were prospectively studied at our University Hospital. Of these, 43 (20 men and 23 women, mean age  $51.02 \pm 14.78$  years) had glottic insufficiency for UVFP due to thyroidectomy (16 cases), cervical spine surgery (2), thoracic

surgery (7), cranial base surgery (5), carotid endarterectomy (2), neck trauma (2), Guillain-Barré syndrome (1), diphtheria (1), or an unknown cause (7). The mean time elapsed from the onset of UVFP was  $8.42 \pm 12.80$  years (median 1.5 years). In the remaining 23 patients (12 men and 11 women,  $43.7 \pm 15.18$  years), glottic insufficiency was related to vocal fold soft tissue defects: iatrogenic vocal fold scarring (10 cases) or bilateral *sulcus vocalis* (13). All patients had previously undergone extensive voice therapy without significant benefit.

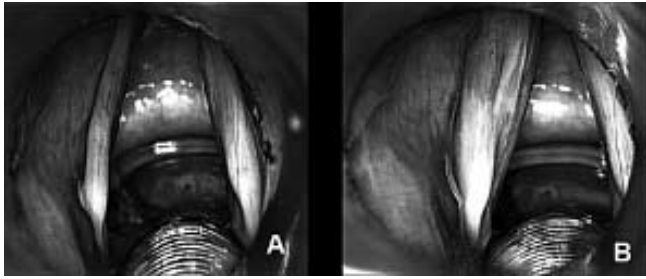
The study was approved by the institutional review board of Ospedale Maggiore Policlinico.

### Surgical technique

The procedure was performed with the patient under general anaesthesia. The usual fat donor site was the lower abdomen, and in thin patients, the fat was harvested from the inner knee or the inner thigh. Donor sites were infiltrated with lidocaine and epinephrine 1:100,000. Fatty tissue was harvested by liposuction under mild negative pressure using a 10 ml Luer-lock syringe connected to a two-hole blunt cannula (2 mm diameter, 23 cm length). The lipoaspirate was processed according to the method described by Coleman<sup>22</sup>, using centrifugation at 1200 g for 3 min to separate the different components into 3 layers: an oily upper layer of ruptured adipocytes, a middle layer of fat cells and a lower layer containing blood and lidocaine. The oily layer was withdrawn with a needle, the lower liquid layer was released removing the Luer-lock plug, and the refined fat tissue was placed in the barrel of a pistol (Medtronic, Micro-France, MCL-55) with a 19 gauge bayonet needle. Air exposure was minimized to avoid bacterial contamination<sup>22</sup>.

Fat was injected under direct microlaryngoscopy into the defective vocal fold in a multilayered way to maximize the surface contact with the host tissue to enhance survival chances<sup>23 24</sup>. The injection was performed slowly to avoid excessive pressure, and the needle was gently retracted to enhance diffusion. In patients with vocal fold paralysis, the first treated site was lateral to the vocal process to obtain medialization, followed by the mid-third and anterior third of the paralyzed fold deep in the vocal muscle. In patients with glottic insufficiency due to soft tissue defects, fat was injected first in the mid-fold, with other sites treated as needed. In cases with scars or *sulci*, the injection was performed also in the superficial layer to free the adhesences and restore the gliding layer. The amount of injected fat ranged from 0.4 to 3 ml for each vocal fold. If only one vocal fold was treated, it was overinflated until its initial volume was subjectively judged to have been almost doubled (Fig. 1); in patients who received bilateral injections, only one fold was overcorrected.

Intravenous clarithromycin 250 mg was given twice daily on the day of surgery, and oral clarithromycin 500 mg was given twice daily for the following 6 days. Dexametha-



**Fig. 1.** Microlaryngoscopic view of vocal folds in a 67-year-old female affected by post-thyroidectomy paralysis of left vocal fold for 72 months. A) Before fat grafting: hypotrophy of the paralyzed vocal fold is clearly visible. B) Augmentation obtained by fat grafting.

sone sodium phosphate 8 mg was routinely administered intra-operatively to prevent oedema.

Fat was injected in the paralyzed vocal fold in all patients with UVFP; in 10 aphonic cases with severe glottic incompetence, a smaller amount (0.4 - 1.2 ml) was also placed in the contralateral fold to enhance glottic closure. In the patients with soft tissue defects in the vocal folds, fat was injected on both sides in 19 cases and unilaterally in 4 cases.

#### *Methods of laryngeal and voice evaluation*

The outcome measures considered in this study were gathered pre-operatively and at 3 and 6 months after lipoinjection. All patients underwent videolaryngostroboscopy with a flexible fiberscope or a 70° rigid fiberoptic endoscope to document the site and severity of the glottic gap and vocal fold vibration abnormalities, to plan the injection sites and to assess post-treatment changes objectively.

Glottic efficiency was tested with the maximum phonation time (MPT) measured while subjects sustained the vowel /a/ at a comfortable pitch and loudness; 3 consecutive trials were run, and the best one was considered.

For perceptual voice evaluation, we used the GRBAS scale<sup>25</sup>, which subjectively scores the grade of dysphonia (G), roughness (R), breathiness (B), asthenicity (A) and strain (S). The voice samples were computer-recorded using a dynamic microphone (model C 1000 S, AKG Acoustics GmbH, Vienna, Austria) at a constant distance of 5 cm from the patient's mouth while the subject produced a sustained/a/, repeated single words and sentences, and continued a conversation. The recordings were subsequently evaluated by 3 experienced independent listeners and scored in the usual manner (0 = normal; 1 = slight disturbance; 2 = moderate disturbance; 3 = severe disturbance). The G, R and B scores were computed for outcome evaluation.

The Voice Handicap Index (VHI)<sup>26</sup>, a 30-item test divided into 3 subscales that measure the functional, physical and emotional features of the disability caused by voice impairment was used for patient self-assessment. The subscale scores ranged from 0 to 50, and the total ranged

from 0 to 150, with a higher score indicating a greater degree of disability.

Voice acoustic analysis data were analyzed with the Multi Dimensional Voice Programme (MDVP, Kay Elemetrics Corp., Lincoln Park, USA): the sustained vowel /a/ was recorded. In our study, 5 variables were considered: jitter (Jitt%) and a coefficient of variation of fundamental frequency (vF0) for short and middle term pitch perturbation analysis, shimmer (Shim%) and a coefficient of variation of amplitude (vAm) for short and middle term amplitude perturbation analysis, and noise to harmonic ratio (NHR). Acoustic analysis was feasible in 46 cases (28 UVFP patients and 18 of the soft tissue defects group), but in the remaining 20, the voice signal was too aperiodic to be analyzed.

#### *Statistical analysis*

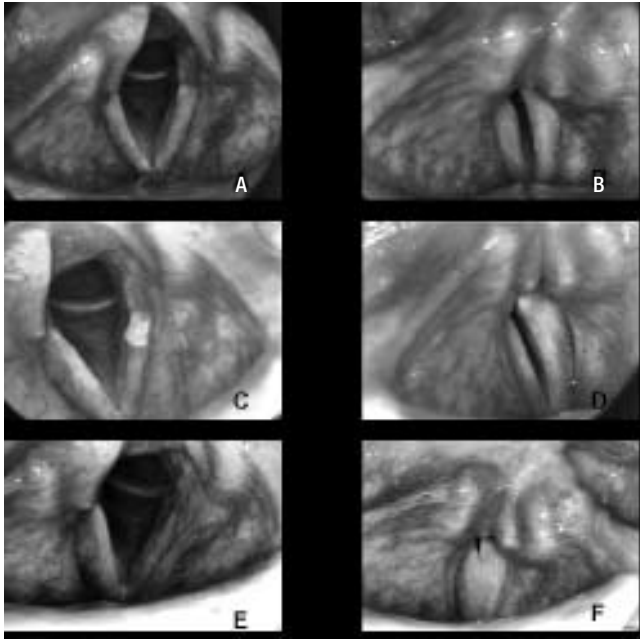
Data are presented as the mean  $\pm$  standard deviation (SD). For the intergroup comparison of data gathered before surgery, the exact Mann-Whitney test was used for continuous variables, and the exact Fisher test was used for ordinal variables. The exact Wilcoxon test was used to compare the data before surgery and after 3 and 6 months follow-up in each group. Two-sided exact tests were used, and p values of less than 0.05 were considered to be significant. A General Linear Model (GLM) for repeated measures was used to investigate changes in the primary outcome variables of MPT, Jitt%, vF0, Shim%, vAm, NHR, GRB, and VHI from baseline and at 3 and 6 months after surgery and if the variations differed between the 2 groups of patients. All statistics were calculated using the Statistical Package for the Social Sciences 17.0 for Windows software package (SPSS Inc, Chicago, IL).

## **Results**

The 2 groups under study were similar as far as concerns the distributions of age and sex ( $p = ns$ ), and at the baseline evaluation, they differed only in the acoustic variable Jitt% ( $p = 0.035$ ) and the perceptual voice measures of G ( $p = 0.003$ ) and B ( $p = 0.004$ ) of the GRBAS scale, which were higher in the UVFP group than in the soft tissue defects group.

All patients had an uneventful post-operative course. None of them presented stridor at any time. No donor site morbidity occurred in any patient.

Videostroboscopy defined the type and entity of the glottic insufficiency and provided evidence that all treated patients achieved an improvement in glottic closure after surgery, although in most patients with soft tissue defects, the mucosal wave showed a reduced amplitude. The videolaryngoscopic images obtained in a UVFP patient, before and after surgery, are shown in Figure 2; in this patient, at 6 months' post-operatively, complete glottic closure was achieved.



**Fig. 2.** A-B): Pre-operative videolaryngoscopy in a man with right UVFP for 19 months: wide gap of glottic closure on phonation (B). C-D): At 3 months post-op, glottic gap is reduced. E-F): At 6 months: complete glottic closure is achieved (F).

The GLM analysis indicated significant improvements in the following outcome measures: MPT ( $p = 0.022$ ), VHI-functional subscale ( $p = 0.002$ ), VHI- physical subscale ( $p < 0.001$ ), VHI- emotional subscale ( $p < 0.001$ ), VHI-total ( $p < 0.001$ ), G ( $p < 0.001$ ) and B ( $p = 0.001$ ) in both groups. For all these variables (Table I and Figures 3- 5), changes from baseline showed that the achieved improvements were already significant at 3 months after surgery (MPT:  $p = 0.005$ , VHI- functional subscale:  $p = 0.006$ , VHI- physical subscale:  $p < 0.001$ , VHI- emotional subscale  $p = 0.006$ , VHI-total:  $p < 0.001$ , G:  $p = 0.002$ , B:

$p < 0.001$ ) and that they were maintained in both groups (all  $p = ns$ ) during the subsequent follow-up (from 3 to 6 months after surgery) (Table I).

The GLM analysis of deviance disclosed a greater reduction in the VHI functional subscale in patients with UVFP than in those with soft tissue defects after 6 months of follow-up ( $p = 0.034$ ). No significant difference was found in the degrees of improvement between groups for MPT and total VHI, although when follow-up ended, the patients with UVFP had higher MPT and lower VHI scores than patients with vocal fold soft tissue defects.

In both groups, both the MPT and total VHI further improved from 3 to 6 months postoperatively as clearly shown by the graphs in Figures 3-4, although this positive trend was not statistically significant.

The acoustic indices behaved differently in the 2 groups: only in the UVFP patients did the Jitt%, vF0, Shim% and NHR improve significantly ( $p = < 0.001$ , 0.001, 0.001, 0.027, respectively) during the first 3 months of follow-up; in the other group, the same variables remained statistically unchanged. Conversely, after the fat injection, vAm remained unchanged in both groups ( $p = ns$ ).

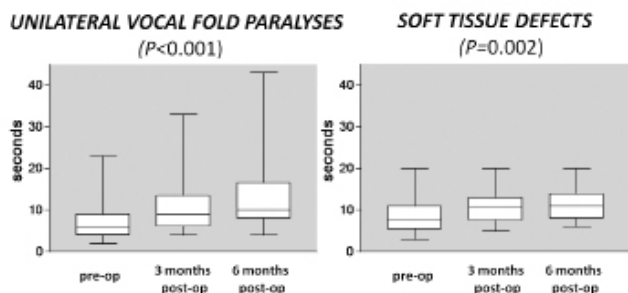
The variable G ( $p = 0.014$ ) improved in both groups, and no significant difference was found in the degree of improvement at 3 and 6 months between the 2 groups. Nevertheless, when follow-up ended, 38% of patients with UVFP had a normal voice and 52% had a slight voice disturbance according to GRBAS evaluation, whereas no patients in the other group had a normal voice and 50% still manifested a moderate disturbance (see Fig. 5).

The variable B behaved similarly to G. Although the baseline values were worse in the UVFP group, a significant improvement occurred for both groups at 3 months after surgery ( $p < 0.001$ ), and a further improvement, which was not statistically significant, was seen at the 6 month

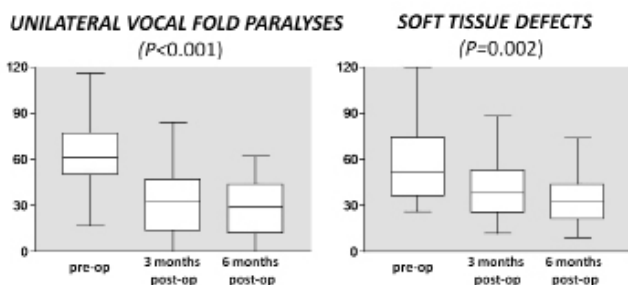
**Table I.** Outcome variables assessed before surgery and at 3 and 6 months follow-up in the 43 patients with unilateral vocal fold paralysis (UVFP) and 23 with vocal fold scarring. Data are displayed as mean  $\pm$  standard deviation.

	Unilateral vocal fold paralysis			Vocal fold soft tissue defects		
	Before surgery	After 3 months	After 6 months	Before surgery	After 3 months	After 6 months
Maximum phonation time (seconds)	7.38 $\pm$ 4.61	10.50 $\pm$ 5.39	13.00 $\pm$ 9.46	8.55 $\pm$ 3.98	10.69 $\pm$ 4.03	11.73 $\pm$ 4.63
Variation coefficient of fundamental frequency	5.09 $\pm$ 4.55	2.21 $\pm$ 1.40	1.81 $\pm$ 1.24	4.56 $\pm$ 6.21	8.27 $\pm$ 12.37	3.45 $\pm$ 2.07
Jitter (%)	5.28 $\pm$ 5.35	1.98 $\pm$ 1.63	1.79 $\pm$ 1.53	3.26 $\pm$ 3.96	3.10 $\pm$ 2.05	3.08 $\pm$ 1.32
Variation coefficient of amplitude	15.18 $\pm$ 10.38	14.41 $\pm$ 10.60	6.80 $\pm$ 4.86	9.06 $\pm$ 5.47	11.39 $\pm$ 11.46	12.04 $\pm$ 7.75
Shimmer (%)	9.02 $\pm$ 8.65	5.49 $\pm$ 3.23	4.96 $\pm$ 3.41	7.55 $\pm$ 6.07	7.85 $\pm$ 6.33	7.93 $\pm$ 2.67
Noise to harmonic ratio (%)	1.08 $\pm$ 3.53	0.16 $\pm$ 0.06	0.14 $\pm$ 0.04	1.42 $\pm$ 4.09	1.01 $\pm$ 2.37	1.07 $\pm$ 0.06
VHI - functional subscale	25.50 $\pm$ 10.21	11.83 $\pm$ 6.83	9.33 $\pm$ 5.79	17.25 $\pm$ 9.08	15.50 $\pm$ 6.74	13.25 $\pm$ 7.69
VHI - physical subscale	25.92 $\pm$ 9.60	10.08 $\pm$ 6.11	10.83 $\pm$ 6.38	27.13 $\pm$ 8.77	16.13 $\pm$ 4.19	15.25 $\pm$ 6.02
VHI - emotional subscale	17.21 $\pm$ 10.05	9.50 $\pm$ 6.72	8.50 $\pm$ 7.97	20.83 $\pm$ 10.02	10.00 $\pm$ 8.19	5.88 $\pm$ 3.60
VHI - total	72.25 $\pm$ 25.07	31.42 $\pm$ 13.93	28.67 $\pm$ 13.36	58.00 $\pm$ 24.36	40.38 $\pm$ 17.00	34.38 $\pm$ 14.36





**Fig. 3.** Maximum phonation time (in seconds) in unilateral vocal fold paralyses (UVFP) and soft tissue defects groups.



**Fig. 4.** Total Voice Handicap Index (VHI) scores in the two groups of patients under study before vocal fold fat injection, and 3 and 6 months post-operatively.

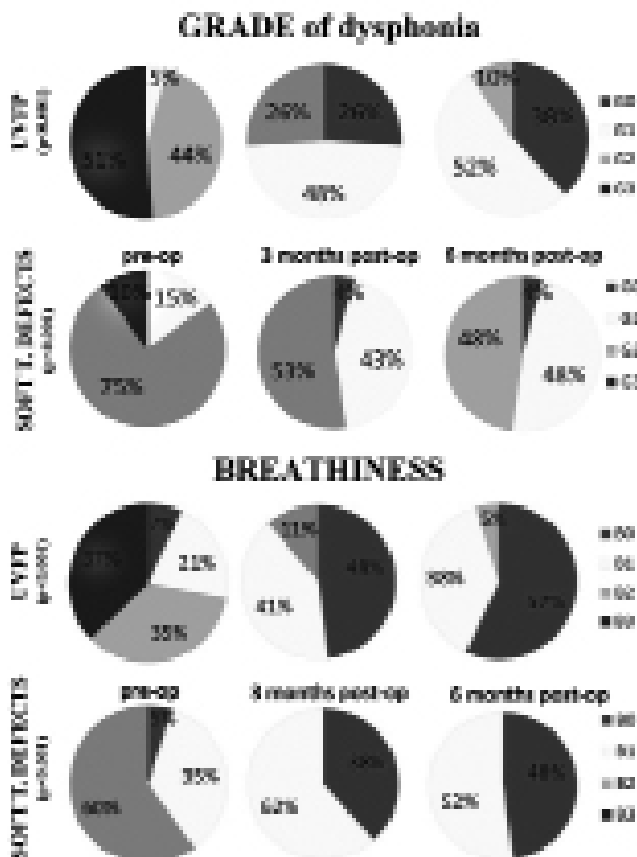
evaluation (Fig. 5). For the variable R, only the UVFP patients significantly improved at 3 and 6 months after surgery ( $p = 0.002$ ), while for the soft tissue defects patients, the improvement was borderline ( $p = 0.054$ ).

### Discussion

The reported results demonstrate that structural fat grafting is an effective technique for vocal fold augmentation to treat breathy dysphonia and vocal fatigue due to glottic insufficiency. All patients underwent vocal fold fat injection according to the technique described by Coleman<sup>22,24</sup> for fat processing and refinement. A crucial factor in allowing the grafted fat to survive to ensure stable results over time is the modality of fat handling for minimizing the resorption rate. The variability in results reported in the literature with vocal fold lipoinjection might depend on the various techniques applied<sup>8,9,27</sup>.

In our case series, another technical point that probably enhanced the voice results was that in 10 of the 43 patients with UVFP, all of whom had particularly severe glottic insufficiency, we also injected the normal moving vocal fold.

In the patients with UVFP and those with soft tissue defects, the primary outcome measures of MPT, GRB and VHI scores improved significantly after lipoinjection, while the acoustic indices significantly improved after surgery only in patients with UVFP. This was an expected finding considering the severe vibratory impairment typi-



**Fig. 5.** Distribution of dysphonia grade (G) and breathiness (B) in unilateral vocal fold paralyses (upper row) and vocal fold soft tissue defects (lower row) before surgery, and 3 and 6 months post-operatively.

cally found in patients with defective vocal fold soft tissues. The grade of dysphonia evaluated by the GRBAS scale and the VHI functional subscale also improved more in the UVFP group than in the soft tissue defects group. Interestingly, maximum phonation time was longer, though not significantly, at 6 months postoperatively than at 3 months, especially in patients with UVFP, indicating that the glottic closure progressively improved over time (Fig. 3). Further improvement at the 6-month follow-up was also found for the VHI scores and for the variables G and B in both groups (Figs. 4, 5) and for the acoustic parameters in the UVFP group only (Table I).

The multidimensional approach we used to assess our patients' outcome provided reliable data and confirmed previous reports that paralytic dysphonia due to UVFP has a more favourable prognosis than soft tissue defects in the vocal folds<sup>28</sup>. Our finding that the results differed in the 2 groups of patients statistically confirmed that the aetiology of glottic insufficiency is a critical factor for prognosis when performing injection laryngoplasty. In patients with UVFP, the anatomy of the cover is preserved, and an efficient vocal fold vibration can be restored if augmentation closes the phonatory glottic gap. Conversely, vocal fold scarring and congenital anoma-

lies such as sulcus vocalis can cause stiffness in the gliding tissue in the vocal fold "cover"<sup>29</sup> and consequently reduce the amplitude of the mucosal wave. An anatomical impairment of the vocal fold gliding cover is a challenging condition to treat because restoring the missing or compromised lamina propria remains one of the main surgical dilemmas in vocal fold microsurgery<sup>28</sup>. In the case of discontinuity of the lamina propria, vocal fold augmentation may reduce the phonatory gap and the air leak and can partially restore the viscoelastic properties of the glottic vibrator. Indeed, in our series, surgery reduced the phonatory gap in all patients, although it failed to normalize the mucosal wave amplitude if the soft tissue defects were present. In their study, Chan and Titze<sup>30</sup> demonstrated that the viscosity of fat is similar to the extracellular matrix in Reinke's space; hence, if fat is injected also in the vocal fold cover, vibration should remain unimpaired. This represents an important point, as the currently available biomaterials do not have rheologic properties adequate to replace the lamina propria<sup>31</sup>. Moreover, non-reabsorbable implants, such as Teflon and silicone, can migrate and give rise to foreign body reactions<sup>32</sup>, and biomaterials, such as collagen, can cause delayed hypersensitivity reactions<sup>33</sup> and vocal fold stiffness from fibrosis<sup>34</sup>. Autogenous fat is non-invasively obtained by liposuction, and it is soft and easily diffuses in the multiple layers of the vocal fold. It is a vital "filler", and the recent studies highlighting the presence of pluripotent stem cells in its stromal vascular fraction support the regenerative potential of adipose tissue for permanently augmenting defective vocal folds<sup>16</sup>. The positive trend over time in the main outcome measures in our study seems to confirm that vocal fold tissues continue to improve even 3 months after lipoinjection and supports the hypothesis of a regenerative role played by the adipose derived stem cells.

In conclusion, vocal fold structural fat grafting is a straightforward and minimally invasive procedure for the rehabilitation of dysphonia in cases of glottic insufficiency, and although UVFP has a more favourable prognosis, patients with vocal fold soft tissue defects can also expect a significant improvement.

## References

- 1 Ward PH, Hanson DG, Abemayor E. *Transcutaneous Teflon injection of the paralyzed vocal cord: a new technique*. Laryngoscope 1985;95:644-9.
- 2 Rosen CA, Gartner-Schmidt J, Casiano R, et al. *Vocal fold augmentation with calcium hydroxylapatite (CaHA)*. Otolaryngol Head Neck Surg 2007;136:198-204.
- 3 Remacle M, Lawson G. *Results with collagen injection into the vocal folds for medialization*. Curr Opin Otolaryngol Head Neck Surg 2007;15:148-52.
- 4 Hertegard S, Hallen L, Laurent C, et al. *Cross-linked hyaluronan used as augmentation substance for treatment of glottal insufficiency: safety aspects and vocal fold function*. Laryngoscope 2002;112:2211-9.
- 5 Mikaelian DO, Lowry LD, Sataloff RT. *Lipoinjection for unilateral vocal cord paralysis*. Laryngoscope 1991;101:465-8.
- 6 Brandenburg JH, Kirkham W, Koschke D. *Vocal cord augmentation with autogenous fat*. Laryngoscope 1992;102:495-500.
- 7 Shindo ML, Zaretsky LS, Rice DH. *Autologous fat injection for unilateral vocal fold paralysis*. Ann Otol Rhinol Laryngol 1996;105:602-6.
- 8 McCulloch TM, Andrews BT, Hoffman HT, et al. *Long-term follow-up of fat injection laryngoplasty for unilateral vocal cord paralysis*. Laryngoscope 2002;112:1235-8.
- 9 Laccourreye O, Papon JF, Kania R, et al. *Intracordal injection of autologous fat in patients with unilateral laryngeal nerve paralysis: long-term results from the patient's perspective*. Laryngoscope 2003;113:541-5.
- 10 Chen YY, Pai L, Lin YS, et al. *Fat augmentation for nonparalytic glottic insufficiency*. ORL 2003;65:176-83.
- 11 Pinto JA, da Silva Freitas ML, Carpes AF, et al. *Autologous grafts for treatment of vocal sulcus and atrophy*. Otolaryngol Head Neck Surg 2007;137:785-91.
- 12 Coleman SR. *Overview of structural fat grafting*. In: *Fat injection: from filling to regeneration*. St. Louis: Quality Medical Publishing; 2009, p. 93-110.
- 13 Zuk PA, Zhu M, Ashjian P, et al. *Human adipose tissue is a source of multipotent stem cells*. Mol Biol Cell 2002;13:4279-95.
- 14 Tholpady SS, Llull R, Ogle RC, et al. *Adipose tissue: stem cells and beyond*. Clin Plast Surg 2006;33:55-62, vi.
- 15 Rehman J, Traktuev D, Li J, et al. *Secretion of angiogenic and antiapoptotic factors by human adipose stromal cells*. Circulation 2004;109:1292-8.
- 16 Lo Cicero V, Montelatici E, Cantarella G, et al. *Do mesenchymal stem cells play a role in vocal fold fat graft survival?* Cell Prolif 2008;41:460-73.
- 17 Fang TJ, Lee LA, Wang CJ, et al. *Intracordal fat assessment by 3-dimensional imaging after autologous fat injection in patients with thyroidectomy-induced unilateral vocal cord paralysis*. Surgery 2009;146:82-7.
- 18 Fang TJ, Li HY, Gliklich RE, et al. *Outcomes of fat injection laryngoplasty in unilateral vocal cord paralysis*. Arch Otolaryngol Head Neck Surg 2010;136:457-62.
- 19 Hsiung MW, Lin YS, Su WF, et al. *Autogenous fat injection for vocal fold atrophy*. Eur Arch Otorhinolaryngol 2003;260:469-74.
- 20 Sataloff RT, Spiegel JR, Hawkshaw M, et al. *Autologous fat implantation for vocal fold scar: a preliminary report*. J Voice 1997;11:238-46.
- 21 Neuenschwander MC, Sataloff RT, Abaza MM, et al. *Management of vocal fold scar with autologous fat implantation: perceptual results*. J Voice 2001;15:295-304.
- 22 Coleman SR. *Facial recontouring with lipostructure*. Clin Plast Surg 1997;24:347-67.
- 23 Cantarella G, Mazzola RF, Domenichini E, et al. *Vocal fold augmentation by autologous fat injection with lipostructure procedure*. Otolaryngol Head Neck Surg 2005;132:239-43.

- <sup>24</sup> Cantarella G, Mazzola RF. *Vocal fold augmentation by autologous fat injection*. In: *Fat injection: from filling to regeneration*. St. Louis: Quality Medical Publishing; 2009. p. 717-34.
- <sup>25</sup> Hirano M. *Clinical examination of voice*. In: Arnold GE, Winckel BD, Wyke BD, editors. *Disorders of human communication*. New York: Springer Verlag; 1981. p. 81-4.
- <sup>26</sup> Jacobson BH, Johnson A, Grywalsky A, et al. *The voice handicap index: development and validation*. *Am J Speech Lang Pathol* 1997;6:66-70.
- <sup>27</sup> Shaw GY, Szewczyk MA, Searle J, et al. *Autologous fat injection into the vocal folds: technical considerations and long-term follow-up*. *Laryngoscope* 1997;107:177-86.
- <sup>28</sup> Sataloff RT. *Autologous fat implantation for vocal fold scar*. *Curr Opin Otolaryngol Head Neck Surg* 2010;18:503-6.
- <sup>29</sup> Hirano M, Kakita Y. *Cover-body theory of vocal fold vibration*. In: Daniloff RC, editor. *Speech Science*. San Diego: College-Hill Press; 1985. p. 1-46.
- <sup>30</sup> Chan RW, Titze IR. *Viscosities of implantable biomaterials in vocal fold augmentation surgery*. *Laryngoscope* 1998;108:725-31.
- <sup>31</sup> Kimura M, Mau T, Chan RW. *Viscoelastic properties of phonosurgical biomaterials at phonatory frequencies*. *Laryngoscope* 2010;120:764-8.
- <sup>32</sup> Kasperbauer JL, Slavitt DH, Maragos NE. *Teflon granules and overinjection of Teflon: a therapeutic challenge for the otorhinolaryngologist*. *Ann Otol Rhinol Laryngol* 1993;102:748-51.
- <sup>33</sup> Takayama E, Ikeda M, Tsuru S, et al. *Is injectable collagen truly safe?* *J Laryngol Otol* 1992;106:704-8.
- <sup>34</sup> Spiegel JR, Sataloff RT, Gould WJ. *The treatment of vocal fold paralysis with injectable collagen: clinical concerns*. *J Voice* 1987;1:119-21.

Received: March 4, 2011 - Accepted: April 3, 2011