

# Chronic cerebro-spinal insufficiency in multiple sclerosis and meniere disease: same background, different patterns?

Pietro Maria Bavera,<sup>1,2</sup>

Federica Di Bernardino,<sup>3</sup> Piero Cecconi,<sup>2</sup>

Laura Mendozzi,<sup>2</sup> Valentina Mattei,<sup>2</sup>

Dario Carlo Alpini<sup>2,4</sup>

<sup>1</sup>Vascular Imaging Diagnostician for Medick-Up Vascular Lab, Milan;

<sup>2</sup>Department of Clinical Sciences, University of Milan, and Audiology Unit, Fondazione IRCCS Ca' Granda Ospedale Maggiore Policlinico, Milan;

<sup>3</sup>IRCCS S. Maria Nascente don Carlo Gnocchi Foundation, Milan;

<sup>4</sup>Vertigo School, Milan Italy

## Abstract

Multiple sclerosis (MS) is a chronic disease of the central nervous system characterized by demyelinating lesions with acute phases and progressive loss of sensorimotor functions. Ménière disease (MD) is a disorder of the inner ear characterized by acute spells of vertigo and hearing loss and progressive loss of cochleo-vestibular function. Both the diseases have a multifactorial pathogenesis and quite the same chronic cerebro-spinal insufficiency (CCSVI) frequency. However, as far as Author's knowledge concerns, no patients affected with both diseases are described so far. The aim of this paper is to investigate whether MS and MD present different CCSVI patterns. Three groups of patients were enrolled: 60 definite MS - 27 definite unilateral MD (MEN) - 41 with other no-Ménière, audio-vestibular disorders (OVD). All subjects underwent magnetic resonance venography (MRV) and venous Duplex (ECD) and only patients that satisfied both MRV and ECD CCSVI diagnostic criteria were considered. J1 was normal in 57% of MS, 88% of MEN and 95% of OVD. Stenosis (ST) were detected, respectively, in 30% of MS and 2% in MEN and OVD. J2 was normal in 78% of MS, 64% of MEN and 95% of OVD. At this level alterations of the trunk (AT) were detected in 17% in MS and 26% in MEN; J3 was normal in 74% of MS, 64% of MEN and 86% of OVD. AT were found in 15% of MS, 26% of MEN and 8% of OVD. Hyperplasia of the Vertebral Veins was observed in 35% of MS, 40% of MEN and in 15% of OVD. Other compensatory collaterals were detected in 25% in MS and

only in 5% in MEN and OVD. Our results indicate that the *MS pattern* is characterized by J1 stenosis, J2 trunk alterations, a prevalence of J1-J2 medial-distal alterations, compensatory collaterals besides vertebral venous system. *MD pattern* is characterized by trunk alteration in J3, a prevalence of J3-J2 medial-proximal alterations and vertebral veins hyperplasia without other detectable collaterals. Although the group of patients with venous alterations is very small, OVD patients show a CCSVI pattern that is more similar to MD than MS pattern. The difference between MS and MD patterns indicates that CCSVI is not a unique entity and it could be an explanation of the fact that subjects affected with both the diseases are not reported.

## Introduction

Multiple Sclerosis (MS) is a chronic disease of the Central Nervous System characterized by demyelinating lesions. Typical course is alternating of acute phases followed by unpredictable periods of remission but, usually, with a progressive loss of sensorial-motor functions. A multifactorial pathogenesis is nowadays accepted<sup>1</sup> even if a unique final autoimmune mechanism is usually considered. Ménière Disease is a disorder of the inner ear characterized by acute spells of vertigo, tinnitus and hearing loss followed by unpredictable period of remission but, usually, with a progressive loss of vestibular and cochlear function. A multifactorial pathogenesis is accepted<sup>2</sup> even if a unique final *hydraulic* mechanism, the so called Endolymphatic Hydrops (EH), is usually considered.<sup>3</sup> Both MS<sup>4-6</sup> and MD<sup>7-9</sup> presents quite the same frequency of cerebro-cervical venous abnormalities as evaluated by means of Magnetic Resonance Venography (MRV) or Duplex exam (ECD) adopting the criteria for the diagnosis of chronic cerebro-spinal insufficiency (CCSVI).<sup>10</sup> Despite this, as far as Author's knowledge concerns, no patients affected with MS and MD are reported in Literature, so far.

The aim of this paper is to investigate if MS and MD present different CCSVI patterns.

## Materials and Methods

Three groups of patients were enrolled: 60 definite Multiple Sclerosis (MS, 43 females and 17 males, mean age 43.7 yy); 27 definite unilateral Ménière Disease (MEN, 17 females and 10 males, mean age

Correspondence: Dario Carlo Alpini, Vertigo School, via Lomellina 58, 20133 Milan, Italy. Fax: +39.02.70105197. E-mail: [vertigoschool5@gmail.com](mailto:vertigoschool5@gmail.com)

Key words: Chronic cerebro-spinal insufficiency; vertebral veins; multiple sclerosis; Ménière disease.

Contribution: PMB designed the experiment and performed Duplex evaluations; PC designed the experiment and analyzed, MRV data; VM performed oto-neurological tests to select audio-vestibular patients; DCA designed the experiment and wrote the manuscript, Mendozzi L designed the experiment and selected multiple sclerosis patients; FDB analyzed the data, wrote the manuscript and critically revised the paper for important intellectual content. All the authors contributed to the preparation of the paper

Conflict of interest: the authors declare no potential conflict of interest.

Received for publication: 3 January 2017.

Revision received: 12 February 2017.

Accepted for publication: 14 February 2017.

This work is licensed under a Creative Commons Attribution 4.0 License (by-nc 4.0).

©Copyright P.M. Bavera et al., 2017

Licensee PAGEPress, Italy

*Veins and Lymphatics* 2017; 6:6533

doi:10.4081/vl.2017.6533

41.5 yy);<sup>11</sup> 41 other vestibular disorders (OVD, 28 females and 13 males, mean age 43.3 yy). These subjects presented unilateral hearing loss and vestibular hypofunction due to different cases: 8 otosclerosis, 3 acoustic neuroma in the othologic phase, 9 inner ear vascular disorders (so called Lyndasy-Hemenway Syndrome), 21 vestibular neuritis.<sup>12</sup>

Multiple Sclerosis diagnoses were performed by a trained neurologist (ML). Diagnosis of MEN or OVD were based on clinical and audio-vestibular investigations by the same audiologist (MV) that was unaware of the MRV and ECD results. The exclusion criteria comprised, for all three groups of patients: retro cochlear lesion or other known anatomic/structural lesions of the ear, temporal bone or head trauma, syndrome features or congenital othologic abnormalities. Furthermore in MEN and OVD groups any known central nervous system disease.

The work was carried out in accordance with the Declaration of Helsinki, including, but not limited to there being no potential harm to participants, guaranteed anonymity

of participants, and informed consent.

All subjects underwent magnetic resonance imaging of the brain during which contrast enhanced imaging of the venous cerebro cervical system was also performed in order to assess the condition of the Internal Jugular Veins (IJVs) and vertebral veins (VVs) and evaluated by the same neuroradiologist (CP) who had no knowledge of the clinical diagnosis. Magnetic Resonance was performed using a 1.5 T scanner with a standardized imaging protocol consisting of axial and coronal fast spin-echo T2-weighted imaging and axial and sagittal spin-echo T1-weighted imaging. The intracranial and cervical venous systems were investigated using computer-based magnetic resonance venography (MRV) performed in three standard orienta-

tions (transverse, coronal, and sagittal). A maximum-intensity projection algorithm was used to display three-dimensional MRV reconstruction angiograms. The subjects underwent contrast-enhanced MRV in the supine position and the right and left cross-sectional areas (CSA) of the IJVs and VVs were compared. Asymmetrical venous flow in the IJVs and VVs was functionally investigated using venous Duplex (ECD) (randomly carried out by Esaote or General Electric with similar probes and settings, by well-trained specialists (BPM), that was unaware of the clinical diagnosis. Duplex was performed at 0° and 90° according to the CCSVI protocol and was considered confirmatory of MRV findings when at least two of the five CCSVI criteria were satisfied.<sup>10,13,14</sup>

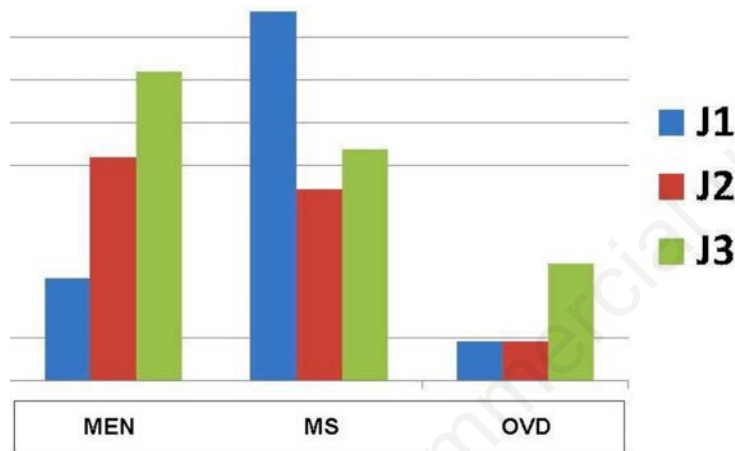
Three pathological conditions have been taken in account: stenosis (ST), VVs hyperplasia (VVH) and alterations of the trunk (AT).

ST was so defined when CSA was less than 0.5 cm<sup>2</sup>, or, at ECD evaluation, if CSA in supine position was smaller than in upright position VVH was so defined when CSA was more than 0.5 cm<sup>2</sup>.

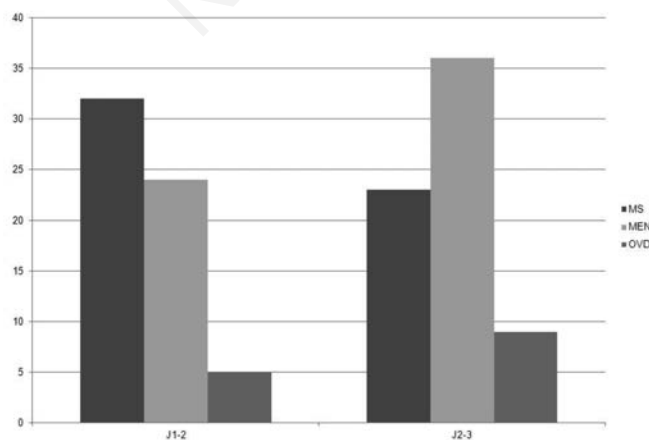
AT was based on ECD findings and included structural abnormalities such as flaps, septa or malformed/immobile valves.

### Statistical analysis

The statistical analysis was carried out by an independent well-trained audiologist (DF) with Statistics 6.1 software (Stat. Soft Inc., Tulsa, OK, USA). Between-group comparisons were made using analysis of variance (ANOVA). Frequencies were compared using the Chi-squared. A P value of <0.05 was considered to be statistically significant.



**Figure 1** Distribution of IJVs anatomic alterations in relationship with topographic segments. IJVs alterations are substantially rare in OVD and, above all, how in MS J1 alterations are more represented while J3 is the specific MEN abnormal segment.



**Figure 2.** Regional distribution of IJVs alterations. Regional distribution is significantly different between MS and MEN with medial-distal prevalence in MS and medial-proximal prevalence in MEN.

### Results

MRV-ECD showed IJVs alterations, any level, in 32 (53%) MS, 13 (46%) MEN and 6 (16%) OVD with significant difference between MS-MEN and OVD but not between MS and MEN.

J1 was normal in 34 (57%) MS, 24 (88%) MEN and 38 (95%) OVD. While comparison between MS and MEN was significant ( $P < 0.001$ ), difference between MEN and OVD were not. ST were detected, respectively, in 30% in MS and 2% in MEN and OVD; AT in 13% of MS, 10% of MEN and 3% of OVD. Therefore, J1 stenosis specifically regards MS rather than MEN and OVD ( $P < 0.001$ ).

J2 was normal in 47 (78%) MS, 17 (64%) MEN and 38 (95%) OVD. While comparison between MS and MEN *versus* OVD was significant ( $P < 0.001$ ) difference between MS and MEN were not, but AT were detected in 10(17%) MS and 7 (26%) MEN. Thus, even if the P-level is low ( $P < 0.05$ ) J2 AT is more represented in MS than in MEN.

J3 was normal in 44 (74%) MS, 17(64%) MEN and 35 (86%) OVD. At this level difference between MEN and OVD is low ( $P = 0.04$ ). Even the difference between MS and MEN is less stronger than in J1 and J2 ( $P = 0.005$ ).

ST were detected, respectively, in 7 (11%) MS and 3 (10%) MEN and 2 (6%) OVD; AT were found in 9 (15%) MS, 7 (26%) MEN and 3 (8%) OVD. Even differences are not statistically significant, J3 AT seems more represented in MEN than in the

other two groups. Figure 1 clearly shows the different patterns of topographic segment alterations distribution, into the three groups with prevalence of alterations in J1 in MS and in J3 in MEN.

Adopting a “regional” criterion, J1-J2 may be considered as medial-distal IJVs alterations while J2-J3 as medial-proximal alterations. “Regional” IJVs abnormalities difference between MS and MEN (Figure 2) with a higher prevalence of J2-J3 alterations in MEN (10 patients, 37%) than in MS (14 patients, 23%) and a higher prevalence of J1-J2 in MS (19 patients 32%) than in MEN (6 patients 22%). Differences are significant at  $P < 0.05$ .

Hyperplasia of the Vertebral Venous system was observed in 21 (35%) MS, 11 (40%) MEN and in 6 (15%) OVD. While difference between MS and MEN *versus* OVD was significant, difference between MS and MEN was not. Other compensatory collaterals were detected in 15 (25%) MS and only in 2 (5%) MEN and OVD.

## Discussion and Conclusions

Our results clearly show that CCSVI may be considered as a typical condition both in MS and MD but is substantially rare in other kind of audio-vestibular disorders.

If CCSVI may be considered a cause per se or the anatomical condition for triggering the effect of other factors may be debated. Anyway, our experience points out that CCSVI is not a unique disorder and that the venous abnormalities pattern might be disease specific. MS is a typical demyelinating disease but demyelination of the vestibular nerve has been described in patients affected with MD, too.<sup>15</sup> Although the hydraulic mechanism of EH is substantially worldwide accepted, there are evidence of MD patients without EH<sup>16</sup> and EH without MD symptoms<sup>17</sup> and Gacek<sup>18</sup> proposed a neuropathic viral mechanism in MD pathogenesis.

May CCSVI, that is considered to be correlated to MS Central Nervous System demyelination, be connectable to vestibular nerve demyelination in MD, too? It is difficult to answer but our experience highlights the fact that in MD patients IJVs alterations regard the proximal segment.

Anyway, CCSVI pattern seems to be substantially different in MS and in MD.

Our results indicate that the *MS pattern* is characterized by J1 stenosis, J2 alterations trunk, a prevalence of J1-J2 medial-distal alterations, compensatory collaterals besides vertebral venous system. On the other hand, *MEN pattern* is characterized by

alteration trunks in J3, a prevalence of J3-J2 medial-proximal alterations and vertebral venous hyperplasia without other detectable collaterals.

On the other hand the role of the origin of the IJVs, that to say the jugular bulb in Ménière Disease is known.<sup>19</sup>

Several studies analyzing the temporal bone imaging<sup>20</sup> or anatomy in MD patients have found consistent alterations in the arrangement of the sigmoid sinus, anteriorly or medially displaced, and jugular bulb abnormalities. According to Redfern *et al.*<sup>21</sup> and Park *et al.*<sup>22</sup> there is a higher frequency of jugular bulb abnormalities in patients with MD than in patients without inner ear symptoms, particularly, the mediolateral and anteroposterior position of the jugular bulb determines encroachment of the surrounding structures. Authors postulated that abnormal position contributes to MD development and that temporal bones of MD patients might be constituted anatomically different, carrying predisposing factors for the development of clinically apparent MD. These findings resemble to our findings: IJVs in general and J3 alterations are significantly highest in MD than in OVD.

The disease-specificity of venous abnormalities was recently reported also by Vannini *et al.*<sup>23</sup> that described different morphology of IJVs' valves in MD patients with respect to Normals and Sudden Neurosensorial Hearing Loss patients.

It is interesting to note that Burcon<sup>24</sup> observed in MD patients a frequent involvement of the upper cervical spine dysfunction, particularly C1 and C2, that the author correlated to vertigo, C1, and hearing loss, C2. It is interesting to underline that in OVD VVs hyperplasia is highly represented than J1-J2 alterations but similarly to J3 abnormalities: VVs 15% - J3 14%. Both Vertebral Veins and proximal Jugular segment are anatomically placed in C1-C2 region and this fact supports the role of upper cervical venous drainage to explain Burcon's paper. Furthermore, Franz *et al.*<sup>25</sup> postulated a cervicogenic disorder, mainly trigeminal based mechanism, as forerunner of MD. Also in this case a *venous* explanation might be coupled to Franz's trigeminal mechanism as happens in migraine patients.<sup>26</sup>

The key point of the paper of Merchant *et al.*<sup>17</sup> conducted on temporal bone cases with a clinical diagnosis of MD or a histopathologic EH diagnosis, is that hydrops per se is not the cause of MD while there are evidences of cellular and molecular bases of the various MD symptoms.<sup>11</sup>

Thus, a specific anatomical abnormality of the temporal bone, regarding the jugular bulb, and/or the highest portion of the cere-

bro-cervical venous drainage system, as shown in this paper through MRV and ECD, may lead to abnormal clearance of audio-vestibular structures inducing citochemical change similar to those observed in MS CCSVI positive patients.

It is interesting to reveal that, although the group of patients with venous alterations is very small, OVD patients show a CCSVI pattern more similar to MD than MS pattern, thus it is reasonable to conclude that CCSVI is not a unique entity and that *neurological* (MS) pattern is distinguishable from the *audiologic* (MD and OVD) pattern. In Author's opinion this explains the fact that no patients affected with MS and MD are reported in Literature.

## References

1. Lassmann H, Bruck W, Lucchinetti CF. The immunopathology of multiple sclerosis: an overview. *Brain Pathol* 2007;17:210-8.
2. Paparella MM. The cause (multifactorial inheritance) and pathogenesis (endolymphatic malabsorption) of Meniere's disease and its symptoms (mechanical and chemical) *Acta Otolaryngol* (Stockh) 1985;99:445-51.
3. Sajjadi H, Paparella MM. Meniere's disease. *Lancet* 2008;372:406-14.
4. Zamboni P, Galeotti R, Menegatti E, et al. Chronic cerebrospinal venous insufficiency in patients with multiple sclerosis. *J Neurol Neurosurg Psychiatry* 2009;80:392-9.
5. Zamboni P, Menegatti E, Galeotti R, et al. The value of cerebral Doppler venous haemodynamics in the assessment of multiple sclerosis. *J Neurol Sci* 2009;282:21-7.
6. Zivadinov R, Marr K, Cutter G, et al. Prevalence, sensitivity, and specificity of chronic cerebrospinal venous insufficiency in MS. *Neurology* 2011;77:138-44.
7. Alpini D, Bavera PM, Hhan A, Mattei V. Chronic Venous Cerebrospinal Insufficiency (CCSVI) in Meniere Disease. Case or Cause? *Science Med* 2013;4:9-15.
8. Di Berardino F, Alpini DC, Bavera PM, et al. Chronic cerebrospinal venous insufficiency in Ménière disease. *Phlebology* 2015;30:274-9.
9. Filipo R, Ciciarello F, Attanasio G, et al. Chronic cerebrospinal venous insufficiency in patients with Ménière's disease. *Eur Archiv Oto-Rhino-Laryngol* 2015;272:77-82.
10. Zivadinov R, Bastianello S, Dake MD,

- et al. International Society for Neurovascular Disease. Recommendations for multimodal non-invasive and invasive screening for detection of extracranial venous abnormalities indicative of chronic cerebrospinal venous insufficiency: a position statement of the International Society for Neurovascular Disease. *J Vasc Interv Radiol* 2014;25:1785-94.e17
11. Lopez-Escamez JA, Carey J, Chung WH, et al. Diagnostic Criteria for Ménière Disease. *J Vest Res* 2015 [Epub ahead of print].
  12. Baloh RW. *Dizziness, Hearing Loss, and Tinnitus*. New York: Oxford; 1988.
  13. Zamboni P, Morovic S, Menegatti E, et al. Screening for chronic cerebrospinal venous insufficiency (CCSVI) using ultrasound--recommendations for a protocol. *Int Angiol* 2011;30:571-97.
  14. Bavera PM, Agus GB, Alpini DC, et al. Results from 823 consecutive Duplex exams for CCSVI in a Vascular Centre. *Acta Phleb* 2012;13:141-8.
  15. Spencer RF, Simanis A, Kilpatrick JK, Shaia WT. Demyelination of Vestibular Nerve Axons in Unilateral Ménière Disease. *Ear Nose and Throat J* 2002;81:785-9.
  16. Rauch SD, Merchant SN, Thedinger BA. Ménière's syndrome and endolymphatic hydrops: a double-blind temporal bone study. *Ann Otol Rhinol Laryngol* 1989;98:873-83.
  17. Merchant SN, Adams JC, Nadol JB Jr. Pathophysiology of Ménière's Syndrome: Are Symptoms Caused by Endolymphatic Hydrops? *Otol Neurotol* 2005;26:74-81.
  18. Gacek RR. Ménière's disease is a viral neuropathy. *ORL* 2009;71:78-86.
  19. Baloh R. Prosper Ménière and his Disease. *Arch Neurol* 2001;58:1151-6.
  20. Hornibrook J, Coates M, Goh T. MRI imaging of the inner ear for Ménière Disease. *N Z Med J* 2010;123:59-63.
  21. Redfern RE, Brown M, Benson AG. High Jugular Bulb in a Cohort of patients with definite Ménière's Disease. *J Laryngol Otol* 2014;128:759-64.
  22. Park JJ, Shen A, Keil S, et al. Jugular bulb abnormalities in patients with Meniere's disease using high-resolution computed tomography. *Eur Arch Otorhinolaryngol* 2015;272:1879-84.
  23. Vannini ME, Menegatti E, Tessari M, et al. High Resolution M-Mode Characterization of Jugular Veins Valves in Healthy Volunteers and in Patients with Neurological Disorders. Poster at VIth Annual ISNVD Meeting, New York City (USA), 29th april 2016
  24. Burcon TM. Health Outcomes Following Cervical Specific Protocol in 300 Patients with Meniere's Followed Over six Years. *J Upper Cervical Chiropractic Res* 2016;2:13-21.
  25. Franz B, Altidis P, Altidis B, Collis-Brown G. Cervicogenic otoocular syndrome: a suspected forerunner of Ménière's disease. *Int Tinnitus J* 1999;5:125-30.
  26. Koerte IK, Schankin CJ, Immler S, et al. Altered cerebrovenous drainage in patients with migraine as assessed by phase-contrast magnetic resonance imaging. *Invest Radiol* 2011;46:434-40.