

Letters to the Editors

Recurrence of mixed cryoglobulinaemia vasculitis following influenza vaccination despite clearance of hepatitis C virus infection

Sirs,

Mixed cryoglobulinaemia vasculitis (MCV) is a serious autoimmune/lymphoproliferative disease triggered by hepatitis C virus (HCV) in most cases. It is characterised by the presence of circulating cryoprecipitable immune complexes consisting of polyclonal IgGs and mono- or polyclonal IgMs with rheumatoid factor activity. The clinical manifestations of MCV are secondary to systemic vasculitis of the small/medium vessels and range from purpura, arthralgia, and asthenia to severe involvement of the peripheral nervous system and the kidneys (1). Over the last three years, the availability of highly efficacious and well-tolerated direct-acting antivirals (DAAs) used in interferon (IFN)-free regimens has revolutionised the management of HCV infection and opened up new opportunities for the treatment of HCV-associated MCV (HCV-MCV) (2-4). Although viral clearance has been associated with remission of vasculitis (5), long-term outcome of MCV patients who have eradicated HCV remains unclear (6-8). Here, we report a case of recurrence of HCV-MCV following influenza vaccination despite viral clearance after treatment with DAAs.

A 54-year-old man with a history of HCV-MCV with extensive purpura, severe nephrotic syndrome and stage 3 chronic kidney disease was referred to us for treatment with DAAs. He had HCV genotype 2 infection and mild liver fibrosis. Furthermore, he was null-responder to prior therapy with pegIFN/ribavirin and had shown transient clinical response to sequential treatment with high-dose pulse glucocorticoids and rituximab. Laboratory analysis showed HCV RNA of 6×10^6 IU/mL, cryocrit and C4 levels of 9% and 0.01 g/L, respectively, serum creatinine of 2 mg/dL, and proteinuria of 3.9 g/24 hours. On physical examination, there was palpable purpura of the lower limbs. Treatment with sofosbuvir plus ribavirin for 12 weeks was therefore started, with dramatic reduction in HCV RNA, rapid decrease in the cryocrit level and progressive improvement in renal function. Purpura disappeared. At post-treatment week 12, HCV RNA and serum cryoglobulins were undetectable, creatinine was 1.4 mg/dL, and proteinuria 0.4 g/24 hours (Fig. 1). A sustained virological response (SVR) and a complete clinical response were therefore achieved. Two months later, the patient underwent seasonal influenza vaccination, 10 days after which he developed upper and lower limb purpura. Recurrence of vasculitis was associated with reappearance of serum cryoglobulins (cryocrit 8%)

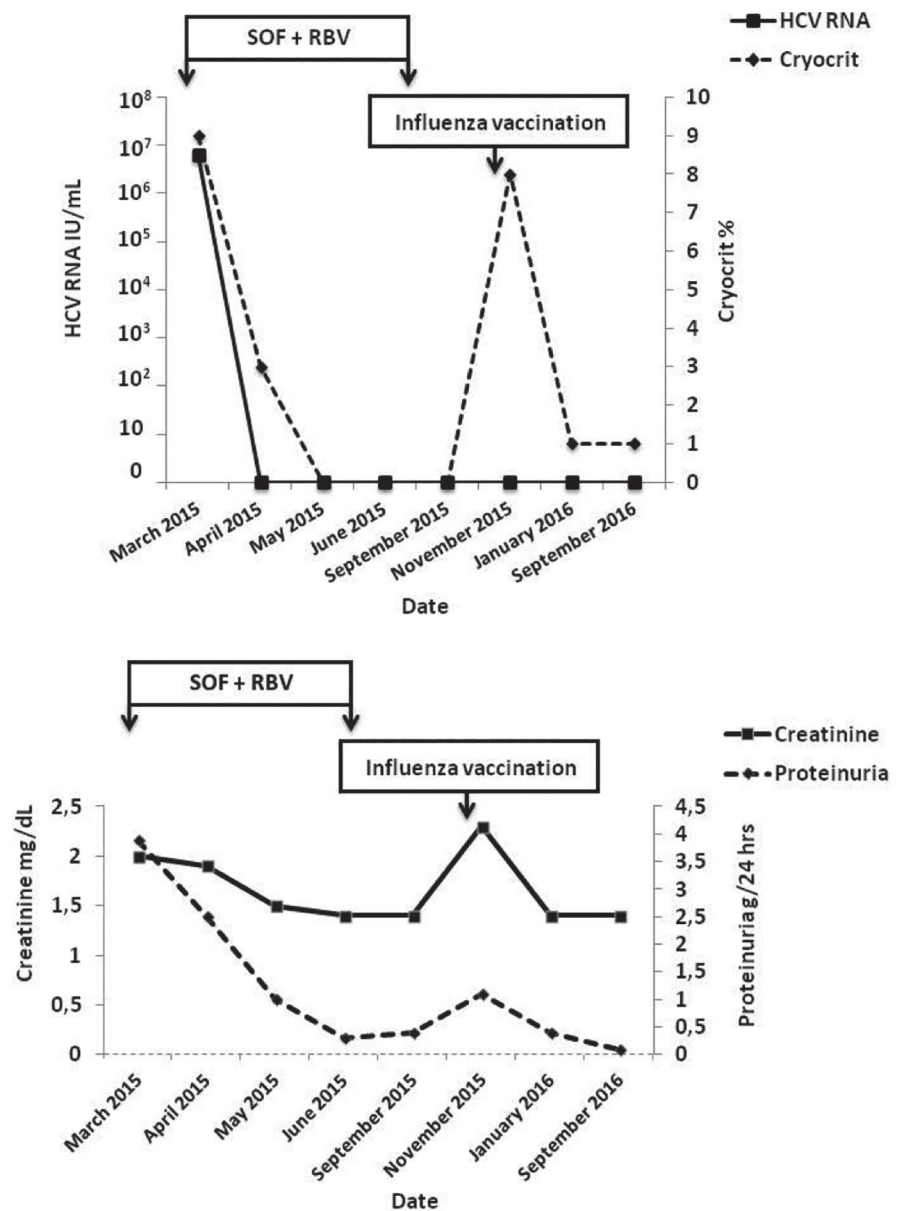


Fig. 1. Changes in the levels of plasma HCV RNA, cryocrit (top panel), serum creatinine and proteinuria (bottom panel) during antiviral therapy with sofosbuvir plus ribavirin and after influenza vaccination. Abbreviations: SOF: sofosbuvir; RBV: ribavirin.

and deterioration of renal function (serum creatinine 2.3 mg/dL, proteinuria 1.1 g/24 hours). HCV RNA was confirmed negative. We closely monitored the patient, who showed a spontaneous, gradual resolution of purpura. The kidney function returned to the pre-vaccination levels within two months. The cryocrit level decreased to 1%, but remained positive (Fig. 1).

MCV is the most frequent extrahepatic manifestation of chronic HCV infection (1). Treatment-induced HCV clearance has been associated with the persistent resolution or at least an improvement of the clinical and laboratory manifestations of HCV-MCV (2-6), although there is increasing evidence of persistent MCV despite virus eradication (7, 8). The latter finding sup-

ports the hypothesis that some cryoglobulin-producing B-cell clones can proliferate independently of the viral trigger, thereby perpetuating vasculitis (7). The same pathogenic mechanism may explain the recurrence of MCV after influenza vaccination in our patient.

To the best of our knowledge, this is the first reported case of vaccine-induced recurrence of HCV-MCV despite the achievement of an SVR to antiviral therapy; only new-onset MCV following influenza or hepatitis B vaccinations in non-HCV-infected subjects was occasionally observed previously (9,10). In the era of IFN-free DAA therapy, long-term effects of HCV eradication in MCV patients remain therefore to be established. New antigenic stim-

Letters to the Editors

uli, including vaccinations, may reactivate latent cryoglobulin-producing B-cell clones in patients who cleared HCV-infection, causing recurrence of vasculitis. However, such recurrences seem self-limited and should not prevent physicians from vaccinating MCV patients when appropriate.

S. SOLLIMA¹,
L. MILAZZO¹,
P. VASSALINI¹,
S. ANTINORI²,
M. GALLI²,

¹III Division of Infectious Diseases, L. Sacco University Hospital, Milan; ²Department of Biomedical and Clinical Sciences L Sacco, University of Milan, Italy.

Address correspondence to:

Dr Salvatore Sollima, III Division of Infectious Diseases, L. Sacco University Hospital, Via GB Grassi, 74, I-20157 Milan, Italy.
E-mail: salvatore.sollima@unimi.it

Competing interests: none declared.

© Copyright CLINICAL AND EXPERIMENTAL RHEUMATOLOGY 2018.

References

1. TERRIER B, CACOUB P: Cryoglobulinemia vasculitis: an update. *Curr Opin Rheumatol* 2013; 25: 10-8.
2. GRAGNANI L, VISENTINI M, FOGNANI E *et al.*: Prospective study of guideline-tailored therapy with direct-acting antivirals for hepatitis C virus-associated mixed cryoglobulinemia. *Hepatology* 2016; 64: 1473-82.
3. SISE ME, BLOOM AK, WISOCKY J *et al.*: Treatment of hepatitis c virus-associated mixed cryoglobulinemia with sofosbuvir-based direct-acting antiviral agents. *Hepatology* 2016; 63: 408-17.
4. EMERY JS, KUCZYNSKI M, LA D *et al.*: Efficacy and safety of direct acting antivirals for the treatment of mixed cryoglobulinemia. *Am J Gastroenterol* 2017; 112: 1298-308.
5. PIETROGRANDE M, DE VITA S, ZIGNEGO AL *et al.*: Recommendations for the management of mixed cryoglobulinemia syndrome in hepatitis C virus-infected patients. *Autoimmun Rev* 2011; 10: 444-54.
6. GRAGNANI L, FOGNANI E, PILUSO A *et al.*: Long-term effect of HCV eradication in patients with mixed cryoglobulinemia: a prospective, controlled, open-label, cohort study. *Hepatology* 2015; 61: 1145-53.
7. SOLLIMA S, MILAZZO L, PERI AM, TORRE A, ANTINORI S, GALLI M: Persistent mixed cryoglobulinaemia vasculitis despite hepatitis C virus eradication after interferon-free antiviral therapy. *Rheumatology (Oxford)* 2016; 55: 2084-5.
8. ARTEMOVA M, ABDURAKHMANOV D, IGNATOVA T, MUKHIN N: Persistent HCV-associated cryoglobulinemic vasculitis following virus eradication after direct-acting antivirals therapy. *Hepatology* 2017; 65: 1770-1.
9. LOHSE A, MICHEL F, AUGE B, TOUSSIROT E, WENDLING D: Vascular purpura and cryoglobulinemia after influenza vaccination. Case-report and literature review. *Rev Rhum Engl Ed* 1999; 66: 359-60.
10. MATHIEU E, FAIN Q, KRIVITZKY A: Cryoglobulinemia after hepatitis B vaccination. *N Engl J Med* 1996; 335: 355.