



# Sequential HER2 blockade as effective therapy in chemorefractory, HER2 gene-amplified, RAS wild-type, metastatic colorectal cancer: learning from a clinical case

Erika Martinelli,<sup>1</sup> Teresa Troiani,<sup>1</sup> Vincenzo Sforza,<sup>1</sup> Giulia Martini,<sup>1</sup> Claudia Cardone,<sup>1</sup> Pietro Paolo Vitiello,<sup>1</sup> Davide Ciardiello,<sup>1</sup> Anna Maria Rachiglio,<sup>2</sup> Nicola Normanno,<sup>2,3</sup> Andrea Sartore-Bianchi,<sup>4,5</sup> Silvia Marsoni,<sup>6</sup> Alberto Bardelli,<sup>7</sup> Salvatore Siena,<sup>4,5</sup> Fortunato Ciardiello<sup>1</sup>

**To cite:** Martinelli E, Troiani T, Sforza V, *et al.* Sequential HER2 blockade as effective therapy in chemorefractory, HER2 gene-amplified, RAS wild-type, metastatic colorectal cancer: learning from a clinical case. *ESMO Open* 2018;3:e000299. doi:10.1136/esmoopen-2017-000299

Received 23 November 2017  
Accepted 23 November 2017

<sup>1</sup>Dipartimento di Internistica Clinica e Sperimentale 'F Magrassi', Università degli Studi della Campania L Vanvitelli, Napoli, Italy

<sup>2</sup>Cell Biology and Biotherapy Unit, National Cancer Institute 'Fondazione Giovanni Pascale', Napoli, Italy

<sup>3</sup>Laboratory of Pharmacogenomics, Centro di Ricerche Oncologiche di Mercogliano (CROM)–National Cancer Institute 'Fondazione Giovanni Pascale', Napoli, Italy

<sup>4</sup>Niguarda Cancer Center, Grande Ospedale Metropolitano Niguarda, Candiolo, Piemonte, Italy

<sup>5</sup>Dipartimento di Oncologia ed Emato-Oncologia, Università degli Studi di Milano, Milano, Italy

<sup>6</sup>Candiolo Cancer Institute-FPO, Candiolo, Italy

<sup>7</sup>Department of Oncology, University of Torino, Torino, Italy

## Correspondence to

Professor Fortunato Ciardiello; fortunatociardiello@yahoo.com

## ABSTRACT

**Background** Constitutive activation of HER2-dependent intracellular signalling by HER2 gene amplification or by HER2 mutations has been demonstrated as a mechanism of primary and secondary cancer resistance to cetuximab or panitumumab in preclinical and clinical models of metastatic colorectal cancer (mCRC). Both HER2 Amplification for Colorectal Cancer Enhanced Stratification (HERACLES) cohort A and My Pathway clinical trials provided clinical evidence that anti-HER2 therapies could be active in these patients.

**Patient and methods** HER2 gene amplification and HER2 protein overexpression analysis were performed in tumour tissue by fluorescence in situ hybridisation and immunohistochemistry. HER2 positivity was defined according to HERACLES CRC-specific HER2 scoring criteria. DNA analysis for multiple assessment of gene mutations or amplifications was carried out with the next-generation sequencing (NGS) Ion AmpliSeq Colon and Lung Cancer Panel and by using a more extensive targeted high-multiplex PCR-based NGS panel (OncoMine Comprehensive Assay).

**Results** We report the clinical case of a patient with HER2 gene amplified and RAS/BRAF wild-type mCRC who experienced a long lasting and relevant clinical efficacy from sequential anti-HER2 therapies (trastuzumab plus lapatinib, pertuzumab plus trastuzumab, trastuzumab emtansine, trastuzumab plus capecitabine) achieving a cumulative clinical benefit of 29 months, after failure of the first three lines of standard treatments, which included all the potentially active drugs in mCRC, and which accounted for only 14 months of disease control. HER gene amplification was confirmed by NGS on two different metastatic lesions during the evolution of the disease.

**Conclusion** The clinical case highlights the role of HER2 gene amplification as a key genetic driver of cancer development and progression in mCRC and suggests that sequential HER2 blockade could be a potential therapeutic strategy.

## INTRODUCTION

Epidermal growth factor receptor (EGFR) is one of the most characterised molecular targets in metastatic colorectal

## Key questions

### What is already known about this subject?

HER2 gene amplification or HER2 activating mutations have been implicated as one of the mechanisms for cancer cell resistance to anti-epidermal growth factor receptor (EGFR) therapies in metastatic colorectal cancer (mCRC). First reports from clinical trials provided clinical evidence that anti-HER2 therapies could be active in these patients.

### What does this study add?

Here we report a clinical case of a patient with HER2-amplified mCRC tumour highlighting its role as a key genetic driver of cancer development and progression. We demonstrated how sequential HER2-directed therapies were a highly effective therapeutic strategy after failure of standard treatments for mCRC.

### How might this impact on clinical practice?

Our data, in agreement with large body of preclinical and clinical evidence, support the need to identify HER2 gene amplification in mCRC because it defines a relatively homogeneous subset of patients with mCRC with intrinsic resistance to EGFR-targeted therapy that could have a significant clinical benefit from anti-HER2 treatments.

cancer (mCRC). Two anti-EGFR blocking monoclonal antibodies (moAbs), cetuximab and panitumumab, are currently approved for treatment. However, the presence of gene alterations in the EGFR-activated downstream intracellular signalling pathways or in other tyrosine kinase receptors could impair the clinical efficacy of anti-EGFR moAbs, leading to primary or intrinsic cancer cell resistance.<sup>1–3</sup> In this respect, RAS gene mutations (KRAS and NRAS exons 2, 3 and 4) are the only biomarkers currently used in clinical

practice as predictive of intrinsic resistance to anti-EGFR therapies.<sup>4,5</sup>

HER2 gene amplification or HER2 activating mutations have been implicated as one of the mechanisms for cancer cell resistance to anti-EGFR therapies in mCRC. The first evidence of HER2 as a potential target in mCRC derived from studies in mCRC xenograft models of RAS wild-type (WT) tumours, which were resistant to cetuximab treatment. In this respect, Bertotti and colleagues identified HER2 amplification as a potential mechanism of primary resistance to cetuximab, in KRAS, NRAS, BRAF and PIK3CA WT tumours.<sup>6</sup> In a large platform of patient-derived tumour xenografts (PDX), HER2 gene amplification was found only in a small percentage (2%–3%) of genetically unselected patients with mCRC. However, in patients with KRAS WT mCRC, whose tumours were resistant to cetuximab treatment, the frequency of HER2 gene amplification raised to 13.6%, whereas it increased to 36% in cetuximab-resistant KRAS, NRAS, BRAF and PIK3CA WT tumours. HER2 gene amplification was demonstrated as a relevant molecular driver for these tumours, suggesting that anti-HER2 therapy could be effective in a selected subset of patients with mCRC. The combined treatments with trastuzumab (an anti-HER2 moAb) and lapatinib (a small molecule tyrosine kinase inhibitor against HER2 and, potentially, against EGFR) or with trastuzumab and pertuzumab (an anti-HER2 moAb that could block HER2/HER3 heterodimerisation) induced significant tumour regressions in HER2-amplified mCRC PDX models.<sup>6</sup>

The role of HER2 in cancer resistance to anti-EGFR moAbs in mCRC has been also investigated by Yonesaka and colleagues, which reported increased HER2 signalling, either by HER2 gene amplification or through enhanced production of the HER3-activating ligand heregulin, as a mediator of colon cancer cell resistance to cetuximab. Activation of HER2 induced extracellular signal-regulated kinase 1/2 signalling and, as a consequence, cetuximab resistance in a panel of human colon cancer cell lines.<sup>7</sup> Inhibition of HER2 signalling or disruption of HER2/HER3 heterodimerisation restored cetuximab sensitivity both in vitro and in vivo in these colon cancer models. These findings were extended to a cohort of patients with mCRC with either intrinsic or acquired resistance to cetuximab therapy. In fact, in these cases, HER2 gene amplification in tumour samples or high levels of circulating heregulin in patient plasma were found.<sup>7</sup>

The Cancer Genome Atlas project identified HER2 gene amplification as well as HER2 gene mutations in CRC.<sup>8</sup> Activating HER2 gene mutations could be equally important for determining resistance to anti-EGFR therapy in CRC. In fact, Kavuri *et al* have demonstrated that the introduction of activating HER2 gene mutations (S310F, L755S, V777L, V841I and L866M) in colon cells increased HER2-activated signalling pathways, anchorage-independent cell growth, and determined cell resistance to cetuximab or to panitumumab treatment with

sustained mitogen-activated protein kinase phosphorylation. Treatments of mice-bearing HER2-mutated PDX with trastuzumab, neratinib (a small molecule anti-HER2 tyrosine kinase inhibitor) or lapatinib, as single agents or in combination, determined tumour regression.<sup>9</sup>

A few studies have explored the feasibility and the potential activity of the anti-HER2 moAb trastuzumab in combination with irinotecan or oxaliplatin-based chemotherapy in patients with mCRC. However, these studies were performed in unselected patients and did not provide useful information on the clinical efficacy of this therapeutic approach.<sup>10,11</sup> Therefore, for more effective studies exploring the potential role of anti-HER2 therapies in patients with mCRC, a methodology for HER2 testing that could be used for the appropriate patient selection was needed. A study to define the criteria for HER2 gene amplification and protein expression in mCRC was recently conducted by a panel of pathologists within the HER2 Amplification for Colorectal Cancer Enhanced Stratification (HERACLES) programme.<sup>12</sup> This was done in two steps. First, pathologists adapted fluorescence in situ hybridisation (FISH) and immunohistochemistry (IHC) protocols, which are currently used for defining HER2 positivity in human breast and gastric cancer, to CRC. In the second step, these criteria were prospectively validated to screen and identify patients with HER2-positive mCRC. Five per cent of patients with KRAS WT mCRC were found to have HER2-positive tumours, according to CRC-specific HER2 scoring criteria.<sup>12</sup>

Several clinical trials are currently ongoing following selection of patients with HER2-positive mCRC (table 1). In this respect, HERACLES is a series of proof-of-concept phase II clinical trials that have been designed to test different anti-HER2 treatments. The HERACLES cohort A study has been conducted in patients with KRAS exon 2 WT, HER2-amplified mCRC, whose tumours were resistant to standard therapies, including anti-EGFR moAbs.<sup>13</sup> Patients were treated with the combination of trastuzumab and lapatinib. Forty-eight out of 914 KRAS exon 2 WT tumours (5%), which were screened, were positive according to CRC-specific HERACLES HER2 scoring criteria. Eight of the 27 patients enrolled in the trial (30%) achieved an objective response, of which one patient (4%) had a complete response and seven patients (26%) had partial responses (PR). In addition, 12 patients (44%) had stable disease (SD) as best response. The median duration of the response was 38 weeks with median progression-free survival (PFS) of 21 weeks and median overall survival of 46 weeks. Notably, responses were significantly more common and PFS was longer in patients whose tumours had high levels of HER2 gene amplification. The combined anti-HER2 treatment with trastuzumab and lapatinib had an acceptable safety profile, with most toxic effects being of grade 1 or 2. No cardiotoxicity was reported. The HERACLES-RESCUE clinical trial is currently treating patients following progression to trastuzumab plus lapatinib therapy from the HERACLES cohort A trial with trastuzumab emtansine (T-DM1).

**Table 1** Ongoing clinical trials evaluating anti-HER2 treatments in mCRC

| Drug                        | Study   | Definition of HER2 positivity   | ClinicalTrials.gov identifier or EUDRACT number | Phase | Status             |
|-----------------------------|---|---|---|-------|--------------------|
| Pertuzumab plus T-DM1       | Pertuzumab and trastuzumab emtansine in HER2-positive colorectal cancer (HERACLES cohort B)   | <ul style="list-style-type: none"> <li>▶ 3+ HER2 score (IHC) in more than 50% of cells</li> <li>▶ 2+ HER2 score (IHC) and a HER2:CEP17 ratio higher than 2 in more than 50% of cells by FISH</li> </ul>   | 2012-002128-33                                  | II    | Active, recruiting |
| T-DM1                       | HER2 Amplification for Colorectal Cancer Enhanced Stratification—rechallenge with HER2 selective cytotoxic uptake of emtansine (HERACLES-RESCUE)            | <ul style="list-style-type: none"> <li>▶ 3+ HER2 score (IHC) in more than 50% of cells</li> <li>▶ 2+ HER2 score (IHC) and a HER2:CEP17 ratio higher than 2 in more than 50% of cells by FISH</li> </ul>   | 2015-003275-30                                  | II    | Active, recruiting |
| Pertuzumab plus trastuzumab | A study evaluating Herceptin/Perjeta, Tarceva, Zelboraf/Cotellic, and Erivedge treatment targeted against certain mutations in cancer patients (My Pathway) | ▶ HER2 overexpression, amplification or HER2-activating mutation  | NCT02091141                                     | II    | Active, recruiting |
| Tucatinib plus trastuzumab  | Tucatinib (ONT-380) and trastuzumab for patients with HER2-positive metastatic colorectal cancer (MOUNTAINEER)  | <ul style="list-style-type: none"> <li>▶ HER2 overexpression (3+ IHC). HER2 2+ IHC is eligible if the tumour is amplified by FISH.</li> <li>▶ HER2 amplification by in situ hybridisation assay (FISH or CISH signal ratio &gt;2.0 or gene copy number &gt;6)</li> <li>▶ HER2 amplification by CLIA-certified NGS sequencing assay</li> </ul> | NCT03043313                                     | II    | Not yet recruiting |

CISH, chromogenic in situ hybridisation; CLIA, Clinical Laboratory Improvement Amendments; EUDRACT, European Clinical Trials Database; FISH, fluorescence in situ hybridisation; HERACLES, HER2 Amplification for Colorectal Cancer Enhanced Stratification; IHC, immunohistochemistry; mCRC, metastatic colorectal cancer; NGS, next-generation sequencing; T-DM1, trastuzumab emtansine.

Finally, the HERACLES cohort B clinical trial is currently recruiting patients with HER2 therapy-naïve, HER2-positive mCRC for the treatment with T-DM1 plus pertuzumab. Moreover, the role of anti-HER2 therapy with trastuzumab plus pertuzumab in patients with mCRC with either HER2-amplified or HER2-mutated tumours, which could be identified by next-generation sequencing (NGS) and/or by IHC or FISH, is currently evaluated in the My Pathway phase II clinical trial.<sup>14</sup> Preliminary results on 34 patients have been reported. Twelve patients had PR as best response, with SD longer than 4 months in three additional patients for an overall response rate of 37.5%. These responses were durable (median, 11.1 months).

Here we report the clinical case of a patient with HER2 gene amplified and RAS and BRAF WT mCRC, who experienced a long lasting and relevant clinical efficacy from sequential anti-HER2 therapies.

## MATERIALS AND METHODS

### Patient treatment

The patient was treated in the Division of Medical Oncology, Dipartimento di Internistica Clinica e Sperimentale 'F Magrassi', Università degli Studi della Campania L Vanvitelli, Naples, Italy. Treatments with

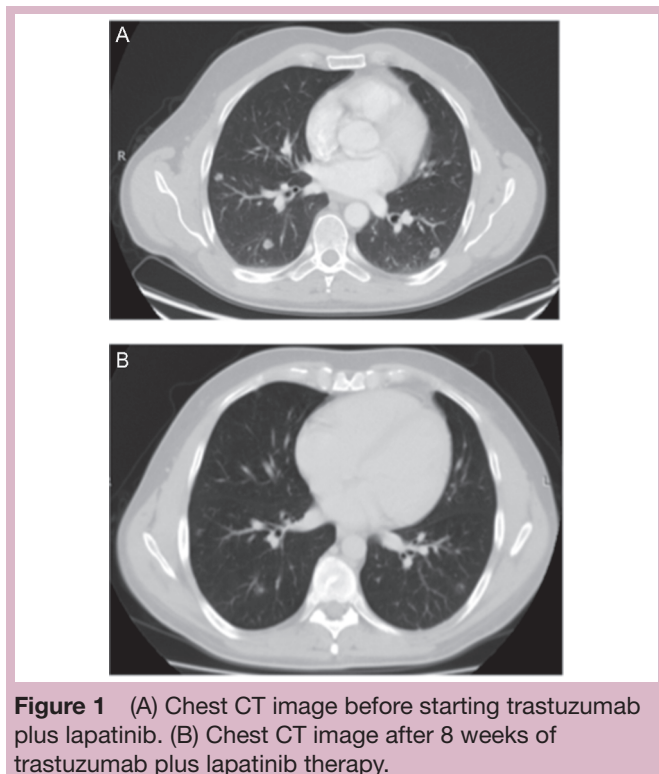
anti-HER2 drugs reported here were within the HERACLES cohort A clinical trial or as off-label therapies that were approved by the local institutional ethics committee. Written informed consent was obtained. Trastuzumab plus lapatinib were administered as reported.<sup>8</sup> Other HER2-directed treatments (trastuzumab plus pertuzumab, T-DM1, capecitabine plus trastuzumab) were given at standard, registered doses and schedules.

### HER2 gene amplification and HER2 protein overexpression analyses

Primary tumour tissue was evaluated for gene amplification and protein expression by FISH and IHC, as previously reported.<sup>12</sup> HER2 positivity was defined according to HERACLES CRC-specific HER2 scoring criteria. IHC had to detect intense cell membrane HER2 protein expression in >50% of cells (3+ score). This was accompanied by HER2 gene amplification (HER2:CEP17 ratio higher than 2 in more than 50% of cells by FISH).

### DNA analysis for multiple assessment of gene mutations or amplifications

Tumour samples were analysed with either of the two following NGS techniques. The first biopsy (from latero-cervical lymph node metastasis) was analysed with the



**Figure 1** (A) Chest CT image before starting trastuzumab plus lapatinib. (B) Chest CT image after 8 weeks of trastuzumab plus lapatinib therapy.

Ion AmpliSeq Colon and Lung Cancer Panel (Life Technologies) using Ion Torrent semiconductor sequencing, as previously reported<sup>15 16</sup> (see online supplementary appendix A for details). The second biopsy (from one of the liver metastases) was analysed by using a more extensive targeted high-multiplex PCR-based NGS panel (OncoMine Comprehensive Assay), as previously described<sup>17</sup> (see online supplementary appendix A for details).

## RESULTS

A 42-year-old Caucasian man was diagnosed in April 2013 with adenocarcinoma of the left colon at colonoscopy. A CT scan ruled out distant metastasis. Thus, in May 2013 the patient underwent potential radical surgery (left hemicolectomy: pT4aG1N1bM0, IIIB stage). 5-Fluorouracil, leucovorin and oxaliplatin (FOLFOX) adjuvant treatment was planned. However, before starting it, the physical evaluation of the patient detected a left laterocervical lymph node enlargement. A biopsy confirmed the diagnosis of lymph node metastasis from colon adenocarcinoma. DNA was extracted from this metastatic site. Multiple gene mutation analysis by NGS of a selected panel of 22 genes (see online supplementary appendix A for details)<sup>15 16</sup> found no gene mutations, including KRAS, NRAS, BRAF, PIK3CA, but detected HER2 gene amplification. A new CT scan revealed several additional abdominal lymph node lesions. In June 2013, the patient started first-line treatment for metastatic disease with folinic acid, fluorouracil & irinotecan plus cetuximab. The best response was SD with PFS of 5 months. A CT scan

demonstrated progression of disease in the left laterocervical lymph nodes and the appearance of novel bilateral lung lesions. Therefore, the patient started second-line treatment with FOLFOX plus bevacizumab. This therapy achieved a minor response as best response with PFS of 6 months, when further progression in lung metastases and abdominal lymph nodes was found. A third-line treatment with regorafenib was started, but the patient's clinical conditions rapidly deteriorated. Within 3 months, the performance status (PS) declined to 2 with reduction of normal physical activities, fatigue and abdominal pain requiring high doses of opioids. Thus, having no standard therapeutic options after regorafenib failure, despite the rapid worsening of the clinical conditions, we evaluated if the patient could receive an experimental therapy within a clinical trial. Since the patient had a tumour with HER2 gene amplification as detected by NGS performed on the first laterocervical lymph node metastasis, the primary tumour was also analysed. HER2 overexpression by IHC with 3+ positive scoring was found. Central laboratory review confirmed HER2 gene amplification by FISH. The patient was, therefore, eligible for treatment in the phase II HERACLES cohort A clinical trial. On October 2014, treatment with trastuzumab and lapatinib (as fourth line of therapy for mCRC) was started. Within 1 week of treatment, PS score restored to 0 with resolution of abdominal pain and no more opioid therapy requirement. The treatment was well tolerated. The patient resumed normal life including work and sports activities. The first CT scan reassessment demonstrated a PR (figure 1), which lasted until September 2015 with a total of 16 courses of trastuzumab and lapatinib administered and a PFS of 12 months. At that time, novel lung metastatic lesions were detected. Despite the progression of disease, the patient maintained PS 0. Therefore, based on the clinical evidence that continuing the HER2 blockade is associated with improved outcome in metastatic breast cancer,<sup>18</sup> we asked our institutional ethics committee the authorisation for an off-label treatment with pertuzumab plus trastuzumab. The patient was treated from October 2015 to July 2016 with this combination (as fifth line), achieving as best response SD and a PFS of 10 months. However, for the first time multiple liver metastases were detected together with novel lung and lymph node metastases. PS worsened to 2 and opioid treatment was restarted. A biopsy of a liver lesion was obtained and was analysed by NGS for a panel of 143 genes (see online supplementary appendix A for details).<sup>17</sup> HER2 gene amplification (with 70% allele frequency) was confirmed, while a novel *TP53*p.R175H gene mutation (c.524G>A, 70.4% allele frequency) was found. No mutations or amplifications were found in KRAS, NRAS, BRAF, AKT, PIK3CA, EGFR, HER3, MET as well as in other genes that could be involved in HER family-activated pathways. Considering the persistence of HER2 gene amplification, without any other gene alterations, that could be targeted with a selective molecular approach, in August 2016 the patient received, as off-label therapy and after ethics committee approval, the

**Table 2** Patient treatment and outcome overview

| Treatment                      | Date of first dose | Line of treatment for metastatic disease | Best response  | PFS (months) |
|--------------------------------|--------------------|--|----------------|--------------|
| FOLFIRI plus cetuximab         | June 2013          | First                                    | SD             | 5            |
| FOLFOX plus bevacizumab        | November 2013      | Second                                   | Minor response | 6            |
| Regorafenib                    | June 2014          | Third                                    | PD             | 3            |
| Trastuzumab plus lapatinib*    | October 2014       | Fourth                                   | PR             | 12           |
| Pertuzumab plus trastuzumab*   | October 2015       | Fifth                                    | SD             | 10           |
| T-DM1*                         | August 2016        | Sixth                                    | SD             | 5            |
| Trastuzumab plus capecitabine* | January 2017       | Seventh                                  | SD             | 2†           |

\*HER2-directed therapies.

†On treatment as 6 April 2017.

FOLFIRI, folinic acid, fluorouracil &amp; irinotecan; FOLFOX, 5-fluorouracil, leucovorin and oxaliplatin; PD, progression of disease; PFS, progression-free survival; PR, partial response; SD, stable disease; T-DM1, trastuzumab emtansine.

first course of T-DM1 therapy. Best response was SD with an improvement of clinical conditions to PS 0 and PFS of 5 months. In December 2016, following lung, liver and abdominal lymph nodes disease progression, the clinical conditions worsened rapidly to PS 3 with dyspnoea requiring oxygen supplementation, lower limbs oedema and abdominal pain. Oral capecitabine plus trastuzumab treatment was started. Symptoms improved to PS 1 within three cycles. As of 6 April 2017, the patient was still on treatment. A summary of the anticancer treatments is illustrated in [table 2](#).

## DISCUSSION

Constitutive activation of HER2-dependent intracellular signalling by HER2 gene amplification or by HER2 mutations has been demonstrated as a mechanism of cancer resistance to cetuximab or panitumumab in PDTX models of mCRC.<sup>6</sup> Furthermore, the HERACLES diagnostic and therapeutic research programme has demonstrated that HER2 gene amplification is detected in a subgroup of patients with mCRC.<sup>8</sup> This correlated with intrinsic cancer resistance to anti-EGFR mAbs in KRAS exon 2 WT tumours. Both HERACLES cohort A and My Pathway clinical trials provided clinical evidence that anti-HER2 therapies could be active in these patients.<sup>13 14</sup>

The clinical case, which is reported here, highlights the role of HER2 gene amplification as a key genetic driver of cancer development and progression. In fact, HER2 gene amplification was detected in the primary tumour as well as in two metastatic sites (laterocervical lymph node and liver metastases) that emerged during clinical progression. Sequential HER2-directed therapies were a highly effective therapeutic strategy after failure of standard treatments for mCRC. In this respect, a cumulative clinical benefit of 29 months with sequential lines of HER2 blockade was achieved, whereas the first three lines of standard treatments, which included all the potentially active drugs in mCRC, accounted for only 14 months of disease control. Further, HER2-directed therapies were very well tolerated with no grade

3/4 toxicities and with no heart function impairment. These results confirm that anti-HER2 therapies are highly effective in patients with HER2-amplified mCRC and suggest that sequential HER2 blockade could be a potential therapeutic strategy.

Taken together, a large body of preclinical and clinical evidence, including this case report, supports the need to identify HER2 gene amplification in mCRC. In fact, although this genetic alteration occurs at low frequency, it defines a relatively homogeneous subset of patients with mCRC with intrinsic resistance to EGFR-targeted therapy and that could have a significant clinical benefit from anti-HER2 treatments.

**Funding** This study was funded by the AIRC (Associazione Italiana per la Ricerca sul Cancro): MFAG-2015-ID:7778 (EM) and IG-2013-ID:14800 (FC). This study was supported by the European Community's H2020 grant agreement number 635342-2 MoTriColor (EM, FC, AB, SS, ASB); AIRC 2010 Special Program Molecular Clinical Oncology 5 per mille, project number 9970 (AB, SM and SS); Fondazione Piemontese per la Ricerca sul Cancro-ONLUS 5 per mille 2011 Ministero della Salute (AB and SM); AIRC IG number 16788 (AB).

**Competing interests** None declared.

**Patient consent** Obtained.

**Provenance and peer review** Not commissioned; internally peer reviewed.

**Open Access** This is an Open Access article distributed in accordance with the Creative Commons Attribution Non Commercial (CC BY-NC 4.0) license, which permits others to distribute, remix, adapt, build upon this work non-commercially, and license their derivative works on different terms, provided the original work is properly cited and the use is non-commercial. See: <http://creativecommons.org/licenses/by-nc/4.0/>

© European Society for Medical Oncology (unless otherwise stated in the text of the article) 2018. All rights reserved. No commercial use is permitted unless otherwise expressly granted.

## REFERENCES

1. Van Cutsem E, Cervantes A, Adam R, *et al*. ESMO consensus guidelines for the management of patients with metastatic colorectal cancer. *Ann Oncol* 2016;27:1386–422.
2. Hynes NE, Lane HA. ERBB receptors and cancer: the complexity of targeted inhibitors. *Nat Rev Cancer* 2005;5:341–54.
3. Ciardiello F, Tortora G. EGFR antagonists in cancer treatment. *N Engl J Med* 2008;358:1160–74.
4. Sforza V, Martinelli E, Ciardiello F, *et al*. Mechanisms of resistance to anti-epidermal growth factor receptor inhibitors in metastatic colorectal cancer. *World J Gastroenterol* 2016;22:6345–61.



5. Prahallad A, Sun C, Huang S, *et al.* Unresponsiveness of colon cancer to BRAF(V600E) inhibition through feedback activation of EGFR. *Nature* 2012;483:100–3.
6. Bertotti A, Migliardi G, Galimi F, *et al.* A molecularly annotated platform of patient-derived xenografts ("xenopatiens") identifies HER2 as an effective therapeutic target in cetuximab-resistant colorectal cancer. *Cancer Discov* 2011;1:508–23.
7. Yonesaka K, Zejnullahu K, Okamoto I, *et al.* Activation of ERBB2 signaling causes resistance to the EGFR-directed therapeutic antibody cetuximab. *Sci Transl Med* 2011;3:99ra86.
8. Cancer Genome Atlas Network. Comprehensive molecular characterization of human colon and rectal cancer. *Nature* 2012;487:330–7.
9. Kavuri SM, Jain N, Galimi F, *et al.* HER2 activating mutations are targets for colorectal cancer treatment. *Cancer Discov* 2015;5:832–41.
10. Clark JW, Hollis D, Mayer R, *et al.* Phase II trial of 5-fluorouracil (5-FU), leucovorin (LV), oxaliplatin (Ox), and trastuzumab (T) for patients with metastatic colorectal cancer (CRC) refractory to initial therapy. *Onkologie* 2003;26(Suppl 3):13–46.
11. Ramanathan RK, Hwang JJ, Zamboni WC, *et al.* Low overexpression of HER-2/neu in advanced colorectal cancer limits the usefulness of trastuzumab (Herceptin) and irinotecan as therapy. A phase II trial. *Cancer Invest* 2004;22:858–65.
12. Valtorta E, Martino C, Sartore-Bianchi A, *et al.* Assessment of a HER2 scoring system for colorectal cancer: results from a validation study. *Mod Pathol* 2015;28:1481–91.
13. Sartore-Bianchi A, Trusolino L, Martino C, *et al.* Dual-targeted therapy with trastuzumab and lapatinib in treatment-refractory, KRAS codon 12/13 wild-type, HER2-positive metastatic colorectal cancer (HERACLES): a proof-of-concept, multicentre, open-label, phase 2 trial. *Lancet Oncol* 2016;17:738–46.
14. Hurwitz H, Hainsworth JD, Swanton C, *et al.* Targeted therapy for gastrointestinal (GI) tumors based on molecular profiles: early results from MyPathway, an open-label phase IIa basket study in patients with advanced solid. *J Clin Oncol* 2016;34(Suppl 4S).
15. Normanno N, Rachiglio AM, Lambiase M, *et al.* Heterogeneity of KRAS, NRAS, BRAF and PIK3CA mutations in metastatic colorectal cancer and potential effects on therapy in the CAPRI GOIM trial. *Ann Oncol* 2015;26:1710–4.
16. Ciardiello F, Normanno N, Maiello E, *et al.* Clinical activity of FOLFIRI plus cetuximab according to extended gene mutation status by next-generation sequencing: findings from the CAPRI-GOIM trial. *Ann Oncol* 2014;25:1756–61.
17. Martinelli E, Sforza V, Cardone C, *et al.* Clinical outcome and molecular characterization of chemorefractory metastatic colorectal cancer patients with long term efficacy of regorafenib treatment. *ESMO Open*. doi: 10.1136/esmoopen-2017-000177. [Epub ahead of print 29 Jul 2017].
18. Schalper KA, Velcheti V, Carvajal D, *et al.* In situ tumor PD-L1 mRNA expression is associated with increased TILs and better outcome in breast carcinomas. *Clin Cancer Res* 2014;20:2773–82.



## Sequential HER2 blockade as effective therapy in chemorefractory, HER2 gene-amplified, RAS wild-type, metastatic colorectal cancer: learning from a clinical case

Erika Martinelli, Teresa Troiani, Vincenzo Sforza, Giulia Martini, Claudia Cardone, Pietro Paolo Vitiello, Davide Ciardiello, Anna Maria Rachiglio, Nicola Normanno, Andrea Sartore-Bianchi, Silvia Marsoni, Alberto Bardelli, Salvatore Siena and Fortunato Ciardiello

*ESMO Open* 2018 3:  
doi: 10.1136/esmoopen-2017-000299

---

Updated information and services can be found at:  
<http://esmoopen.bmj.com/content/3/1/e000299>

---

*These include:*

### References

This article cites 16 articles, 4 of which you can access for free at:  
<http://esmoopen.bmj.com/content/3/1/e000299#ref-list-1>

### Open Access

This is an Open Access article distributed in accordance with the Creative Commons Attribution Non Commercial (CC BY-NC 4.0) license, which permits others to distribute, remix, adapt, build upon this work non-commercially, and license their derivative works on different terms, provided the original work is properly cited and the use is non-commercial. See: <http://creativecommons.org/licenses/by-nc/4.0/>

### Email alerting service

Receive free email alerts when new articles cite this article. Sign up in the box at the top right corner of the online article.

---

### Topic Collections

Articles on similar topics can be found in the following collections

[Open access](#) (183)

---

### Notes

---

To request permissions go to:  
<http://group.bmj.com/group/rights-licensing/permissions>

To order reprints go to:  
<http://journals.bmj.com/cgi/reprintform>

To subscribe to BMJ go to:  
<http://group.bmj.com/subscribe/>