

Large oral ulcer of tongue related to dental trauma

Gian Paolo Bombeccari¹, Gianpaolo Guzzi², Francesco Pallotti³, Massimo Porrini¹, Aldo Bruno Gianni¹, Francesco Spadari¹

SUMMARY

A 36-year-old Philippine male has a several month-history of burning pain of his tongue with lingual erythema and oral bleeding. Here we describe a classical case of oral chronic ulcer related to mechanical dental trauma. In this case, unilateral crossbite malocclusion was able to produce oral mucosal lesion that was sufficient to cause a large, chronic tongue ulcer and subsequent mild epithelial dysplasia. A specific tongue-retaining device was made. In absence of dental trauma, his chronic ulcer of the tongue resolved within a few weeks. This case suggests evidence on the direct relationship between chronic oral trauma and the potential occurrence of a dysplastic process.

Keywords: chronic traumatic ulcer, oral dysplasia, tongue ulcer, dental trauma, malocclusion.

INTRODUCTION

Among the etiological factors of a chronic traumatic ulcer (CTU), the injury of mechanical nature plays an important role. The edges and surface of the tongue and the occlusal axis of the cheek mucosa are usually the most involved sites (1, 2). Prosthetic irregularities, metal wires, and cracked teeth are the most common causes of CTU, hyperplasia, and fibrosis, as the result of impact on the oral mucosa.

Several authors hypothesized a cause-and-effect relationship between repetitive dental trauma and oral carcinoma (1-9). Two authors have attempted to demonstrate that CTU acts as a tumor promoter in experimental model (10, 11)

Unfortunately, at present, there are no reports demonstrating the histopathological evidence of the potentially carcinogenic effects on oral tissues caused by dental trauma.

In this report, we describe the management of a mild epithelial dysplasia of the tongue caused by

a chronic dental traumatism arising from occlusal trauma due to unilateral crossbite of the maxilla.

CASE REPORT

In May 2012, a 36-year-old Philippine male presented to our oral pathology department complaining of glossodynia, red tongue, and oral bleeding. He reported the presence of a tongue lesion developed about 6 months earlier, after he realized that he had bite his tongue.

The lesion in his tongue enlarged, with increasing pain, over time. He had no history of smoking or alcohol consumption. His past medical history was not contributory. In the previous months, he did not take any medications. The intraoral examination displayed a deep ulcer on the left border of the middle third of the tongue. On palpation, which was hard-elastic, with elevated edges, measuring 0.8×0.5 cm (Fig. 1). The patient had a ipsilateral (skeletal) posterior crossbite involving maxillary first and second premolars and first molar (2.4, 2.5, 2.6) teeth associated with maxillary hypoplasia and macroglossia were clinically evident as the putative etiologic factors (Fig. 2). Considering the oral examination, we think that his tongue ulcer resulted from traumatic tongue injury caused by dental trauma.

In order to reduce associated tongue biting, especially during sleep, we performed a coronal reduction (coronal plastic) on maxillary first and second premolars (2.4, 2.5, 2.6) teeth, considering

¹Maxillo-Facial and Dental Unit, Fondazione Ca' Granda IRCCS Ospedale Maggiore Policlinico Milan. Department of Biomedical, Surgical and Dental Sciences, University of Milan, Italy

²Italian Association for Metals and Biocompatibility Research – A.I.R.M.E.B., Milan, Italy

³Unit of Anatomical Pathology, Fondazione IRCCS Ca' Granda Ospedale Maggiore Policlinico, University of Milan, Milan, Italy

Address correspondence to Dr. Gian Paolo Bombeccari, Maxillo-Facial and Dental Unit, Fondazione Ca' Granda IRCCS Ospedale Maggiore Policlinico Milan. Department of Biomedical, Surgical and Dental Sciences, University of Milan, Via Della Commenda 10, 20122 Milan, Italy.

E-mail address: gpombeccari@libero.it

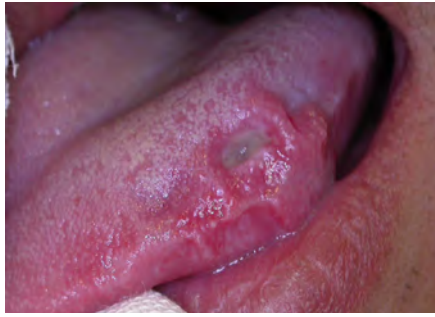

Fig. 1. Traumatic ulcer on the left border of the tongue

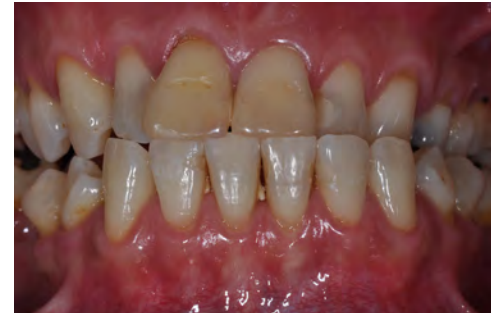
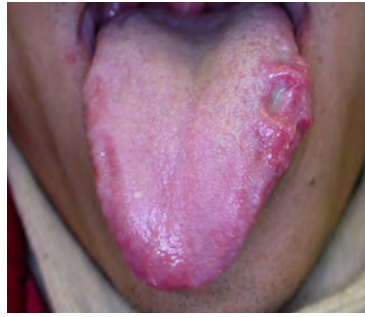
Fig. 2. Unilateral crossbite associated with hypomaxillia

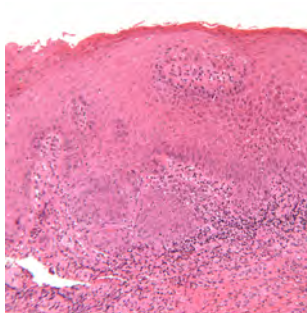


Fig. 3. Mucosa of the tongue, with acanthosis and mild dysplasia (10× EE)

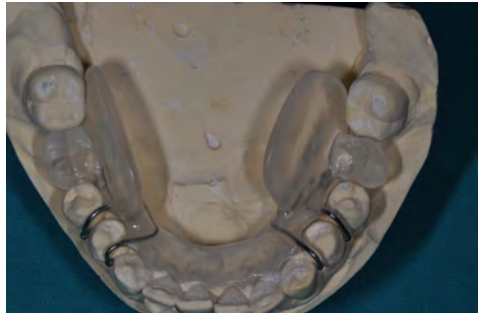


Fig. 4. The acrylic resin device (tongue retaining-device) on the plaster model

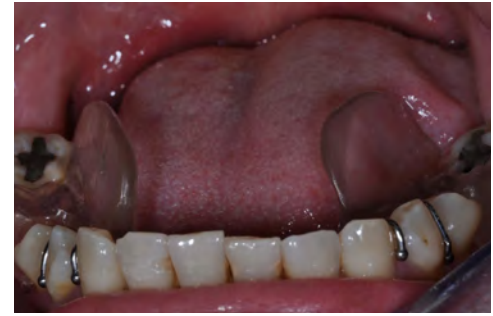

Fig. 5. The device positioned in the mouth; note that the lingual flanges protect the patient's tongue

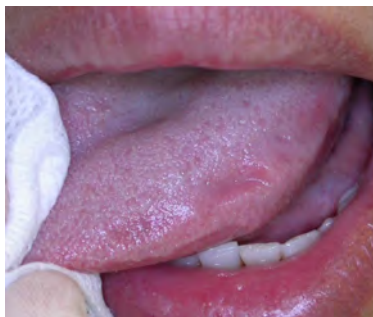

Fig. 6. The complete healing of the lesion 2 months after the biopsy

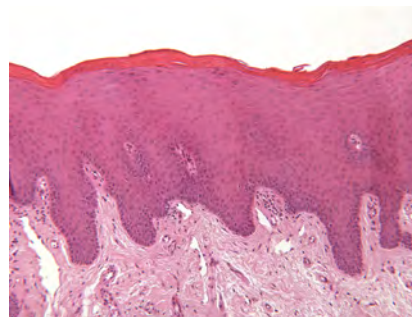


Fig. 7. Tongue mucosa without signs of inflammation and dysplasia (4x EE)

that the tongue ulcer was probable caused by dental trauma.

At 15 days after surgical excision, only a partial reduction of the ulcerative lesion was noted in his tongue, which still appeared infiltrated to palpation. The intraoral examination showed abnormal looking of the tongue mucosa with an extensive ulceration with irregular borders, covered with fibrin (about 8 mm shallow), surrounded by an erythematous atrophic area. Whitish areas were noted in the rim of the tongue ulcer. There was hardening of the marginal edges, indicating an early infiltration, suggestive of chronic traumatic ulcer and this was confirmed by an incisional biopsy performed by using a punch scalpel of 4 millimeters of diameter. Histopathological evaluation of the tongue ulcer showed acanthosis and mild epithelial dysplasia (Fig. 3). The complete remission of the lesion has been considered impro-

able, because of the macroglossia and dental trauma. In addition, we noted other areas of his tongue traumatized by occlusal trauma. Surgical excision of the lesion could not guarantee long term results, due to the persistent dental traumatism. Any orthodontic treatment would have required too long time and in any case the prognosis would remain uncertain.

Thus, all the possible rehabilitative therapies were largely explained at the patient, but he refused. As temporary emergency option, a removable acrylic resin device with lateral flanges (tongue retaining-device, TRD) was made to protect against the chronic persistent dental trauma of the mucosa of the tongue (Fig. 4, 5).

The design of the tongue retaining-device was not fixed to teeth and the patient could easily remove it. The tongue retaining-device had a passive application, in the case under discussion, and it was made as space maintainer with tooth-like morphology in his edentulous areas. The base of the removable tongue retaining-device was not in direct contact with alveolar mucosa, and its stability was assured by ortho metal hooks of stabilization as well as the acrylic base on lingual surfaces of the teeth.

The TDR was made with heat-polymerized denture resin (i.e.; conventional heat polymerized acrylic resin).The patient wore the tongue retain-

ing-device all day long, except during meals. On follow-up examinations (after 15 to 60 days), the clinical observations after the insertion of the tongue retaining-device, revealed a gradual remission of his tongue lesion, up to the complete healing.(Fig. 6). At six months follow-up, a sample of tongue tissue of 3 millimeters of diameter was obtained from the area of the lesion, to confirm a pathologic regression. (Fig. 7). At 30-months follow-up, he has no evidence of recurrence of the tongue lesion.

DISCUSSION

Clinical differential diagnosis of chronic traumatic ulcer of the tongue is addressed toward other solitary chronic ulcers of the mouth, such as bacterial ulcers (secondary syphilis, tuberculosis), mycotic ulcers (deep-mycosis), autoimmune ulcers (type-major aphthous stomatitis), and tongue injuries associated with the eruption of primary lower incisors (Riga-Fede disease). Another pathological entity to be considered in the differential diagnosis of oral ulcer is a traumatic ulcerative granuloma with stromal eosinophilia in which, the tongue is the most commonly affected site. It is characterized by the presence of mildly indurated borders, a rapid growth rate, resembling a traumatic ulceration and/or deep fungal infection or a squamous cell carcinoma. Microscopically, it distinguishes toward CTU by an intact, well differentiated epithelium, an intense inflammatory cell infiltrate and pronounced eosinophilia (12)

Epidemiological studies generally analyze relationship between CTUs originated by dentures and cancer, but mostly they do not include other traumatic factors such as defective teeth or parafunctional habits (4). Chronic traumatic ulcer (CTU) may be painless with a hardened base and raised borders. Consequently, it may be indistinguishable from squamous cell carcinoma on the basis of its clinical features. Traumatic oral ulcers are associated with an identifiable mechanical, chemical, thermal and/or radiotherapeutic cause. Chronic trauma as etiologic agent in the oral carcinogenesis is controversial, in consideration of the current evidence (13).It is hypothesized that chronic irritation from dental trauma may facilitate exposure to carcinogens, so this may act as a cofactor primarily in high-risk individuals groups (13). Velly *et al.* have stated that chronic physical irritation of the tongue epithelium on action of an inappropriate dentition may promote dysplasia and carcinogenesis, independently from other risk factors (1). Likewise, Rosenquist *et al.*, these reported similar findings in a case-control

study in the Sweden population (8). Experimental studies in animal models showed that oral chronic traumatism could induce ulcerative lesions of the oral cavity in a similar manner to those of chronic traumatic ulcers in humans (10, 11). These studies demonstrated that CTUs play a role at the stage of promotion of oral carcinogenesis, initiated by another carcinogen such as tobacco smoke as well as alcohol in humans. However, confounding factors as tobacco and alcohol were not present in the case of our patient. Two mechanisms could account in inflammation of CTUs related-cancer. First, cells undergoing an increase of mitosis to repair soft tissue injury and this is associated with increase in the likelihood of DNA damage by other chemical agents to initiate oral carcinogenesis (10, 11). Second, chronic inflammation at the site affected by chronic oral trauma could release chemical mediators and increase oxidative stress (11, 14). Moreover, among others independent risk factors, the socioeconomic status is widely held to be inversely related to the incidence of oral cancer. Such factor is also reflected in subjects with malocclusion, and their overall compliance with healthcare guidelines and prevention (15).

In this case study under discussion, considering that histopathologic findings of chronic oral ulcer revealed a mild dysplasia, a timely treatment was necessary to heal his tongue lesions. On one hand, an orthodontic/orthopedic approach takes long time to obtain a complete healing and increase the risk to developing an oral neoplasia. On the other hand, a surgical excision of the lesion would have certainly been faster but it would not have guaranteed a stable healing because of the constant presence of malocclusion. The latter, in any case, it is an invasive surgical approach. We decided against the surgical approach and the patient concurred.

We made a specific tongue retaining-device (TRD) on the basis of the concept of tongue guard appliance. The patient achieved a complete healing of the lesions through a progressive improvement and results stability over time. In the present case, the treatment success was possible given the complete compliance of our patient. The healing of this CTU of the tongue suggests that early dysplastic lesions may be reversible if the source of irritation can be eliminated (16).

To our knowledge, there was only one case report about the direct relationship between chronic traumatic ulcer and oral carcinoma associated with chemical carcinogens (6). We were unable to find any case study regarding the relationship between dental trauma and oral ulcer with dysplasia.

CONCLUSION

This case suggest that a clear cause-effect relationship between chronic traumatism and oral ulcer

with of mild dysplasia. Our experience highlights the importance of the early diagnosis and treatment to prevent the malignant transformation of oral ulcer lesion.

REFERENCES

1. Velly AM, Franco EL, Schlecht N, et al. Relationship between dental factors and upper aerodigestive tract cancer. *Oral Oncol* 1998; 34:284-91.
2. Kabat GC, Hebert JR, Wynder EL. Risk factors for oral cancer in women. *Cancer Res* 1989; 49:2803-6.
3. Gallego L, Junquera L. Oral carcinoma associated with implant-supported overdenture trauma: a casa report. *Dent Traumatol* 2009;25:e3-e4.
4. Piemonte ED, Lasoz JP, Brunotto M. Relationship between chronic trauma of the oral mucosa, oral potentially malignant disorders and oral cancer. *J Oral Pathol Med* 2010;39:513-7.
5. Dayal, Reddy R, Anuradha Bhat K. Malignant potential of oral submucous fibrosis due to intraoral trauma. *Indian J Med Sci* 2000;54:182-7.
6. Thumfart W, Weidenbecher M, Waller G, Pesch HJ. Chronic mechanical trauma in the aetiology of oropharyngeal carcinoma. *J Maxillofac Surg* 1978;6:217-21.
7. Marshall JR, Graham S, Haughey BP, Shedd D, O'Shea R, Brasure J, et al. Smoking, alcohol, dentition and diet in the epidemiology of oral cancer. *Eur J Cancer B Oral Oncol* 1992;28B:9-15.
8. Rosenquist K. Risk factors in oral and oropharyngeal squamous cell carcinoma: a population-based case-control study in southern Sweden. *Swed Dent J Suppl* 2005;179:1-66.
9. Orbak R, Bayraktar C, Kavrut F, Gündođdu C. Poor oral hygiene and dental trauma as the precipitating factors of squamous cell carcinoma. *Oral Oncol Extra* 2005;41:109-13.
10. Perez MA, Raimondi AR, Itoiz ME. An experimental model to demonstrate the carcinogenic action of oral chronic traumatic ulcer. *J Oral Pathol Med* 2005;34:17-22.
11. Sato T. A study on effect of mechanical irritation in development and progression of tongue cancer. *Kokubyo Gakkai Zasshi* 1995;62:532-50.
12. Gonçales ES, Rubira-Bullen IF, Rubira CM, Miyazawa M, Chinellato LE, Consolaro A. Eosinophilic ulcer of the oral mucosa versus squamous cell carcinoma. *Quintessence Int* 2007;38:677-80.
13. Warnakulasuriya S. Causes of oral cancer-an appraisal of controversies. *Br Dent J* 2009;207:471-5.
14. Kawanishi S, Hiraku Y, Pinlaor S, Ma N. Oxidative and nitrate DNA damage in animals and patients with inflammatory disease in relation to inflammation-related carcinogenesis. *Biol Chem* 2006;387:365-72.
15. Lockhart PB, Norris CM, Pulliam C. Dental factors in the genesis of squamous cell carcinoma of the oral cavity. *Oral Oncol* 1998;34:133-9.
16. Neville BW, Day TA. Oral cancer and precancerous lesions. *CA Cancer J Clin* 2002;52:195-215.

Received: 29 08 2016
Accepted for publishing: 28 06 2017