



## An unusual type of myeloid sarcoma localization following myelofibrosis: A case report and literature review



Nicola Orofino<sup>a</sup>, Daniele Cattaneo<sup>a</sup>, Cristina Bucelli<sup>a</sup>, Loredana Pettine<sup>a</sup>, Sonia Fabris<sup>a</sup>, Umberto Gianelli<sup>b</sup>, Nicola Stefano Fracchiolla<sup>a</sup>, Agostino Cortelezzi<sup>a</sup>, Alessandra Iurlo<sup>a,\*</sup>

<sup>a</sup> Hematology Division, IRCCS Ca' Granda – Maggiore Policlinico Hospital Foundation, Milan, Italy

<sup>b</sup> Division of Pathology, Department of Pathophysiology and Transplantation, University of Milan, and IRCCS Ca' Granda - Maggiore Policlinico Hospital Foundation, Milan, Italy

### ARTICLE INFO

#### Keywords:

Myeloid sarcoma  
Primary myelofibrosis  
Calreticulin

### ABSTRACT

Myeloid Sarcoma (MS) is a rare malignancy that can present as an isolated disease or more frequently in association with or following acute myeloid leukemia or other myeloid neoplasms and rarely following myelofibrosis.

Since molecular pathogenesis and prognostic factors of MS are not well understood, its prognosis remains poor even in the era of novel agents and target therapies.

We report the case of a patient with MS following myelofibrosis with multiple subcutaneous, cutaneous and muscle localizations; the latter has been reported in the literature as anecdotal. In this way we aimed to enhance the understanding of this disease.

### 1. Introduction

Myeloid Sarcoma (MS) is a rare entity characterized by the proliferation of immature myeloid cells in extramedullary sites. The 2008 WHO Classification of Tumours of Haematopoietic and Lymphoid Tissues and its updated 2016 version clarified the diagnosis of MS as “a tumor mass consisting of myeloid blasts with or without maturation occurring at an anatomic site other than the bone marrow” [1,2]. A predilection for males (male: female ratio = 1.2:1) is reported, with a median age at diagnosis of 56 years [3].

Myeloid sarcoma can be observed as a de novo malignancy (without leukemic presentation in peripheral blood and bone marrow), during the course of acute myeloid leukemia (AML), affecting 2.5–9% of all AML patients, myelodysplastic syndromes (MDS) or myeloproliferative neoplasms (MPNs, both chronic myeloid leukemia and *BCR-ABL1*-negative MPNs) or MDS/MPNs such as chronic myelomonocytic leukemia (CMML); it has also been described as a relapse in a previous AML [1,4,5].

Myeloid sarcoma most commonly involve lymph nodes, skin, soft tissues and testes. In less than 10% of cases the presentation may be at multiple anatomical sites.

Since MS can present at multiple sites that can be often clinically silent, Positron Emission Tomography (FDG-PET) has been demonstrated as a useful tool in detecting extramedullary AML and, as

previously revealed, it should be used both in diagnosis and after treatment, in order to evaluate response to therapy [6].

Differential diagnosis should be made with other hematological malignancies involving lymph nodes, skin and other extra-hematological sites, such as B-cell lymphomas, cutaneous or peripheral T-cell lymphomas [3].

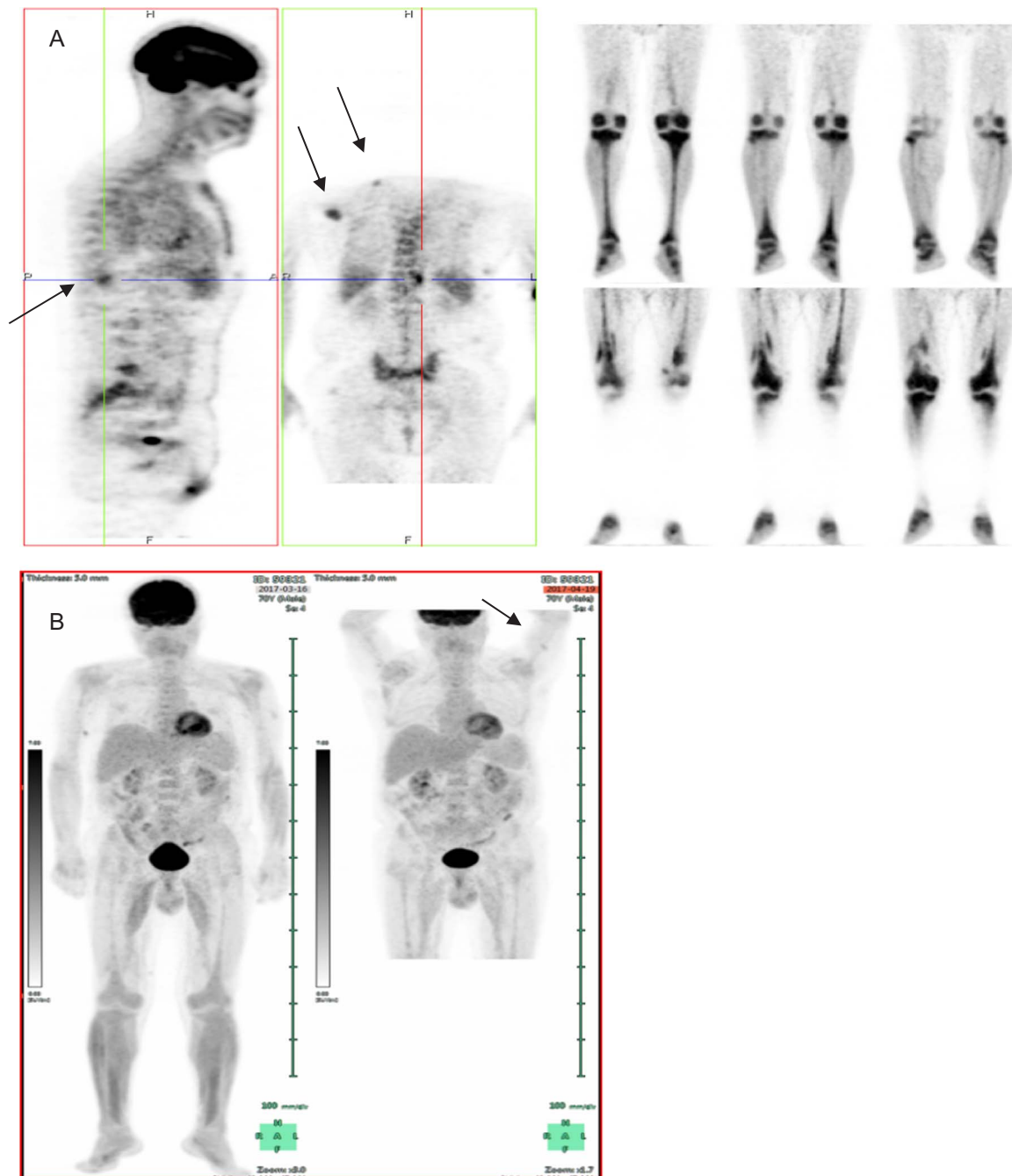
As far as genetic/molecular lesions are concerned, MS does not differ from AML. In fact, chromosomal aberrations are detected by Fluoresce in Situ Hybridization (FISH) and/or conventional cytogenetics in about half of cases and include:  $-7$ ,  $+8$ , MLL-rearrangement,  $inv(16)$ ,  $+4$ ,  $-16/16q-$ ,  $5q-$ ,  $20q-$  and  $+11$ . About 16% of patients carries nucleophosmin (NPM1) mutations, as shown by aberrant cytoplasmic NPM1 expression [1]. Furthermore, about 20–30% of MS, especially those evolving from AML, harbor mutations of FMS-like tyrosine kinase 3 (FLT3) gene, commonly Internal Tandem Duplications (ITD) [7].

Here we report an unusual case of MS presenting with multiple skin, subcutaneous and muscular lesions in a patient affected by primary myelofibrosis (PMF) which was diagnosed approximately 16 years before.

### 2. Case report

A 53-years-old man was diagnosed with pre-fibrotic PMF in 2000 in

\* Correspondence to: Hematology Division, IRCCS Ca' Granda – Maggiore Policlinico Hospital Foundation, Via Francesco Sforza 35, 20122 Milan, Italy.  
E-mail address: [aiurlo@policlinico.mi.it](mailto:aiurlo@policlinico.mi.it) (A. Iurlo).



**Fig. 1.** (A). FDG-PET detection of multiple metabolically active lesions on soft tissues on right and left shoulder, chest wall, back, epigastric region and legs (arrows). (B). FGD post induction and consolidation chemotherapy showing persistence of one metabolic active subcutaneous lesion on left arm (arrow).

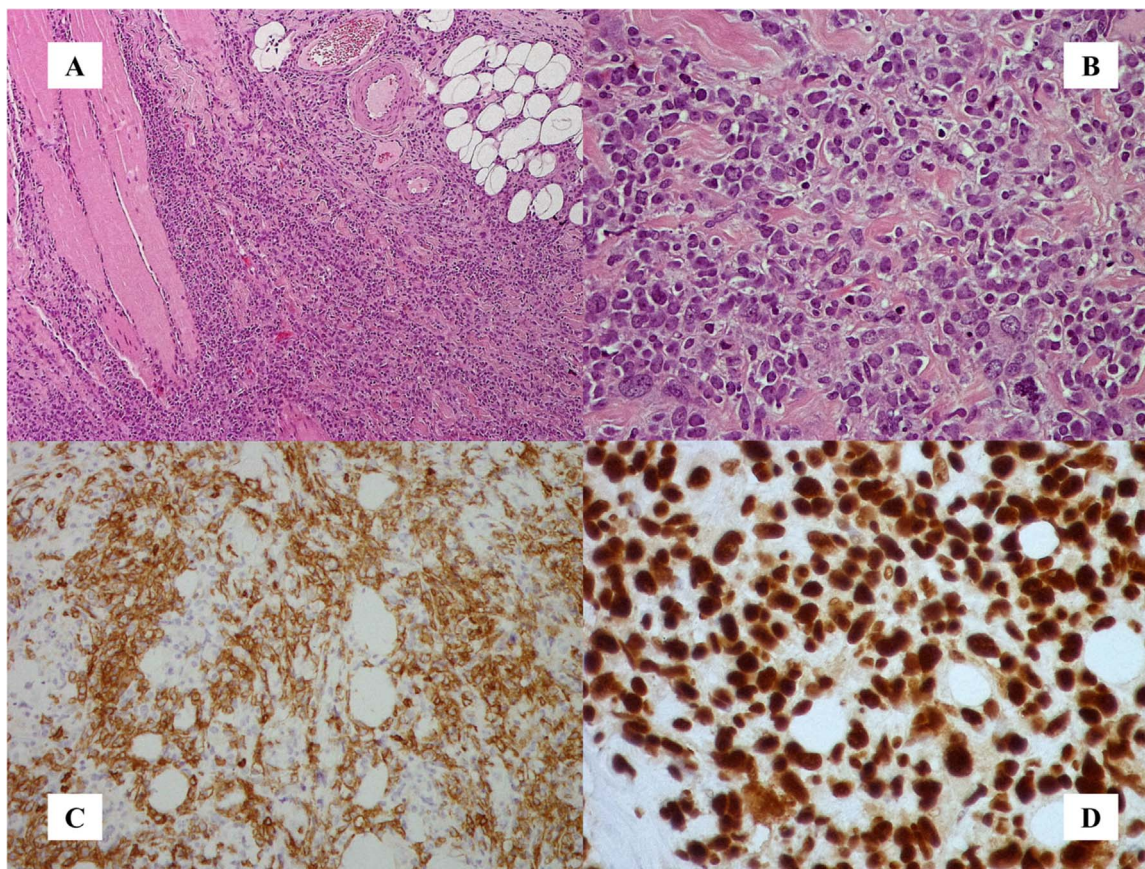
another Hospital, because of persistent, severe thrombocytosis. Conventional cytogenetic analysis showed a normal male karyotype. Consequently, he was initially treated with low-dose acetylsalicylic acid and hydroxyurea. Ten years later, he was admitted to our Institution and molecular evaluations were done, demonstrating the absence of *JAK2V617F* and *MPL* mutations, as well as *BCR-ABL1* fusion gene.

After one year of follow-up, hematological investigations revealed severe anemia (hemoglobin level of 7.6 g/dL). Since the negativity of further diagnostic evaluations, a new bone marrow biopsy was performed, revealing an increase in bone marrow fibrosis (MF-2, according to the EUMNET consensus) [7]. Consequently, the patient stopped assuming hydroxyurea and was started on corticosteroids and transfusional supportive therapy. Further molecular tests showed a type-2 mutation of the *CALR* gene (ins5-bp). At that point, MySEC score [8]

was retrospectively evaluated and it resulted Intermediate – 1.

In September 2016 the patient presented with asymptomatic subcutaneous nodules on the chest wall, neck and left arm, with a maximum diameter of 2 cm; at ultrasound examination they were hypoechogenic irregular nodules that invaded the surrounding muscle tissue. Furthermore, a FDG-PET detected multiple metabolically active lesions in soft tissues (SUV max 4.5) on right and left shoulder, chest wall, back, epigastric region and legs (Fig. 1).

Finally, a biopsy of a sub-cutaneous lesion was performed and the histopathologic examination revealed the presence of a granulocytic sarcoma. Immunohistochemistry showed that the majority of proliferating cells expressed CD34, CD43, CD117(+/-), CD45/LCA(+/-) antigens, but were negative for CD20, CD3, CD30, CD68/kp1, CD68R antigens and for myeloperoxidase. Immunohistochemical positivity of



**Fig. 2.** (A-B). Excisional biopsy of a cutaneous lesion revealing the presence of a diffuse infiltration of proliferating elements with a blastic habit, involving also the subcutaneous fat and muscle tissues. (C). Immunohistochemistry showing that the majority of proliferating cells expressed CD34 antigen. (D). Immunohistochemical positivity of NPM1 with nuclear dislocation.

NPM1 with nuclear dislocation was also present, whereas FLT3 mutations were not found (Fig. 2). Subsequently a new bone marrow biopsy showed leukemic transformation of PMF, with a normal male karyotype.

The patient underwent “3+7” induction chemotherapy with daunorubicin and cytarabine, followed by consolidation treatment with three courses of intermediate dose Ara-C, obtaining complete morphologic and immunophenotypic remission with typical features of PMF, clinical disappearance of subcutaneous nodules, but persistence of FDG-PET pathological uptake on both arms. As the pathological uptake on the right arm was in the area of a previous venous access (Fig. 1), we decided to perform radiotherapy (RT) on the contralateral arm.

### 3. Discussion

The natural history of PMF is characterized by the possibility of blastic transformation in approximately 20% of all the cases [9]. Several factors might predict leukemic transformation, including percentage of circulating blasts, low platelets count and the presence of an unfavorable karyotype. At a molecular level, it is well known that PMF patients harboring type-1 *CALR* mutation have a more indolent clinical course compared to other mutational profiles, especially considering those cases without known driver mutations (i.e. triple-negative patients). Furthermore, patients carrying high risk mutations, namely *ASXL1*, *IDH1-2*, *EZH2* and *SRSF2* show a reduced leukemia-free survival [10–12].

Nevertheless, factors that could be associated with MS development and predict a possible evolution of PMF are poorly understood, because of the rarity of these conditions.

Only few cases of MS have been reported in the literature so far

[4,5], and even fewer cases developed synchronous or metachronous PMF.

Regarding MS pathogenesis, aberrant tropism of leukemic blasts for extramedullary tissues is poorly understood. It is clear that homing of tumor cells is a complex phenomenon determined by several factors, including the expression of chemokine receptors and adhesion molecules that is already under control of many genetic and epigenetic mechanisms [13]. To address the hypothesis that MS is genetically similar to AML, in 2015 Li et al. performed next-generation sequencing analysis in six cases of isolated MS [11], and confirmed the frequent occurrence of FLT3 and NPM1 mutations. Furthermore, they identified other mutations in a broad spectrum of AML associated genes, including tumor suppressors (*WT1*), epigenetic modifiers (*TET2*, *ASXL1*, *EZH2*), spliceosome proteins (*SF3B1*) and tyrosine kinase (*FLT3* and *KIT*). With regard to *KIT* mutation, interestingly, Li et al. showed the presence of somatically acquired mutation *KIT*<sup>M541L</sup> in four of the six analyzed patients, being the latter previously associated with a variety of neoplasms including hematologic malignancies such as CML or Chronic Eosinophilic Leukemia [11, 14, 15].

Concerning MS prognosis, it varies according to the different background of MS formation. In particular, it seems clear that isolated MS presents a more favorable clinical course than cases with either concomitant AML or at AML relapse. In addition, Lan et al. and Kawamoto et al. showed a more aggressive clinical course in MS following MDS or MPN [5,16].

Furthermore, the authors showed that immunohistochemical expression of CXCR4, that could be implicated in MS pathogenesis, was a poor prognostic factor for overall survival (OS) [5].

CXCR4 over-expression in cancer is thought to be associated with chemotaxis, invasion, angiogenesis and proliferation. It has also been

demonstrated that in hematological malignancies, the over-expression of CXCR4 is related to a shortened progression-free and overall survival, in particular in AML patients [13,17].

This genomic complexity of MS implies that this malignancy presents a poor response to therapy. In fact, as recently reported by Lazzarotto et al., the complete remission rate of a cohort of 48 MS treated with various intensive induction chemotherapy regimens (including fludarabine-based, anthracycline and cytarabine containing treatments) was about 45%, and the median (OS) of the entire population was 16.7 months, with a 5-year OS of 33%. This outcome was favorably influenced by response to first induction chemotherapy and was better in patients receiving allogeneic stem cell transplantation [18].

Demethylating agents may have a role in the therapeutic scenario of MS patients, in particular for those who are ineligible for intensive treatments, although the number of cases treated is still low, due to the rarity of this disease. Recently, Gornicec et al. described three MS cases treated with decitabine achieving a good response [19]. Two other cases with durable remission were previously described [20,21].

Little is still known about the efficacy of novel agents, in particular FLT3-inhibitors in the treatment of this rare malignancy.

Radiotherapy may also be useful in the treatment of MS. In fact, this therapeutic approach provides timely symptom palliation with modest radiation doses and minimal toxicity [22]. Some case-series reported that RT for consolidation in addition to systemic chemotherapy was associated with a better outcome in patients with MS [23]. Consolidation with RT has also been suggested in patients with incomplete response to chemotherapy [24].

#### 4. Conclusion

MS, and in particular those following MF, are a rare entity. Indeed, in the two largest patient series reported so far, only few subjects had a diagnosis of MS concurrent or subsequent to MF [4,5]. Furthermore, muscle involvement is reported as anecdotal. Since its pathogenesis and genomic landscape are not well understood, the prognosis remains dismal, even in the novel agent era. Therefore, each case description is fundamental to provide a better knowledge about this rare malignancy.

#### References

- [1] S.H. Swerdlow, E. Campo, N.L. Harris, et al., WHO Classification of Tumours of Haematopoietic and Lymphoid Tissues, IARC Press, Lyon, France, 2008.
- [2] D.A. Arber, A. Orazi, R. Hasserjian, et al., The 2016 revision to the World Health Organization classification of myeloid neoplasms and acute leukemia, *Blood* 127 (2016) 2391–2405.
- [3] L.M. Almond, M. Charalampakis, S.J. Ford, et al., Myeloid sarcoma: presentation, diagnosis, and treatment, *Clin. Lymphoma Myeloma Leuk.* 17 (2017) 263–267.
- [4] S.A. Pileri, S. Ascani, M.C. Cox, et al., Myeloid sarcoma: clinico-pathologic, phenotypic and cytogenetic analysis of 92 adult patients, *Leukemia* 21 (2007) 340–350.
- [5] K. Kawamoto, H. Miyoshi, N. Yoshida, et al., Clinicopathological, cytogenetic, and prognostic analysis of 131 myeloid sarcoma patients, *Am. J. Surg. Pathol.* 40 (2016) 1473–1483.
- [6] F. Stölzel, C. Röhlig, J. Radke, et al., <sup>18</sup>F-FDG-PET/CT for detection of extramedullary acute myeloid leukemia, *Haematologica* 96 (2011) 1552–1556.
- [7] M.A. Ansari-Lari, C.F. Yang, R. Tinawi-Aljundi, et al., FLT3 mutations in myeloid sarcoma, *Br. J. Haematol.* 126 (2004) 785–791.
- [8] F. Passamonti, T. Giorgino, B. Mora, et al., A clinical-molecular prognostic model to predict survival in patients with post polycythemia vera and post essential thrombocythemia myelofibrosis, *Leukemia* (2017), <http://dx.doi.org/10.1038/leu.2017.169> (Epub ahead of print).
- [9] J. Thiele, H.M. Kvasnicka, F. Facchetti, et al., European consensus on grading of bone marrow fibrosis and assessment of cellularity, *Haematologica* 90 (2005) 1128–1132.
- [10] A. Tefferi, Primary myelofibrosis: 2017 update on diagnosis, risk-stratification, and management, *Am. J. Hematol.* 91 (2016) 1262–1271.
- [11] Z. Li, F. Stölzel, K. Onel, et al., Next-generation sequencing reveals clinically actionable molecular markers in myeloid sarcoma, *Leukemia* 29 (2015) 2113–2116.
- [12] E. Rumi, D. Pietra, C. Pascutto, et al., Clinical effect of driver mutations of JAK2, CALR, or MPL in primary myelofibrosis, *Blood* 124 (2014) 1062–1069.
- [13] H. Zhao, L. Guo, H. Zhao, et al., CXCR4 over-expression and survival in cancer: a system review and meta-analysis, *Oncotarget* 6 (2015) 5022–5040.
- [14] K. Inokuchi, H. Yamaguchi, M. Tarusawa, et al., Abnormality of c-kit oncoprotein in certain patients with chronic myelogenous leukemia: potential clinical significance, *Leukemia* 16 (2002) 170–177.
- [15] A. Iurlo, U. Gianelli, A. Beghini, et al., Identification of kit (M541L) somatic mutation in chronic eosinophilic leukemia, not otherwise specified and its implication in low-dose imatinib response, *Oncotarget* 5 (2014) 4665–4670.
- [16] T.Y. Lan, D.T. Lin, H.F. Tien, et al., Prognostic factors of treatment outcomes in patients with granulocytic sarcoma, *Acta Haematol.* 122 (2009) 238–246.
- [17] A.C. Spoo, M. Lubbert, W.G. Wierda, et al., CXCR4 is a prognostic marker in acute myelogenous leukemia, *Blood* 109 (2007) 786–791.
- [18] D. Lazzarotto, A. Candoni, C. Fili, et al., Clinical outcome of myeloid sarcoma in adult patients and effect of allogeneic stem cell transplantation. Results from a multicenter survey, *Leuk. Res.* 53 (2017) 74–81.
- [19] M. Gornicec, A. Wolfner, S. Stanzel, et al., Evidence for a role of decitabine in the treatment of myeloid sarcoma, *Ann. Hematol.* 96 (2017) 505–506.
- [20] S.N. Singh, Q. Cao, I. Gojo, et al., Durable complete remission after single agent decitabine in AML relapsing in extramedullary sites after allo-SCT, *Bone Marrow Transplant.* 47 (2012) 1008–1009.
- [21] G. Modi, I. Madabhavi, H. Panchal, et al., primary vaginal myeloid sarcoma: a rare case report and review of the literature, *Case Rep. Obstet. Gynecol.* (2015) 9574.
- [22] M.D. Hall, Y.J. Chen, T.E. Schulthesis, et al., Treatment outcomes for patients with chloroma receiving radiation therapy, *J. Med. Imaging Radiat. Oncol.* 58 (2014) 523–527.
- [23] A.M. Tsimberidou, H.M. Kantarjian, E. Estey, et al., Outcome in patients with nonleukemic granulocytic sarcoma treated with chemotherapy with or without radiotherapy, *Leukemia* 17 (2003) 1100–1103.
- [24] R.L. Bakst, M.D. Tallman, D. Douer, et al., How I treat extramedullary acute myeloid leukemia, *Blood* 118 (2011) 3785–3793.