

R E V I E W

Rotator cuff calcific tendinopathy: from diagnosis to treatment

Vito Chianca¹, Domenico Albano², Carmelo Messina⁷, Federico Midiri⁴, Giovanni Mauri⁵, Alberto Aliprandi⁶, Michele Catapano³, Lorenzo Carlo Pescatori³, Cristian Giuseppe Monaco³, Salvatore Gitto³, Anna Pisani Mainini³, Angelo Corazza⁷, Santi Rapisarda⁷, Grazia Pozzi⁷, Antonio Barile⁸, Carlo Masciocchi⁸, Luca Maria Sconfienza⁹

¹Department of Advanced Biomedical Sciences, Federico II University, Napoli, Italy; ²Department of Radiology, DIBIMED, University of Palermo, Palermo, Italy; ³Scuola di Specializzazione in Radiodiagnostica, Università degli Studi di Milano, Milano, Italy; ⁴University of Palermo, Palermo, Italy; ⁵Division of Interventional Radiology, Istituto Europeo di Oncologia, Milano, Italy; ⁶Unit of Radiology, Istituti Clinici Zucchi, Monza, Italy; ⁷Unit of Diagnostic and Interventional Radiology, IRCCS Istituto Ortopedico Galeazzi, Milano, Italy; ⁸Unit of Diagnostic and Interventional Radiology, Università dell'Aquila, Italy; ⁹Department of Biomedical Sciences for Health, Università degli Studi di Milano, Milano, Italy

Summary. Rotator cuff calcific tendinopathy (RCCT) is a very common condition caused by the presence of calcific deposits in the rotator cuff (RC) or in the subacromial-subdeltoid (SASD) bursa when calcification spreads around the tendons. The pathogenetic mechanism of RCCT is still unclear. It seems to be related to cell-mediated disease in which metaplastic transformation of tenocytes into chondrocytes induces calcification inside the tendon of the RC. RCCT is a frequent finding in the RC that may cause significant shoulder pain and disability. It can be easily diagnosed with imaging studies as conventional radiography (CR) or ultrasound (US). Conservative management of RCCT usually involves rest, physical therapy, and oral NSAIDs administration. Imaging-guided treatments are currently considered minimally-invasive, yet effective methods to treat RCCT with about 80% success rate. Surgery remains the most invasive treatment option in chronic cases that fail to improve with other less invasive approaches. (www.actabiomedica.it)

Key words: calcific tendinopathy, rotator cuff, US, MRI, percutaneous treatments

Introduction

Rotator cuff calcific tendinopathy (RCCT) is a very common condition caused by the presence of calcific deposits in the rotator cuff (RC) or in the subacromial-subdeltoid (SASD) bursa when calcification spreads around the tendons (1-5). This condition has been reported in 2.5%-7.5% of healthy shoulders in adults (6-10), occurring in women in about 70% of cases, especially during the 4th and 5th decades of life (11-15) and seems not to be correlated to physical activity (16-20). In about 10-20% of patients, calcific deposits are bilateral.

In the RC, the most affected area is the critical zone of the supraspinatus tendon (80%), followed by the lower side of the infraspinatus (15%), and the preinsertional area of the subscapularis tendon (5% of cases) (5, 21-25). However, other sites in the body may be affected, being the extrarotator tendons of the hip the most frequently involved.

Deposits may be asymptomatic in 20% of cases or determine low-grade pain, which may be associated with acute or gradual restriction of range of movements (26-30). Classically, this condition tends to have spontaneous resolution and it is uncommon to

see associated degenerative tendon changes (31-35). If symptomatic, RCCT usually responds to relative rest, oral nonsteroidal anti-inflammatory drugs (NSAIDs), corticosteroids injection within the SASD bursa, and physical therapy (36-42). However, RCCT may represent a highly disabling condition in some cases, with pain resistant to high doses of NSAIDs, usually increasing at night (43-47).

No standard of care has been established for RCCT and its management includes surgery (48), shock wave therapy (27), and image-guided procedures (43, 49-52).

Pathophysiology

The pathogenetic mechanism of RCCT is still unclear. It seems to be related to cell-mediated disease in which metaplastic transformation of tenocytes into chondrocytes induces calcification inside the tendon of the RC (1). Burkhead (53) and Gohlke (54) postulated a pathogenesis based on a degenerative process involving tendon fibers with necrotic changes that progress into dystrophic calcification. However, this theory seems not to be compatible with the *restitutio ad integrum* that happens when RCCT spontaneously resolves (55). Rui et al suggested that calcification process could be the result of erroneous differentiation of tendon stem cells into bone cells (56); this theory was supported by Hashimoto et al who showed that injection of recombinant human bone morphogenetic protein-2 into the rabbit's tendon induces ectopic ossicle formation (57).

Other authors correlated RCCT with a decrease of intratendinous oxygen concentration that can promote tendon fibrocartilaginous metaplasia and cellular necrosis, ultimately followed by calcium deposition (16, 58-63).

At any rate, pathogenesis of RCCT can be divided into three stages, as reported by Uthoff et al. (16):

1: *precalcific stage*, with tendon transformation in fibrocartilaginous tissue which acts as a substrate for calcium deposition.

2: *calcific stage*, with real calcium deposition. It is composed of the formative and resorptive phase. The first is characterized by calcium crystals deposition into the tendon, which is mediated by the chondrocytes of

the fibrocartilaginous metaplasia. The resorptive phase begins after a variable time period of silent course of disease in which vascular weaving develops in the affected area with subsequent macrophages phagocytosis of the calcium deposit (36). This phase is characterized by edema and increased intratendinous pressure with possible extravasation of calcium crystals in the SASD bursa. The resorptive phase is usually associated with the development of acute pain that can be highly disabling and unresponsive to common analgesics.

3: *Postcalcific stage*, with tendon tissue remodelling by fibroblasts after calcium deposition, which can last several months. The postcalcific stage and the resorptive phase of the calcific stage seem to occur simultaneously, with the replacement of calcium deposits by granulation tissue. This process usually ends with complete healing of the involved tendon.

Imaging

Conventional radiography (CR)

CR is widely used in the musculoskeletal system to evaluate a number of different conditions (64-68). When dealing with RCCT, CR may detect the presence of calcifications in the soft tissues around the humerus and in the subacromial space, thus confirming the clinical suspect. CR can also detect the presence of a calcification in patients who perform the examinations for other reasons. Standard radiographs used for diagnosis and follow-up of RCCT are the antero-posterior (AP), outlet, and axillary views, as they provide useful information regarding location and morphology of the calcium deposits (69-71).

Several authors tried to classify the calcium deposits on the basis of the size, morphology, or radiographic appearance. Mole et al classified the deposits in four classes (72): (i) type A, sharply defined, homogenous and dense calcification; (ii) type B, sharply defined, dense in appearance, with multiple fragments; (iii) type C, heterogeneous calcification in appearance, with a dawning deposit; (iv) type D, dystrophic calcification in the tendon insertion. The type C and D are associated with the resorptive phase and calcific deposits are barely visible on radiographs in this phase (73). Gartner

and Heyer (21) classified RCCT into: (i) type I, well circumscribed, dense calcification, formative phase; (ii) type II: soft contour/dense or sharp/transparent; and type III; translucent and cloudy appearance without clear circumscription, resorptive phase (Fig. 1).

Ultrasound (US)

US is a well-accepted modality for the evaluation of soft tissue structures throughout the body (21, 34, 38, 74-93). On US, the calcium deposits usually appear hyperechoic with or without acoustic posterior shadowing. Bianchi and Martinoli (94) described three different calcifications types, based on their different percentage of calcium. In type I, calcifications appear as hyperechoic foci with a well-defined acoustic shadowing due to their substantial quantitative of calcium. In type II, calcification appears as hyperechoic foci with a mild acoustic shadow due to the reduced amount of calcium; in type III, calcification appears almost isoechoic with the tendon, without an acoustic shadow and often they are difficult to diagnose. Type I correspond to formative phase while type II and III calcifications correspond to the resorptive phase. Sconfienza et al. (95, 96) proposed a different classification of RCCT at ultrasound: (i) hard calcifications, hyperechoic with strong acoustic shadowing; (ii) soft

calcifications, hyperechoic, almost isoechoic with the tendon, without acoustic shadowing; and (iii) fluid calcifications, hypo/anechoic, without acoustic shadowing (Fig. 2). This classification is mainly related to the

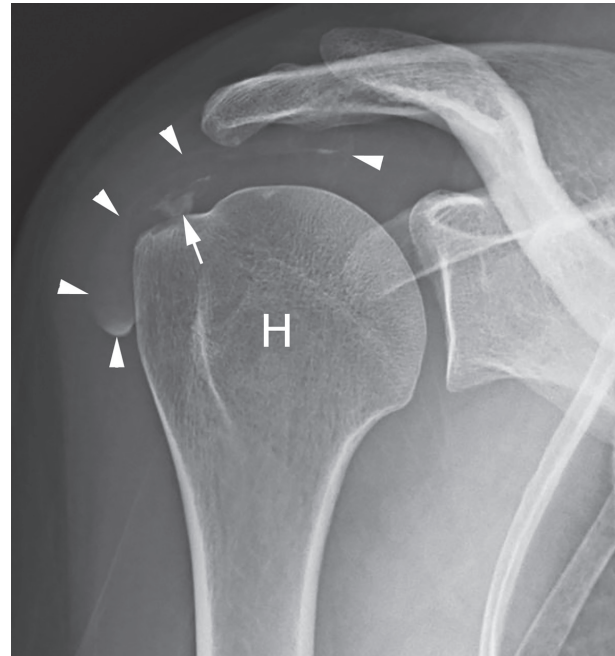


Figure 2. Calcific tendinopathy of the supraspinatus (arrow). In this case, most of the calcification has drained into the subacromial-subdeltoid bursa (arrowheads), which can be easily seen on conventional radiograph. H=humeral

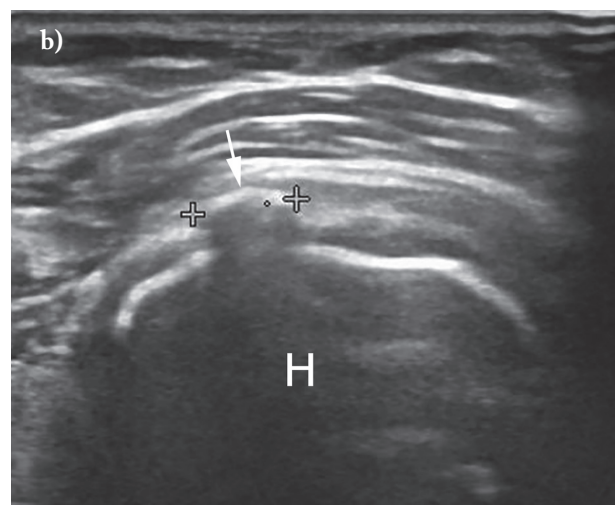
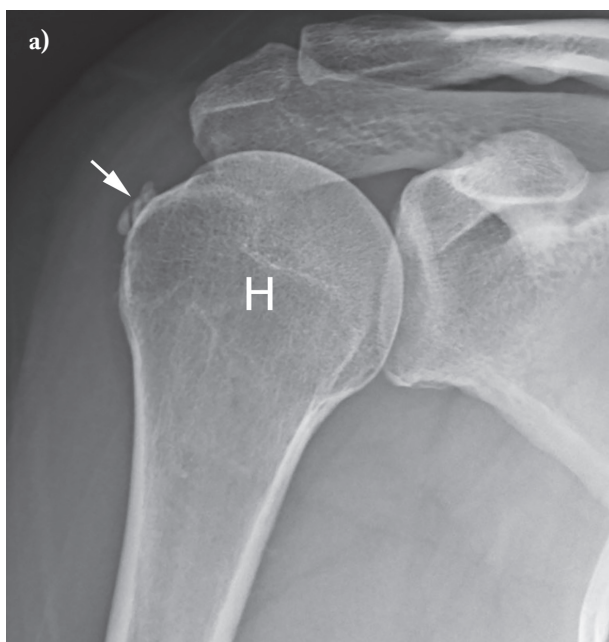


Figure 1. Calcific tendinopathy (arrow) of the supraspinatus tendon evaluated using (a) conventional radiography and (b) ultrasound in the same patient. The calcification has a maximum diameter of 7 mm. H=humeral

three different types of RCCT commonly encountered in patients undergoing interventional procedures (see below). Chiou et al described the potential advantage of color doppler in the identification of the formative and resorptive phase of calcifications with a strong correlation between color Doppler findings and clinical symptoms (97).

Magnetic Resonance Imaging (MRI)

MRI is a well-established imaging technique (98) in the musculoskeletal system and particularly in the shoulder (18, 30, 99-101). However, the low amount of resonating protons contained in calcific deposits usually leads to poor visibility of the calcification itself (80). Conversely, when the calcification is particularly oedematous, signal changes may occur, mimicking the presence of a tendon tear.

In 2016, Nörenberg et al (102) evaluated the diagnostic performance of susceptibility-weighted imaging (SWI) for the detection of shoulder calcific deposits in comparison to that of conventional radiography. SWI showed sensitivity of 98% and specificity of 96% for the identification of calcifications when compared with radiography, thus leading to better diagnostic performance than standard shoulder MRI protocols.

MRI may be used to evaluate intraosseous migration of calcification in some cases of RCCT (102). Porcellini et al suggested that calcium deposits in contact with the tuberosities consistently produce cortical lesions which determine less improvement after therapeutic treatment(103). This is also confirmed by Klontzas et al (104) who recently reported that patients with intraosseous extension have a less satisfactory outcome compared to patients with uncomplicated RCCT.

Treatment

Conservative treatment

Conservative management of RCCT usually involves rest, physical therapy, and oral NSAIDs administration. Matsen et al supposed that physiotherapy with range of motion exercises could be able to avoid

gleno-humeral stiffness and frozen shoulder, but there is no evidence that RCCT is linked with gleno-humeral capsular impairment (105). Ogon et al defined the failure of conservative treatment as the persistence of clinical symptoms for at least 6 months, including 3 months of standardized treatment (106).

Various injections with different techniques have been used in the management of RCCT, using or not US guidance. An intra-SASD injection of corticosteroids may be used to relieve patient's symptoms due to subacromial impingement and bursitis (107). However, it has been demonstrated that US-guided percutaneous aspiration of calcific tendinopathy (US-PICT) is superior to SASD bursa injections in this setting (108).

Extra-corporeal shock wave therapy (ESWT)

ESWT is an option for the management of RCCT, with reported alternate results. This method is based on the application of repetitive pulses over the affected shoulder. The exact underlying mechanism of the therapeutic effect of ESWT on RCCT is still debated. Regarding the direct mechanical effect, ESWT induce calcium deposit fragmentation due to the increasing pressure inside the deposit itself, while regarding its molecular effect, it seems to be related to the phagocytosis of calcium deposit induced by neovascularization inflammatory response and leukocyte chemotaxis(109). There is evidence in literature that ESWT in association with needling procedure could lead to higher frequency of therapeutic success compared with ESWT alone(110). At any rate, the use of ESWT in patients with acute pain given by RCCT in resorption seems to be suboptimal.

US-PICT and needling

US is widely used as guidance for musculoskeletal procedures (111-117) especially in the shoulder (118), allowing to avoid radiation exposure for both radiologist and patients (83, 119, 120). US-PICT is currently accepted as a first-line, safe, and effective treatment for RCCT (121, 122) with significant pain relief and a low incidence of minor complications such as vasovagal reaction and bursitis (123).

Different approaches have been reported in recent studies and all include the use of a fluid (local anaesthetic or saline solution) to dissolve calcium deposits; one needle (124-126) or two needles (49) are used to inject and retrieve the fluid to dissolve calcium deposits. Recent evidence showed that a double-needle approach might be more appropriate to treat harder deposits, while one needle may be more useful in treating fluid calcifications (96).

US-PICT is always indicated in the acute phase of the pathology, in presence of soft or fluid calcifications. In cases of hard calcifications in mildly symptomatic patients, elective treatments should be considered (43). Percutaneous treatment is not indicated when patients are asymptomatic, calcification is very small (≤ 5 mm), or it has migrated into the bursal space (127). There is evidence that patients with intraosseous migration of calcification experience worse results (104).

Some advantages of US-PICT are that the procedure does not require any hospitalization, is performed under local anesthesia, the patient can return home about 30 minutes after the procedure is completed, there is no need of post-procedural immobilization, and the patient can return to work the day after the procedure.

In brief, US-PICT is performed with patient supine after sterile preparation of the skin and US probe, and the calcification is visualized along its major axis; a small amount of local anaesthetic (up to 10 ml of lidocaine) is injected in the SASD bursa and near the

calcification. If two needles are used, the first is inserted into the lowest portion of the calcification with needle bevel open towards the probe, while the second needle is inserted into the calcification parallel and superficial to the first one, with its bevel opposite to the first needle in order to create a correct washing circuit (128, 129). Applying an intermittent pressure, the calcification is progressively filled with saline solution to dissolve its core and allowing the washing fluid to get out of the second needle, until a complete internal emptying is visualized. If the calcification is treated with one needle only, washing procedure is performed by pushing the syringe plunger to hydrate the deposit and calcium refluxes back together with saline solution or anaesthetic within the same syringe (55).

It is preferable to use warm saline solution to reduce procedure duration and improve calcium deposit dissolution, particularly in cases of hard calcifications (95). There is also evidence that the use of warm saline could be also associated with a reduction in postprocedural bursitis incidence (95). The final phase of the procedure involves injection of low-solubility steroid into the SASD bursa; color Doppler may be a useful tool to ensure the injected fluids in the correct site (117).

An alternative procedure is to perform dry needling of the calcification. It consists of a series of punctures performed under US guidance on the degenerated area of the tendon to fragment the deposit, induce local bleeding, and promote calcium deposit resorption (117) (Fig. 3).

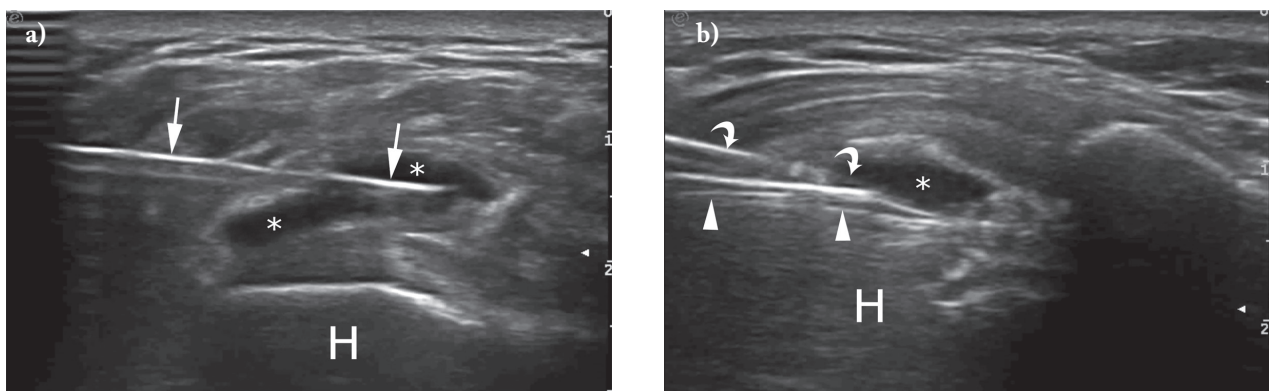


Figure 3. End of ultrasound-guided percutaneous irrigation of calcific tendinopathy procedure performed with (a) one needle (arrow) and (b) two needles (superficial needle, curved arrows; deeper needle, arrowheads). The calcification is totally empty (asterisks) in both cases. H=humeral

Surgery

Arthroscopy is another option to treat RCCT. Currently, it is regarded as the last option in chronic cases in which conservative or less invasive approaches have failed. Calcium deposits under arthroscopic evaluation were identified as a bulge within tendon structure, also known as the “calcific bulging sign” (130). Calcification removal techniques vary regarding the type of tendon incision and the instrumentation used to remove the calcium deposit (131).

One of the great advantages of surgery is that, while removing the calcification, the surgeon may also perform other procedures, such as subacromial decompression and thorough cleaning of the joint (132). However, surgery requires hospitalization, general anesthesia or sedation, and quite a long rehabilitation period after treatment.

Conclusion

RCCT is a frequent finding in the RC that may cause significant shoulder pain and disability. It can be easily diagnosed with imaging studies as CR or US. Although resorption of deposits occurs spontaneously in the majority of cases, some patients show persistent clinical symptoms requiring medical attention. Most patients respond favourably to conservative treatments, but if symptoms persist, other therapeutic options such as US-PICT or ESWT may be considered. Surgery remains the most invasive treatment option in chronic cases that fail to improve with other less invasive approaches.

References

1. A DEC, Pulcinelli F, Rose GD, Pitino D, Ferretti A. Calcific tendinitis of the shoulder. *Joints* 2014; 2: 130-6.
2. Silvestri E, Barile A, Albano D, Messina C, Orlandi D, Corazza A, Zugaro L, Masciocchi C, Sconfienza LM. Interventional therapeutic procedures in the musculoskeletal system: an Italian Survey by the Italian College of Musculoskeletal Radiology. *Radiol Med* 2017, in press.
3. Splendiani A, Ferrari F, Barile A, Masciocchi C, Gallucci M. Occult neural foraminal stenosis caused by association between disc degeneration and facet joint osteoarthritis: Demonstration with dedicated upright MRI system. *Radiol Med* 2014; 119: 164-174.
4. Barile A, Lanni G, Conti L, Mariani S, Calvisi V, Castagna A, Rossi F, Masciocchi C. Lesions of the biceps pulley as cause of anterosuperior impingement of the shoulder in the athlete: Potentials and limits of MR arthrography compared with arthroscopy. *Radiol Med* 2013; 118: 112-122.
5. Masciocchi C, Conchiglia A, Gregori LM, Arrigoni F, Zugaro L, Barile A. Critical role of HIFU in musculoskeletal interventions. *Radiol Med* 2014; 119: 470-475.
6. Speed CA, Hazleman BL. Calcific tendinitis of the shoulder. *N Engl J Med* 1999; 340: 1582-4.
7. Barile A, Arrigoni F, Bruno F, Guglielmi G, Zappia M, Reginelli A, Ruscitti P, Cipriani P, Giacomelli R, Brunese L, Masciocchi C. Computed Tomography and MR Imaging in Rheumatoid Arthritis. *Radiol Clin North Am* 2017;
8. Zappia M, Castagna A, Barile A, Chianca V, Brunese L, Pouliart N. Imaging of the coracoglenoid ligament: a third ligament in the rotator interval of the shoulder. *Skelet Radiol* 2017; 46: 1101-1111.
9. Barile A, Arrigoni F, Zugaro L, Zappia M, Cazzato RL, Garnon J, Ramamurthy N, Brunese L, Gangi A, Masciocchi C. Minimally invasive treatments of painful bone lesions: state of the art. *Med Oncol* 2017; 34:
10. Arrigoni F, Barile A, Zugaro L, Splendiani A, Di Cesare E, Caranci F, Ierardi AM, Floridi C, Angileri AS, Reginelli A, Brunese L, Masciocchi C. Intra-articular benign bone lesions treated with Magnetic Resonance-guided Focused Ultrasound (MRgFUS): imaging follow-up and clinical results. *Med Oncol* 2017; 34:
11. Clavert P, Sirveaux F, Societe francaise da. [Shoulder calcifying tendinitis]. *Rev Chir Orthop Reparatrice Appar Mot* 2008; 94: 336-55.
12. Reginelli A, Zappia M, Barile A, Brunese L. Strategies of imaging after orthopedic surgery. *Musculoskeletal Surg* 2017; 101:
13. Di Pietto F, Chianca V, de Ritis R, Cesarano E, Reginelli A, Barile A, Zappia M, Ginolfi L. Postoperative imaging in arthroscopic hip surgery. *Musculoskeletal Surg* 2017; 101: 43-49.
14. Barile A, Bruno F, Mariani S, Arrigoni F, Reginelli A, De Filippo M, Zappia M, Splendiani A, Di Cesare E, Masciocchi C. What can be seen after rotator cuff repair: a brief review of diagnostic imaging findings. *Musculoskeletal Surg* 2017; 101: 3-14.
15. Barile A, Bruno F, Mariani S, Arrigoni F, Brunese L, Zappia M, Splendiani A, Di Cesare E, Masciocchi C. Follow-up of surgical and minimally invasive treatment of Achilles tendon pathology: a brief diagnostic imaging review. *Musculoskeletal Surg* 2017; 101: 51-61.
16. Uthoff HK, Sarkar K. Calcifying tendinitis. *Baillieres Clin Rheumatol* 1989; 3: 567-81.
17. Welfling J, Kahn MF, Desroy M, Paolaggi JB, de Seze S. Calcifications of the shoulder. II. The disease of multiple tendinous calcifications. *Rev Rhum Mal Osteoartic* 1965; 32: 325-34.

18. De Filippo M, Pesce A, Barile A, Borgia D, Zappia M, Romano A, Pogliacomini F, Verdano M, Pellegrini A, Johnson K. Imaging of postoperative shoulder instability. *Musculoskelet Surg* 2017; 101: 15-22.
19. Masciocchi C, Arrigoni F, Marra AL, Mariani S, Zugaro L, Barile A. Treatment of focal benign lesions of the bone: MRgFUS and RFA. *Br J Radiol* 2016; 89:
20. Barile A, La Marra A, Arrigoni F, Mariani S, Zugaro L, Splendiani A, Di Cesare E, Reginelli A, Zappia M, Brunese L, Duka E, Carrafiello G, Masciocchi C. Anaesthetics, steroids and platelet-rich plasma (PRP) in ultrasound-guided musculoskeletal procedures. *Br J Radiol* 2016; 89:
21. Gartner J, Heyer A. Calcific tendinitis of the shoulder. *Orthopade* 1995; 24: 284-302.
22. Zoccali C, Rossi B, Zoccali G, Barbarino E, Gregori L, Barile A, Masciocchi C. A new technique for biopsy of soft tissue neoplasms: A preliminary experience using MRI to evaluate bleeding. *Minerva Med* 2015; 106: 117-120.
23. Arrigoni F, Gregori LM, Zugaro L, Barile A, Masciocchi C. MRgFUS in the treatment of MSK lesions: A review based on the experience of the university of L'Aquila, Italy. *Transl. Cancer Res* 2014; 3: 442-448.
24. Masciocchi C, Conti L, D'Orazio F, Conchiglia A, Lanni G, Barile A, Errors in musculoskeletal MRI, Errors in Radiology, Springer-Verlag Milan 2012, pp. 209-217.
25. Limbucci N, Rossi F, Salvati F, Pistoia LM, Barile A, Masciocchi C. Bilateral Suprascapular nerve entrapment by glenoid labral cysts associated with rotator cuff damage and posterior instability in an amateur weightlifter. *J Sports Med Phys Fitness* 2010; 50: 64-67.
26. McKendry RJ, Uthoff HK, Sarkar K, Hyslop PS. Calcifying tendinitis of the shoulder: prognostic value of clinical, histologic, and radiologic features in 57 surgically treated cases. *J Rheumatol* 1982; 9: 75-80.
27. Cacchio A, Paoloni M, Barile A, Don R, de Paulis F, Calvisi V, Ranavolo A, Frascarelli M, Santilli V, Spacca G. Effectiveness of radial shock-wave therapy for calcific tendinitis of the shoulder: single-blind, randomized clinical study. *Phys Ther* 2006; 86: 672-82.
28. Klausner A, Demharter J, De Marchi A, Sureda D, Barile A, Masciocchi C, Faletti C, Schirmer M, Kleffel T, Bohndorf K, group Is. Contrast enhanced gray-scale sonography in assessment of joint vascularity in rheumatoid arthritis: results from the IACUS study group. *Eur Radiol* 2005; 15: 2404-10.
29. Zappia M, Reginelli A, Russo A, D'Agosto GF, Di Pietto F, Genovese EA, Coppolino F, Brunese L. Long head of the biceps tendon and rotator interval. *Musculoskeletal Surg* 2013; 97: S99-S108.
30. Zappia M, Di Pietto F, Aliprandi A, Pozza S, De Petro P, Muda A, Sconfienza LM. Multi-modal imaging of adhesive capsulitis of the shoulder. *Insights Imaging* 2016; 7: 365-71.
31. Uthoff HK, Sarkar K. Classification and definition of tendinopathies. *Clin Sports Med* 1991; 10: 707-20.
32. Zappia M, Carfora M, Romano AM, Reginelli A, Brunese L, Rotondo A, Castagna A. Sonography of chondral print on humeral head. *Skelet Radiol* 2016; 45: 35-40.
33. Perrotta FM, Astorri D, Zappia M, Reginelli A, Brunese L, Lubrano E. An ultrasonographic study of entheses in early psoriatic arthritis patients naive to traditional and biologic DMARDs treatment. *Rheumatol Int* 2016; 36: 1579-1583.
34. Pinto A, Brunese L, Pinto F, Reali R, Daniele S, Romano L. The Concept of Error and Malpractice in Radiology. *Semin Ultrasound CT MRI* 2012; 33: 275-279.
35. Nurzynska D, DiMeglio F, Castaldo C, Latino F, Romano V, Miraglia R, Guerra G, Brunese L, Montagnani S. Flatfoot in children: Anatomy of decision making. *Ital J Anat Embryol* 2012; 117: 98-106.
36. Greis AC, Derrington SM, McAuliffe M. Evaluation and nonsurgical management of rotator cuff calcific tendinopathy. *Orthop Clin North Am* 2015; 46: 293-302.
37. Pinto A, Pinto F, Faggian A, Rubini G, Caranci F, Macarini L, Genovese EA, Brunese L. Sources of error in emergency ultrasonography. *Crit Ultrasound J* 2013; 5: 1-5.
38. Zappia M, Aliprandi A, Pozza S, Doniselli FM, Gitto S, Sconfienza LM. How is shoulder ultrasound done in Italy? A survey of clinical practice. *Skeletal Radiol* 2016; 45: 1629-1634.
39. Perrotta FM, Astorri D, Zappia M, Reginelli A, Brunese L, Lubrano E. An ultrasonographic study of entheses in early psoriatic arthritis patients naive to traditional and biologic DMARDs treatment. *Rheumatol Int* 2016; 36: 1579-1583.
40. Caranci F, Briganti F, La Porta M, Antinolfi G, Cesarano E, Fonio P, Brunese L, Coppolino F. Magnetic resonance imaging in brachial plexus injury. *Musculoskeletal Surg* 2013; 97: S181-S190.
41. Bernuzzi G, Petraglia F, Pedrini MF, De Filippo M, Pogliacomini F, Verdano MA, Costantino C. Use of platelet-rich plasma in the care of sports injuries: our experience with ultrasound-guided injection. *Blood Transfus* 2014; 12 Suppl 1: s229-34.
42. Bertolini L, Vaglio A, Bignardi L, Buzio C, De Filippo M, Palmisano A, Mercati K, Zompatori M, Maggiore U. Subclinical interstitial lung abnormalities in stable renal allograft recipients in the era of modern immunosuppression. *Transplant Proc* 2011; 43: 2617-23.
43. Serafini G, Sconfienza LM, Lacelli F, Silvestri E, Aliprandi A, Sardanelli F. Rotator cuff calcific tendonitis: short-term and 10-year outcomes after two-needle us-guided percutaneous treatment--nonrandomized controlled trial. *Radiology* 2009; 252: 157-64.
44. Cappabianca S, Colella G, Russo A, Pezzullo M, Reginelli A, Iaselli F, Rotondo A. Maxillofacial fibrous dysplasia: personal experience with gadolinium-enhanced magnetic resonance imaging. *Radiol Med* 2008; 113: 1198-210.
45. Valentini G, Marcoccia A, Cuomo G, Vettori S, Iudici M, Bondanini F, Santoriello C, Ciani A, Cuzzolino D, De Matteis GM, Cappabianca S, Vitelli F, Spano A. Early systemic sclerosis: marker autoantibodies and videocapillaroscopy

- patterns are each associated with distinct clinical, functional and cellular activation markers. *Arthritis Res Ther* 2013; 15: R63.
46. Di Zazzo E, Porcile C, Bartollino S, Monchamont B. Critical Function of PRDM2 in the Neoplastic Growth of Testicular Germ Cell Tumors. *Biology (Basel)* 2016; 5:
 47. Caranci F, Cicala D, Cappabianca S, Briganti F, Brunese L, Fonio P. Orbital Fractures: Role of Imaging. *Semin Ultrasound CT MRI* 2012; 33: 385-391.
 48. Yoo JC, Park WH, Koh KH, Kim SM. Arthroscopic treatment of chronic calcific tendinitis with complete removal and rotator cuff tendon repair. *Knee Surg Sports Traumatol Arthrosc* 2010; 18: 1694-9.
 49. Farin PU, Jaroma H, Soimakallio S. Rotator cuff calcifications: treatment with US-guided technique. *Radiology* 1995; 195: 841-3.
 50. Ronco V, Potenza DM, Denti F, Vullo S, Gagliano G, Tognolina M, Guerra G, Pinton P, Genazzani AA, Mapelli L, Lim D, Moccia F. A novel Ca(2)(+)-mediated cross-talk between endoplasmic reticulum and acidic organelles: implications for NAADP-dependent Ca(2)(+) signalling. *Cell Calcium* 2015; 57: 89-100.
 51. Briganti F, Delehaye L, Leone G, Sicignano C, Buono G, Marseglia M, Caranci F, Tortora F, Maiuri F. Flow diverter device for the treatment of small middle cerebral artery aneurysms. *J Neurointervent Surg* 2016; 8: 287-294.
 52. Muccio CF, Caranci F, D'Arco F, Cerase A, De Lipsis L, Esposito G, Tedeschi E, Andreula C. Magnetic resonance features of pyogenic brain abscesses and differential diagnosis using morphological and functional imaging studies: A pictorial essay. *J Neuroradiol* 2014; 41: 153-167.
 53. Burkhead WZ, Jr. A history of the rotator cuff before Codman. *J Shoulder Elbow Surg* 2011; 20: 358-62.
 54. Gohlke F. Early European contributions to rotator cuff repair at the turn of the 20th century. *J Shoulder Elbow Surg* 2011; 20: 352-7.
 55. Sconfienza LM, Vigano S, Martini C, Aliprandi A, Randelli P, Serafini G, Sardanelli F. Double-needle ultrasound-guided percutaneous treatment of rotator cuff calcific tendinitis: tips & tricks. *Skeletal Radiol* 2013; 42: 19-24.
 56. Rui YF, Lui PP, Chan LS, Chan KM, Fu SC, Li G. Does erroneous differentiation of tendon-derived stem cells contribute to the pathogenesis of calcifying tendinopathy? *Chin Med J (Engl)* 2011; 124: 606-10.
 57. Hashimoto Y, Yoshida G, Toyoda H, Takaoka K. Generation of tendon-to-bone interface "enthesis" with use of recombinant BMP-2 in a rabbit model. *J Orthop Res* 2007; 25: 1415-24.
 58. Mohr W, Bilger S. Basic morphologic structures of calcified tendopathy and their significance for pathogenesis. *Z Rheumatol* 1990; 49: 346-55.
 59. Dragoni S, Turin I, Laforenza U, Potenza DM, Bottino C, Glasnov TN, Prestia M, Ferulli F, Saitta A, Mosca A, Guerra G, Rosti V, Luinetti O, Ganini C, Porta C, Pedrazzoli P, Tanzi F, Montagna D, Moccia F. Store-operated Ca2+ entry does not control proliferation in primary cultures of human metastatic renal cellular carcinoma. *Biomed Res Int* 2014; 2014: 739494.
 60. Briganti F, Tedeschi E, Leone G, Marseglia M, Cicala D, Giamundo M, Napoli M, Caranci F. Endovascular treatment of vertebro-vertebral arteriovenous fistula. *Neuroradiol J* 2013; 26: 339-346.
 61. Carotti M, Salaffi F, Di Carlo M, Giovagnoni A. Relationship between magnetic resonance imaging findings, radiological grading, psychological distress and pain in patients with symptomatic knee osteoarthritis. *Radiol Med* 2017;
 62. Offidani A, Cellini A, Valeri G, Giovagnoni A. Subclinical joint involvement in psoriasis: magnetic resonance imaging and X-ray findings. *Acta Derm Venereol* 1998; 78: 463-5.
 63. Valeri G, Ferrara C, Ercolani P, De Nigris E, Giovagnoni A. Tendon involvement in rheumatoid arthritis of the wrist: MRI findings. *Skeletal Radiol* 2001; 30: 138-43.
 64. Renner JB. Conventional radiography in musculoskeletal imaging. *Radiol Clin North Am* 2009; 47: 357-72.
 65. Caranci F, Tedeschi E, Leone G, Reginelli A, Gatta G, Pinto A, Squillaci E, Briganti F, Brunese L. Errors in neuroradiology. *Radiol Med* 2015; 120: 795-801.
 66. Pinto A, Reginelli A, Pinto F, Lo Re G, Midiri F, Muzj C, Romano L, Brunese L. Errors in imaging patients in the emergency setting. *Br J Radiol* 2016; 89:
 67. Cataldi V, Laporta T, Sverzellati N, De Filippo M, Zompatori M. Detection of incidental vertebral fractures on routine lateral chest radiographs. *Radiol Med* 2008; 113: 968-77.
 68. Catapano M, Albano D, Pozzi G, Accetta R, Memoria S, Pregliasco F, Messina C, Sconfienza LM. Differences between orthopaedic evaluation and radiological reports of conventional radiographs in patients with minor trauma admitted to the emergency department. *Injury* 2017; 48: 2451-6.
 69. ElShewy MT. Calcific tendinitis of the rotator cuff. *World J Orthop* 2016; 7: 55-60.
 70. Messina C, Albano D, Rapisarda S, Sconfienza LM. Misdiagnosis of vertebral fractures on plain films: Are radiologists really working so bad? *Bone* 2017; 105: 307.
 71. De Filippo M, Ingegnoli A, Carloni A, Verardo E, Sverzellati N, Onniboni M, Corsi A, Tomassetti S, Mazzei M, Volterrani L, Poletti V, Zompatori M. Erdheim-Chester disease: clinical and radiological findings. *Radiol Med* 2009; 114: 1319-29.
 72. Mole D, Kempf JF, Gleyze P, Rio B, Bonnomet F, Walch G. Results of endoscopic treatment of non-broken tendinopathies of the rotator cuff. 2. Calcifications of the rotator cuff. *Rev Chir Orthop Reparatrice Appar Mot* 1993; 79: 532-41.
 73. Gosens T, Hofstee DJ. Calcifying tendinitis of the shoulder: advances in imaging and management. *Curr Rheumatol Rep* 2009; 11: 129-34.
 74. Corazza A, Orlandi D, Fabbro E, Ferrero G, Messina C, Sartoris R, Perugin Bernardi S, Arcidiacono A, Silvestri E, Sconfienza LM. Dynamic high-resolution ultrasound of the shoulder: how we do it. *Eur J Radiol* 2015; 84: 266-77.
 75. Longo S, Corradi A, Michielon G, Sardanelli F, Sconfienza LM. Ultrasound evaluation of the subacromial space

- in healthy subjects performing three different positions of shoulder abduction in both loaded and unloaded conditions. *Phys Ther Sport* 2017; 23: 105-112.
76. Filippou G, Adinolfi A, Delle Sedie A, Filippucci E, Iagnocco A, Porta F, Sconfienza LM, Tormenta S, Di Sabatino V, Picerno V, Frediani B. Radiologists and rheumatologists on performing and reporting shoulder ultrasound: from disagreement to consensus. *Reumatismo* 2014; 66: 233-9.
 77. Albano D, Messina C, Uselli FG, De Girolamo L, Grassi M, Maccario C, Bignotti B, Tagliafico A, Sconfienza LM. Magnetic resonance and ultrasound in achilles tendinopathy: Predictive role and response assessment to platelet-rich plasma and adipose-derived stromal vascular fraction injection. *Eur J Radiol* 2017; 95: 130-135.
 78. Gitto S, Messina C, Mauri G, Aliprandi A, Sardanelli F, Sconfienza LM. Dynamic high-resolution ultrasound of intrinsic and extrinsic ligaments of the wrist: How to make it simple. *Eur J Radiol* 2017; 87: 20-35.
 79. Sconfienza LM, Mauri G, Messina C, Aliprandi A, Secchi F, Sardanelli F, Randelli PS. Ultrasound-Guided Percutaneous Tenotomy of Biceps Tendon: Technical Feasibility on Cadavers. *Ultrasound Med Biol* 2016; 42: 2513-7.
 80. Filippou G, Adinolfi A, Cimmino MA, Scire CA, Carta S, Lorenzini S, Santoro P, Sconfienza LM, Bertoldi I, Picerno V, Di Sabatino V, Ferrata P, Galeazzi M, Frediani B. Diagnostic accuracy of ultrasound, conventional radiography and synovial fluid analysis in the diagnosis of calcium pyrophosphate dihydrate crystal deposition disease. *Clin Exp Rheumatol* 2016; 34: 254-60.
 81. Filippou G, Adinolfi A, Iagnocco A, Filippucci E, Cimmino MA, Bertoldi I, Di Sabatino V, Picerno V, Delle Sedie A, Sconfienza LM, Frediani B, Scire CA. Ultrasound in the diagnosis of calcium pyrophosphate dihydrate deposition disease. A systematic literature review and a meta-analysis. *Osteoarthritis Cartilage* 2016; 24: 973-81.
 82. Sdao S, Orlandi D, Aliprandi A, Lacelli F, Sconfienza LM, Randelli F, Sardanelli F, Serafini G. The role of ultrasonography in the assessment of peri-prosthetic hip complications. *J Ultrasound* 2015; 18: 245-50.
 83. Messina C, Banfi G, Aliprandi A, Mauri G, Secchi F, Sardanelli F, Sconfienza LM. Ultrasound guidance to perform intra-articular injection of gadolinium-based contrast material for magnetic resonance arthrography as an alternative to fluoroscopy: the time is now. *Eur Radiol* 2016; 26: 1221-5.
 84. Sconfienza LM, Orlandi D, Lacelli F, Serafini G, Silvestri E. Dynamic high-resolution US of ankle and midfoot ligaments: normal anatomic structure and imaging technique. *Radiographics* 2015; 35: 164-78.
 85. Aleo E, Barbieri F, Sconfienza L, Zampogna G, Garlaschi G, Cimmino MA. Ultrasound versus low-field magnetic resonance imaging in rheumatic diseases: a systematic literature review. *Clin Exp Rheumatol* 2014; 32: S91-8.
 86. Orlandi D, Fabbro E, Ferrero G, Martini C, Lacelli F, Serafini G, Silvestri E, Sconfienza LM. High-resolution ultrasound of the extrinsic carpal ligaments. *J Ultrasound* 2012; 15: 267-72.
 87. Orlandi D, Sconfienza LM, Fabbro E, Ferrero G, Martini C, Lacelli F, Serafini G, Silvestri E. Preliminary ultrasound evaluation of the rotator cable in asymptomatic volunteers. *J Ultrasound* 2012; 15: 16-9.
 88. Sconfienza LM, Orlandi D, Fabbro E, Ferrero G, Martini C, Savarino E, Silvestri E. Ultrasound assessment of the rotator cuff cable: comparison between young and elderly asymptomatic volunteers and interobserver reproducibility. *Ultrasound Med Biol* 2012; 38: 35-41.
 89. Sartoris R, Orlandi D, Corazza A, Sconfienza LM, Arcidiacono A, Bernardi SP, Schiaffino S, Turtulici G, Caruso P, Silvestri E. In vivo feasibility of real-time MR-US fusion imaging lumbar facet joint injections. *J Ultrasound* 2017; 20: 23-31.
 90. Carrafiello G, Fontana F, Cotta E, Petullà M, Brunese L, Mangini M, Fugazzola C. Ultrasound-guided thermal radiofrequency ablation (RFA) as an adjunct to systemic chemotherapy for breast cancer liver metastases. *Radiol Med* 2011; 116: 1059-1066.
 91. Reginelli A, Russo A, Iasiello F, Urraro F, Maresca D, Maggioletti N, Gallo MG, Antinolfi G, Stanzione F, D'Andrea A, Brunese L. Role of diagnostic imaging in the diagnosis of acute appendicitis: A comparison between ultrasound and computed tomography. *Recenti Prog Med* 2013; 104: 597-600.
 92. Piccolo CL, Galluzzo M, Ianniello S, Trinci M, Russo A, Rossi E, Zeccolini M, Laporta A, Guglielmi G, Miele V. Pediatric musculoskeletal injuries: role of ultrasound and magnetic resonance imaging. *Musculoskelet Surg* 2017; 101: 85-102.
 93. Ianniello S, Piccolo CL, Buquicchio GL, Trinci M, Miele V. First-line diagnosis of paediatric pneumonia in emergency: Lung ultrasound (LUS) in addition to chest-X-ray (CXR) and its role in follow-up. *Br J Radiol* 2016; 89:
 94. Bianchi S, Martinoli C. Ultrasound of the musculoskeletal system, *Ultrasound of the musculoskeletal system*, Springer Berlin 2007, pp. 198-332.
 95. Sconfienza LM, Bandirali M, Serafini G, Lacelli F, Aliprandi A, Di Leo G, Sardanelli F. Rotator cuff calcific tendinitis: does warm saline solution improve the short-term outcome of double-needle US-guided treatment? *Radiology* 2012; 262: 560-6.
 96. Orlandi D, Mauri G, Lacelli F, Corazza A, Messina C, Silvestri E, Serafini G, Sconfienza LM. Rotator Cuff Calcific Tendinopathy: Randomized Comparison of US-guided Percutaneous Treatments by Using One or Two Needles. *Radiology* 2017; 285: 518-527.
 97. Chiou HJ, Chou YH, Wu JJ, Hsu CC, Huang DY, Chang CY. Evaluation of calcific tendonitis of the rotator cuff: role of color Doppler ultrasonography. *J Ultrasound Med* 2002; 21: 289-95; quiz 296-7.
 98. Sardanelli F. Trends in radiology and experimental research. *European Radiology Experimental* 2017; 1: 1.
 99. Barile A, Bruno F, Mariani S, Arrigoni F, Reginelli A, De Filippo M, Zappia M, Splendiani A, Di Cesare E, Masciocchi C. What can be seen after rotator cuff repair: a brief

- review of diagnostic imaging findings. *Musculoskelet Surg* 2017; 101: 3-14.
100. Barile A, Lanni G, Conti L, Mariani S, Calvisi V, Castagna A, Rossi F, Masciocchi C. Lesions of the biceps pulley as cause of anterosuperior impingement of the shoulder in the athlete: potentials and limits of MR arthrography compared with arthroscopy. *Radiol Med* 2013; 118: 112-22.
 101. Aliprandi A, Messina C, Arrigoni P, Bandirali M, Di Leo G, Longo S, Magnani S, Mattiuz C, Randelli F, Sdao S, Sardanelli F, Sconfienza LM, Randelli P. Reporting rotator cuff tears on magnetic resonance arthrography using the Snyder's arthroscopic classification. *World J Radiol* 2017; 9: 126-133.
 102. Merolla G, Bhat MG, Paladini P, Porcellini G. Complications of calcific tendinitis of the shoulder: a concise review. *J Orthop Traumatol* 2015; 16: 175-83.
 103. Porcellini G, Paladini P, Campi F, Pegreff F. Osteolytic lesion of greater tuberosity in calcific tendinitis of the shoulder. *J Shoulder Elbow Surg* 2009; 18: 210-5.
 104. Klontzas ME, Vassalou EE, Karantanas AH. Calcific tendinopathy of the shoulder with intraosseous extension: outcomes of ultrasound-guided percutaneous irrigation. *Skeletal Radiol* 2017; 46: 201-208.
 105. FA M, SB L, JA S. Practical evaluation in management of the shoulder, WB Saunders 1994.
 106. Ogon P, Suedkamp NP, Jaeger M, Izadpanah K, Koestler W, Maier D. Prognostic factors in nonoperative therapy for chronic symptomatic calcific tendinitis of the shoulder. *Arthritis Rheum* 2009; 60: 2978-84.
 107. Uthoff HK, Loehr JW. Calcific Tendinopathy of the Rotator Cuff: Pathogenesis, Diagnosis, and Management. *J Am Acad Orthop Surg* 1997; 5: 183-191.
 108. de Witte PB, Selten JW, Navas A, Nagels J, Visser CP, Nelissen RG, Reijnen M. Calcific tendinitis of the rotator cuff: a randomized controlled trial of ultrasound-guided needling and lavage versus subacromial corticosteroids. *Am J Sports Med* 2013; 41: 1665-73.
 109. Kim YS, Lee HJ, Kim YV, Kong CG. Which method is more effective in treatment of calcific tendinitis in the shoulder? Prospective randomized comparison between ultrasound-guided needling and extracorporeal shock wave therapy. *J Shoulder Elbow Surg* 2014; 23: 1640-6.
 110. Krasny C, Enenkel M, Aigner N, Wlk M, Landsiedl F. Ultrasound-guided needling combined with shock-wave therapy for the treatment of calcifying tendonitis of the shoulder. *J Bone Joint Surg Br* 2005; 87: 501-7.
 111. Orlandi D, Corazza A, Arcidiacono A, Messina C, Serafini G, Sconfienza LM, Silvestri E. Ultrasound-guided procedures to treat sport-related muscle injuries. *Br J Radiol* 2016; 89: 20150484.
 112. Lanza E, Banfi G, Serafini G, Lacelli F, Orlandi D, Bandirali M, Sardanelli F, Sconfienza LM. Ultrasound-guided percutaneous irrigation in rotator cuff calcific tendinopathy: what is the evidence? A systematic review with proposals for future reporting. *Eur Radiol* 2015; 25: 2176-83.
 113. Orlandi D, Corazza A, Fabbro E, Ferrero G, Sabino G, Serafini G, Silvestri E, Sconfienza LM. Ultrasound-guided percutaneous injection to treat de Quervain's disease using three different techniques: a randomized controlled trial. *Eur Radiol* 2015; 25: 1512-9.
 114. Orlandi D, Corazza A, Silvestri E, Serafini G, Savarino EV, Garlaschi G, Mauri G, Cimmino MA, Sconfienza LM. Ultrasound-guided procedures around the wrist and hand: how to do. *Eur J Radiol* 2014; 83: 1231-1238.
 115. Sconfienza LM, Lacelli F, Bruno A, Serafini G. Ultrasound guidance can improve the outcome of botulinum toxin A injection. *Eur J Phys Rehabil Med* 2009; 45: 153; author reply 153.
 116. Sconfienza LM, Perrone N, Lacelli F, Lentino C, Serafini G. Ultrasound-guided injection of botulinum toxin A in the treatment of iliopsoas spasticity. *J Ultrasound* 2008; 11: 113-7.
 117. Albano D, Chianca V, Tormenta S, Migliore A, Sconfienza LM. Old and new evidence concerning the crucial role of ultrasound in guiding intra-articular injections. *Skeletal Radiol* 2017; 46: 963-964.
 118. Tagliafico A, Serafini G, Sconfienza LM, Lacelli F, Perrone N, Succio G, Martinoli C. Ultrasound-guided viscosupplementation of subacromial space in elderly patients with cuff tear arthropathy using a high weight hyaluronic acid: prospective open-label non-randomized trial. *Eur Radiol* 2011; 21: 182-7.
 119. Messina C, Orlandi D, Sconfienza LM. Do we still need fluoroscopy to perform injections in the musculoskeletal system? *Skeletal Radiol* 2016; 45: 1717-1718.
 120. Messina C, Sconfienza LM. Do we still need to take fluoroscopic guidance into account when injecting joints? *Semin Arthritis Rheum* 2017; 46: e16.
 121. Messina C, Sconfienza LM. Ultrasound-Guided Percutaneous Irrigation of Calcific Tendinopathy. *Semin Musculoskelet Radiol* 2016; 20: 409-413.
 122. Cacchio A, Rompe JD, Serafini G, Sconfienza LM, Sardanelli F. US-guided percutaneous treatment of shoulder calcific tendonitis: some clarifications are needed. *Radiology* 2010; 254: 990; author reply 990-1.
 123. Sconfienza LM, Randelli F, Sdao S, Sardanelli F, Randelli P. Septic bursitis after ultrasound-guided percutaneous treatment of rotator cuff calcific tendinopathy. *PM R* 2014; 6: 746-8.
 124. Aina R, Cardinal E, Bureau NJ, Aubin B, Brassard P. Calcific shoulder tendinitis: treatment with modified US-guided fine-needle technique. *Radiology* 2001; 221: 455-61.
 125. Giacomoni P, Siliotto R. Echo-guided percutaneous treatment of chronic calcific tendinitis of the shoulder. *Radiol Med* 1999; 98: 386-90.
 126. Orlandi D, Fabbro E, Mauri G, Savarino E, Serafini G, Sconfienza LM. RE: A Simple technique to restore needle patency during percutaneous lavage and aspiration of calcific rotator cuff tendinopathy. *PM R* 2013; 5: 633.
 127. Sconfienza LM, Albano D, Messina C, Silvestri E, Tag-

- liafico AS. How, When, Why in Magnetic Resonance Arthrography: an International Survey by the European Society of Musculoskeletal Radiology (ESSR). *Eur Radiol* 2017, in press.
128. Messina C, Banfi G, Orlandi D, Lacelli F, Serafini G, Mauri G, Secchi F, Silvestri E, Sconfienza LM. Ultrasound-guided interventional procedures around the shoulder. *Br J Radiol* 2016; 89: 20150372.
129. Sconfienza LM, Serafini G, Sardanelli F. Treatment of calcific tendinitis of the rotator cuff by ultrasound-guided single-needle lavage technique. *AJR Am J Roentgenol* 2011; 197: W366; author reply 367.
130. Rupp S, Seil R, Kohn D. Tendinosis calcarea of the rotator cuff. *Orthopade* 2000; 29: 852-67.
131. Rebuzzi E, Coletti N, Schiavetti S, Giusto F. Arthroscopy surgery versus shock wave therapy for chronic calcifying tendinitis of the shoulder. *J Orthop Traumatol* 2008; 9: 179-85.
132. Fields LK, Muxlow CJ, Caldwell PE, 3rd. Arthroscopic treatment of subscapularis calcific tendonitis. *Arthrosc Tech* 2014; 3: e571-3.

Received: 15 September 2017

Accepted: 20 December 2017

Correspondence:

Luca Maria Sconfienza

Unit of Diagnostic and Interventional Radiology,

IRCCS Istituto Ortopedico Galeazzi, Milano

Phone +39 02 6621 4497

E-mail: io@lucasconfienza.it