

Contents lists available at ScienceDirect

Indian Pacing and Electrophysiology Journal

journal homepage: www.elsevier.com/locate/IPEJ

Unusual induction of a *very slow supraventricular tachycardia*: What is the mechanism?



Maria Silvia Negroni, MD ^{*}, Simone Persampieri, MD, Fabio Mazzoleni, MD, Laura Toffetti, MD, Stefano Carugo, MD, PhD

Divisione di Cardiologia, Ospedale San Paolo, Dipartimento Scienze della Salute Università degli Studi di Milano, Italy

ARTICLE INFO

Article history:

Received 25 November 2016

Received in revised form

14 February 2017

Accepted 16 March 2017

Available online 19 March 2017

1. Case presentation

A 73-year-old man with fatigue and exertional dyspnea was referred to our clinic for evaluation of daily episodes of regular palpitations. His past medical history was notable for hypertension, diabetes mellitus, chronic obstructive pulmonary disease and hypothyroidism on medical therapy. Five months' prior he was implanted with a permanent bicameral pacemaker (PM) for sick sinus syndrome associated with head trauma secondary to syncope; the pacemaker was programmed in DDD mode, with a lower rate of 50 bpm, an upper rate of 130 bpm, and the AAI-DDD mode switch algorithm on to minimize right ventricular pacing. A 24-h Holter monitor showed several episodes of a regular rhythm, with no visible P waves, at a rate between 75 and 95 bpm. Of note, these paroxysms were induced by premature atrial contractions (PACs) conducted with a longer PR and often terminated by premature ventricular contractions (PVCs) with a retrograde P wave (Fig. 1). While interrogating his device, this clinical *slow tachycardia* was easily inducible with both atrial and ventricular pacing. Despite beta-blocker therapy (metoprolol 100 mg BID), symptoms did not resolve and the patient was brought to the electrophysiology (EP) lab for an EP study and ablation. Fig. 2 shows the response to atrial extrastimuli delivered at different phases of the tachycardia cycle. Fig. 3 shows a peculiar phenomenon occurring

during atrial induction of the tachycardia. What is the mechanism?

2. Commentary

Baseline sinus cycle length (CL), atrial-His (AH), and His-ventricular (HV) intervals were 1300, 166, and 66 ms, respectively. Ventricular pacing showed concentric and decremental ventriculoatrial (VA) conduction. With programmed atrial stimulation (single extrastimulus with coupling intervals of 420–400 ms) a short RP, regular, narrow complex slow tachycardia with a CL of 800 ms was reproducibly induced, compatible with the clinical one. The tachycardia was also easily induced with programmed ventricular pacing (single extrastimulus with coupling interval of 380 ms and VA interval of 200 ms; Fig. 4).

The differential diagnosis of short RP tachycardia includes typical slow-fast atrioventricular nodal reentrant tachycardia (AVNRT), atrio-ventricular reentrant tachycardia (AVRT), atrial tachycardia (AT) with a long AH interval, and junctional automatic tachycardia (JT).

AVRT was excluded by the VA interval <70 ms and failure to advance the atrium when pacing the ventricle during His bundle refractoriness. AT was ruled out by evidence of a VAV response upon the cessation of ventricular overdrive pacing that entrained the tachycardia. These findings do not help to distinguish between the other two arrhythmias, typical AVNRT and JT, both usually showing simultaneous atrial and ventricular activation. The atrio-ventricular relationship during tachycardia was 1:1, therefore a JT with 1:1 retrograde conduction cannot be excluded. While the slow rate points to JT, the occurrence of an anterograde AH “jump” at the time of tachycardia induction favors AVNRT. To clarify the mechanism, another diagnostic pacing maneuver can be used. As proposed by Padanilam et al., a single PAC introduced during the tachycardia is helpful to differentiate AVNRT and non-reentrant JT, particularly when the tachycardia CL is very slow, rising suspicion of JT [1]. More specifically, when a PAC is introduced during His bundle refractoriness, any perturbation to the subsequent His (advance, delay or termination of the tachycardia) indicates that anterograde slow pathway (SP) conduction is necessary for maintenance of the tachycardia, confirming the diagnosis of AVNRT with a 100% specificity. In our case, a PAC from the high right atrial lateral

^{*} Corresponding author. Divisione di Cardiologia, Ospedale San Paolo, Dipartimento Scienze della Salute, Università degli Studi di Milano, Via A. di Rudinì 8, 20142 Milan, Italy.

E-mail address: mariasilvia.negroni@ao-sanpaolo.it (M.S. Negroni).

Peer review under responsibility of Indian Heart Rhythm Society.

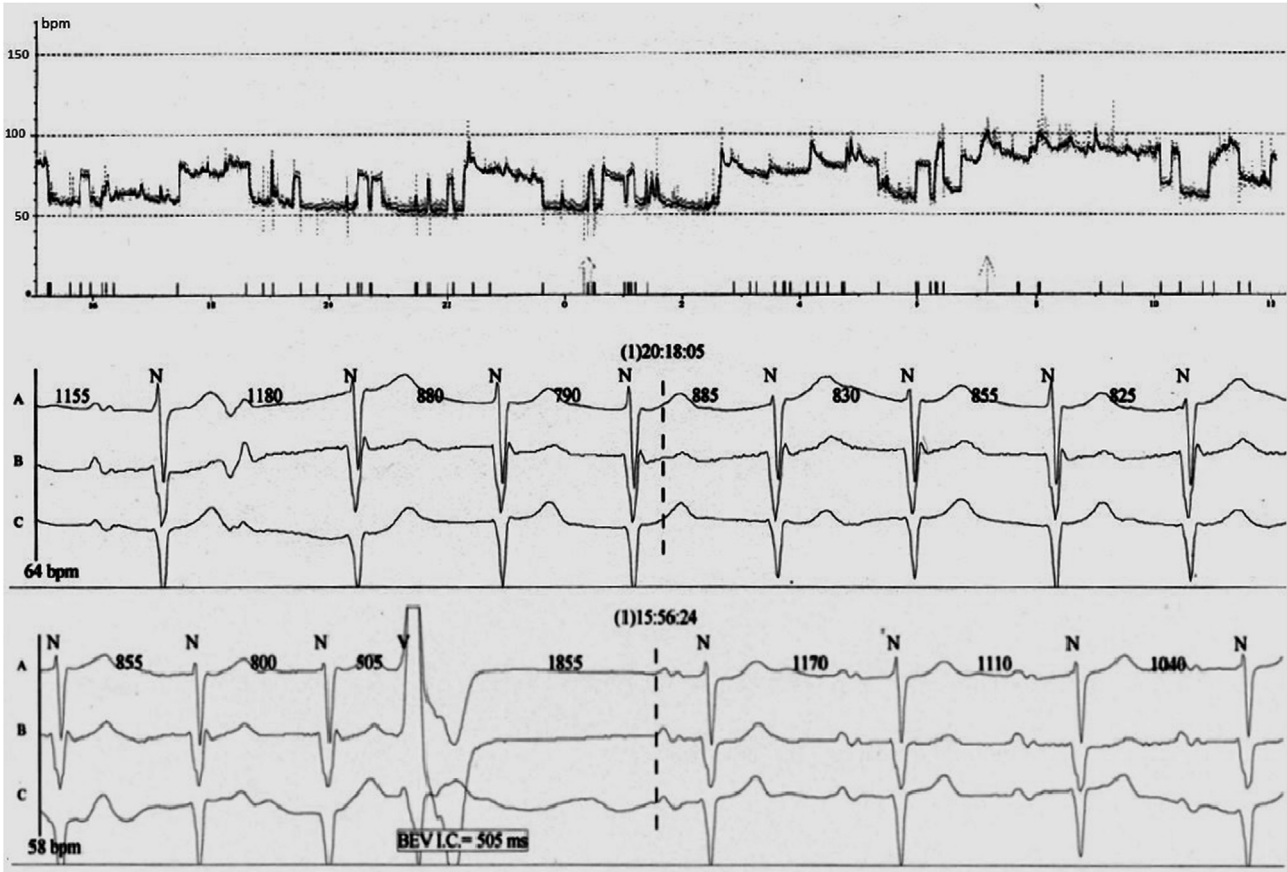


Fig. 1. Heart rate trend from the 24-h Holter monitoring with paroxysms of *slow supraventricular tachycardia*. The 3 channels rhythm strip show initiation of the tachycardia by a premature atrial contraction conducted with a longer PR and termination by a premature ventricular contraction with a retrograde P wave.

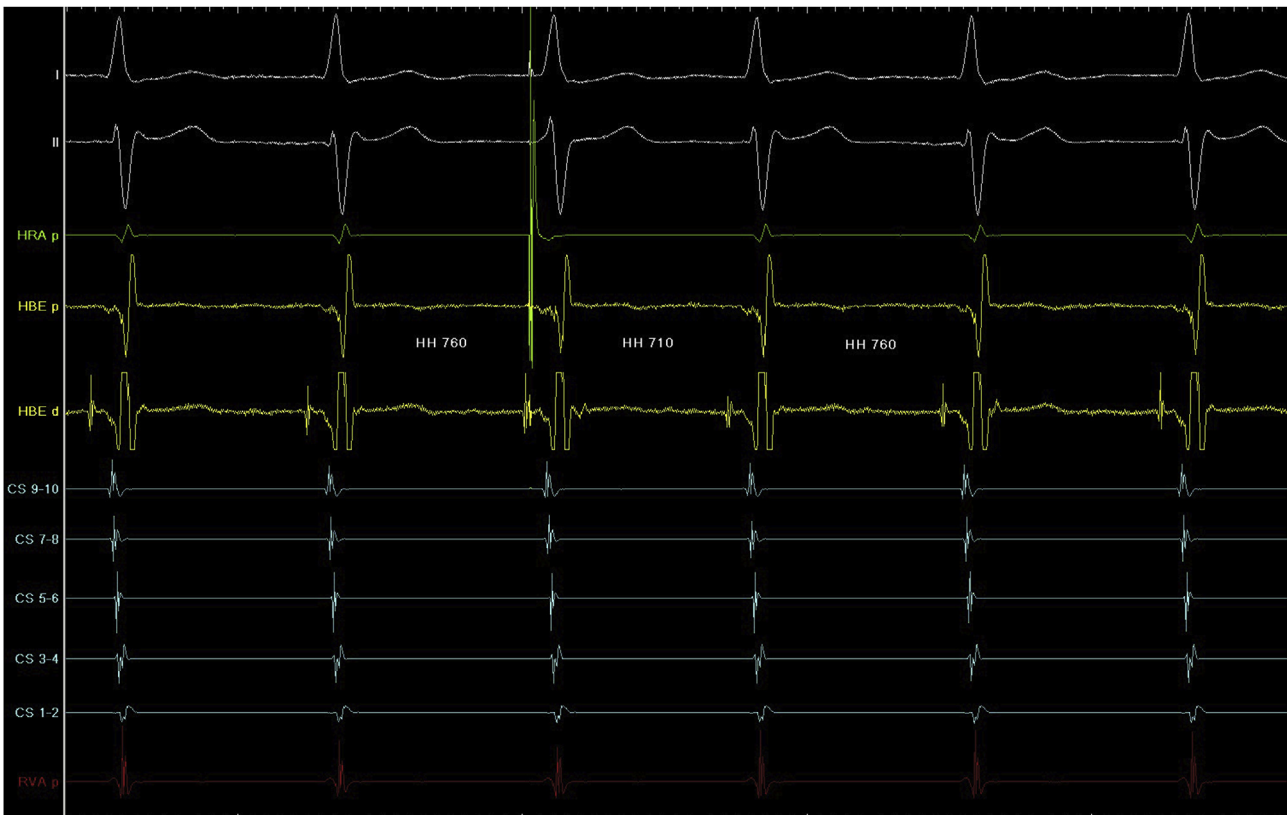

Fig. 2. In response to an atrial extrastimulus delivered during His bundle refractoriness (arrow) the subsequent His potential is advanced by 50 ms, pointing to AVNRT. The measurement in milliseconds are H-H intervals, with the electrograms recorded at a sweep speed of 100 mm/s. HRA, high right atrium, HBE, his bundle electrogram; CS, coronary sinus; RVA, right ventricular apex.

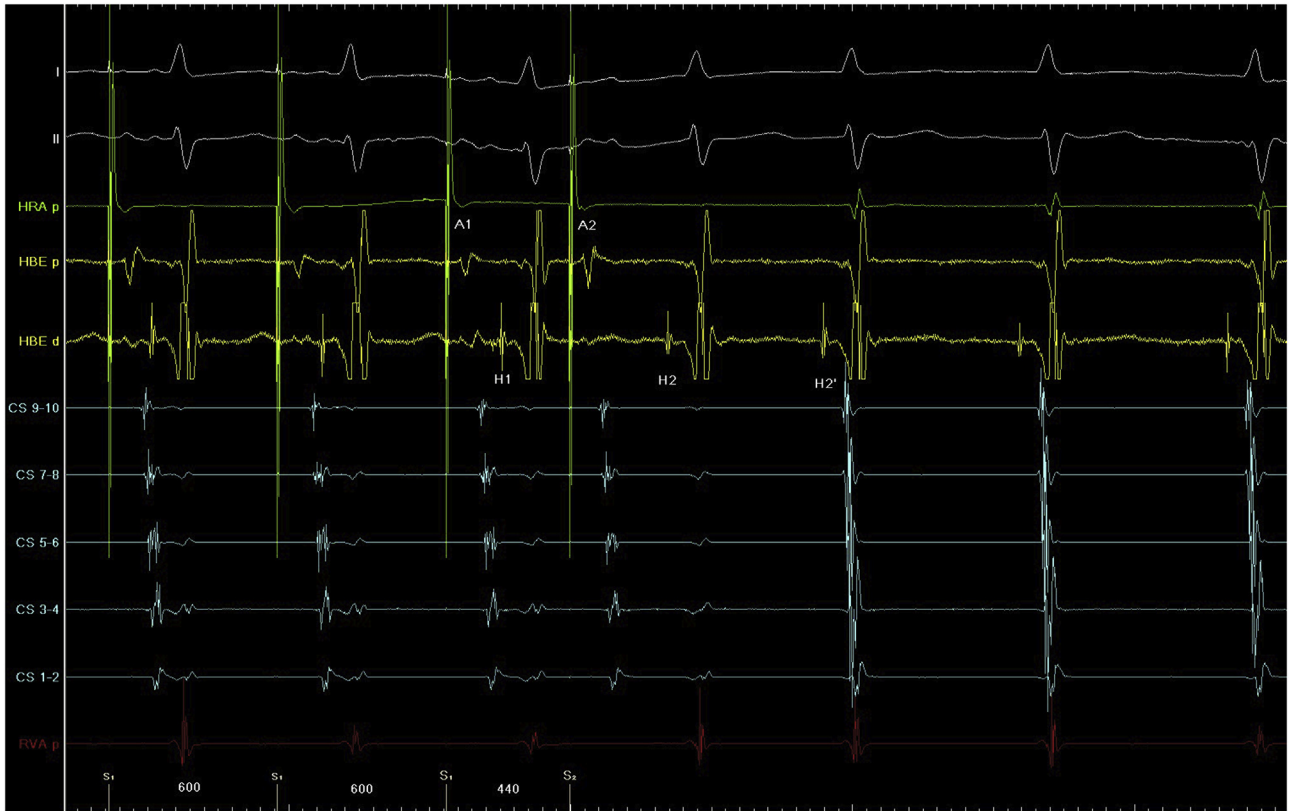

Fig. 3. Simultaneous conduction of an atrial extrastimulus (A2) over a relatively slow FP and a SP (A2H2 and A2H2' respectively) followed by induction of AVNRT with a CL of 750 ms. Electrograms recorded at a sweep speed of 100 mm/s. HRA, high right atrium; HBE, his bundle electrogram; CS, coronary sinus; RVA, right ventricular apex.

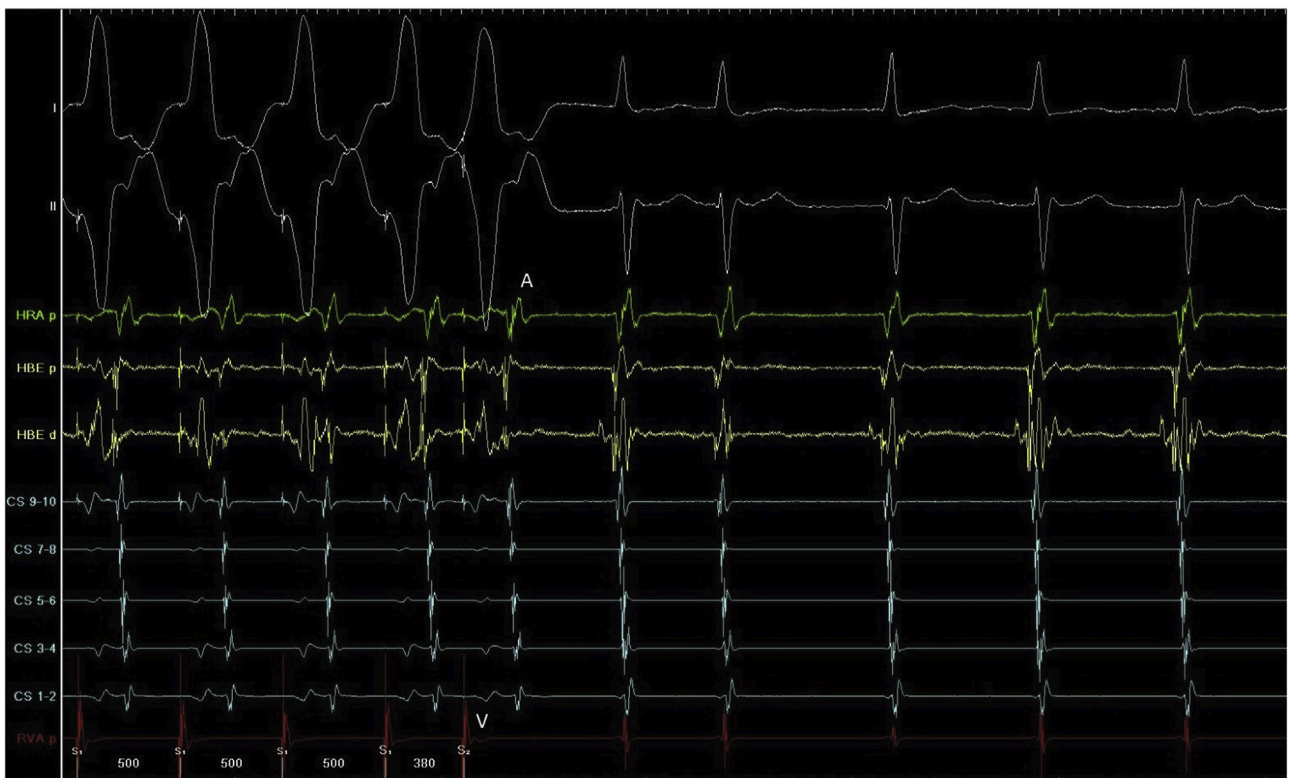

Fig. 4. Induction of AVNRT with programmed ventricular pacing: single extrastimulus with coupling interval of 380 ms and VA interval of 200 ms. Electrograms recorded at a sweep speed of 100 mm/s. HRA, high right atrium; HBE, his bundle electrogram; CS, coronary sinus; RVA, right ventricular apex.

wall, delivered just after His bundle, advanced the next His by 50 ms, proving early engagement of the SP and excluding JT (Fig. 2).

Another observation pointing to AVNRT is the double ventricular response during programmed atrial stimulation (600/440 ms) followed by induction of the tachycardia (Fig. 3). The atrial extrastimulus was conducted twice to the ventricles, with an A2H2 interval of 300 ms and a remarkably prolonged A2H2' interval of 840 ms. As expected, the H2V2 and H2'V2' intervals were equal and no different than the HV interval recorded in sinus rhythm or atrial pacing, per retroconduction over the fast pathway (FP). This response (“double fire”) is typical of a dual AV node physiology and a poorly conducting SP, as first described by Wu et al., in 1975 and can be observed upon induction of typical AVNRT [2]. In our case, the A2H2 interval represented conduction over a relatively slow FP, while the A2H2' interval conduction over a SP with very slow conduction properties, which was involved in both initiation and maintenance of the slow tachycardia. In our patient, the markedly prolonged AH intervals are justified by age, high dose beta-blocker therapy and by hypervagotonia on the AV node. A double ventricular response is typical of a poorly retrogradely conducting SP [3]: the premature atrial impulse is conducted over the FP, with no retrograde conduction into the SP, therefore there is no collision with the slow anterograde wavefront which then reaches the FP when it has regained excitability, allowing for completion of the AVNRT circuit. The other signs of a poorly conducting SP in this patient: the slow rate of the “tachycardia” and the easily

inducibility with ventricular pacing. More specifically, to induce AVNRT with ventricular pacing, retroconduction through the FP is associated with minimal to no retrograde concealed conduction into the SP, allowing for subsequent anterograde conduction through the slowly conducting SP and completion of the tachycardia circuit.

Given the loss of AV synchrony, the patient was very symptomatic during this “slow” tachycardia, requiring treatment. Radiofrequency energy was delivered in the region of the SP, eliminating both the “double fire” response and the tachycardia. At follow-up the patient was asymptomatic, with no further evidence of the slow tachycardia on a 24-h Holter.

Conflicts of interests

The authors have no conflicts of interest to disclose.

References

- [1] Padanilam BJ, Manfredi JA, Steinberg LA, Olson JA, Fogel RI, Prystowsky EN. Differentiating junctional tachycardia and atrioventricular node re-entry tachycardia based on response to atrial extrastimulus pacing. *J Am Coll Cardiol* 2008;52:1711–2.
- [2] Wu D, Denes P, Dhingra R, Pietras RJ, Rosen KM. New manifestations of dual A-V nodal pathways. *Eur J Cardiol* 1975;2:459–66.
- [3] Lin FC, Yeh SJ, Wu D. Determinants of simultaneous fast and slow pathway conduction in patients with dual atrioventricular nodal pathways. *Am Heart J* 1985;109:963–70.