

Unilateral Facial Ulceration

Maria Gavrilova, MD; Alejandro Martin-Gorgojo, MD; Carmen Ruiz-Domenech, MD; Maria-Dolores Alonso-Salvador, MD; Maria del Carmen Gomez-Mateo, MD; Esperanza Jorda-Cuevas, MD, PhD; Departments of Dermatology (Drs Gavrilova, Martin-Gorgojo, Ruiz-Domenech, and Jorda-Cuevas), Neurology (Dr Alonso-Salvador), and Anatomy Pathology (Dr Gomez-Mateo), Clinical University Hospital of Valencia, Valencia, Spain

REPORT OF A CASE

A 67-year-old white woman presented with a 5-year history of several asymptomatic facial ulcers. Her medical history included hypertension and ischemic stroke, which had occurred 6 years earlier. She complained of an

uncomfortable sensation in the affected areas, which caused her to pick at and scratch them frequently.

Cutaneous examination demonstrated multiple ulcers, all strictly limited to the left side of the face (**Figure 1**). Each ulcer showed well-defined borders with irregular outlines. Neurologic examination revealed no

abnormalities other than mild paresthesias on the left side of the face. Histologic analysis was performed with hematoxylin-eosin staining (**Figure 2** and **Figure 3**).

What is your diagnosis?

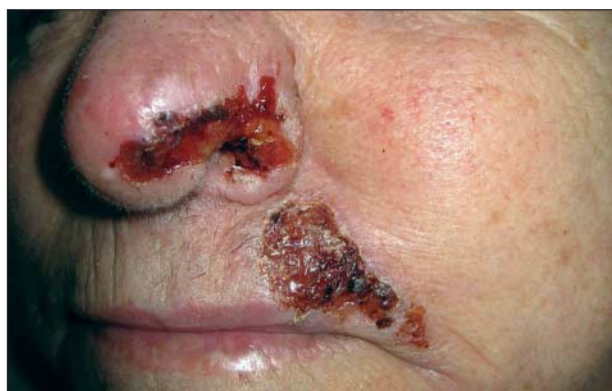

Figure 1.

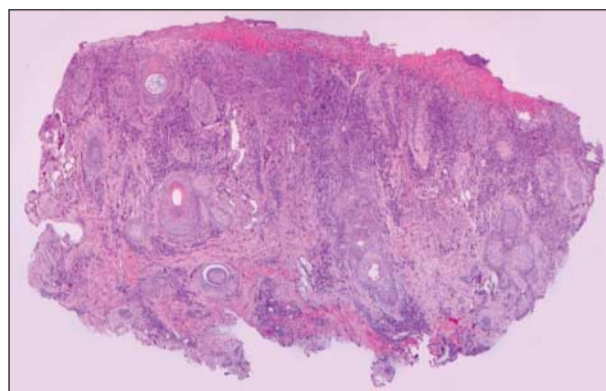


Figure 2.

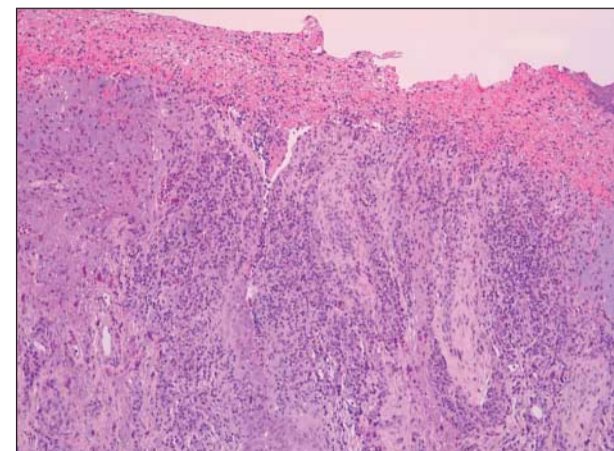


Figure 3.

A 26-Year-Old Man With an Eczematous Lesion on the Nipple

Gianluca Nazzaro, MD; Antonella Coggi, MD; Raffaele Gianotti, MD; Università degli Studi di Milano, Fondazione IRCCS Cà Granda Ospedale Maggiore Policlinico, Milano, Italy

REPORT OF A CASE

A 26-year-old white man presented with a 4-month history of an eczematous pruritic lesion on his nipple and areola. The patient had atopic dermatitis since infancy.

Physical examination revealed a well-defined, erythematous, and edematous plaque with numerous vascular points on the surface (**Figure 1**). Because the lesion showed the clinical appearance of eczema, it was treated with topical steroid without clinical improve-

ment and later with systemic antibiotics for possible bacterial superinfection. A skin biopsy was performed for histopathologic examination (**Figure 2**) with periodic acid-Schiff staining (**Figure 3**).

What is your diagnosis?

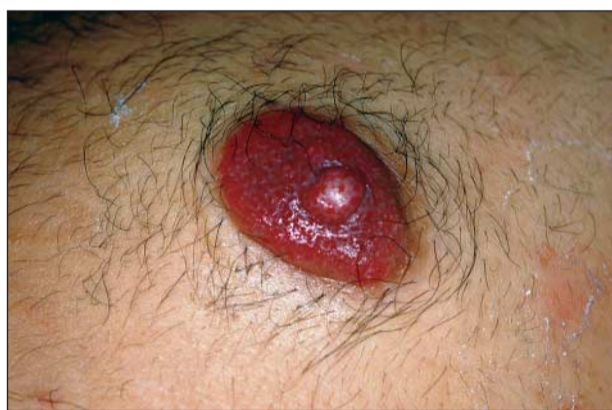

Figure 1.

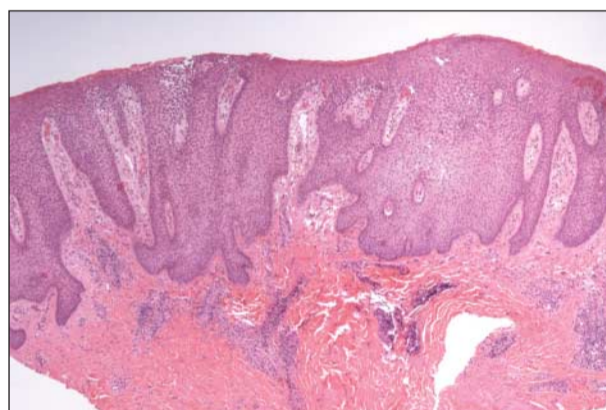


Figure 2.

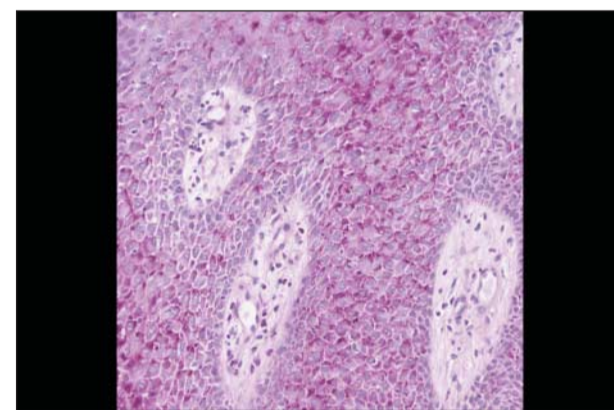


Figure 3.

Translucent Nasal Papules in a 3-Year-Old Boy

Helene S. Scheer, MD; Christian Kegel, MD; Jivko Kamarashev, MD; Lisa Weibel, MD; University Children's Hospital Zurich (Drs Scheer and Weibel), University Hospital Zurich (Drs Kamarashev, Scheer, and Weibel), and Kempf & Pfaltz Histological Diagnostics (Dr Kegel), Zurich, Switzerland

REPORT OF A CASE

A 3-year-old boy presented with 10 bluish to translucent domed papules 1 to 3 mm in diameter on the tip of his nose (**Figure 1** and **Figure 2**). His parents had first

noticed them when he was 8 months old and had observed an increase in number over time. They did not report any pruritus, and there was no association of the appearance of the papules with physical exercise, heat, or exposure to humidity. The boy was otherwise healthy,

and the family history was unremarkable. One of the papules was excised by punch biopsy and histopathologically examined (**Figure 3**).

What is your diagnosis?

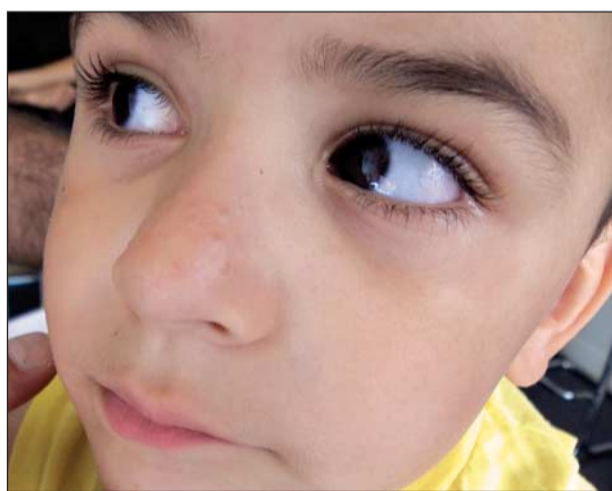

Figure 1.

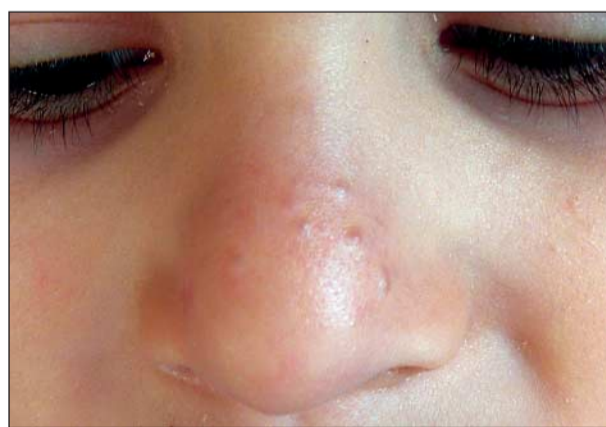

Figure 2.

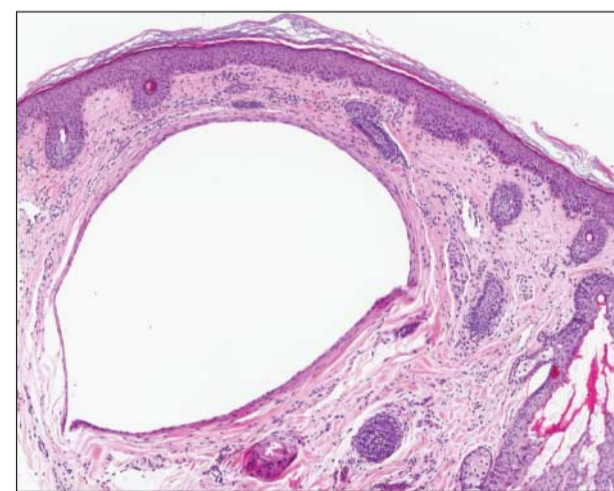


Figure 3.

Lentigolike Macules and Erythematous Plaques on Trunk and Extremities

Farah Succaria, MD; Nada El-Saad Debahy, MD; Rim Ishak, MD; Mazen Kurban, MD; Ossama Abbas, MD; American University of Beirut Medical Center, Beirut, Lebanon

REPORT OF A CASE

A 60-year-old woman presented with an 8-year history of an asymptomatic progressive skin eruption on the trunk and extremities. The skin eruption was reported to be worse during the summer. The patient was otherwise healthy and

receiving no drug therapy. Her family history was positive for similar skin condition in 2 sisters. Previous treatment with topical steroids was unsuccessful.

Physical examination revealed multiple erythematous and hyperpigmented tan macules and papules over the chest, upper extremities (mainly hands), bilateral

thighs, and shins (**Figure 1** and **Figure 2**). Some of the lesions were covered by discrete scales. No hair, nail, or mucosal abnormalities were present. A punch biopsy specimen was obtained (**Figure 3**).

What is your diagnosis?

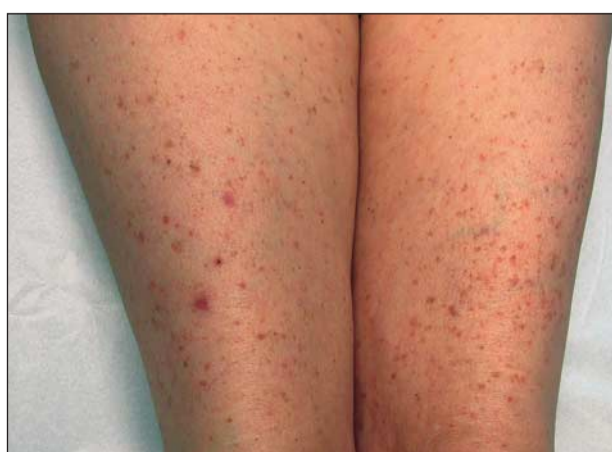

Figure 1.

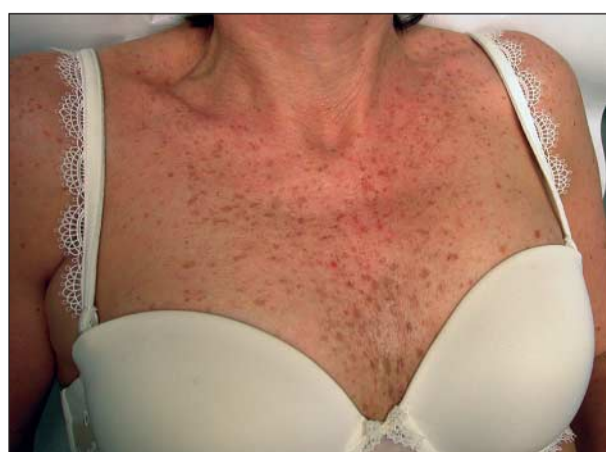

Figure 2.

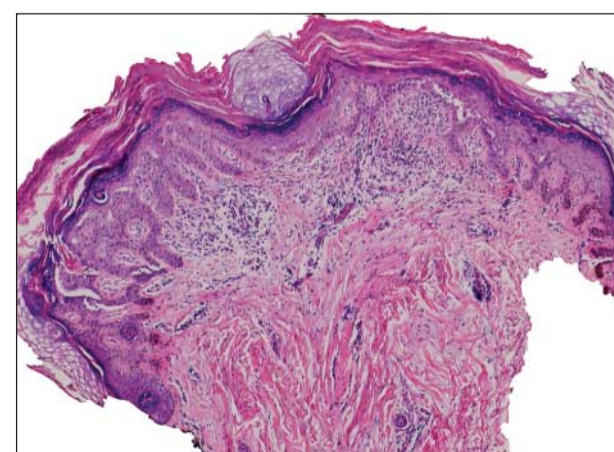


Figure 3.