

## Cognitive correlates of neuroimaging abnormalities in the onset of schizophrenia: A case report

Silvia Grassi, Giulia Orsenigo, Marta Serati, Elisabetta Caletti, Alfredo Carlo Altamura, Massimiliano Buoli

Silvia Grassi, Giulia Orsenigo, Marta Serati, Elisabetta Caletti, Alfredo Carlo Altamura, Massimiliano Buoli, Department of Psychiatry, University of Milan, Fondazione IRCCS Ospedale Maggiore Policlinico, Mangiagalli e Regina Elena, 20122 Milan, Italy

First decision: April 18, 2017  
Revised: April 27, 2017  
Accepted: May 12, 2017  
Article in press: May 15, 2017  
Published online: June 22, 2017

**Author contributions:** Grassi S and Orsenigo G collected data; Serati M revised report; Caletti E performed neuropsychological tests; Altamura AC designed the report; Buoli M wrote the paper.

**Institutional review board statement:** This case report was exempted from IRB standards of University of Milan.

**Informed consent statement:** Patient gave his written informed consent and permission for disclosure of his protected health information.

**Conflict-of-interest statement:** Professor Altamura has served as a consultant or on Advisory Boards for Roche, Merck, Astra Zeneca, Bristol Myers Squibb, Janssen/Cilag and Lundbeck. Drs Grassi, Orsenigo, Serati, Caletti and Buoli do not have any affiliation with or financial interest in any organization that might pose a conflict of interest with the present article.

**Open-Access:** This article is an open-access article which was selected by an in-house editor and fully peer-reviewed by external reviewers. It is distributed in accordance with the Creative Commons Attribution Non Commercial (CC BY-NC 4.0) license, which permits others to distribute, remix, adapt, build upon this work non-commercially, and license their derivative works on different terms, provided the original work is properly cited and the use is non-commercial. See: <http://creativecommons.org/licenses/by-nc/4.0/>

**Manuscript source:** Invited manuscript

**Correspondence to:** Silvia Grassi, MD, Department of Psychiatry, University of Milan, Fondazione IRCCS Ospedale Maggiore Policlinico, Mangiagalli e Regina Elena, Via F. Sforza 35, 20122 Milan, Italy. [silvia.grassi1@unimi.it](mailto:silvia.grassi1@unimi.it)  
Telephone: +39-02-55035983  
Fax: +39-02-55033190

Received: December 17, 2016

Peer-review started: December 19, 2016

### Abstract

Increasing evidence shows that cognitive impairment and brain abnormalities can appear early in the first episodes of schizophrenia, but it is currently debated how brain changes can correlate with clinical presentation of schizophrenic patients. Of note, this report describes the case of a young schizophrenic male presenting parietal magnetic resonance/positron emission tomography abnormalities and cognitive impairment, documented by specific neuropsychological tests. In our knowledge only few studies have investigated if neuropsychological abnormalities could be concomitant with both structural and functional neuroimaging. This case shows that impairment in specific cognitive domains is associated with structural/functional brain abnormalities in the corresponding brain areas (frontal and parietal lobes), supporting the hypothesis of disconnectivity, involving a failure to integrate anatomical and functional pathways. Future research would define the role of cognitive impairment and neurodegeneration in psychiatric nosography and, in particular, their role in the early phases of illness and long-term outcome of schizophrenic patients.

**Key words:** Positron emission tomography; Magnetic resonance; Schizophrenia; Neuropsychology

© **The Author(s) 2017.** Published by Baishideng Publishing Group Inc. All rights reserved.

**Core tip:** Schizophrenia is associated with impairment in executive function, verbal memory, verbal fluency and attention. Neuropsychological tests are associated with structural and functional brain alterations. This

case report is an example of the potential correlation between clinical symptoms (*e.g.*, cognitive impairment) and brain changes. These data may help in the prediction of possible outcome of schizophrenia patients.

Grassi S, Orsenigo G, Serati M, Caletti E, Altamura AC, Buoli M. Cognitive correlates of neuroimaging abnormalities in the onset of schizophrenia: A case report. *World J Psychiatr* 2017; 7(2): 128-132 Available from: URL: <http://www.wjgnet.com/2220-3206/full/v7/i2/128.htm> DOI: <http://dx.doi.org/10.5498/wjp.v7.i2.128>

## INTRODUCTION

A number of data would indicate schizophrenia as a progressive neurodegenerative disorder<sup>[1]</sup> whose outcome is influenced by many biological and clinical factors<sup>[2]</sup>. Of note, recent literature shows that neuropsychological deficits at onset may predict the clinical course of illness<sup>[3]</sup> being often associated with frontal and parietal lobe dysfunctions<sup>[4-6]</sup>. Moreover, a recent trial found that brain abnormalities of schizophrenic patients change according to age at onset. In particular, early onset patients show parietal abnormalities, while adult onset patients exhibit frontal and temporal ones<sup>[7]</sup>.

To our knowledge there are few studies<sup>[8-10]</sup> associating cognitive frontal and parietal deficits with structural [magnetic resonance (MR)] and functional neuroimaging [positron emission tomography (PET)] and the anatomical and functional relationships underlying this deficit remain to be elucidated. Dysconnectivity, a failure in functional integration, is considered a key mechanism in the pathophysiology of cognitive impairments (in particular working memory performance) in individuals with schizophrenia<sup>[11]</sup>.

The present paper deals with a recent diagnosed schizophrenic patient showing frontal and parietal lobe MR/PET abnormalities clinically associated with deficits in the corresponding cognitive domains.

## CASE REPORT

The patient was a 19-year-old man admitted in our department. The patient showed no psychiatric comorbidity with an Axis I disorder neither personality disorders. A neurological exam, performed by a neurologist, was negative. Diagnosis of undifferentiated schizophrenia and exclusion of comorbid conditions were assessed through the administration of semi-structured interviews based on DSM-IV criteria (SCID I and II). Patient had family history for psychiatric disorders: The father was an alcohol abuser, one schizophrenic uncle (father's brother) committed suicide and the grandmother in mother line was affected by bipolar disorder. At the admission in our ward the patient was drug-naïve and showed persecutory delusion, auditory hallucinations, thought/behavioural disorganization and a duration of untreated psychosis

of 9 mo<sup>[12]</sup>. Baseline score at Positive and Negative Syndrome Scale<sup>[13]</sup> was 84, while baseline score at Brief Psychiatric Rating Scale was 55<sup>[14]</sup>. In the first days of admission patient underwent to neuropsychological tests, cerebral MR and cerebral PET.

A neuropsychological battery was designed to encompass the areas believed to be affected by Schizophrenia<sup>[15]</sup>. Results and standard scores are summarized in Table 1. Patient's neurocognitive performances provided evidence for impairment in the following domains: Executive function (Cognitive Estimation, Verbal fluency, Trail Making Test), verbal memory, verbal ability (Boston Naming Test, phonemic Verbal Fluency) and attention (Visual Search, Trail Making Test). In addition, the patient failed in two Wechsler Adult Intelligence Scale<sup>[16]</sup> subscales: Verbal Comprehension Index and Perceptual Organization Index.

MR was performed using a circular polarized head coil and included Turbo Spin-Echo T1-weighted sequences, T2-weighted sequences and FLAIR. Imaging in three planes was performed using 5-mm slice thickness. MR revealed normal-sized ventricles, normal-sized subarachnoidal spaces, no abnormalities in gray matter, but bilaterally soft hyper-intensities in superior parietal lobe<sup>[4]</sup> periventricular white matter.

Fluorodeoxyglucose (FDG) was injected in condition of rest and fasting and after 30 min three-dimensional scan was performed. The images were compared to a cohort of normal ones. Fluoro-D-Glucose PET (Figures 1 and 2) showed glucose frontal and parietal lobes hypometabolism bilaterally. No further abnormalities in FDG distribution were observed.

MR and PET were performed by neuroradiologists collaborating within our department.

Of note, neuropsychological results are consistent with outlined MR abnormalities and PET images (fronto-parietal abnormalities)<sup>[17]</sup>.

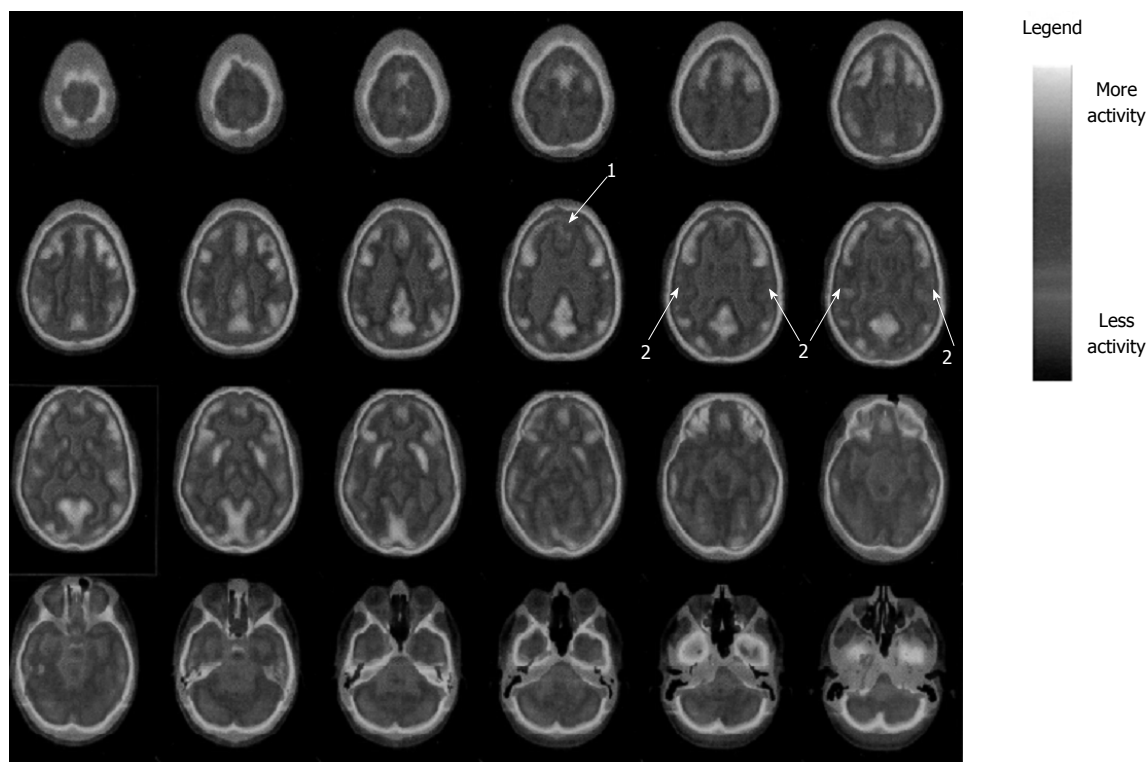
## DISCUSSION

The present case report confirms data from literature of early cognitive deficits in the course of schizophrenia<sup>[18,19]</sup> and neuroimaging parietal abnormalities in early onset schizophrenic patients<sup>[7,20,21]</sup>. In addition, the correspondence between cognitive deficits and morphological/functional brain alterations<sup>[22]</sup> contributes to clarify the influence of brain changes in schizophrenia clinical presentation as well as to support the hypothesis of schizophrenia as a neurodegenerative disorder<sup>[23,24]</sup>. Recent trials found that brain abnormalities are more severe in patients with a longer duration of illness<sup>[25-27]</sup>, novel antipsychotics are promising molecules for their efficacy in stopping the neurodegenerative process<sup>[28,29]</sup>. In this context cognitive and neuroimaging follow-up of our case can be useful to discriminate if neurodegenerative process of schizophrenia progresses in the course of illness or it is specific of early stages<sup>[24,30,31]</sup>. Finally, it would be important in the future to define the role of neuroimaging abnormalities in influencing outcome. MR

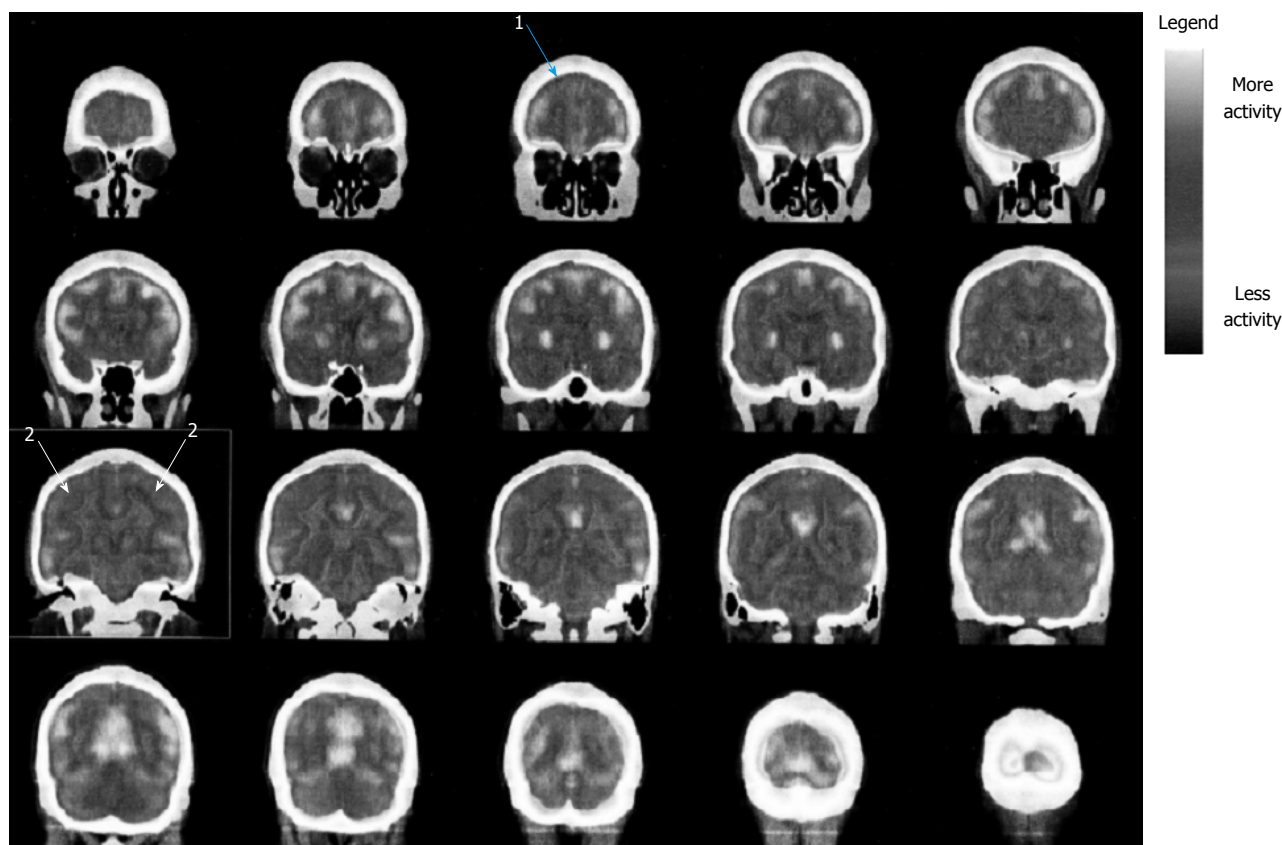
**Table 1 Neuropsychological results**

Test	Patient score	Normal value	Result	Z-score
Mini-mental state examination	27.19	24-29.19	Normal	0.45
Executive functions: Tower of London	25	20-36	Normal	-0.75
Frontal assessment battery	15.98	13.5-17.3	Normal	-0.95
Cognitive estimation task	19.97	0-18	Failed	2.43
Bizarreness	6	0-4	Failed	4
Problem solving: Raven's progressive matrices	29.05	18.6-33.05	Normal	0.89
Assessment of cognitive impairment in memory				
Verbal memory and learning				
Digit Span	5.75	3.75-8.75	Normal	-0.4
Verbal Learning	10.50	6.50-21.50	Normal	-0.93
Recall of prose: Immediate and after 10 min	3.50	8.00-27.50	Failed	-2.92
Spatial short-term memory (Corsi test)	4.50	3.50-8.50	Normal	-1.20
Attention and speed information processing				
Trail making test				
Part A	33	< 93 s	Normal	
Part B, dual task	161	< 282 s	Normal	
Part B-A	128	< 186 s	Borderline score	-1.36
Visual search	34.25	31-51.25	Borderline score	
Verbal fluency				
Phonemic	23	17-59	Borderline score	-1.43
Categories	32	25-58	Normal	-1.15
Language				
Boston naming test	31	43-60	Failed	-4.82
Token test	32	29-36	Normal	-0.29
Wechsler adult intelligence scale-revised	General IQ = 75 (verbal IQ = 81; performance IQ = 74) VCI = 5.5; POI = 6.25	80-120	Borderline score	-2.50

The standard scores, reported in the second column, are calculated considering a normal population. Our patient's scores, adjusted for age, sex and education are shown in the first column next to each test. A score is considered pathological when the score is present less than 5% of the normal population. Sometimes normal scores are considered pathological due to the clinical condition and the global performance. VCI: Verbal comprehension index; POI: Perceptual organization index.



**Figure 1 D-glucose (fluorodeoxyglucose) positron emission tomography, transversal sections.** Pointer 1 displays the frontal lobe hypo-metabolism; pointer 2 displays the parietal lobe hypo-metabolism.



**Figure 2** Fluoro-D-glucose (fluorodeoxyglucose) positron emission tomography, coronal sections. Pointer 1 displays the frontal lobe hypo-metabolism; Pointer 2 displays the parietal lobe hypo-metabolism.

and PET could be useful tools to make diagnosis and to predict long-term course of schizophrenic illness.

## COMMENTS

### Case characteristics

A 19-year-old male patient with severe schizophrenia presentation.

### Clinical diagnosis

Patient was hospitalized because of prominent persecutory delusion, auditory hallucinations, aggressiveness and thought/behavioural disorganization.

### Differential diagnosis

Bipolar disorder, substance use disorder.

### Laboratory diagnosis

Routine blood tests were resulted within normal limits.

### Imaging diagnosis

At magnetic resonance imaging bilaterally soft hyper-intensities in superior parietal lobe periventricular white matter were detected, while positron emission tomography showed glucose parietal lobes hypo-metabolism bilaterally.

### Pathological diagnosis

Schizophrenia, acute episode.

### Treatment

Ziprasidone 80 mg × 2 and Gabapentin 300 mg × 3.

### Related reports

Severe cognitive impairment as showed by neuropsychological tests.

### Term explanation

Dysconnectivity means abnormal functional integration among brain regions resulting in impaired modulation of neurotransmitters.

### Experiences and lessons

It is important to perform imaging evaluation and neuropsychological tests to better define long-term outcome of schizophrenia patients.

### Peer-review

This case report is novel and well designed.

## REFERENCES

- 1 **van Haren NE**, Schnack HG, Cahn W, van den Heuvel MP, Lepage C, Collins L, Evans AC, Hulshoff Pol HE, Kahn RS. Changes in cortical thickness during the course of illness in schizophrenia. *Arch Gen Psychiatry* 2011; **68**: 871-880 [PMID: 21893656 DOI: 10.1001/archgenpsychiatry.2011.88]
- 2 **Altamura AC**, Bobo WV, Meltzer HY. Factors affecting outcome in schizophrenia and their relevance for psychopharmacological treatment. *Int Clin Psychopharmacol* 2007; **22**: 249-267 [PMID: 17690594 DOI: 10.1097/YIC.0b013e3280de2c7f]
- 3 **Wölwer W**, Brinkmeyer J, Riesbeck M, Freimüller L, Klimke A, Wagner M, Möller HJ, Klingberg S, Gaebel W. Neuropsychological impairments predict the clinical course in schizophrenia. *Eur Arch Psychiatry Clin Neurosci* 2008; **258** Suppl 5: 28-34 [PMID: 18985291 DOI: 10.1007/s00406-008-5006-2]



- 4 **Brunet-Gouet E**, Decety J. Social brain dysfunctions in schizophrenia: a review of neuroimaging studies. *Psychiatry Res* 2006; **148**: 75-92 [PMID: 17088049 DOI: 10.1016/j.psychres.2006.05.001]
- 5 **Ragland JD**, Laird AR, Ranganath C, Blumenfeld RS, Gonzales SM, Glahn DC. Prefrontal activation deficits during episodic memory in schizophrenia. *Am J Psychiatry* 2009; **166**: 863-874 [PMID: 19411370 DOI: 10.1176/appi.ajp.2009.08091307]
- 6 **Schmidt A**, Smieskova R, Simon A, Allen P, Fusar-Poli P, McGuire PK, Bendfeldt K, Aston J, Lang UE, Walter M, Radue EW, Riecher-Rössler A, Borgwardt SJ. Abnormal effective connectivity and psychopathological symptoms in the psychosis high-risk state. *J Psychiatry Neurosci* 2014; **39**: 239-248 [PMID: 24506946 DOI: 10.1503/jpn.130102]
- 7 **Kyriakopoulos M**, Perez-Iglesias R, Woolley JB, Kanaan RA, Vyas NS, Barker GJ, Frangou S, McGuire PK. Effect of age at onset of schizophrenia on white matter abnormalities. *Br J Psychiatry* 2009; **195**: 346-353 [PMID: 19794204 DOI: 10.1192/bjp.bp.108.055376]
- 8 **Deserno L**, Sterzer P, Wüstenberg T, Heinz A, Schlagenhauf F. Reduced prefrontal-parietal effective connectivity and working memory deficits in schizophrenia. *J Neurosci* 2012; **32**: 12-20 [PMID: 22219266 DOI: 10.1523/JNEUROSCI.3405-11.2012]
- 9 **Pujol N**, Penadés R, Rametti G, Catalán R, Vidal-Piñeiro D, Palacios E, Bargallo N, Bernardo M, Junqué C. Inferior frontal and insular cortical thinning is related to dysfunctional brain activation/deactivation during working memory task in schizophrenic patients. *Psychiatry Res* 2013; **214**: 94-101 [PMID: 23993992]
- 10 **He Z**, Deng W, Li M, Chen Z, Jiang L, Wang Q, Huang C, Collier DA, Gong Q, Ma X, Zhang N, Li T. Aberrant intrinsic brain activity and cognitive deficit in first-episode treatment-naïve patients with schizophrenia. *Psychol Med* 2013; **43**: 769-780 [PMID: 22883428 DOI: 10.1017/S0033291712001638]
- 11 **Stephan KE**, Friston KJ, Frith CD. Dysconnection in schizophrenia: from abnormal synaptic plasticity to failures of self-monitoring. *Schizophr Bull* 2009; **35**: 509-527 [PMID: 19155345 DOI: 10.1093/schbul/sbn176]
- 12 **Altamura AC**, Serati M, Buoli M. Is duration of illness really influencing outcome in major psychoses? *Nord J Psychiatry* 2015; **69**: 403-417 [PMID: 25768662 DOI: 10.3109/08039488.2014.990919]
- 13 **Kay SR**, Opler LA, Lindenmayer JP. The Positive and Negative Syndrome Scale (PANSS): rationale and standardisation. *Br J Psychiatry Suppl* 1989; **155** (Suppl 7): 59-67 [PMID: 2619982]
- 14 **Flemenbaum A**, Zimmermann RL. Inter- and intra-rater reliability of the Brief Psychiatric Rating Scale. *Psychol Rep* 1973; **32**: 783-792 [PMID: 4704758]
- 15 **Stefanopoulou E**, Manoharan A, Landau S, Geddes JR, Goodwin G, Frangou S. Cognitive functioning in patients with affective disorders and schizophrenia: a meta-analysis. *Int Rev Psychiatry* 2009; **21**: 336-356 [PMID: 20374148 DOI: 10.1080/09540260902962149]
- 16 **Kay SR**. Schizophrenic WAIS pattern by diagnostic subtypes. *Percept Mot Skills* 1979; **48**: 1241-1242 [PMID: 492898 DOI: 10.2466/pms.1979.48.3c.1241]
- 17 **Leeson VC**, Barnes TR, Harrison M, Matheson E, Harrison I, Mutsatsa SH, Ron MA, Joyce EM. The relationship between IQ, memory, executive function, and processing speed in recent-onset psychosis: 1-year stability and clinical outcome. *Schizophr Bull* 2010; **36**: 400-409 [PMID: 18682375 DOI: 10.1093/schbul/sbn100]
- 18 **Fitzgerald D**, Lucas S, Redoblado MA, Winter V, Brennan J, Anderson J, Harris A. Cognitive functioning in young people with first episode psychosis: relationship to diagnosis and clinical characteristics. *Aust N Z J Psychiatry* 2004; **38**: 501-510 [PMID: 15255822 DOI: 10.1111/j.1440-1614.2004.01403.x]
- 19 **Fatouros-Bergman H**, Cervenka S, Flyckt L, Edman G, Farde L. Meta-analysis of cognitive performance in drug-naïve patients with schizophrenia. *Schizophr Res* 2014; **158**: 156-162 [PMID: 25086658 DOI: 10.1016/j.schres.2014.06.034]
- 20 **Bartholomeusz CF**, Cropley VL, Wannan C, Di Biase M, McGorry PD, Pantelis C. Structural neuroimaging across early-stage psychosis: Aberrations in neurobiological trajectories and implications for the staging model. *Aust N Z J Psychiatry* 2017; **51**: 455-476 [PMID: 27733710 DOI: 10.1177/0004867416670522]
- 21 **Yildiz M**, Borgwardt SJ, Berger GE. Parietal lobes in schizophrenia: do they matter? *Schizophr Res Treatment* 2011; **2011**: 581686 [PMID: 22937268 DOI: 10.1155/2011/581686]
- 22 **Minatogawa-Chang TM**, Schaufelberger MS, Ayres AM, Duran FL, Gutt EK, Murray RM, Rushe TM, McGuire PK, Menezes PR, Sczufca M, Busatto GF. Cognitive performance is related to cortical grey matter volumes in early stages of schizophrenia: a population-based study of first-episode psychosis. *Schizophr Res* 2009; **113**: 200-209 [PMID: 19616413 DOI: 10.1016/j.schres.2009.06.020]
- 23 **Rund BR**. Is schizophrenia a neurodegenerative disorder? *Nord J Psychiatry* 2009; **63**: 196-201 [PMID: 19235629 DOI: 10.1080/08039480902767286]
- 24 **Olabi B**, Ellison-Wright I, McIntosh AM, Wood SJ, Bullmore E, Lawrie SM. Are there progressive brain changes in schizophrenia? A meta-analysis of structural magnetic resonance imaging studies. *Biol Psychiatry* 2011; **70**: 88-96 [PMID: 21457946 DOI: 10.1016/j.biopsych.2011.01.032]
- 25 **Hulshoff Pol HE**, Kahn RS. What happens after the first episode? A review of progressive brain changes in chronically ill patients with schizophrenia. *Schizophr Bull* 2008; **34**: 354-366 [PMID: 18283048 DOI: 10.1093/schbul/sbm168]
- 26 **Torres US**, Duran FL, Schaufelberger MS, Crippa JA, Louzã MR, Sallet PC, Kanegusuku CY, Elkis H, Gattaz WF, Bassitt DP, Zuardi AW, Hallak JE, Leite CC, Castro CC, Santos AC, Murray RM, Busatto GF. Patterns of regional gray matter loss at different stages of schizophrenia: A multisite, cross-sectional VBM study in first-episode and chronic illness. *Neuroimage Clin* 2016; **12**: 1-15 [PMID: 27354958 DOI: 10.1016/j.nicl.2016.06.002]
- 27 **Buoli M**, Caldiroli A, Panza G, Altamura AC. Prominent clinical dimension, duration of illness and treatment response in schizophrenia: a naturalistic study. *Psychiatry Investig* 2012; **9**: 354-360 [PMID: 23251199 DOI: 10.4306/pi.2012.9.4.354]
- 28 **van Haren NE**, Hulshoff Pol HE, Schnack HG, Cahn W, Mandl RC, Collins DL, Evans AC, Kahn RS. Focal gray matter changes in schizophrenia across the course of the illness: a 5-year follow-up study. *Neuropsychopharmacology* 2007; **32**: 2057-2066 [PMID: 17327887 DOI: 10.1038/sj.npp.1301347]
- 29 **Ozcelik-Eroglu E**, Ertugrul A, Oguz KK, Has AC, Karahan S, Yazici MK. Effect of clozapine on white matter integrity in patients with schizophrenia: a diffusion tensor imaging study. *Psychiatry Res* 2014; **223**: 226-235 [PMID: 25012780 DOI: 10.1016/j.psychres.2014.06.034]
- 30 **Zanello A**, Curtis L, Badan Bâ M, Merlo MC. Working memory impairments in first-episode psychosis and chronic schizophrenia. *Psychiatry Res* 2009; **165**: 10-18 [PMID: 19046607 DOI: 10.1016/j.psychres.2007.10.006]
- 31 **Braw Y**, Bloch Y, Mendelovich S, Ratzoni G, Gal G, Harari H, Tripto A, Levkovitz Y. Cognition in young schizophrenia outpatients: comparison of first-episode with multiepisode patients. *Schizophr Bull* 2008; **34**: 544-554 [PMID: 17984299 DOI: 10.1093/schbul/sbm115]

**P- Reviewer:** Belli H, Kravos M **S- Editor:** Ji FF **L- Editor:** A  
**E- Editor:** Li D





Published by **Baishideng Publishing Group Inc**  
7901 Stoneridge Drive, Suite 501, Pleasanton, CA 94588, USA  
Telephone: +1-925-223-8242  
Fax: +1-925-223-8243  
E-mail: [bpgoffice@wjgnet.com](mailto:bpgoffice@wjgnet.com)  
Help Desk: <http://www.f6publishing.com/helpdesk>  
<http://www.wjgnet.com>

