

Is This Melanoma? A Quiz

Stefano VERALDI, Paolo PONTINI, Francesco SALA and Diego TOSI

Department of Pathophysiology and Transplantation, Università degli Studi di Milano, IRCCS Foundation, Cà Granda Ospedale Maggiore Policlinico, via Pace n.9, IT-20122 Milan, Italy. E-mail: stefano.veraldi@unimi.it

A 46-year-old man was referred to our department by his general practitioner with a clinical diagnosis of melanoma on the fifth left toe. The patient reported that he was in good general health and not on any systemic drug therapy. The slightly painful lesion had appeared approximately 6 weeks earlier, during a trip to Fortaleza (Brazil).

Dermatological examination revealed a pigmented, slightly infiltrated lesion, approximately oval in shape, 0.8 × 0.5 cm, brownish-black in colour, with poorly defined

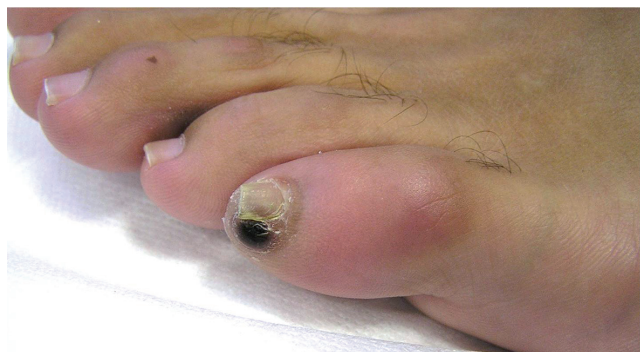

Fig. 1. Pigmented, slightly infiltrated lesion, oval in shape, brownish-black in colour, with poorly defined borders.

borders (**Fig. 1**). Dermoscopy of the lesion is shown in **Fig. 2**.

What is your diagnosis? See next page for answer.

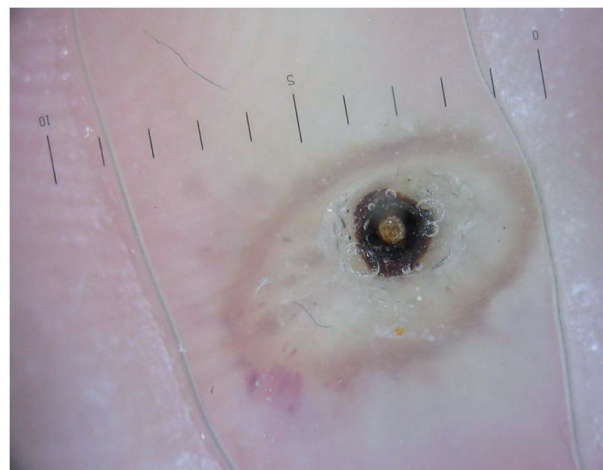


Fig. 2. Grey-yellowish round lesion with a central black pore corresponding to the posterior portion of the abdomen of the flea. A haemorrhagic ring surrounds the whole lesion.

ANSWERS TO QUIZ

Is This Melanoma? A Commentary

Acta Derm Venereol 2017; 97: 868–869.

Diagnosis: Tungiasis

Tungiasis is an infestation caused by penetration into the skin by the gravid female of the flea *Tunga penetrans* Linnaeus 1758 (Insecta, Siphonaptera: Tungidae). Tungiasis is characterized clinically by one or more papular or nodular lesions, grey or yellowish in colour, with a small central brown-black opening corresponding to the posterior portion of the abdomen of the flea. It is usually located on the feet (toes, peri- and subungual folds, interdigital folds, sole and heel). Diagnosis is usually easy. However, less common clinical varieties of tungiasis have been described: plantar wart-like lesions, as well as crusted, bullous, pustular and ulcerative lesions (1).

Dermoscopy is useful in the diagnosis of infections and infestations of the skin (2, 3), including tungiasis (2–14). The dermoscopic picture of tungiasis is characterized by a whitish to light brown nodule, with a peripheral pigmented ring surrounding a black central pore, corresponding to the posterior portion of the abdomen of the flea (2–4, 7, 10, 12, 13). In addition, grey-blue blotches (2, 3, 6, 10) and whitish oval structures linked together to form chain-like structures

(“whitish chains”) (3, 9) may be seen, corresponding to the eggs in the abdomen of the flea. Clusters of eggs may also be observed as jelly-like bags (3, 7, 13). Furthermore, a “radial crown” has been described (10).

The lesion was removed successfully by curettage (Fig. 3). Parts of the body of the flea and some eggs were observed. A 3-month follow-up was negative.

REFERENCES

1. Veraldi S, Valsecchi M. Imported tungiasis: a report of 19 cases and review of the literature. *Int J Dermatol* 2007; 46: 1061–1066.
2. Zalaudek I, Giacomel J, Cabo H, Di Stefani A, Ferrara G, Hofmann-Wellenhof R, Malvey J, Puig S, Stolz W, Argenziano G. Entodermoscopy: a new tool for diagnosing skin infections and infestations. *Dermatology* 2008; 216: 14–23.
3. Lacarrubba F, Verzi AE, Dinotta F, Scavo S, Micali G. Dermatoscopy in inflammatory and infectious skin disorders. *G Ital Dermatol Venereol* 2015; 150: 521–531.
4. Bauer J, Forschner A, Garbe C, Röcken M. Dermoscopy of tungiasis. *Arch Dermatol* 2004; 140: 761–763.
5. Bauer J, Forschner A, Garbe C, Röcken M. Variability of dermoscopic features of tungiasis. *Arch Dermatol* 2005; 141: 643–644.
6. Di Stefani A, Rudolph CM, Hofmann-Wellenhof R, Müllegger RR. An additional dermoscopic feature of tungiasis. *Arch Dermatol* 2005; 141: 1045–1046.
7. Cabrera R, Daza F. Tungiasis: eggs seen with dermoscopy. *Br J Dermatol* 2008; 158: 635–636.
8. Gibbs SS. The diagnosis and treatment of tungiasis. *Br J Dermatol* 2008; 159: 981.
9. Bakos RM, Bakos L. ‘Whitish chains’: a remarkable in vivo dermoscopic finding of tungiasis. *Br J Dermatol* 2008; 159: 991–992.
10. Marazza G, Campanelli A, Kaya G, Braun RP, Saurat JH, Piguet V. *Tunga penetrans*: description of a new dermoscopic sign – the radial crown. *Arch Dermatol* 2009; 145: 348–349.
11. Cabrera R, Daza F. Dermoscopy in the diagnosis of tungiasis. *Br J Dermatol* 2009; 160: 1136–1137.
12. Yotsu RR, Tamaki T, Ujiie M, Takeshita N, Kanagawa S, Kudo K, Hayashi T. Imported tungiasis in a Japanese student returning from East Africa. *J Dermatol* 2011; 38: 185–189.
13. Dunn R, Asher R, Bowling J. Dermoscopy: ex vivo visualization of fleas head and bag of eggs confirms the diagnosis of tungiasis. *Australas J Dermatol* 2012; 53: 120–122.
14. Maco V, Maco VP, Tantalean ME, Gotuzzo E. Histopathological features of tungiasis in Peru. *Am J Trop Med Hyg* 2013; 88: 1212–1216.

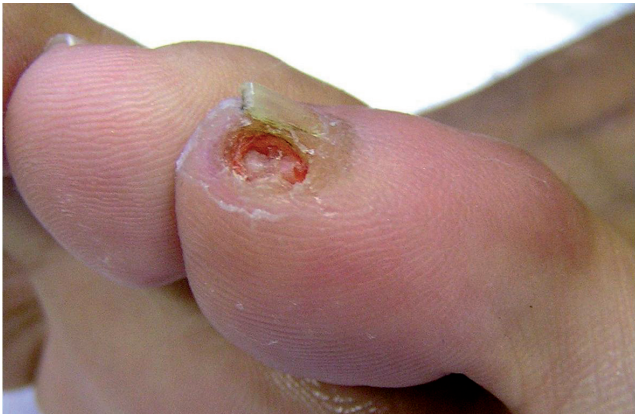

Fig. 3. The lesion was successfully removed by curettage.