

OCCUPATIONAL ASTHMA CAUSED BY COBALT CHLORIDE IN A DIAMOND POLISHER AFTER CESSATION OF OCCUPATIONAL EXPOSURE: A CASE REPORT

ANNA KRAKOWIAK¹, WOJCIECH DUDEK¹, MACIEJ TARKOWSKI², SYLWIA ŚWIDERSKA-KIĘLBIK¹, EWA NIEŚCIERENKO³, and CEZARY PAŁCZYŃSKI¹

¹ Department of Occupational Diseases
Center of Occupational and Environmental Allergy

² Department of Immunotoxicology
Nofer Institute of Occupational Medicine
Łódź, Poland

³ Mazowiecki Occupational Medical Center
Płock, Poland

Abstract

Objectives: The inspiration of cobalt containing dust leads to various respiratory symptoms, including asthma and interstitial lung disease. Occupational asthma caused by cobalt chloride has been diagnosed in a 35-year-old patient, who worked as a diamond polishing disc former. The patient presented a 2-year history of dyspnea, cough and symptoms of rhinitis.

Materials and Methods: The patient underwent a medical history interview, skin prick tests with common and occupational allergens (cobalt and nickel chloride), and pulmonary function testing both before and after the nasal provocation with 0.05% cobalt chloride. Additionally, the authors analyzed morphological and biochemical changes before and after the specific nasal challenge test. Cell proliferation analysis was also carried out. **Results:** Skin prick tests (SPTs) with common environmental allergens were found to be negative, while SPTs with cobalt chloride were positive for all applied solutions. The provocation with cobalt chloride caused a significant increase in the proportion of eosinophils, basophils and albumin during the late allergic reaction. The positive lymphocyte transformation caused by cobalt was also observed. **Conclusions:** Cobalt salts may induce occupational asthma. The mechanism of this asthma may be IgE-mediated. The cobalt-sensitized lymphocytes may play an important role in this disease.

Key words:

Cobalt, Nasal washings, Lymphocyte proliferation

INTRODUCTION

Cobalt is a hard magnetic metal that is commonly used as a binder in cemented tungsten carbide, in the glass, printing, ceramic and photographic industries. Cobalt compounds are used as pigments, animal feed additives and foam sta-

bilizers [1,2]. Professions, in which cobalt-related respiratory diseases occur include diamond polishing, porcelain painting, tungsten carbide manufacturing and cobalt extraction. The inspiration of dust containing cobalt leads to various respiratory symptoms, including irritation of the

Received: February 28, 2005. Accepted: May 2, 2005.

Address reprint requests to A. Krakowiak MD, Department of Occupational Diseases, Nofer Institute of Occupational Medicine, św. Teresy 8, 91-348 Łódź, Poland (e-mail: annakrak@imp.lodz.pl).

upper respiratory tract, asthma, and a form of interstitial lung disease called "hard metal lung" [3,4]. This report details the initial and follow-up laboratory examinations of cobalt-induced occupational asthma with special reference to cobalt-induced changes in nasal washings and in lymphocyte proliferation.

The results of several studies on the course of occupational asthma show that ventilation disorders, airway obstruction, and clinical symptoms may persist after cessation of exposure [1,5,6]. In this article, the authors present a case of cobalt asthma with the progression of clinical state after leaving the occupational exposure.

Case history

A 35-year-old man with a 2-year history of cough and dyspnea was admitted to the Department of Occupational Diseases, the Nofer Institute of Occupational Medicine in September 2000. He was a diamond polishing disc former. He had been working in hard metal industry since 1990 and had to quit his job 8 months ago because of respiratory disorders. His job comprised polishing of discs out of forms and clearing the form and the disc. He suffered from wheezing, shortness of breath and rhinitis, but could not precisely describe the onset of these symptoms. He used to smoke, but quit smoking in 1999 due to his disease. The patient had no history of asthma or allergic disorders in his family. Because of his symptoms he was first admitted to the local hospital ward of internal diseases in January 2000, where he was attended by a general practitioner (GP), and treated with salmeterol xinafoate, salbutamol sulphate, and a combination of fenoterol hydrobromide with ipratropium bromide.

On his first admission to the Department of Occupational Diseases (September 2000), the patient presented symptoms of dyspnea with wheezing. The chest was asymmetric, due to lateral spinal curvature. The heart rate was 100 per min.

Informed consent had been provided by the worker before the challenge studies with cobalt chloride salts were performed.

MATERIALS AND METHODS

Laboratory tests

The subject underwent a medical history, physical examination and pulmonary function testing by means of spirometry.

Skin prick tests (SPTs) with a battery of the most common allergens (commercial set of Allergopharma, Germany) including: *Dermatophagoides pteronyssinus*, *Dermatophagoides farinae*, grass and trees I (alder, hazel, poplar, elm, willow) and II (birch, beech, oak, plane), moulds I (*Alternaria tenuis*, *Botrytis cinerea*, *Cladosporium herbarum*, *Culvularia lunata*, *Helminthosporium*) and II (*Aspergillus fumigatus*, *Mucor mucedo*, *Penicillium notatum*, *Pullularia pullulans*, *Rhizopus nigricans*, *Serpula lacrymans*), feathers and cobalt chloride (prick-by-prick) [4], and nickel chloride (prick-by-prick) suspended in physiological saline solution at concentrations of 0.01%, 0.1% and 1% (the authors' own method).

The negative control was allergen diluent and the positive one – histamine dihydrochloride solution at 1mg/ml. All tested sites were examined after 20 min and then after 24 h respectively: a wheal of 3 mm larger than negative control was considered positive.

Total serum IgE level and the presence of specific IgE (RAST) for such common allergens as *D. pteronyssinus* and house dust mite were evaluated (Pharmacia, Sweden).

Total and differential white blood cell counts (WBCs) were determined before and every time after the nasal provocation with 0.05% solution with cobalt chloride.

Nasal provocation test

In the first stage – the nasal provocation with placebo – phosphate-buffered saline solution (PBS) was performed, and after 3 days the nasal provocation was carried out with 0.05% cobalt chloride in PBS (the authors' own method).

Nasal lavage procedure

The subject underwent nasal lavage before the provocation and then 30 min, 4 and 24 h after the challenge with 0.05% solution of cobalt chloride.

Before the provocation each nostril was washed 10 times with 6 ml of saline using a 5 ml syringe closely fitting the nostril. Nasal washings were collected as mentioned above (before the provocation and then 30 min, 4 and 24 h after the provocation). All washings were always performed on the same side of the nasal cavity.

Centrifugation (10 min at 1000 rpm) of the nasal washings was performed to isolate the cell pellet and the supernatant. The obtained sediment was washed with sterile phosphate-buffered saline (Dulbecco, Sigma, USA) and 0.1% human serum albumin (HSA, Behringwerke A.G., Germany) and then suspended in 1 ml buffer with HSA. Subsequently, the cells were stained using: (a) the Turk method for leukocytes, (b) the Dunger method for eosinophils, and (c) 0.06% toluidine blue in 30% ethanol for basophils (metachromatic cells). The cells were counted in a Fuchs-Rosenthal chamber. The number of cells in 1 ml of the recovered fluid was determined.

The samples were further centrifuged at 2000 rpm for 5 min, transferred onto a slide, and air-dried. The slides were stained following the Giemsa method. The differential cell count was performed on 200 cells/slide.

The supernatant total protein content was evaluated with the Lowry method [7].

Albumin concentration was measured using the "rocket" method of Laurell [8] (the assay ranged between 20 and 200 µg/ml). The permeability index, i.e. the albumin to total protein ratio was calculated.

Bronchoscopy and bronchoalveolar lavage procedure

One bronchoscopy with bronchoalveolar lavage (BAL) was performed before the provocation. Bronchoscopy after the nasal provocation with cobalt chloride was not performed due to decrease in spirometric parameters after the challenge that persisted until 24 h after the provocation.

Premedications included intramuscular atropine sulfate (1 mg) and diazepam (10 mg). Minimal quantities of 4% lidocaine were used for the airway anesthesia. A fiberoptic bronchoscope (BF 1T30; Olympus Corporation of Japan) was wedged in the lateral segment of the middle lobe and 140 ml of sterile warmed 0.9% NaCl were inserted in 20

ml portions and aspirated with about a 70% recovery, and then collected into a sterile siliconized glass vessel. The cytological smears were made from the bronchoalveolar lavage fluid (BALF) cellular sediment with trypan blue (evaluation of cells number and viability). The lavage fluid was centrifuged at 1400 g for 1 min, then concentrations of albumin, total protein and the permeability index, i.e. the albumin to total protein ratio were calculated. A cell count was performed using a Burkner chamber. Cell staining was carried out by the Papanheim method. Differential cell counts were expressed in percentages.

Pulmonary function and histamine challenge testing

The whole nasal challenge time was 15 min. The positive response was defined as at least 20% fall in forced expiratory volume in one second (FEV₁) from the baseline. Bronchial response was measured by monitoring of FEV₁ before, and then 5 min, 5 and 24 h after the provocation (Vicatet 2A, Mijnhardt, Holland).

Histamine challenge testing was evaluated according to Cockcroft et al. [9] before the provocation.

Other evaluations included: blood laboratory tests, SPTs with cobalt chloride, spirometry and chest radiograph during the next three hospitalizations in the Department of Occupational Diseases (twice in December 2002; one in March 2003).

Cell proliferation assay

Peripheral blood mononuclear cells (PBMCs) were isolated by centrifugation at 400 g, 21°C for 30 min on the gradient of Histopaque (1.077 g/ml). Cells were suspended at the concentration of 2 million cells per 1 ml of culture medium (RPMI 1640, 10% FCS, streptomycin, gentamycin, penicillin, 2 mM L-glutamine).

Cells were transferred to 24 well plates, and each well consisted of 2 million cells in 1 ml. Cells were set up in the wells to include 3 different concentrations of the antigen, the negative control (cells in culture medium) and the positive control (mitogen stimulated). PBMCs were cultured for total of 10 days.

Cell proliferation analyses were carried out using the manufacturer's kit (Roche) and according to its protocol

with a slight modification. The modification that we have introduced concerned the use of relatively larger amounts of reagents per well, since we utilized a higher number of cells and volume of the medium in cell culture. The test was based on the incorporation of bromo-deoxyuridine into DNA of proliferating cells. The BrdU was added 18 h before the completion of the test and detected by anti-BrdU antibodies conjugated with horseradish peroxidase. The final results of the developing color reaction was measured on a spectrophotometer (Bio-Rad).

RESULTS

On admission, the patient's lung function parameters (before the nasal provocation with cobalt chloride) were: FVC – 5.08 (82%) and FEV₁ – 3.15 (63%). DLCO measured during the first hospitalization was within the normal range.

Blood laboratory findings were within the normal range, MCV and MCH were slightly increased. The following parameters were found to be normal: glucose, cholesterol, urea, clotting parameters, creatinine, transaminases, bilirubine and triglycerides.

The authors did not find any abnormalities in the chest radiograph and computerized tomography (CT) scans. USG of the abdomen was normal, except for slightly enlarged liver.

Total IgE level was 176 kU/l, therefore the patient was considered to be atopic. SPTs with a battery of the most common allergens were found to be negative. No specific IgE to *D. pteronyssinus* and to house dust mite were found.

The results of SPTs with cobalt chloride appeared to be positive for all applied solutions, while SPTs with nickel chloride were negative.

Cellular and biochemical findings in nasal lavage after the specific challenge test

Allergen challenge caused an increase in the proportion of eosinophils after 4 and 24 h and in the proportion of basophils after 24 h, but no changes were observed in the proportion of neutrophils (Fig. 1).

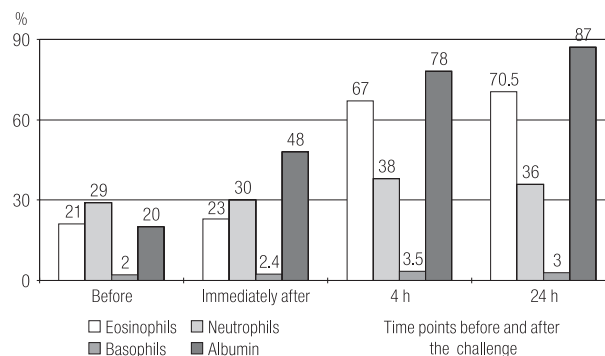


Fig. 1. The proportion of cells and the level of albumin in nasal lavage fluid before and after the specific challenge test (cobalt chloride).

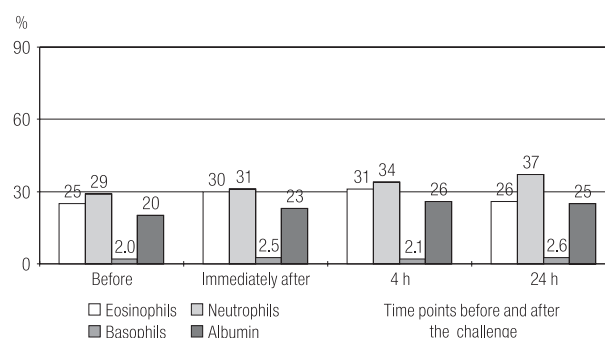


Fig. 2. The proportion of cells and the level of albumin in nasal lavage fluid before and after the placebo challenge.

The specific challenge induced the increase in the percentage of albumin (the mucosal/ascular permeability index) only after 24 h (Fig. 1).

No changes in the morphological and biochemical findings were observed at any time after the challenge with placebo (Fig. 2).

Cellular populations in BALF before the specific challenge test are presented in Table 1. We were not able to perform bronchoscopy after the nasal challenge with cobalt chloride due to the clinical state of the patient.

Table 1. Cellular and biochemical findings in bronchoalveolar lavage fluid before the nasal challenge with cobalt chloride.

Cells	Before the nasal challenge with cobalt chloride (%)
Macrophages	78.5
Monocytes	6.5
Neutrophils	1.9
Eosinophils	6.5
Lymphocytes	5.6
Basophils	1.0
Albumin	6.5

Pulmonary function and airway hyperreactivity

The results of spirometric parameters during the patient's hospitalizations are presented in Table 2.

Allergen provocation caused a decrease in FEV₁ and peak respiratory flow (PEF) during the late allergic reaction (Figs. 3 and 4). No significant changes in FEV₁ and PEF were noticed after the challenge with placebo (Figs. 3 and 4).

Histamine specific inhalatory challenge test was performed only before the specific nasal provocation (PC₂₀–3.8 mg/ml). We were not able to perform this test after the

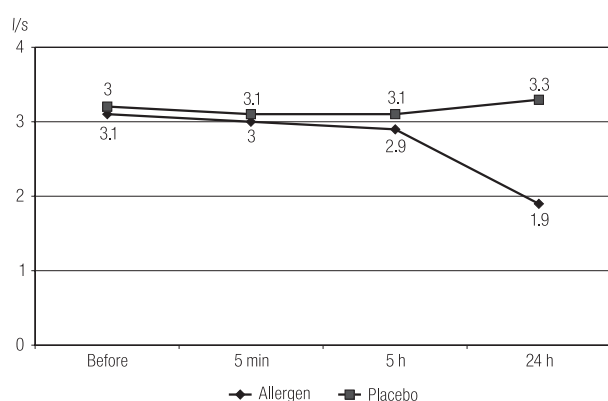


Fig. 3. FEV₁ changes before and after the nasal challenge with cobalt chloride and placebo.

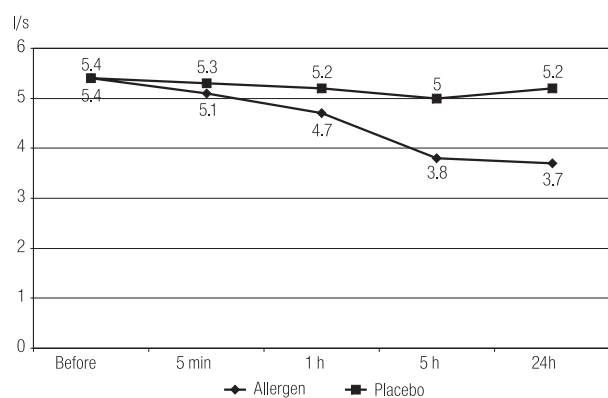


Fig. 4. PEF changes before and after the nasal challenge with cobalt chloride and placebo.

Table 2. Pulmonary function tests – a follow up study

Number	N1			N2			N3			N4		
	A	P	%P	A	P	%P	A	P	%P	A	P	%P
FVC (L)	5.08	6.15	82	4.98	6.15	80	4.99	6.15	94	5.70	6.15	93
FEV ₁ (L/s)	3.15	5.01	63	3.10	5.01	61	3.0	5.01	59	2.98	5.01	59

A – actual; P – predicted; N1 – the first hospitalization in the Department of Occupational Diseases; N2 – the second hospitalization; N3 – the third hospitalization; N4 – the fourth hospitalization.

Table 3. Follow-up results – current medication and PC₂₀

	Avoidance of occupational exposure	Follow-up period (months)	Histamine PC ₂₀	Current medication
Patient	Yes	12	3.2	Bronchodilator + oral and inhaled corticosteroids
Patient	Yes	14	(-)	
Patient	Yes	24	(-)	

(-) – Not done, because of the patient's clinical state.

provocation with cobalt chloride due to the clinical state of the patient.

We were also able to perform the histamine specific inhalatory challenge test during the second hospitalization (PC₂₀ 3.2 mg/ml) (Table 3).

When seen on the next hospitalization in the Department, the patient was still breathless, his condition had worsened considerably with dyspnea at the lightest effort and even at rest. Pulmonary function tests revealed the significant decrease in FEV₁ (Table 2).

The patient's airway hyperresponsiveness worsened despite complete avoidance of cobalt chloride exposure and continuous administration of anti-asthmatic medication.

Laboratory data showed normal hematologic parameters, and the chest radiographs did not show progressive changes compared with those on the first radiograph.

On the patient's first examination in our Department corticosteroid treatment was initiated in a dose of 32 mg. The dose was tapered to 8 mg on his discharge.

He was advised to discontinue exposure to cobalt chloride and to take anti-asthma medication.

Cell proliferation assay

The results are presented as a relative increase in proliferation above the control which constituted cells sus-

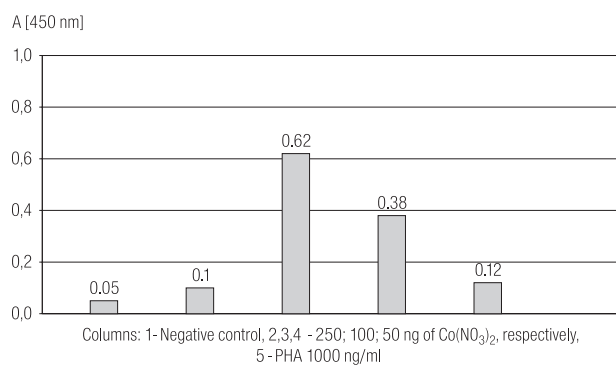


Fig. 5. Proliferation of PBMCs in response to cobalt.

pendent in culture media only. The response was dose-dependent and reached an optimum at 100 ng/ml of $\text{Co}(\text{NO}_3)_2$ (Fig. 5).

DISCUSSION

Cobalt has been regarded as an agent responsible for the development of asthmatic reactions in workers exposed to hard metal dust [1,2,4]. The known ability of cobalt to sensitize the respiratory tract is still discussed. Occupational asthma in hard metal workers is characterized by wheezing, cough and shortness of breath. In the majority of subjects with diagnosed occupational asthma induced by cobalt, the asthmatic response develops during the late reaction.

The appearance of late allergic reaction observed in our study after the nasal provocation with cobalt chloride is compatible with that found in the cases with occupational asthma induced by low-molecular weight substances.

The clinical symptoms and work history of our patient suggested that he was suffering from asthma with hypersensitivity to cobalt. The diagnosis was based on the following clinical findings: SPTs results, the positive bronchial response to the nasal challenge testing with cobalt chloride and the absence of abnormalities in x-ray films and CT scans.

Our patient was considered to be atopic. Atopy is a well documented risk factor for the development of occupational allergy due to high-molecular weight allergens such as flour, laboratory animal allergens and some low-molecular weight substances (e.g., nickel salts and trimellitic anhydride) [10–13]. We did not perform the patch test with

cobalt salts, as in our opinion this test is not a valuable method for the diagnosis of occupational asthma [2,14].

Typically, the nasal allergen challenge induces a prolonged increase in the number of eosinophils and basophils and in the albumin/protein ratio [15,16]. In the present study we also observed similar morphological and biochemical changes after the nasal challenge with cobalt chloride.

We did not find significant changes in the percentage of neutrophils after the nasal challenge with cobalt chloride either in the early or in the late allergic reactions. Other studies have described an increase in neutrophil chemotactic activity associated with activation of these cells during asthmatic reactions provoked by diisocyanates [17,18].

The result of BALF performed in our patient was normal before the nasal challenge with cobalt chloride. We assume, however, that these cells should have accumulated in the respiratory tract after the specific challenge test, like in the nasal lavage, as we believe that the ongoing inflammation in the nose reflect the same process in the lower part of the respiratory tract. Because of the clinical state of the patient, we were not able to perform bronchoscopy with BAL after the nasal provocation with cobalt chloride and during the next hospitalization in our Department.

One could expect that after cessation of occupational exposure to the particular sensitizing agent, the patient should have recovered. Unfortunately such a course of the disease can be observed only in a few cases of occupational asthma [19]. Some patients show persistent asthma even after total removal from occupational exposure, whereas others recover completely with normalization of their nonspecific bronchial reactivity. We noticed the increased bronchial hyperreactivity to histamine in the patient also during his second hospitalization in our Department. This is also likely to be due to persistent immunologic sensitization to the occupational agent, which was proved by positive SPTs with cobalt chloride during the second hospitalization.

In addition, we noticed the positive lymphocyte transformation to cobalt, thus suggesting the immunological mechanism of bronchial asthma caused by this low-molecular weight allergen.

The clinical state of our patient at first examination differed from that at re-examinations. His condition had worsened considerably with dyspnea at the lightest effort and even at rest. The use of oral corticosteroids was increased from 32 mg during the first examination per day to 48 mg during the last hospitalization in the Department. Also a daily dose of beta agonists was increased from 4.12 puffs per day during the first hospitalization to 6.78 puffs per day on average during the last hospitalization.

CONCLUSIONS

Although numerous reports on immunoallergic origin of cobalt sensitivity have been published, it seems that the mechanism by which this agent induces bronchial asthma is still unknown. Morphological and biochemical changes in the nasal washings after the nasal challenge resemble the features of IgE-mediated allergic inflammation, especially the influx of eosinophils and subsequent increase in mucosal permeability. However, several features revealed in the present study, especially in nasal washings following the provocation with cobalt chloride, differ from those seen after the provocation with high-molecular weight allergens. The main difference applies to the kinetics of changes. Significant changes in nasal washings could be detected 4 h after the cobalt chloride provocation that accompanied bronchoconstriction which peaked 24 h later. In comparison with high-molecular weight allergens, these changes are observed earlier, during the immediate response.

REFERENCES

1. Davidson AG, Haslam PL, Corrin B, Coutts II, Dewar A, Riding WD, et al. *Interstitial lung disease and asthma in hard-metal workers: bronchoalveolar lavage, ultrastructural and analytical findings and results of bronchial provocation tests*. *Thorax* 1983;38:119–28.
2. Wittczak T, Dudek W, Pałczyński C. *Lung disease of the proven or suspected immunological etiology induced by occupational exposure to metals*. In: Pałczyński C, editor. *Occupational Allergy in Health Service Workers*. Łódź: Nofer Institute of Occupational Medicine; 2002. p.187–212 [in Polish].
3. Lison D, Lauerys R, Demedts M, Nemery B. *Experimental research into the pathogenesis of cobalt/hard metal lung disease*. *Eur Respir J* 1996;9:1024–8.
4. Wittczak T, Walusia J, Krakowiak A, Pałczyński C. *Occupational asthma and interstitial cobalt-induced changes in a dental technician: A case report*. *Meda Pr* 2003;54(2):159–64 [in Polish].
5. Demedts M, Gheysens B, Nagels J, Verbeke E, Lauweryns J, van den Eeckhout A, et al. *Cobalt lung in diamond polishers*. *Am Rev Respir Dis* 1984;130(1):130–5.
6. Górski P, Kołacińska B, Wittczak T. *Analysis of the clinical state of patients with occupational asthma following cessation of exposure to allergens*. *Occup Med* 1999;49(5):285–9.
7. Lowry OL, Rosebrough MJ, Farr AL, Randall RJ. *Protein measurement with the folin-phenol reagent*. *J Biol Chem* 1951;193:265–75.
8. Laurell CB. *Antigen-antibody crossed electrophoresis*. *Anal Biochem* 1966;15:45–55.
9. Cockcroft DW, Killian DN, Mellon JJ, Hargreave FE. *Bronchial reactivity to histamine: a method and clinical survey*. *Clin Allergy* 1977;7:235–43.
10. Walusiak J, Hanke W, Górski P, Pałczyński C. *Respiratory allergy in apprentice bakers: do occupational allergies follow up the allergic march?* *Allergy* 2004;59:442–50.
11. Krakowiak A, Pałczyński C. *Occupational allergy to allergens of animal origin*. In: Pałczyński C, editor. *Occupational Allergy in Health Service Workers*. Łódź: Nofer Institute of Occupational Medicine; 2002. p.155–66 [in Polish].
12. Estlander T, Kanerva L, Tupasela O, Keskinen H, Jolanki R. *Immediate and delayed allergy to nickel with contact urticaria, rhinitis and asthma and contact dermatitis*. *Clin Exp Allergy* 1993;23 (4):306–10.
13. Drexler H, Weber A, Letzel S. *Detection and clinical relevance of a type I allergy with occupational exposure to hexahydrophthalic anhydride and methyltetrahydrophthalic anhydride*. *Int Arch Occup Environ Health* 1994;65(5):279–83.
14. Pałczyński C, Walusiak J, Wittczak T, Krakowiak A, Górski P. *Occupational Asthma: Recommendations for Prophylactic Examinations of Persons Occupationally Exposed to High-molecular Weight Allergens*. Łódź: Nofer Institute of Occupational Medicine; 2001 [in Polish].
15. Sastre J, Vandenplas O, Park HS. *Pathogenesis of occupational asthma*. *Eur Respir J* 2003;22:364–73.
16. Walusiak J, Wiszniewska M, Krawczyk-Adamus P, Pałczyński C. *Occupational allergy to wheat flour. Nasal response to specific inhalative challenge in asthma and rhinitis vs. isolated rhinitis: A comparative study*. *Int J Occup Med Environ Health* 2004;17(4):433–40.

17. Park HS, Jung KS, Kim HY, Nahm DH, Kang KR. *Neutrophil activation following TDI bronchial challenges to the airway secretion from subjects with TDI-induced asthma.* Clin Exp Allergy 1999;29:1395-401.
18. Lemiere C, Romeo P, Chaboillez S, Tremblay C, Malo JL. *Airway inflammation and functional changes after exposure to different concentrations of isocyanates.* J Allergy Clin Immunol 2002;110:641-6.
19. Lemiere C, Cartier A, Malo JL, Lehrer S. *Persistent specific bronchial reactivity to occupational agents in workers with normal nonspecific bronchial reactivity.* Am J Respir Crit Care Med 2000;62:976-80.