

No Untoward Effect of Long-Term Ketoconazole Administration on Electrocardiographic QT Interval in Patients with Cushing's Disease

Martina De Martin¹, Paola Maria Toja², Karine Goulene³, Piero Radaelli¹, Francesco Cavagnini¹, Marco Stramba-Badiale³ and Francesca Pecori Giraldi^{1,4}

¹Neuroendocrinology Research Laboratory, IRCCS Istituto Auxologico Italiano, Milan, Italy, ²Division of Endocrinology and Metabolic Diseases, IRCCS Istituto Auxologico Italiano, Milan, Italy, ³Department of Geriatrics and Cardiovascular Medicine, IRCCS Istituto Auxologico Italiano, Milan, Italy and ⁴Department of Clinical Sciences and Community Health, University of Milan, Milan, Italy

(Received 1 June 2015; Accepted 1 September 2015)

Abstract: Ketoconazole is listed among drugs that prolong QT interval and may increase the risk of torsade de pointes, a severe ventricular arrhythmia. This compound has recently been approved for treatment of Cushing's syndrome, a severe endocrine disorder. These patients harbour several risk factors for prolonged QT interval, for example hypokalaemia and left ventricular hypertrophy, but no study has evaluated whether administration of ketoconazole affects their QT interval. The aim of this study was to assess the QT interval in patients with Cushing's disease during long-term administration of ketoconazole. Electrocardiograms from 15 patients with Cushing's disease (12 women, 3 men, age: 37.8 ± 2.66 years) on ketoconazole treatment (100 mg–800 mg qd) for 1 month to 12 years were reviewed retrospectively. QT interval was measured and corrected for heart rate (QTc). Measurements before and during ketoconazole treatment were compared and any abnormal QTc value recorded. Concurrent medical therapies were also documented. On average, QTc was superimposable before and during ketoconazole treatment (393.2 ± 7.17 versus 403.3 ± 6.05 msec. in women; 424.3 ± 23.54 versus 398.0 ± 14.93 msec. in men, N.S.). QTc normalized on ketoconazole in one man with prolonged QTc prior to treatment; no abnormal QTc was observed in any other patient during the entire observation period, even during concurrent treatment with other QT-prolonging drugs. In conclusion, long-term ketoconazole administration does not appear to be associated with significant prolongation of QT interval in patients with Cushing's disease. ECG monitoring can follow recommendations drawn for other low-risk QT-prolonging drugs with attention to specific risk factors, for example hypokalaemia and drug interactions.

Prolongation of the electrocardiographic QT interval may be due to administration of drugs that are known to prolong ventricular repolarization, for example antiarrhythmic agents, as well as non-cardiac drugs [1]. In fact, the pro-arrhythmic potential of any new drug must be established prior to its use in clinical practice [2]. Iatrogenic QT interval prolongation predisposes to torsade de pointes, a severe ventricular arrhythmia which may resolve spontaneously or, if prolonged, lead to syncope and, possibly, cardiac arrest. Thus, drug-induced QT prolongation is closely monitored, and lists of drugs known to prolong QT interval are being continuously updated [3].

One such drug is ketoconazole, an imidazole derivative with potent inhibitory effects on several cytochromes, including the liver CYP3A4 enzyme. In fact, ketoconazole may interfere with hepatic metabolism [4], thus lengthening plasma half-life of known QT-prolonging drugs, for example antiarrhythmics, antihistamines, antidepressants and antibiotics, resulting in QT prolongation [5,6]. It is classified among low-risk QT-prolonging drugs, that is, may increase the risk of torsade de pointes if administered to patients at risk for QT interval prolongation [3]. Clinical evidence on this side effect was collected during the use of ketoconazole as an antifungal agent, usually at 50–

200 mg qd, for a few weeks at most. Ketoconazole as an antimycotic has since been withdrawn, but it remains one of the major drugs for Cushing's syndrome, a rare endocrine disorder characterized by considerable morbidity due to excess cortisol secretion. Ketoconazole inhibits adrenal steroidogenesis and is required in these patients to contain hypercortisolism prior to surgery, after unsuccessful surgery and/or while awaiting the effects of radiotherapy [7–9]; in this condition, ketoconazole is administered at higher doses, for example 200–1200 mg qd, and often for months or even years. After decades of off-label use [9,10], ketoconazole has been recently approved by the European Medical Agency for treatment of patients with Cushing's syndrome [11] and is likely to achieve a more widespread use.

We have recently observed a prolongation of the electrocardiographic QT interval in male patients with Cushing's syndrome [12]; thus, these patients may incur in additional risk of prolonged QT interval if administered ketoconazole. Safety of ketoconazole administration may become a primary issue, especially if other risk factors for QT interval prolongation, for example hypokalaemia and left ventricular hypertrophy, occur or additional QT-prolonging drugs are administered. However, no study has yet evaluated whether prolongation of QT interval occurs in patients with Cushing's syndrome during ketoconazole treatment. We therefore decided to analyse electrocardiographic readings in patients with Cushing's

Author for correspondence: Francesca Pecori Giraldi, University of Milan, Istituto Auxologico Italiano, Via Zucchi 18, 20095 CUSANO MILANINO (MI), Italy (fax +39-02-619113033, e-mail fpg@auxologico.it).

syndrome on ketoconazole in order to report on changes in QT interval.

Patients and Methods

Study population. Fifteen patients treated with ketoconazole for ACTH-dependent pituitary Cushing's syndrome, that is, Cushing's disease (12 women, three men; age: 37.8 ± 2.66 years; range: 23–59 years), were studied. Nine patients were hypertensive and three presented left ventricular hypertrophy as assessed by echocardiography. Ketoconazole was administered prior to surgery in five patients and after unsuccessful surgery or after relapse of hypercortisolism in 10 patients. Length of treatment with ketoconazole ranged from 1 month to 12 years, median 7 months; dosage was 100–800 mg/daily, median 600 mg/daily (table 1). Overall, analysis comprised 598 patient-months. Details of the three patients on long-term ketoconazole treatment were as follows: patients #3 and #12 had achieved partial control of hypercortisolism with radiotherapy after surgical failure and were unwilling to undergo adrenalectomy; patient #15 developed a stroke after relapse of hypercortisolism and could not be submitted to further surgery/radiotherapy. In all three patients, urinary free cortisol was within the normal range on ketoconazole. Case history of the entire series included cardiac disorders and any drug known to affect QT interval: in detail, five patients were on antidepressive medication, and one was administered glibenclamide; two had been briefly treated with ciprofloxacin (table 1). The study was approved by the Ethical Committee of our institution.

Electrocardiogram. Standard electrocardiograms had been performed in patients on ketoconazole at various time-points over the years, in

keeping with our clinical surveillance practice. These tracings were recovered and QT interval duration measured by a cardiologist blinded to patients' status. In detail, QT interval (lead II of the conventional 12-lead electrocardiogram) was measured in five non-consecutive beats [13] and divided by the square root of the R-R interval according to Bazett's formula (QTc) [14]. Electrocardiographic tracings were also reviewed for hypokalaemia-induced prominent U waves. Normal values for QTc are <440 msec. for men and <460 msec. for women. For statistical analysis, readings before starting ketoconazole and from the last available ECG on ketoconazole (see table 1 for length of follow-up) were compared.

Hormonal and biochemical evaluation. Urinary free cortisol (UFC), ACTH and serum cortisol, as well as gonadal status, thyroid function and serum electrolytes, were evaluated at baseline and during ketoconazole treatment. UFC was measured after extraction by solid-phase radioimmunoassay (DPC Coat-a-Count; Los Angeles, USA); serum cortisol and plasma ACTH were measured by commercial immunometric assays (Diasorin, Saluggia, Italy). TSH, free thyroid hormones and androgens were assayed by electrochemiluminescence (ECLIA; Roche Diagnostics, Monza, Italy). Clinical chemistry platform was used to determine serum electrolytes as well as routine clinical analyses (Hitachi 917; Roche Diagnostics, Monza, Italy). Normal values in our laboratory for UFC, serum cortisol and plasma ACTH are 10–80 µg/24 hr, 5–25 µg/dL and 10–50 pg/mL, respectively; total testosterone should be comprised within 9.9–27.8 nmol/L in adult males.

Statistical analysis. Quantitative values were compared by Wilcoxon's test for paired data. Statistical significance was accepted at $p < 0.05$. Data are described as mean \pm S.E.M.

Table 1.

Features of patients with Cushing's disease on ketoconazole.

Baseline					On ketoconazole						
Pt #	Sex/Age	LVH	Kalaemia	QTc	QT-prolonging drugs	Disease phase	Dose, mg	Length	Kalaemia	QTc	QT-prolonging drugs
1	M/36	No	3.9	436		Prior to TSS	800	5	3.8	426	
2	M/30	No	4.4	379		TSS failure	600	24	4.5	393	
3	M/23	Yes	3.15	458		TSS failure; after RT	100	132	3.8	375	
4	F/55	Yes	3.7	418	Fluoxetine 20 mg	TSS failure	200	60	4.0	406	Fluoxetine 20 mg
5	F/42	No	4.7	408	Paroxetine 20 mg	Prior to TSS	400	6	5.3	431	Paroxetine 20 mg
6	F/31	No	3.9	372		Prior to TSS	600	7	4.5	377	
7	F/40	No	3.9	424		Prior to TSS	600	1	4.4	408	
8	F/34	No	4.1	433		Prior to TSS	600	6	3.6	440	
9	F/59	Yes	3.5	391	Citalopram 20 mg Glibenclamide 15 mg	TSS failure	400	5	3.7	388	Citalopram 20 mg Glibenclamide 15 mg Ciprofloxacin 1 g (1 week)
10	F/34	No	4.2	402		TSS failure; after RT	600	7	4.0	392	Escitalopram 20 mg
11	F/27	No	4.4	367		TSS failure; after RT	400	18	4.4	388	
12	F/51	No	4.5	368		TSS failure; after RT	400	132	4.4	375	Ciprofloxacin 1 g (1 week)
13	F/29	No	3.8	375		Relapse	600	36	3.8	408	
14	F/41	No	4.1	360		TSS failure	800	12	4.3	400	
15	F/35	No	3.9	402		Relapse	400	144	3.3	450	Paroxetine 20 mg

LVH, left ventricular hypertrophy as assessed by echocardiography; TSS, transphenoidal surgery; RT, radiotherapy. Length of ketoconazole treatment is given in months. QTc values on ketoconazole represent the last available measure during treatment. Unless otherwise stated, treatment with known QT-prolonging drugs was protracted over years. Daily dosage is given for all drugs. Data in bold represent abnormal values.

Results

In all patients but one, patient #3, QTc values were within the normal range prior to ketoconazole administration. Further, QTc measurements were comprised within the normal range in all patients during ketoconazole administration, and no arrhythmic or otherwise acute cardiac event was reported over the entire 598-patient-month observation period. On average, QTc values before and at the last available reading during ketoconazole treatment were superimposable in both sexes (393.2 ± 7.17 versus 405.2 ± 6.96 msec. in women and 424.3 ± 23.54 versus 398.0 ± 14.93 msec. in men, respectively, both NS).

In patient #3, QTc was prolonged prior to starting ketoconazole (458 msec.) and then normalized and remained within the normal range throughout ketoconazole treatment for 11 years (range 367–410 msec., 375 msec. at last measurement; table 1). Of note, markedly abnormal QTc had been registered in this patient during the active disease phase (485 msec.) which then shortened upon partial remission of hypercortisolism with transsphenoidal surgery (458 msec.). The patient presented left ventricular hypertrophy (LVMI 63.2 g/m^2 ; normal range $<50 \text{ g/m}^2$), modest hypokalaemia (3.15 mEq/L) and subnormal testosterone levels (5.84 nmol/L) at diagnosis; ventricular hypertrophy ameliorated (LVMI 55.8 g/m^2) after surgery, while biochemical alterations normalized and remained stable during treatment with ketoconazole: potassium values ranged from 3.8 to 4.15 mEq/L and testosterone concentrations from 18.8 to 19.9 nmol/L.

Several patients were administered QT-prolonging drugs, for example antibiotics, psychotropic drugs and oral hypoglycaemic agents (table 1), while on ketoconazole without prolongation of the QT interval. Notably, no changes in QTc were observed in patients treated with ketoconazole for 11 and 12 years (patients #12 and #15) even during concomitant administration of ciprofloxacin for 1 week and paroxetine for 2 years, respectively (table 1). Patient #15 also developed transitory hypokalaemia (3.3 mEq/L) while on ketoconazole, but her QTc remained below 460 msec. (fig. 1).

No significant elevation of liver enzymes, that is increase greater than 3 times the upper limit of the normal range, as per the National Cancer Institute-Common Toxicology Criteria Adverse Events version 4.03 (NCI-CTCAE v.4.03 published in June 2010), was observed on ketoconazole in any patient.

Discussion

Ketoconazole is classified among low-risk QT interval-prolonging drugs [3] and is thus weakly associated with the risk of torsade de pointes, the most severe ventricular arrhythmia resulting from prolonged QT interval. Ketoconazole is considered among QT-prolonging drugs as it is known to inhibit, in addition to steroidogenic CYP enzymes [15], also hepatic CYP3A4 [5] thereby prolonging half-life of drugs metabolized by this enzyme, for example antiarrhythmics, antihistamines, antidepressants and antibiotics. In fact, co-administration of ketoconazole has been shown to prolong QT interval in

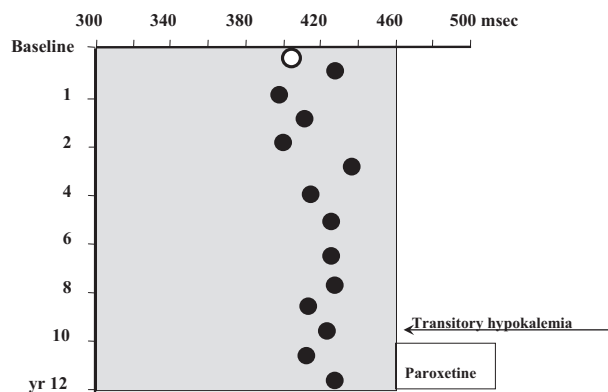


Fig. 1. QTc interval in patient #15 treated with 400 mg ketoconazole qd for 12 years. Baseline measurement is shown as empty circle; filled circles indicate measurements on ketoconazole. Shaded area indicates normal range. Transitory hypokalaemia was registered at 10-year evaluation (3.3 mEq/L). Paroxetine 20 mg qd was added in the last 2 years.

healthy volunteers administered antihistamines such as terfenadine [16,17], loratadine or ebastine [18,19], domperidone – a gastrointestinal stimulant [20] – or the macrolide telithromycin [21]. Increases in QT interval reported in these studies range from 10 msec. with ebastine or telithromycin, 20 mm with domperidone and up to 70 msec. with terfenadine [16,18,21,22]. In addition to these studies in healthy volunteers, single-case reports described prolonged QT interval, torsade de pointes and syncopal episodes in patients treated with ketoconazole and terfenadine, astemizole or cetirizine [23–26].

Ketoconazole may also have a direct effect on QT interval. In fact, experimental studies have shown that ketoconazole blocks cardiac potassium HERG (I_{kr}) channels [27–29] and alters HERG protein channel trafficking [28], thus prolonging action potential. Further, ketoconazole may slow inactivation of voltage-gated L-type calcium channels [30]. Overall, however, thorough QT (TQT) studies [2] in healthy volunteers demonstrated that ketoconazole had a slight, non-significant effect on QT interval, that is ~8 msec. [18,22,31].

Ketoconazole has been withdrawn as an antifungal but is still in use in Cushing's syndrome, a severe endocrine disorder characterized by excess cortisol secretion. First-choice therapy for this condition is surgical removal of the causative lesion, but medical treatment is frequently required prior to surgery, after unsuccessful surgery and/or while awaiting the effects of radiotherapy [7–9]. Dosage of ketoconazole in this setting is higher than in mycotic infections (e.g. 400–1200 mg qd versus 50–200 mg qd) [9] and treatment carried out for longer periods of time, often months or even years if there are no viable, alternative treatment options. In Cushing's syndrome, ketoconazole has been used off-label for decades and was just recently approved by the European Medicines Agency [11]. The recent sanctioning is likely to lead to a greater use of this compound, but no data on its possible untoward effect on QT interval in patients with Cushing's syndrome are as yet available.

Our study now shows that administration of ketoconazole in patients with Cushing's disease is not associated with

significant QT interval prolongation. We even observed normalization of QT interval in the patient with prolonged QTc prior to efficacious ketoconazole treatment. It is worth recalling that ketoconazole is listed among drugs at conditional risk of torsade de pointes, thus determined by drug overdose, drug–drug interactions or when administered to high-risk individuals. Thus, unless these conditions are met, ketoconazole is weakly associated with risk of torsade de pointes.

As regards drug overdosage, 400 mg ketoconazole daily was administered for up to 12 years without significant QTc interval prolongation. Half-life of ketoconazole ranges from 2 to 10 hr with almost complete hepatic metabolism and excretion in faeces, and drug accumulation does not appear to occur during prolonged administration [32,33].

Conversely, drug interactions might represent a problem during long-term administration as these patients may necessitate additional medical therapy – possibly comprising other drugs at risk of QT interval prolongation such as antidepressants, antidiabetics or antibiotics over time. In our series, this indeed occurred but was not associated with significant QTc prolongation. Of note, while significant QT prolongation has been reported during co-administration of ketoconazole and drugs with known risk of torsade de pointes [23–25], not all associations lead to relevant QT prolongation [34,35]. Further, experimental studies showed that sequential administration of I_{Kr} blockers, such as ketoconazole and domperidone, may result in competitive antagonism rather than potentiation of the HERG channel [36].

Likelihood of torsade de pointes on ketoconazole is higher in patients with hypokalaemia and left ventricular hypertrophy, both conditions frequent in Cushing's syndrome. Indeed, we recently reported a prolongation of QT interval in male patients with Cushing's syndrome [12], linked in part to hypokalaemia. Low testosterone levels also appeared to contribute to prolonged QTc in men with Cushing's disease, an observation which is in keeping with the role of testosterone on QT interval duration [37] and the high prevalence of abnormal QTc measurements in hypogonadal male individuals [38,39]. One patient of the present series, a man with prolonged QTc interval at initial evaluation, presented both hypokalaemia and hypogonadism at the time. Surgery led to partial remission of hypercortisolism and shortening of QT interval which, however, remained abnormal. Treatment with ketoconazole was initiated leading to containment of excess cortisol secretion and normalization of testosterone and potassium levels. QT interval shortened further on ketoconazole and remained within the normal range throughout the entire 11-year treatment. Similarly, QT interval was normal in all patients well controlled with ketoconazole, even if other QT interval-prolonging drugs were co-administered. This indicates that administration of ketoconazole to patients who present prolonged QT interval secondary to a given, acquired disorder does not interfere with normalization of QT interval if the underlying cause is resolved. This finding tallies with the observation that normalization of prolonged QT interval may occur during efficacious treatment of acromegaly by octreotide, a somatostatin

analogue listed among agents at possible risk of torsade de pointes. In fact, abnormal QT interval measurements decreased during octreotide administration in these patients, in parallel with amelioration of ventricular hypertrophy [40].

Lastly, it is worth mentioning that our study – albeit a small series – conforms with Clinical Trial Evaluation requirements for negative TQT studies, that is collection of baseline and periodic on-therapy ECG in accordance with current practices in a given therapeutic field [2,41]. In the present case, the latter encompasses repeat ECG assessments on ketoconazole and close surveillance of patients who develop electrolyte abnormalities or require concomitant administration of known QT-prolonging drugs. Once these factors are taken into due account, monitoring of patients with Cushing's disease on ketoconazole can follow recommendations for any drug at low risk of QT prolongation. Indeed, as discussed above, control of hypercortisolism with ketoconazole is associated with resolution of factors which may increase risk of QT prolongation in patients with Cushing's disease *per se*, for example hypogonadism and hypokalaemia.

In conclusion, our study shows that long-term ketoconazole administration to patients with Cushing's disease is not associated with significant QT interval prolongation. Our observation provides significant safety information on the use of ketoconazole in these patients. ECG surveillance during ketoconazole treatment in these patients can follow recommendations as for any low-risk QT-prolonging drug [42].

References

- 1 Roden DM. Drug-induced prolongation of the QT interval. *N Engl J Med* 2004;**350**:1013–22.
- 2 Clinical Evaluation of QT/QTc interval prolongation and proarrhythmic potential of non-antiarrhythmic drugs. <http://www.fda.gov/downloads/drugs/guidancecomplianceregulatoryinformation/guidances/ucm073153.pdf/> (last accessed on 30 October 2005).
- 3 Assessing risk of drugs that prolong the QT interval and cause arrhythmias. <https://www.crediblemeds.org/new-drug-list/> (last accessed on 30 June 2015).
- 4 O'Brien PJ. High-content analysis in toxicology: screening substances for human toxicity potential, elucidating subcellular mechanisms and *in vivo* use as translational safety biomarkers. *Basic Clin Pharmacol Toxicol* 2014;**115**:4–17.
- 5 Albengres E, Le Louet H, Tillement JP. Systemic antifungal agents. Drug interactions of clinical significance. *Drug Saf* 1998;**18**:83–97.
- 6 Spina E, de Leon J. Metabolic drug interactions with newer antipsychotics: a comparative review. *Basic Clin Pharmacol Toxicol* 2007;**100**:4–22.
- 7 Sonino N. The use of ketoconazole as an inhibitor of steroid production. *N Engl J Med* 1987;**317**:812–8.
- 8 Castinetti F, Guignat L, Giraud P, Muller M, Kamenicky P, Druil D *et al.* Ketoconazole in Cushing's disease: is it worth a try? *J Clin Endocrinol Metab* 2014;**99**:1623–30.
- 9 Pecori Giraldo F, Cavagnini F. Advances in the medical management of Cushing's syndrome. *Expert Opin Pharmacother* 2008;**9**:2423–33.
- 10 Biller BMK, Grossman AB, Stewart PM, Melmed S, Bertagna X, Bertherat J *et al.* Treatment of ACTH-dependent Cushing's syndrome: a consensus statement. *J Clin Endocrinol Metab* 2008;**93**:2454–62.

- 11 Ketoconazole HRA recommended for approval in Cushing's syndrome. http://www.ema.europa.eu/docs/en_GB/document_library/Press_release/2014/09/WC500173638.pdf/ (last accessed on 26 September 2014).
- 12 Pecori Giralaldi F, Toja PM, Michailidis G, Metinidou A, De Martin M, Scacchi M *et al.* High prevalence of prolonged QT interval duration in male patients with Cushing's disease. *Exp Clin Endocrinol Diabetes* 2011;**119**:221–4.
- 13 Schwartz PJ, Garson A Jr, Paul T, Stramba-Badiale M, Vetter VL, Wren C *et al.* Guidelines for the interpretation of neonatal electrocardiogram. A task force of the European Society of Cardiology. *Eur Heart J* 2002;**23**:1329–44.
- 14 Schwartz PJ, Moss AJ, Vincent GM, Crampton RS. Diagnostic criteria for the long QT syndrome. *Circulation* 1993;**88**:782–4.
- 15 Engelhardt D, Weber MM. Therapy of Cushing's syndrome with steroid biosynthesis inhibitors. *J Steroid Biochem Mol Biol* 1994;**49**:261–7.
- 16 Honig PK, Wortham DC, Zamani K, Conner DP, Mullin JC, Cantilena LR. Terfenadine-ketoconazole interaction. Pharmacokinetic and electrocardiographic consequences. *JAMA* 1993;**269**:1513–8.
- 17 Paserchia LA, Hewett J, Woosley RL. Effects of ketoconazole on QTc. *Clin Pharmacol Ther* 1994;**55**:146.
- 18 Chaikin P, Gillen MS, Malik M, Pentikis H, Rhodes GR, Roberts DJ. Co-administration of ketoconazole with H1-antagonists ebastine and loratadine in healthy subjects: pharmacokinetic and pharmacodynamic effects. *Br J Clin Pharmacol* 2005;**59**:346–54.
- 19 Moss AJ, Morganroth J. Cardiac effects of ebastine and other antihistamines in humans. *Drug Saf* 1999;**21**(Suppl 1):69–80.
- 20 Medicines Control Council. Interaction between ketoconazole and domperidone and the risk of QT prolongation—important safety information. *S Afr Med J* 2006;**96**:596.
- 21 KETEK (Telithromycin) Briefing document for the FDA anti-infective drug products Advisory Committee Meeting. http://www.fda.gov/ohrms/dockets/ac/01/briefing/3746b_01_aventis.pdf/ (last accessed on 1 March 2001).
- 22 Boyce MJ, Baisley KJ, Warrington SJ. Pharmacokinetic interaction between domperidone and ketoconazole leads to QT prolongation in healthy volunteers: a randomized, placebo-controlled, double-blind, crossover study. *Br J Clin Pharmacol* 2012;**73**:411–21.
- 23 Zimmermann M, Duruz H, Guinand O, Broccard O, Levy P, Lacatis D *et al.* Torsades de Pointes after treatment with terfenadine and ketoconazole. *Eur Heart J* 1992;**13**:1002–3.
- 24 Tsai WC, Tsai LM, Chen JH. Combined use of astemizole and ketoconazole resulting in torsade de pointes. *J Formos Med Assoc* 1997;**96**:144–6.
- 25 Mok NS, Lo YK, Tsui PT, Lam CW. Ketoconazole induced Torsades de Pointes without concomitant use of QT interval-prolonging drug. *J Cardiovasc Electrophysiol* 2005;**16**:1375–7.
- 26 Monahan BP, Ferguson CL, Killeavy ES, Lloyd BK, Troy J, Cantilena LR Jr. Torsades de pointes occurring in association with terfenadine use. *JAMA* 1990;**264**:2788–90.
- 27 Dumaine R, Roy ML, Brown AM. Blockade of HERG and Kv1.5 by ketoconazole. *J Pharmacol Exp Ther* 1998;**286**:727–35.
- 28 Takemasa H, Nagatomo T, Abe H, Kawakami K, Igarashi T, Tsurugi T *et al.* Coexistence of hERG current block and disruption of protein trafficking in ketoconazole-induced long QT syndrome. *Br J Pharmacol* 2008;**153**:439–47.
- 29 Ridley JM, Milnes JT, Duncan RS, McPate MJ, James AF, Witchel HJ *et al.* Inhibition of the HERG K⁺ channel by the antifungal drug ketoconazole depends on channel gating and involves the S6 residue F656. *FEBS Lett* 2006;**580**:1999–2005.
- 30 Sung DJ, Kim JG, Won KJ, Kim B, Shin HC, Park JY *et al.* Blockade of K⁺ and Ca²⁺ channels by azole antifungal agents in neonatal rat ventricular myocytes. *Biol Pharm Bull* 2012;**35**:1469–75.
- 31 Ferber G, Zhou M, Darpo B. Detection of QTc effects in small studies—implications for replacing the thorough QT study. *Ann Noninvasive Electrocardiol* 2015;**20**:368–77.
- 32 Badcock NR, Bartholomeusz FD, Frewin DB, Sansom LN, Reid JG. The pharmacokinetics of ketoconazole after chronic administration in adults. *Eur J Clin Pharmacol* 1987;**33**:531–4.
- 33 Van Tyle JH. Ketoconazole. Mechanism of action, spectrum of activity, pharmacokinetics, drug interactions, adverse reactions and therapeutic use. *Pharmacotherapy* 1984;**4**:343–73.
- 34 Darpo B, Ferber G, Zhou M, Sumeray M, Sager P. Lomitapide at supratherapeutic plasma levels does not prolong the QTc interval—results from a TQT study with moxifloxacin and ketoconazole. *Ann Noninvasive Electrocardiol* 2013;**18**:577–89.
- 35 Herranz U, Rusca A, Assandri A. Emedastine-ketoconazole: pharmacokinetic and pharmacodynamic interactions in healthy volunteers. *Int J Clin Pharmacol Ther* 2001;**39**:102–9.
- 36 Hreiche R, Plante I, Drolet B, Morissette P, Turgeon J. Lengthening of cardiac repolarization in isolated guinea pigs hearts by sequential or concomitant administration of two I_{Kr} blockers. *J Pharm Sci* 2011;**100**:2469–81.
- 37 James AF, Choisy SCM, Hancox JC. Recent advances in understanding sex differences in cardiac repolarization. *Prog Biophys Mol Biol* 2007;**94**:265–319.
- 38 Pecori Giralaldi F, Toja PM, Filippini B, Michailidis G, Scacchi M, Stramba-Badiale M *et al.* Increased prevalence of prolonged QT interval in males with primary or secondary hypogonadism. A pilot study. *Int J Androl* 2010;**33**:e132–8.
- 39 Pecori Giralaldi F, Manzoni G, Michailidis G, Scacchi M, Stramba-Badiale M, Cavagnini F. High prevalence of prolonged QT interval in obese hypogonadal males. *Obesity* 2011;**19**:2015–8.
- 40 Fatti LM, Scacchi M, Lavezzi E, Pecori Giralaldi F, De Martin M, Toja PM *et al.* Effects of treatment with somatostatin analogues on QT interval duration in acromegalic patients. *Clin Endocrinol* 2006;**65**:626–30.
- 41 Al-Khatib SM, LaPointe NM, Kramer JM, Califf RM. What clinicians should know about the QT interval. *JAMA* 2003;**289**:2120–7.
- 42 Fabritz L, Kirchhof P. Predictable and less predictable unwanted cardiac drug effects: individual predisposition and transient precipitating factors. *Basic Clin Pharmacol Toxicol* 2010;**106**:263–8.