

Contents lists available at [SciVerse ScienceDirect](http://SciVerse.Sciencedirect.com)

Cancer Treatment Reviews

journal homepage: www.elsevierhealth.com/journals/ctrv

Complications of Treatment

Emerging toxicities in the treatment of non-small cell lung cancer: Ocular disorders



Francesco Agustoni, Marco Platania, Milena Vitali, Nicoletta Zilembo, Eva Haspinger, Valentina Sinno, Rosaria Gallucci, Filippo de Braud, Marina Chiara Garassino*

Medical Oncology Department, Fondazione IRCCS Istituto Nazionale dei Tumori, Milano, Italy

ARTICLE INFO

Article history:

Received 14 January 2013

Received in revised form 7 May 2013

Accepted 20 May 2013

Keywords:

Non-small-cell lung cancer

Chemotherapy

Target therapies

Ocular toxicity

Ophthalmology

ABSTRACT

The treatment of advanced disease (stage IIIb and IV) of non-small cell lung cancer (NSCLC) is based on systemic treatment with platinum-based chemotherapy or biological compounds depending on the disease molecular profile. In the last few years, intensive investigational efforts in anticancer therapy have led to the registration of new active chemotherapeutic agents, combination regimens, and biological drugs, expanding choices for customizing individual treatment. However, the introduction of new drugs in the clinical setting has led to several new toxicities, creating some difficulties in daily management. Among these, ocular toxicity is generally overlooked as more common toxicities such as myelosuppression, stomatitis, diarrhea, vomiting, “hand-foot syndrome”, and neurological alterations attract greater attention. Ophthalmic complications from cytotoxic chemotherapeutics are rare, transient, and of mild/moderate intensity but irreversible acute disorders are possible. The best way to prevent potential irreversible visual complications is an awareness of the potential for ocular toxicity because dose reductions or early drug cessation can prevent serious ocular complications in the majority of cases. However, given the novelty of many therapeutic agents and the complexity of ocular pathology, oncologists may be unfamiliar with these adverse effects of anticancer therapy. Although toxicities from chemotherapy are generally intense but short lasting, toxicities related to targeted drugs are often milder but longer lasting and can persist throughout treatment. Here we review the principal clinical presentations of ocular toxicity arising from chemotherapy [1–3], target therapies [4], and newly developed drugs and provide some recommendations for monitoring and management of ocular toxicity.

© 2013 The Authors. Published by Elsevier Ltd. Open access under [CC BY-NC-ND license](http://creativecommons.org/licenses/by-nc-nd/4.0/).

Introduction

The treatment of non-small cell lung cancer (NSCLC) is challenging, but several new targeted agents are emerging from the pipeline. At the same time, oncologists face the prospect of new types of adverse events, among them ocular toxicity. Although targeted agents are directed against aberrations in tumor cells, they are associated with toxicities affecting multiple organs, including the eye, as a result of target expression in ocular and eyelid tissue.

Ocular toxicity (Table 1) is generally underestimated and considered minor. Nevertheless, oncologists must be challenged to recognize clinical cases and understand how to manage them; it is also important that oncologists refer to the ophthalmologist

when the complexity of clinical status require a specialistic evaluation. Some ocular toxicity (e.g., conjunctivitis) may be diagnosed during a normal physical examination whereas retinal damage requires a specialist ophthalmologic examination.

Ocular toxicities are grouped in the CTC-AE [5] for ocular toxicity, which mainly takes into account interference with the activities of daily living, as for other adverse events. However, while for chemotherapeutics, toxicities are generally short lived and the intensity can be considered a good marker for intervention, toxicities for targeting agents can be long lasting albeit of relatively mild intensity, and the existing systems for recording are not adequate for measuring patient unease.

At present, with new investigational agents with known pre-clinical ocular toxicity observed in animal models, clinical trials include specialist ophthalmologic visits; this is mandatory as part of many study protocol procedures.

Ophthalmological toxicities arising from chemotherapy

The ocular complications associated with cancer chemotherapeutics have been described in three major systematic reviews

* Corresponding author. Address: Medical Oncology Department, Fondazione IRCCS Istituto Nazionale dei Tumori, Milano 20133, Italy. Tel.: +39 02 2390 3813; fax: +39 02 2390 2149.

E-mail address: marina.garassino@istitutotumori.mi.it (M.C. Garassino).

Table 1
Definitions of common ocular toxicity.

Toxicity	Definition
Blepharitis	Inflammation of the eyelids, mainly at the margin; main signs are redness and flaking of skin on the lids and crusting worse on waking
Central serous retinopathy	Localized serous retinal detachment observable only on fundoscopy; manifests as slightly blurry vision and the perception of objects smaller than they really are (micropsia)
Conjunctivitis	Inflammation and redness of the conjunctiva
Cystoid macular edema	Chronic inflammation of the macular area only observable on fundoscopy and confirmed by fluorescein angiography
Epiphora	Excessive tear production usually caused by eye irritation
Hemianopia	Visual field defect that respects the vertical midline in both eyes; it can be homonymous or bitemporal
Keratitis	Inflammation of the cornea, usually referring to the corneal surface (epithelium); manifests as pain, photophobia, and increased lacrimation, more evident in slit lamp examination with the aid of a dye
Periorbital edema	Inflammation and increased fluid accumulation of the interstitial tissues from the eyelid into the orbital septum; manifests as a hard swelling of the eyelids
Photopsia/ photophobia	Ocular pain and sensitivity to light
Trichomegaly	Pathologically long eyelashes that can get misdirected and cause ocular surface abrasions
Uveitis	Inflammation of the uveal tract; it can be anterior (involving the anterior chamber and iris) or posterior (involving the vitreous and choroid)

[1–3], but none has specifically focused on NSCLC patients. Here we review only toxicities related to approved chemotherapeutics for NSCLC and that are commonly used by oncologists in their daily clinical practice, referring both to the adjuvant and to the meta-static setting.

Cisplatin is a heavy metal compound and the cornerstone of several antitumor therapies. All the main clinical guidelines (American Society of Clinical Oncology (ASCO) [6] and European Society of Medical Oncology (ESMO) [7]) recommend a first-line cisplatin-based chemotherapy as the treatment of choice in the advanced and adjuvant setting. Drugs that may be combined with platinum include the third-generation cytotoxic drugs docetaxel, gemcitabine, irinotecan, paclitaxel, pemetrexed, vinorelbine and etoposide (just for small-cell lung cancer). Neurotoxicity represents the major dose-limiting toxicity of cisplatin. The neuropathy is uncommon below a cumulative cisplatin dose of 400 mg/m² but nearly universal in the cumulative-dose range of 600–800 mg/m². The cumulative dose that causes peripheral neuropathy tends to be higher in children and younger patients than in the elderly and the risk of neurotoxicity is higher in patients with renal dysfunction [8–10]. Visual impairment has been considered an infrequent form of cisplatin neurotoxicity. Case reports have attributed visual alterations to optic neuritis and cortical blindness, which have sometimes been accompanied by seizure activity [11–14]. Ocular toxicity has generally been reported after the use of regimens with higher doses or greater dose frequencies than those recommended by the manufacturer. Improvement and/or total recovery usually occurs after discontinuation of cisplatin [15]. An alert of possibly cisplatin-induced retinal ischemia was reported by Kwan in 2006 [16].

Intravenous administration of **carboplatin** is less frequently associated with ocular disturbances, and a few cases of maculopathy, optic neuropathy, cortical blindness, sore eyes, blurred vision, and chorioretinitis to optic neuritis have been reported [17–19]. In any case, visual disturbances were reversible after drug cessation.

Pemetrexed is an antifolate chemotherapeutic agent. The antitumor activity of this agent likely derives from inhibition of several key folate-requiring enzymes, including thymidylate synthase, dihydrofolate reductase, and glycinamide ribonucleotide formyltransferase. The drug is currently approved for the treatment of pleural mesothelioma combined with a platinum compound and for first- and second-line therapy in advanced NSCLC with non-squamous histology. The only well-known drug-related ocular adverse event is conjunctivitis, also a common adverse effect of other antimetabolite antineoplastic agents such as cytosine arabinoside, 5-fluorouracil, and methotrexate [20,1,21]. This disturbance is generally associated with hyperemia, irritation, and serous secretions. It has been reported in less than 5% of mesothelioma-naïve pa-

tients who were randomly assigned to receive cisplatin in combination with pemetrexed or single-agent cisplatin, with the same incidence in the two arms. Another case has been documented in which a patient received pemetrexed as third-line therapy for NSCLC advanced disease and developed conjunctivitis; this was a cutaneous adverse event that consisted of the simultaneous occurrence of periorbital edema, conjunctivitis, and inflammatory edema of the upper and lower limbs [22].

Several prophylactic approaches have been investigated in the prevention of antimetabolite-induced conjunctivitis. Matteucci et al., [23] investigated in a randomized trial the efficacy of dexamethasone in combination with diclofenac eye drops as prophylaxis for conjunctivitis induced by high-dose cytosine arabinoside. They concluded that the combination of dexamethasone/diclofenac therapy compared with dexamethasone alone significantly prevented drug-induced conjunctivitis (incidence 13% vs. 45% respectively; $p \leq 0.09$). Treatment of drug-induced conjunctivitis usually involves the use of artificial tears, withdrawal of the agent which determined the toxicity, and a short course of topical steroids, and is typically curative [1,21], even though, most of the time, the conjunctivitis is recurrent despite symptomatic treatment. Steroidal therapy (topical or systemical) should be administered only if a possible infectious has been eliminated.

Gemcitabine has structural similarities to the other antimetabolite chemotherapeutic drugs so that ocular toxicities cannot be completely excluded. The drug is currently approved for the treatment of advanced disease and commonly used in the locally advanced and metastatic settings. Only one case of a drug-related visual serious adverse event has been reported, identified as a Purtscher retinopathy [24]. This is a rare syndrome characterized by the appearance of a vaso-occlusive retinal injury and concomitant presence of cutaneous vasculitis; this retinopathy was associated with digital necrosis and antinuclear antibody elevation. Another case report [25] of gemcitabine-induced retinopathy in a diabetic patient presented with retinal changes that included aneurysms, cotton-wool spots, intraretinal hemorrhages, and vascular leakage on fluorescein angiogram; clinical improvement after gemcitabine withdrawal and relapse of retinopathy from re-exposure strongly suggested gemcitabine to be causative of the disorder.

Docetaxel is an effective chemotherapeutic agent that is widely used in the treatment of locally advanced and metastatic NSCLC. Canalicular and nasolacrimal duct obstruction possibly due to stromal fibrosis are well-known ocular side effects of docetaxel [26]. Epiphora due to canalicular stenosis in patients treated with weekly docetaxel was first reported by Esmaeli et al., [27]. Nasolacrimal duct obstruction secondary to treatment with docetaxel may be partly due to stromal fibrosis in the mucosal lining of the lacrimal

drainage apparatus. These changes are consistent with a previous preclinical observation that docetaxel is excreted via the lacrimal glands. Early detection is important to prevent irreversible stenosis that would require surgical intervention by dacryocystorhinostomy. Skolnik and Doughman [28] also reported a case of erosive conjunctivitis and punctual stenosis secondary to docetaxel administration; the erosive conjunctivitis resolved after drug discontinuation.

Paclitaxel is as widely used as docetaxel in the treatment of local and metastatic NSCLC. This drug is known to produce neurotoxicity. Both transient and scintillating scotoma and visual impairment have been reported with paclitaxel [29]. Photopsia usually appears during the last 30 min of the infusion and resolves completely within 3 h. It usually occurs in patients who receive doses of 250 mg/m² or more but rarely can develop at doses of 175 mg/m² given intravenously [30]. One of the rare side-effects caused by taxanes is a bilateral cystoid macular edema [31]; it tends to be bilateral and can be confirmed by its biomicroscopic appearance on optical tomography scan, but the particularity of this kind of ocular disorder is that it is angiographically silent; fluorescein angiography demonstrated the unusual finding of the absence of localized retinal capillary leakage [32]. The mechanism of this edema is not clearly understood, and existing hypotheses do not explain this phenomenon very well. Very faint permeability of retinal vessels has been suggested as an explanation with a breakdown of the retinal blood-ocular barrier so minute that even a small fluorescein molecule cannot extrude or only minimally extrudes. Another possible pathogenic mechanism, suggested by Joshi and Garretson [33], is a toxic effect of paclitaxel on Müller cells, which are responsible for maintaining osmotic gradients within the neurosensory retina, resulting in intracellular fluid accumulation. Some patients treated with paclitaxel develop visual evoked potential abnormalities typical of demyelinating optic neuropathy; a reversible scotoma was reported by Capri et al. [29], and the abnormal visual evoked potential suggested an involvement of the optic nerve, comparable to the changes seen in ischemic neuropathies. Glaucoma also has been reported as a consequence of paclitaxel and docetaxel therapy [34,35]. It is interesting to note that ophthalmologists have used an *in vitro* model for proliferative vitreoretinopathy to evaluate the action of paclitaxel on chorioretinal fibroblast proliferation and contractility. Proliferative vitreoretinopathy results in retinal detachment and visual impairment due to fibroblastic proliferation in the vitreous and subsequent cellular contraction; dose–response curves obtained show paclitaxel to be a potent inhibitor of both cellular events [36].

Vinorelbine is a plant alkaloid that stabilizes the microtubules by inhibiting the polymerization of tubulin, and the drug is currently approved for the treatment of advanced NSCLC. To our knowledge, no case of ocular toxicities has been reported with vinorelbine.

Ophthalmological toxicities arising from targeted therapies

At present, only agents targeting EGFR- and ALK-pathways have an established role for the treatment of advanced NSCLC. However, several targeted compounds are under investigation, and some of them have yielded promising results in the early phases of their development. Finally, no targeted agents have a role in the adjuvant setting.

Anti-EGFR agents

Agents targeting EGFR can be divided into at least two groups: EGFR tyrosine kinase inhibitors (TKIs) and EGFR-targeting monoclonal antibodies (mAbs). To date, only EGFR-TKIs and in particular gefitinib and erlotinib are commonly used in the clinical

practice while afatinib and dacomitinib are now approaching this level of use.

Gefitinib and **erlotinib** are orally active EGFR-TKIs that selectively target HER1 (human epidermal growth factor receptor EGFR [ErbB1]). In preclinical toxicity studies of gefitinib at 40 mg/kg/day in rats and dogs, reversible thinning of corneal epithelium was observed in both species after 1 and 6 months. Furthermore, in dogs treated with the highest dose of gefitinib for 6 months, the corneal opacification first observed at one month progressed on treatment and did not reverse during a 3-month withdrawal period [37]. Other EGFR inhibitors have caused similar corneal changes in preclinical models, which are consistent with the pharmacological actions of gefitinib [38]. EGFR is strongly expressed in the basal epithelial cells of limbal and conjunctival epithelia and throughout the corneal epithelium; however, little or no EGFR expression is seen in the superficial conjunctival or limbal epithelia, demonstrating that EGFR is preferentially expressed in basal epithelial cells that have the greatest proliferative potential. The EGFR ligand, EGF, promotes migration and proliferation of epithelial cells, thus facilitating corneal epithelial wound healing. Furthermore, endogenous EGF is synthesized by the lacrimal glands in response to corneal epithelial injury. EGF occurs in high concentrations in tears and is important for normal ocular homeostasis [39]. The prescribing information for gefitinib [40] notes that eye pathologies are common and include conjunctivitis, blepharitis, and eye dryness, events that can occur in association with other dryness scenarios (principally cutaneous reactions) of grade CTCAE 1 [5]. Uncommon ocular-related adverse events include reversible corneal erosion associated with eyelash growth. Although it appears to be a class effect associated with EGFR inhibitors, the occurrence of eyelash growth in relation to EGFR mutations is unknown; whether eyelash growth correlates with clinical response of lung cancer to EGFR inhibitors or whether it occurs as an unrelated adverse event remains to be evaluated on a larger scale. In addition, the prescribing information reports “very rare” cases of corneal membrane sloughing and ocular ischemia.

The prescribing information for erlotinib [41] notes that conjunctivitis and keratoconjunctivitis sicca each occurred in 12% of patients with NSCLC in one study [42]. Moreover, one patient in treatment with erlotinib plus chemotherapy developed corneal erosion/ulcer as an inflammatory mucous/cutaneous complication. Bilateral periorbital rash, conjunctivitis, and eyelid ectropion have been reported with erlotinib.

Afatinib (also called BIBW 2992) is a novel dual irreversible EGFR/HER2 TKI that has been shown in preclinical studies to potentially prevent, delay, or overcome resistance to reversible EGFR-TKIs [43]; the preclinical *in vitro* and *in vivo* activity profile includes EGFR mutant models with activating EGFR mutations, considering the most common mutations (L858R and deletion of exon 19) and also the exon 20 gatekeeper T790M mutation [44,45]. The findings from these preclinical studies prompted the investigation of afatinib in patients with NSCLC and EGFR mutations (LUX-Lung program). Ocular toxicity has been reported in a few patients. In LUX-Lung 1 trial [46], ocular effects were reported in 13% of patients who received afatinib (13% Grade 1–2, <1% Grade 3–4); similar results are reported in LUX-Lung 2 trial [47], with 20% of ocular effects in patients received afatinib 40 mg/die and 28% in patients received afatinib 50 mg/die, with no event of Grade 3–4 toxicity. The two most common events were conjunctivitis and dry skin.

No data on the ocular toxicity of **dacomitinib**, an irreversible EGFR-TKI pan-human inhibitor, are available [48].

Basti [49] has listed the most common ocular toxicities in patients on EGFR inhibitors:

- Squamous blepharitis: This condition typically presents with hyperemia of the eyelid margin; it often accompanies an acneiform rash.

- **Trichomegaly:** Usually the lashes are elongated; in rare cases, the lashes may be misdirected inward and rub on the eyeball, causing significant irritation.
- **Meibomitis:** Patients with meibomitis complain of a burning sensation or mild redness of the eye, often accompanied by some mucus discharge.
- **Dysfunctional tear syndrome:** Dysfunctional tear syndrome can coexist with any of the above three conditions; the tear film is suboptimal and causes a dry, tired sensation of the eye as well as momentary sharp pain and/or burning.

The suggested treatment of these toxicities is mainly a warm compress, eyelid hygiene, corticosteroids, or anti-inflammatory medications. In case of keratitis or dry-eye syndrome, topical lubricants may be useful. It is important to specify that the steroidal therapy can be dangerous, should be administered on a short period of time (10 days) and should be considered only if a possible infectious has been eliminated. However, if important clinical manifestations are present, dose modification or interruption is recommended.

Table 2 lists a clinical trial sequence that is performed in lung cancer using anti-EGFR inhibitors, with reported percentages of ocular toxicities.

As the data in Table 2 suggest, only a few trials specified mucous/cutaneous toxicities with ocular disorders. Only in the IDEAL1 trial [53] was performed an ophthalmic monitoring, which did not reveal any significant drug-related abnormalities or drug-related G3 or G4 events; G1 or G2 drug-related ophthalmic adverse events were reported in 43 patients (21%), but none required withdrawal from therapy. Mok et al. [54] (studying efficacy and safety of erlotinib in 1,242 East/South-east Asian patients) reported conjunctivitis, blepharitis, keratitis, eye pain, dry eyes, and corneal erosion. Ranson et al. [62] (studying gefitinib) reported conjunctivitis in 15.6% of patients; Baselga et al. [63] (also studying gefitinib) noted that one patient had a grade 3 epithelial defect in the cornea, caused by abnormal eyelash growth, and the patient was withdrawn from the study. Perez-Soler et al. [64] (studying erlotinib) noted that less than 10% of their patients exhibited signs of ocular toxicity and that none exceeded grade 2.

ALK inhibitors

The fusion oncogene, echinoderm microtubule-associated protein-like 4–anaplastic lymphoma kinase (EML4-ALK), is present in approximately 5% of NSCLC tumors.

Crizotinib is an oral TKI that silences the protein product of the ALK fusion gene and has recently been approved for the treatment of NSCLC aberrantly expressing ALK. The efficacy of crizotinib in patients with locally advanced or metastatic ALK-positive NSCLC has been assessed in a two-part, phase I trial and a phase II trial [65–66]. Patients enrolled into these studies had received prior systemic therapy, with the exception of 15 patients in the phase II trial, who had no prior systemic treatment for locally advanced or metastatic disease. In the phase I trial ALK-positive NSCLC was identified using the Vysis ALK Break-Apart FISH Probe Kit; in the phase II trial ALK-positive NSCLC was identified using a number of local clinical trial assays. The primary efficacy endpoint in both studies was Objective Response Rate (ORR) according to Response Evaluation Criteria in Solid Tumors (RECIST). In the phase I trial the Objective Response Rate was 61%, with 68 patients responders (median duration of response: 48.1 weeks); in the phase II trial the Objective Response Rate was 61%, with 71 patients responders (median duration of response: 48.1 weeks). In US crizotinib is approved by FDA for the treatment of patients with locally advanced or metastatic non-small cell lung cancer (NSCLC) that is anaplastic lymphoma kinase (ALK)-positive as detected by an FDA-approved test; in Europe EMA has approved crizotinib not in first-line, but only when the disease has already been treated before. Emerging data suggest that crizotinib may also have activity in other subsets of lung cancer, including tumors demonstrating amplification or mutation of the MET oncogene, or translocation of the ROS1 oncogene [67]. Treatment-related visual disorders (including visual impairment, photopsia, blurred vision, vitreous floaters, photophobia and diplopia) were reported in 62% of crizotinib recipients enrolled in the phase I trial [65] or phase II trial [66]; most of these events were grade 1 and usually started within 2 weeks of treatment initiation.

New drugs

The mitogen-activated protein kinase (MEK) pathway is a signal transduction pathway that ultimately leads to cellular proliferation. **MEK-inhibitors** are a novel class of molecules under investigation in multiple tumor types, including NSCLC. In particular, they seem to be active in patients with KRAS mutations. There are many compounds undergoing testing in clinical trials (e.g., GSK1120212, AZD6244, PD0325901).

Visual changes observed in subjects receiving GSK1120212 may include but are not restricted to:

Table 2
Clinical trials performed in lung cancer using EGFR-inhibitors and ALK-inhibitors, with reported percentage of ocular toxicity.

Trial	No. patients	Ocular effects
LUX-lung 1 (afatinib) [46]	585 (33% Caucasian/66.1% Asian/0.9% others)	13% All grades; <1% grades 3–5
LUX-lung 2 (afatinib) [47]	129 (87% Asian/12% Whit/1% Black)	28% All grades
TITAN (erlotinib) [50]	203 (13.8% Asian/86.2% Caucasian)	N.A.
BR.21 (erlotinib) [42]	485 (12.9% Asian/87.1% others)	9% All grades; 1% grades 3–5
EURTAC (erlotinib) [51]	86 Caucasian	N.A.
SATURN (erlotinib) [52]	433 Caucasian	N.A.
TRUST (erlotinib) [54]	1,242 Asian	14% All grades
IDEAL 1 (gefitinib) [53]	210 Asian	21% All grades
ISEL (gefitinib)[55]	1,126 Asian	N.A.
INSTEP (gefitinib)[56]	100 (4% Asian/96% Caucasian)	5% All grades
IPASS (gefitinib) [57]	607 Asian	N.A.
INTEREST (gefitinib) [58]	729 (21.1% Asian/75.4% Caucasian/1.4% Black/2.1% others)	N.A.
First-SIGNAL (gefitinib) [59]	159 Asian	N.A.
Northeast Japan study group: (gefitinib vs. Carboplatin–Paclitaxel) [60]	114 Asian	N.A.
WJTOG3405(gefitinib) [61]	87 Asian	N.A.
Phase II trial (dacomitinib vs. erlotinib) [48]	94 (24.5% Asian/75.5% Caucasian)	N.A.
Phase I crizotinib [66]	119 (29% Asian/62% Caucasian/3% Black/6% others)	62% All grades
Phase II crizotinib [67]	136 (32% Asian/64% Caucasian/3% Black/1% others)	62% All grades

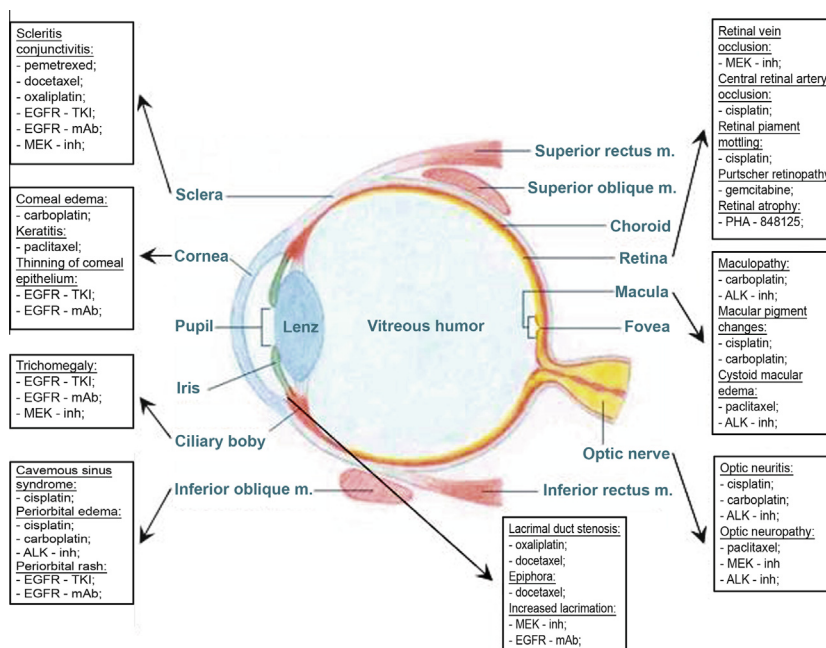


Fig. 1. Anatomic drawing of the eye and anticancer drugs associated with ocular disorders (ALK, anaplastic lymphoma kinase; EGFR, epidermal growth factor receptor; mAbs, monoclonal antibodies; MEK, mitogen-activated protein kinase; TKIs, tyrosine kinase inhibitors).

- Gradual or immediate loss of vision including blind spots
- Temporarily or permanently blurred vision
- Dimness of vision
- Double vision
- Halo vision around lights
- Colorful spots or floaters
- Changes in color vision

Selumetinib (AZD6244) is an orally available, selective, non-ATP competitive inhibitor of MEK1/MEK2 kinase; early phase clinical studies of selumetinib monotherapy showed target inhibition [68] and tumor response [69]; in a phase II trial selumetinib monotherapy showed little clinical activity in an unselected pretreated population with NSCLC [70]. In a phase II study with selumetinib plus docetaxel versus placebo plus docetaxel for KRAS-mutant advanced non-small-cell lung cancer [71], although the addition of selumetinib to docetaxel as second-line treatment did not significantly improve overall survival, the combination resulted in clinically meaningful and statistically significant improvements in progression-free survival, response and patient-reported outcomes. Selumetinib was correlated with some ocular disorders, such as blurred vision, diplopia, visual disturbance, eyelid edema, increased lacrimation, subconjunctival hemorrhage, and retinal pigment epithelium detachment.

PHA-848125 is a potent inhibitor of the kinase activity of the CDK2/Cyclin A complex, showing activity also towards closely related CDKs (CDK1, CDK4, and CDK5) and TRKA [72,73]. The anti-proliferative effect of PHA-848125 was tested on a panel of 120 tumoral cell lines established from different solid tumors, including lung cancer, thymic carcinomas, leukemias and lymphomas [74]. In combination studies, PHA-848125 exhibited synergistic or more than additive activity when administered with docetaxel, topotecan or temozolomide, and additive effect when combined with bevacizumab, irinotecan, 5-FU and gemcitabine. Combinations were well tolerated; ocular toxicity was observed in rats after prolonged administration (≥ 1 month) of PHA-848125. Bilateral retinal atrophy occurred from the dose of 16 mg/kg/day in females and at 24 mg/kg/day in males in the 4-week study. The same

finding was seen in rats given the dose of 16 mg/kg/day for 3 cycles of 3 weeks + 1 week rest or 5 cycles of 2 weeks + 1 week rest. This effect did not regress after the 2- or 4-week recovery periods. The dose of 8 mg/kg/day, given for 4 consecutive weeks or cyclically for 3 months, was the NOEL for ocular changes. No retinal changes were seen in rats following administration of PHA-848125 for 7 consecutive days up to the highest dose (51.8 mg/kg/day).

For these patients, it is important from the beginning to have a baseline ophthalmologic examination including visual acuity and fundoscopy. Also useful are retinal photographs and a visual field examination (Fig. 1).

Conclusion

There is no consensus or recommendation about routine ophthalmologic monitoring and management of ocular toxicity (Table 3). For anticancer agents that have the potential to induce ocular adverse side effects, a baseline ophthalmologic examination is recommended before starting treatment (e.g., visual acuity, tonometry, fundoscopy, color vision test, automated perimetry, retinal photographs) and during subsequent cycles of therapy. Some ocular toxicities can be diagnosed and graded by this routine examination whereas others (e.g., retinal detachment, altered visual acuity) require a dedicated ophthalmologic examination. In patients who experienced peripheral neuropathy during chemotherapy, a particular ophthalmological evaluation including an automated perimetry and a color vision test should be proposed to detect an asymptomatic optic neuritis. Many side effects can be managed just by dose interruption or dose modification with adequate supportive care. Anticipation of various treatment-related toxicities may provide the opportunity for clinicians to develop intervention strategies that could minimize or eliminate an expected side effect. There are many possible ways to manage ocular side effects that the patient can apply, including using a warm compress, eyelid hygiene, corticosteroids, or anti-inflammatory topical medications, or topical lubricants, and avoiding light exposure (dark room, sunglasses). The use of corticosteroids, valid therapeutical approach in many situations of ocular disorders,

Table 3
Management of common ocular toxicities (ALK, anaplastic lymphoma kinase; EGFR, epidermal growth factor receptor; mAbs, monoclonal antibodies; MEK, mitogen-activated protein kinase; TKIs, tyrosine kinase inhibitors).

Toxicity	Drug	Management
Blepharitis	EGFR-TKIs, EGFR mAbs	Warm compress, eyelid hygiene, corticosteroids, or anti-inflammatory medications
Blurred vision	Cisplatin, carboplatin, paclitaxel	Refer to ophthalmologist, discontinuation of cisplatin
Conjunctivitis	Pemetrexed, docetaxel, oxaliplatin, EGFR-TKIs, EGFR mAbs, MEK-inhibitors	Holding agent, corticosteroids, or anti-inflammatory medications, artificial tears
Corneal edema	Carboplatin	Refer to ophthalmologist
Cystoid macular edema	Paclitaxel, ALK-inhibitors	Refer to ophthalmologist; holding agent
Diplopia	MEK-inhibitors	Refer to neurologist and ophthalmologist
Epiphora	Docetaxel, ALK-inhibitors	Topical lubricants, refer to ophthalmologist
Keratitis	Paclitaxel	Topical lubricants, refer to ophthalmologist
Lacrimal duct stenosis	Oxaliplatin, docetaxel	Holding agent, refer to ophthalmologist
Maculopathy	Cisplatin, carboplatin, ALK-inhibitors, MEK-inhibitors	Refer to ophthalmologist, discontinuation of cisplatin
Optic neuritis	Cisplatin, carboplatin, paclitaxel ALK-inhibitors, MEK-inhibitors	Refer to neurologist and ophthalmologist, discontinuation of cisplatin
Papilledema	Cisplatin, oxaliplatin	Corticosteroids or anti-inflammatory medications, discontinuation of cisplatin
Periorbital edema	Cisplatin, carboplatin, ALK-inhibitors	Warm compress, refer to ophthalmologist, discontinuation of cisplatin
Periorbital rash	EGFR-TKIs, EGFR mAbs	Corticosteroids or anti-inflammatory medications, warm compress, eyelid hygiene
Photopsia	Paclitaxel	Topical lubricants, avoid light exposure
Ptosis	Oxaliplatin	Refer to neurologist and ophthalmologist
Retinopathy	Cisplatin, gemcitabine	Refer to neurologist and ophthalmologist; discontinuation of cisplatin
Retinal vein occlusion	Cisplatin, MEK-inhibitors	Refer to ophthalmologist; discontinuation of cisplatin
Trichomegaly	EGFR-TKIs, EGFR mAbs, MEK-inhibitors	Clip long or misdirected eyelashes; refer to ophthalmologist
Uveitis	MEK-inhibitors	Refer to ophthalmologist

can be dangerous and should be restricted to non infectious complications. A possible choice for patients could be simply clinical observation. However, if symptoms do not resolve or residual symptoms are present, the patient should be promptly referred to an ophthalmologist.

In conclusion, ophthalmic complications induced by cytotoxic chemotherapy and target therapies are often underestimated because of the priority given to other life-threatening effects. An ophthalmic baseline examination prior to anticancer treatment and careful monitoring during treatment may lead to a reduction in ocular side effects when predisposed patients are screened and carefully examined during administration of treatment. An annual ophthalmologic evaluation should be proposed for patient treated with target therapy such as EGFR-TKIs and ALK-inhibitors in order to improve an early diagnosis of ocular disorders. All patients should be informed about possible visual disturbance and about the necessity of informing their oncologists as soon as they experience any ocular alteration. The possible reversal of some of these adverse events, if discovered in time, emphasizes how important it is for clinicians to be aware of these ocular reactions and suggest an immediate consultation with an ophthalmologist where warranted. Because of the complexity of this kind of malignancies, a multi-disciplinary approach should be improved between different specialists. It is very important that oncologists and ophthalmologists work together to prevent irreversible ocular toxicity and determine the true cause of visual disturbance, as part of multi-disciplinary effort. In fact, not all visual disturbances are related to primary ocular disorders because malignancy, metastases, or non-oncologic diseases can also simulate some symptoms.

Finally, new toxicity criteria including not only the intensity, but also the duration, should be introduced into the management of patients undergoing targeted therapies.

Conflict of interest statement

All authors of this manuscript declare no potential conflicts of interest.

Acknowledgment

All authors of this manuscript have directly participated in its planning and execution and declare no potential conflicts of interest.

References

- [1] Schmid KE, Kornek GV, Scheithauer W, et al. Update on ocular complications of systemic cancer chemotherapy. *Surv Ophthalmol* 2006;51(1):19–37.
- [2] Omoti AE, Omoti CE. Ocular toxicity of systemic anticancer chemotherapy. *Pharm Pract* 2006;4(2):55–9.
- [3] al-Tweigeri T, Nabholz JM, Mackey JR. Ocular toxicity and cancer chemotherapy. A review. *Cancer* 1996;78(7):1359–73.
- [4] Renouf DJ, Velasquez-Martin JP, Simpson R, et al. Ocular toxicity of target therapies. *J Clin Oncol* 2012;30(26):3277–86 [10].
- [5] CTCAE4.02. Common Terminology Criteria for Adverse Events (CTCAE). Version 4.0. Published: May 28, 2009 (v4.02: Sept. 15, 2009). US Department of Health and Human Services.
- [6] Azzoli CG, Baker Jr S, Temin S, et al. American society of clinical oncology clinical practice guideline update on chemotherapy for stage IV non-small cell lung cancer. *J Clin Oncol* 2009;27:6251–66.
- [7] D'Addario G, Früh M, Reck M, et al. Non-small cell lung cancer: ESMO clinical recommendations for diagnosis, treatment and follow-up. *Ann Oncol* 2009;20(Suppl. 4):68–70.
- [8] Becher R, Schutt P, Oleska R. Peripheral neuropathy and ophthalmologic toxicity after treatment with cis-dichlorodiamminoplatinum. *J. Cancer Res Clin Oncol* 1980;96:219–21.
- [9] Ostrow S, Hahn D, Wiernik PH, et al. Ophthalmologic toxicity after cis-dichlorodiamminoplatinum(II) therapy. *Cancer Treat Rep* 1978;62:1591–4.
- [10] Walsh TJ, Clark AW, Parhad IM, et al. Neurotoxic effects of cisplatin therapy. *Arch Neurol* 1982;39:719–20.
- [11] Berman IJ, Mann MP. Seizures and transient cortical blindness associated with cisplatin therapy in a thirty year old man. *Cancer* 1980;45:764–6.
- [12] Pippit CH, Muss HB, Homesley HD, et al. Cisplatin-associated cortical blindness. *Gynecol Oncol* 1981;12:253–5.
- [13] Caraceni A, Martini C, Spatti G, et al. Recovering optic neuritis during systemic cisplatin and carboplatin chemotherapy. *Acta Neurol Scand* 1997;96:260–1.
- [14] Katz BJ, Ward JH, Digre KB, et al. Persistent severe visual and electroretinographic abnormalities after intravenous cisplatin therapy. *J Neuroophthalmol* 2003;23(2):132–5.
- [15] Imperia PS, Lazarus HM, Lass JH. Ocular complications of systemic cancer chemotherapy. *Surv Ophthalmol* 1989;34:209–30.
- [16] Kwan AS, Sahu A, Palaxes G. Retinal ischaemia with neovascularization in cisplatin related retinal toxicity. *Am J Ophthalmol* 2006;141(1):196–7.

- [17] Lauer AK, Wobig JL, Shults WT, et al. Severe ocular and orbital toxicity after intracarotid etoposide phosphate and carboplatin therapy. *Am J Ophthalmol* 1999;127:230–3.
- [18] O'Brien ME, Tonge K, Blake P, et al. Blindness associated with high dose carboplatin. *Lancet* 1992;339:558.
- [19] Rankin EM, Pitts JK. Ophthalmic toxicity during carboplatin therapy. *Ann Oncol* 1993;4:337–8.
- [20] Cloutier AO. Ocular side effects of chemotherapy: nursing management. *Oncol Nurs Forum* 1992;19(8):1251–9.
- [21] Hazin R, Abuzetun JY, Daoud YJ, et al. Ocular complications of cancer therapy: a primer for the ophthalmologist treating cancer patients. *Curr Opin Ophthalmol* 2009;20(4):308–17.
- [22] Eguia B, Ruppert AM, Fillon J, et al. Skin toxicities compromise prolonged pemetrexed treatment. *J Thorac Oncol* 2011;6(12):2083–92.
- [23] Matteucci P, Carlo-Stella C, Di Nicola M, et al. Topical prophylaxis of conjunctivitis induced by high-dose cytosine arabinoside. *Haematologica* 2006;91(2):255–7.
- [24] Banach MJ, Williams GA. Purtscher retinopathy and necrotizing vasculitis with gemcitabine therapy. *Arch Ophthalmol* 2000;118:726–7.
- [25] Tran TH, Desauw C, Rose C. Gemcitabine-induced retinopathy in a diabetic patient. *Acta Ophthalmol* 2008;87(1):114–5.
- [26] Esmaeli B, Hidaji L, Adinin RB, et al. Blockage of the lacrimal drainage apparatus as a side effect of docetaxel therapy. *Cancer* 2003;98:504–7.
- [27] Esmaeli B, Burnstine MA, Ahmadi MA. Docetaxel-induced histologic changes in the lacrimal sac and the nasal mucosa. *Ophthalm Plast Reconstr Surg* 2003;19:305–8.
- [28] Skolnick CA, Doughman DJ. Erosive conjunctivitis and punctal stenosis secondary to docetaxel (taxotere). *Eye Contact Lens* 2003;29:134–5.
- [29] Capri G, Munzone E, Tarenzi E, et al. Optic nerve disturbance: new form of paclitaxel neurotoxicity. *J Natl Cancer Inst* 1994;86:1099–101.
- [30] Seidman AD, Barrett S, Canezo S. Photopsia during 3-hour paclitaxel administration at dose > or = 250 mg/m². *J Clin Oncol* 1994;12:1741–2.
- [31] Kuznetcova T, Cech P, Herbot CP. The mystery of angiographically silent macular oedema due to taxanes. *Int Ophthalmol* 2012;32:299–304.
- [32] Georgakopoulos CD, Makri O, Vasilakis P, et al. Angiographically silent cystoid macular oedema secondary to paclitaxel therapy. *Clin Exp Optom* 2012;95:233–6.
- [33] Joshi MM, Garretson BR. Paclitaxel maculopathy (case report). *Arch Ophthalmol* 2007;125:709–10.
- [34] Fabre-Guillevin E, Tchen N, Anibali-Charpiat MF, et al. Taxane-induced glaucoma (case report). *Lancet* 1999;354:1181–2.
- [35] De Giorgi U, Acciarri R, Fiorentini G, et al. Glaucoma and paclitaxel (case report). *Lancet* 2000;355:231.
- [36] Van Bockxmeer FM, Martin CM, Thompson DE, et al. Taxol for the treatment of proliferative vitreoretinopathy. *Invest Ophthalmol* 1985;26:1140–7.
- [37] Yano S, Kondo K, Yamaguchi M, et al. Distribution and function of EGFR in human tissue and the effect of EGFR tyrosine kinase inhibition. *Anticancer Res* 2003;23:3639–50.
- [38] Breider MA. Irreversible inhibition of ErbB receptor family in rats results in epithelial atrophy and ulcerative dermatitis. *Pharmacol Exp Ther* 2000;41:493.
- [39] Tullo AB, Esmaeli B, Murray PI, et al. Ocular findings in patients with solid tumors treated with epidermal growth factor receptor tyrosine kinase inhibitor gefitinib (Iressa ZD1839) in Phase I and II clinical trials. *Eye* 2005;19:729–38.
- [40] Iressa (gefitinib) tablets (prescribing information), AstraZeneca Pharmaceuticals, 2005.
- [41] Tarceva (erlotinib) tablets (prescribing information), OSI Pharmaceuticals, Inc. and San Francisco, Calif: Genentech, Inc., 2005.
- [42] Shepherd FA, Rodrigues Pereira J, Ciuleanu T, et al. Erlotinib in previously treated non-small cell lung cancer. *N Engl J Med* 2005;353(2):123–32.
- [43] Solca F, Schweifer N, Baum A, et al. BIBW 2992, an irreversible dual EGFR/her2 kinase inhibitor that show activity on L858R/T790M EGFR mutants. In: Proceedings of the AACR-NCI-EORTC international conference on molecular targets and cancer therapeutics, Philadelphia, PA, November 14–18, 2005, 118 (abstr A242).
- [44] Li D, Ambrogio L, Shimamura T, et al. BIBW 2992, an irreversible dual EGFR/HER2 inhibitor highly effective in preclinical lung cancer models. *Oncogene* 2008;27:4702–11.
- [45] Sos ML, Rode HB, Heynck S, et al. Chemogenomic profiling provides insights into the limited activity of irreversible EGFR inhibitors in tumor cells expressing the T790M EGFR resistance mutation. *Cancer Res* 2010;70:868–74.
- [46] Miller VA, Hirsh V, Cadranell J, et al. Afatinib versus placebo for patients with advanced, metastatic non-small-cell lung cancer after failure of erlotinib, gefitinib, or both, and one or two lines of chemotherapy (LUX-Lung 1): a phase 2b/3 randomized trial. *Lancet Oncol* 2012;13(5):528–38.
- [47] Yang JCH, Shih JY, Su WC, et al. Afatinib for patients with lung adenocarcinoma and epidermal growth factor receptor mutations (LUX-Lung 2): a phase 2 trial. *Lancet Oncol* 2012;13:539–48.
- [48] Ranalingam SS, Blackhall F, Krzakowski M, et al. Randomized phase II study of dacomitinib (PF-00299804), an irreversible pan-human epidermal growth factor receptor inhibitor, versus erlotinib in patients with advanced non-small cell lung cancer. *J Clin Oncol* 2012;4(3):1–2 [Epub ahead of print].
- [49] Basti S. Ocular toxicities of epidermal growth factor receptor inhibitors and their management. *Cancer Nurs* 2007;30(4):S10–6.
- [50] Ciuleanu T, Stelmakh L, Cicens S, et al. Erlotinib versus docetaxel or pemetrexed as second-line therapy in patients with advanced non-small cell lung cancer (NSCLC) and poor prognosis: efficacy and safety results from the Phase III TITAN study. *Lancet Oncol* 2012;13(3):300–8.
- [51] Rosell R, Carcereny E, Gervais R, et al. Erlotinib versus standard chemotherapy as first-line treatment for european patients with advanced EGFR mutation-positive non-small cell lung cancer (EURTAC): a multicentre, open-label, randomized Phase 3 trial. *Lancet Oncol* 2012;13(3):239–46.
- [52] Cappuzzo F, Ciuleanu T, Stelmakh L, et al. Erlotinib as maintenance treatment in advanced non-small cell lung cancer: a multicentre, randomized, placebo-controlled, phase 3 study. *Lancet Oncol* 2010;11(6):521–9.
- [53] Fukuoka M, Yano S, Giaccone G, et al. Multi-institutional randomized phase II trial of gefitinib for previously treated patients with advanced non-small cell lung cancer (The IDEAL 1 Trial). *J Clin Oncol* 2004;22(23):4811–20.
- [54] Mok TS, Wu YL, Au JS, et al. Efficacy and safety of erlotinib in 1,242 East/South-east Asian patients with advanced non-small cell lung cancer. *Thorac Oncol* 2010;5(10):1609–15.
- [55] Thatcher N, Chang A, Parikh P, et al. Gefitinib plus best supportive care in previously treated patients with refractory advanced non-small cell lung cancer: results from a randomized, placebo-controlled, multicentre study (Iressa survival evaluation in lung cancer). *Lancet* 2005;366(9496):1527–37.
- [56] Goss G, Ferry D, Wierzbicki R, et al. Randomized phase II study of gefitinib compared with placebo in chemotherapy-naïve patients with advanced non-small cell lung cancer and poor performance status. *J Clin Oncol* 2009;27(13):2253–60.
- [57] Mok TS, Wu YL, Thongprasert S, et al. Gefitinib or carboplatin-paclitaxel in pulmonary adenocarcinoma. *N Engl J Med* 2009;361:947–57.
- [58] Kim ES, Hirsh V, Mok TS, et al. Gefitinib versus docetaxel in previously treated non-small cell lung cancer (INTEREST): a randomized Phase III trial. *Lancet* 2008;372(9652):1809–18.
- [59] Han JY, Park K, Kim SW, et al. First-SIGNAL: first-line single-agent iressa versus gemcitabine and cisplatin trial in never-smokers with adenocarcinoma of the lung. *J Clin Oncol* 2012;30(10):1122–8.
- [60] Maemondo M, Inoue A, Kobayashi K, et al. Gefitinib or chemotherapy for non-small cell lung cancer with mutated EGFR. *N Engl J Med* 2010;362(25):2380–8.
- [61] Mitsudomi T, Morita S, Yatabe Y, et al. Gefitinib versus cisplatin plus docetaxel in patients with non-small cell lung cancer harbouring mutations of the epidermal growth factor receptor (WJTOG3405): an open-label, randomized, phase 3 trial. *Lancet Oncol* 2010;11(2):121–8.
- [62] Ranson M, Hammond LA, Ferry D, et al. ZD1839, a selective oral epidermal growth factor receptor-tyrosine kinase inhibitor, is well tolerated and active in patients with solid, malignant tumors: results of a phase I trial. *J Clin Oncol* 2002;20:2240–50.
- [63] Baselga J, Rischin D, Ranson M, et al. Phase I safety, pharmacokinetic and pharmacodynamic trial of ZD1839, a selective oral epidermal growth factor receptor tyrosine kinase inhibitor, in patients with five selected solid tumor types. *J Clin Oncol* 2002;20:4292–302.
- [64] Perez-Soler R, Chachoua A, Hammond LA, et al. Determinants of tumor response and survival with erlotinib in patients with non-small cell lung cancer. *J Clin Oncol* 2004;22(16):3238–47.
- [65] Camidge DR, Bang Y, Kwak EL, et al. Progression-free survival (PFS) from a phase I study of crizotinib (PF-02341066) in patients with ALK-positive non-small cell lung cancer (NSCLC) [abstract no. 2501]. *J Clin Oncol* 2011; 29 Suppl. plus oral presentation at the 47th Meeting of the American Society of Clinical Oncology; 2011 Jul 3–7; Chicago (IL).
- [66] Kim DW, Blackhall F, Soria JC, et al. A global phase 2 study including efficacy, safety, and patient-reported outcomes with crizotinib in patients with AL-positive non-small cell lung cancer [abstract no. 9084 plus oral presentation]. *European Multidisciplinary Cancer Congress*; 2011 Sep 23–27; Stockholm.
- [67] Kwak EL, Bang YJ, Camidge DR, et al. Anaplastic lymphoma kinase inhibition in non-small cell lung cancer. *N Engl J Med* 2010;363(18):1693–703 [28].
- [68] Adjei AA, Cohen RB, Franklin W, et al. Phase I pharmacokinetic and pharmacodynamic study of the oral, small-molecule mitogen-activated protein kinase 1/2 inhibitor AZD6244 (ARRY-142886) in patients with advanced cancers. *J Clin Oncol* 2008;26:2139–46.
- [69] Banerji U, Camidge DR, Verheul HM, et al. The first-in-human study of the hydrogen sulfate (Hyd-sulfate) capsule of the MEK1/2 inhibitor AZD6244 (ARRY-142886): a phase I open-label multicenter trial in patients with advanced cancer. *Clin Cancer Res* 2010;16:1613–23.
- [70] Hainsworth JD, Cebotaru CL, Kanarev V, et al. A phase II, open-label, randomized study to assess the efficacy and safety of AZD6244 (ARRY-142886) versus pemetrexed in patients with non-small cell lung cancer who have failed one or two prior chemotherapeutic regimens. *J Thorac Oncol* 2010;5:1630–6.
- [71] Janne PA, Shaw AT, Rodrigues Pereira J, Jeannin G, et al. Selumetinib plus docetaxel for KRAS-mutant advanced non-small cell lung cancer: a randomised, multicentre, placebo-controlled, phase 3 study. *Lancet Oncol* 2013;14:38–47.
- [72] Shapiro GI. Cyclin-dependent kinase pathways as targets for cancer treatment. *J Clin Oncol* 2006;24(11):1770–83.
- [73] Benson C, Kaye S, Workman P, et al. Clinical anticancer drug development: targeting the cyclin-dependent kinases. *Br J Cancer* 2005;92(1):7–12.
- [74] Investigator Brochure for PHA-848125AC, Version 7. Nerviano Medical Sciences; 2011. Document no. CDKO-125a-IB7.