

A possible role of inner ear melanocytes in tinnitus and audiovestibular disorders



S. Barozzi¹, D. Ginocchio¹, L. Del Bo²

¹Dept. of Clinical Sciences and Community Health, Università degli Studi, Milano, Italia

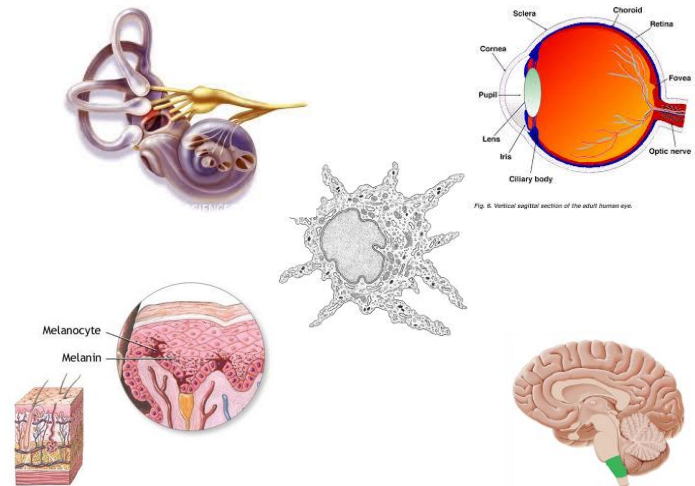
²Fondazione Ascolta e Vivi, Milano, Italia



Melanocytes: their role in the inner ear

Melanocytes are present in the skin and hair follicles, as well as in the eye, the leptomeninges, the anal canal and the inner ear.

In the *inner ear*, melanocytes are present both in the cochlea and in the vestibular organs. In the *cochlea* melanocytes have been identified in the intermediate layer of the stria vascularis; they are essential in regulating the integrity of the barrier and maintaining normal hearing thresholds. In mice, their depletion causes a substantial reduction in endocochlear potentials accompanied by significant hearing loss¹. In the *vestibular labyrinth*, melanocytes are subepithelially located in the dark-cell areas, at the base of the cristae ampullaris in each semicircular canal and in the utricular wall. They are mainly involved in the ion and material transport necessary for the maintenance of normal volumes and ion concentration of the inner ear fluids. In individuals with Ménière's disease, Masutani et al. reported a reduced density and morphological abnormalities of the dark cells in the semicircular canals².



Immunotherapy for melanoma and audiovestibular symptoms

Recently, audiovestibular dysfunctions have been demonstrated in patients treated with immunotherapy for metastatic melanoma.

Yeh et al. illustrated the case of a man with a history of metastatic melanoma who manifested ocular, cutaneous and audiological symptoms resembling Vogt-Koyanagi-Harada syndrome after successful immunotherapy³.

Seaman et al.⁴ reported audiovestibular dysfunctions in patients treated for melanoma with adoptive cell immunotherapy: 17 out of the 32 patients suffered from a mild/moderate hearing loss and 7 had vestibular complaints ranging from minor dizziness to severe oscillopsia and imbalance.

Audiological abnormalities related to melanocyte disorders

Waardenburg syndrome	Autosomal dominant disorder; sensorineural hearing loss, heterochromia iridis and patchy abnormal depigmentation of hair and skin.
Vogt-Kayanagi-Harada disease	Multisystem autoimmune disorder; panuveitis, headache, skin vitiligo, alopecia and inner ear disturbances.
Birdshot retinochoroidopathy	Rare autoimmune disease; posterior uveitis. A fluctuating hearing loss has been described.
Vitiligo and Alopecia areata	Audiological abnormalities have been reported.

A Clinical Case

Exacerbation of audiovestibular symptoms in a patient with Ménière's disease and choroidal melanoma

Recently, we reported the case of a patient in whom the appearance of a choroidal melanoma coincided with the exacerbation of tinnitus and vertigo spells in a unilateral Ménière's disease that had been clinically silent for more than ten years⁵.

The symptoms disappeared after the radiotherapy treatment and did not show up again during the following three years.

References

- Zhang W, Dai M, Fridberger A et al. Perivascular-resident macrophage-like melanocytes in the inner ear are essential for the integrity of the intrastrial fluid-blood barrier. *Proc Natl Acad Sci U S A*. 2012;109(26):10388-10393.
- Masutani H, Takahashi H, Sando I. Dark cell pathology in Ménière's disease. *Acta Otolaryngol*. 1992;112(3):479-85.
- Yeh S, Karne NK, Kerkar SP et al. Ocular and systemic autoimmunity after successful tumor-infiltrating lymphocyte immunotherapy for recurrent, metastatic melanoma. *Ophthalmology* 2009;116(5):981-989.
- Seaman BJ, Guardiani EA, Brewer CC et al. Audiovestibular dysfunction associated with adoptive cell immunotherapy for melanoma. *Otolaryngol Head Neck Surg*. 2012;147(4):744-749.
- Barozzi S, Ginocchio D, Cesarani A. Exacerbation of audiovestibular symptoms in a patient with Ménière's disease and choroidal melanoma. *Am J Otolaryngol*. 2014 Sep-Oct;35(5):676-7

Discussion

A melanoma is an immunogenic tumor, frequently associated with spontaneous autoimmune manifestations such as spontaneous regression, vitiligo-like reactions or auto-immune retinopathy (melanoma associated retinopathy).

We suggest that inner ear melanocytes could be a target of an autoimmune process in patients affected by melanoma. The immune system could produce antibodies that cross-react with both the melanoma cells and the labyrinth melanocytes, causing an altered homeostasis of endolymphatic liquids. The supposed autoimmune reaction might provoke some labyrinthic disorders such as vertigo, hearing loss, aural fullness and tinnitus resembling or influencing Ménière's disease. In this perspective, audiovestibular disorders could be interpreted as an attempt by the individual immune system to develop anti-tumoral response.

Conclusion

A possible role of inner ear melanocytes should be considered as a potential cause of labyrinthic disorders. Audiovestibular symptoms could be part of a systemic autoimmune process in patients with melanoma, as well as ocular symptoms in melanoma associated retinopathy.

