

ORIGINAL PAPER

VALUE OF PERFUSION CT PARAMETERS, MICROVESSEL DENSITY AND VEGF EXPRESSION IN DIFFERENTIATION OF BENIGN AND MALIGNANT PROSTATE TUMOURS

ELZBIETA LUCZYNSKA¹, ANNA GASINSKA², PAWEL BLECHARZ³, ANDRZEJ STELMACH⁴,
BARBARA ALICJA JERECZEK-FOSSA^{5,6}, MARIAN REINFUSS⁷

¹Radiology Department, Center of Oncology, M. Sklodowska-Curie Memorial Institute, Cracow Branch, Krakow, Poland

²Clinical Radiobiology Department, Center of Oncology, M. Sklodowska-Curie Memorial Institute, Cracow Branch, Krakow, Poland

³Gynecologic Oncology Department, Center of Oncology, M. Sklodowska-Curie Memorial Institute, Cracow Branch, Krakow, Poland

⁴Surgery Department, Center of Oncology, M. Sklodowska-Curie Memorial Institute, Cracow Branch, Krakow, Poland

⁵Radiotherapy Department, European Institute of Oncology, Milan, Italy

⁶University of Milan, Milan, Italy

⁷Radiotherapy Department, Center of Oncology, M. Sklodowska-Curie Memorial Institute, Cracow Branch, Krakow, Poland

The purpose of this study was to assess the correlation between parameters evaluated using computed tomography perfusion (CTP) and microvessel density (MVD), the vascular endothelial growth factor labelling index (VEGFLI), as well as known clinicopathological indicators of tumour malignancy, in non-advanced prostatic cancer.

We included 110 patients with early stage prostate cancer who were subjected to CT examinations followed by radical prostatectomy between 2007 and 2011 (in this analysis we included only patients diagnosed with CT). Both in affected and in healthy tissue the following perfusion parameters were assessed: blood flow (BF), blood volume (BV), mean transit time (MTT) and permeability-surface area product (PS). After surgery in the resected prostate tumour tissue the MVD and VEGFLI were assessed.

The mean BF and PS values were significantly higher in carcinomas with high histological grade ($p = 0.02$). The sensitivity, specificity and accuracy of the threshold BF value, for the distinction between malignant and healthy prostate tissue, were: 67%, 54% and 59% respectively. For BV sensitivity was 71%, specificity was 52%, and accuracy was 48%. Microvessel density significantly correlated with BV, MTT and PS ($p < 0.05$), while VEGFLI did not correlate with any of the perfusion parameters.

Our results suggest that BF and PS might be helpful in discrimination between benign and malignant prostate tissue, while the positive correlation between BV, MTT, PS and MVD might suggest their potential utility in assessment of cancer angiogenesis.

Key words: perfusion computed tomography, prostate cancer, microvessels, vascular endothelial growth factor.

Introduction

Prostate cancer is a biologically heterogeneous disease. Many patients with localized, slow-growing cancers survive for a long time even in the absence of therapy, while others develop metastases despite apparently organ-confined disease and application of local therapy [1, 2].

Prostate biopsy is still considered the gold standard for diagnosis of prostate cancer. The question arises, whether conventional procedures, such as computed tomography (CT) and magnetic resonance imaging (MRI) as well as transrectal ultrasound (TRUS), which have not yet been proven reliable in the diagnosis of prostate cancer [3], might be of diagnostic value in the future.

The development of prostate cancer is a multi-step process, advancing from high-grade prostatic intraepithelial neoplasia (PIN) to focal carcinoma, invasive carcinoma, and finally to metastatic disease. Therefore the planning of future therapies should involve targeting the molecules, that are related to events associated with each step of progression. One of such events is angiogenesis – a very complicated process requiring extensive interactions between cells (cancer, epithelial and immune cells), cytokines, and extracellular matrix components [4-6]. Studies have demonstrated that the expression of factors stimulating angiogenesis, such as vascular endothelial growth factor (VEGF), platelet-derived growth factor (PDGF), and transforming growth factor (TGF), are increased in prostate carcinoma [7, 8]. Moreover, it has been shown that there is a progressive increase in angiogenesis as prostate cancer advances through various pathologic stages.

There are many parameters associated with the process of angiogenesis which may be evaluated in tumours. One of such parameter is microvascular density (MVD) [9]. This parameter can be assessed based on the expression of CD34 or CD31 on the endothelial cells of the blood vessels. On the other hand the expression of VEGF might be an indicator of intensity of neoangiogenesis [10]. Apart from providing information on tumour invasiveness, these markers have been used to choose the appropriate anti-angiogenic therapy [11].

Functional CT is a high spatial resolution technique for assessing tumour neovasculature, but the signal-to-noise ratio remains poor as compared with MRI [12]. In oncology, CTP is a recognized method for the assessment of tumour vascularity. This method allows the evaluation of capillaries' permeability based on the permeability coefficient (PS). Therefore it is believed that, CTP can reflect tumour microvascular density [13].

In many types of tumour, a correlation has been noted between perfusion parameters in CT and angiogenesis markers assessed in the tumour [14].

However, these relationships are poorly understood in prostate cancer. Recently, Osimani *et al.* [15] found a positive correlation between MVD and CTP parameters. On the other hand the correlation between VEGF expression and the aforementioned parameter has not been studied so far, and hence remains unknown.

Therefore, the purpose of the present study was to assess of the correlation between CTP parameters and MVD or VEGF as well as the relationship between all the above-mentioned parameters and known clinicopathological indicators of tumour malignancy. We would like to determine whether CTP, which is less invasive than tumour biopsy, could be helpful in distinguishing between benign and malignant prostate tissue as well as between less and more malignant prostate carcinomas.

Material and methods

Patients

One hundred and ten patients with early stage prostate cancer, who had been diagnosed using TRUS/BGI between 2007 and 2011 were included in the present study. All patients were subjected to radical prostatectomy which consisted of removal of prostate and seminal vesicles within 2 to 4 weeks after the CT test. The mean age of patients was 62.7 ± 6.4 years.

Clinical staging was carried out according to the American Joint Committee on Cancer (AJCC) and the International Union Against Cancer. Grading was established based on the Gleason score (GS) differentiation system (range 2-10) [16], independently by two experienced pathologists. Patients were divided into three Gleason score groups following the criteria defined by the AJCC: well differentiated tumours (Gleason score ≤ 6), moderately differentiated tumours (Gleason score of 7) and poorly differentiated tumours (Gleason score 8-10) [17]. Clinical characteristics of the group are presented in Table I.

The protocol was approved by the local bioethical committee and every patient submitted written consent.

Computed tomography examination

Computed tomography examinations were performed with a 16-section multidetector CT (MDCT) scanner (LightSpeed 16; GE Healthcare, Milwaukee, Wis). Preliminary non-contrast CT of the pelvis (5-mm thickness) was performed to locate the prostate. The total area of examination was 4 cm. After detecting the centre of the prostate gland, 50 ml of contrast medium was administered and a scan was performed 2 cm upwards, followed by a second injection of 50 ml and a scan of 2 cm downwards. A total of 100 ml of nonionic iodinated contrast material was injected (Ultravist 370 mg I/ml; Bayer Schering Pharma, Germany) followed by 50 ml of saline solution at

Table I. The relationship between evaluated perfusion parameters, microvessel density (MVD) and VEGRLI expression in relation to clinical and histological features of prostate cancer

PARAMETER	TOTAL	BF (ML/MIN/100 G) MEAN ± SE	BV (ML/100 G) MEAN ± SE	MTT (s) MEAN ± SE	PS (ML/MIN/100G) MEAN ± SE	MVD MEAN ± SE	VEGRLI MEAN ± SE
Tumors	110	43.9 ± 1.2	5.0 ± 0.2	8.2 ± 0.2	31.7 ± 1.2	100.1 ± 2.7	14.8 ± 1.4
Normal tissue	110	25.2 ± 0.9	2.4 ± 0.1	6.5 ± 0.1	19.6 ± 0.9	–	–
p-value ¹		0.00	0.00	0.00	0.00	–	–
Degree of histological malignancy							
G1	65	42.0 ± 1.5	4.7 ± 0.2	8.1 ± 0.2	30.2 ± 1.7	99.9 ± 3.6	16.2 ± 2.0
G2	39	45.1 ± 1.8	5.4 ± 0.3	8.4 ± 0.2	32.9 ± 1.7	102.0 ± 4.6	13.1 ± 2.6
G3	6	56.7 ± 8.7	5.0 ± 0.6	8.4 ± 0.2	40.1 ± 6.0	90.4 ± 3.8	15.8 ± 4.6
p-value ²		0.02	0.2	0.55	0.14	0.65	0.62
pTNM							
1	8	51.9 ± 7.2	4.5 ± 0.4	8.0 ± 0.5	34.9 ± 5.5	99.7 ± 7.1	10.7 ± 1.9
2	66	42.4 ± 1.5	4.9 ± 0.2	8.1 ± 0.2	29.2 ± 35.7	97.6 ± 3.0	14.4 ± 2.1
3	31	44.9 ± 2.1	5.4 ± 0.3	8.4 ± 0.2	35.7 ± 2.2	107.0 ± 6.3	17.0 ± 2.7
4	5	44.2 ± 5.7	4.9 ± 0.6	8.0 ± 0.3	35.0 ± 5.1	90.0 ± 17.8	19.1 ± 6.8
p-value ²		0.24	0.45	0.84	0.09	0.91	0.70

¹probability of difference between mean value depend on T-test for dependent samples

²probability of difference between mean value depend on ANOVA test

BF – blood flow, BV – blood volume, MTT – mean transit time, PS – permeability-surface area product, MVD – microvessel density, VEGFLI – vascular endothelial growth factor labelling index

a rate of 5 ml/s via an 18-gauge cannula, which was placed in the right antecubital vein in all the patients to exclude any source of variability. Computed tomography perfusion scanning started 5 seconds after contrast administration, with the following parameters: 4 contiguous 5-mm reconstructed sections at a constant table position, 1-second gantry rotation time, 80 kVp and 180 mA. Images were acquired every second for 50 seconds.

Immediately after completion of CTP scanning, MDCT of the abdomen and pelvis was performed by using 16 × 0.625 mm collimation; 1.25 mm section thickness and increment; rotation time 0.6 s; speed 9.38 mm/rotation; FOV 18 cm; intravenous contrast material (Ultravist 370 mg I/ml; Bayer Schering Pharma, Germany); 1.5 ml/kg at an injection rate of 2 ml/s; acquisition delay 70 s.

The obtained images were anonymized and transferred to an image-processing workstation (Advantage Windows 4.2, GE Healthcare). Computed tomography perfusion data was analyzed by two radiologists working separately (EL and STD) with 4 and 3 years of experience in CTP imaging respectively. Commercially available software (CT Perfusion 4, GE Healthcare) was used for analysis, using a deconvolution-based technique. The arterial input was obtained from a standardized place in the region of the external iliac artery (EIA), with selection of the

section that allowed for best visualization in order to avoid partial volume artefacts. A time-attenuation curve, expressed in HU/s, was automatically generated by the software for the arterial input; its geometric evaluation allowed readers to assess the timing of the CTP scans in each patient, excluding any early enhancement, identifying correctly the end of the first pass of contrast material, and excluding any recirculation effect in the CTP measurements.

Functional maps of blood flow (BF), blood volume (BV) and mean transit time (MTT) were generated according to the central volume principle, which relates BF, BV, and MTT by the equation: $BF = BV / MTT$ [18].

Regions of interest (ROI) were manually drawn along the visible margins of the obvious prostate cancer in all sections in which cancer was visible and saved for each patient. Mean values of perfusion parameters were then calculated for each patient in tumour and healthy tissue separately. For display purposes, the functional maps were presented in coloured images (Fig. 1).

Immunohistochemical assessment of parameters associated with tumour angiogenesis

Immunohistochemistry was performed on formalin-fixed, paraffin-embedded tissue sections (5 μm

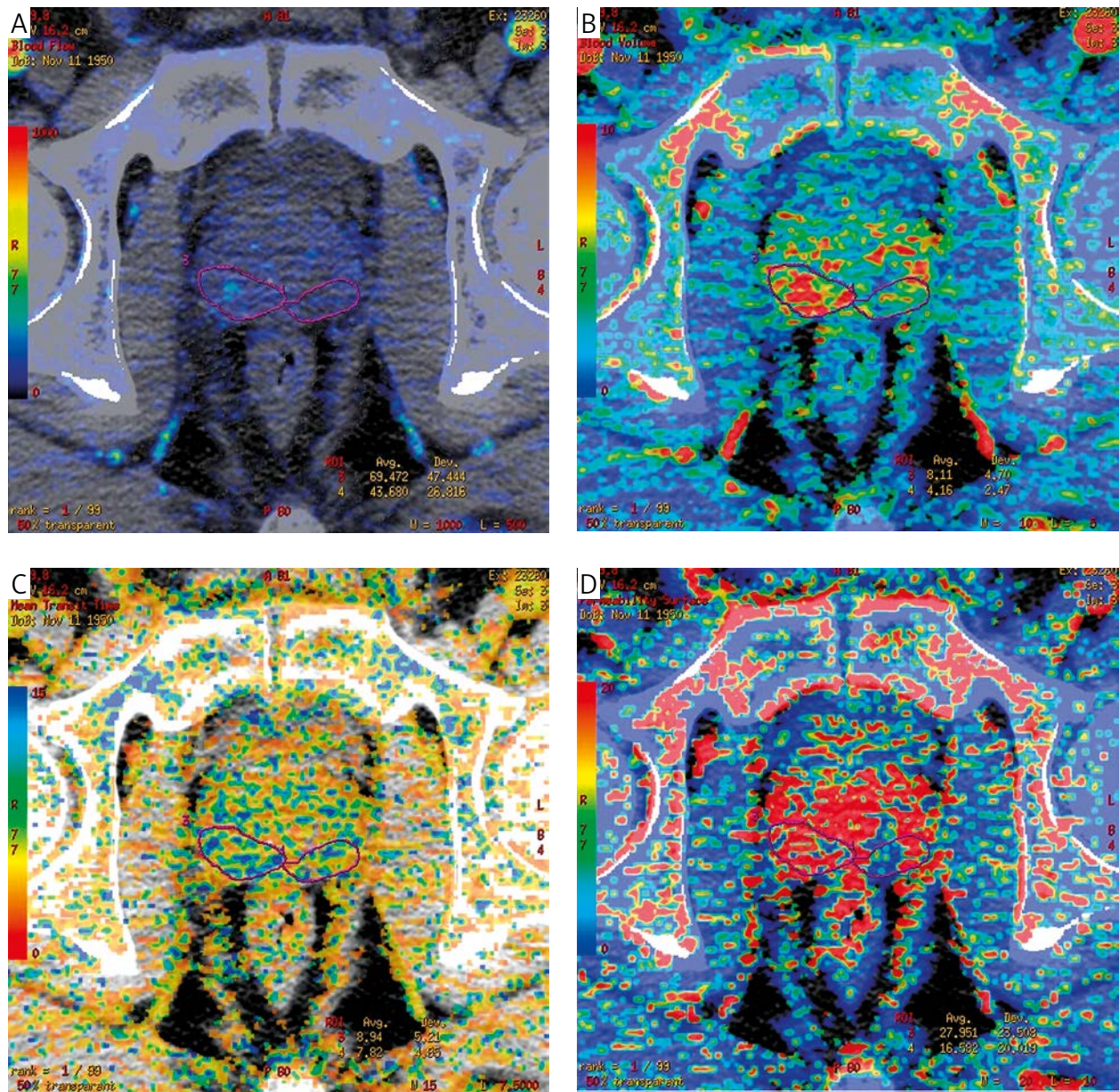


Fig. 1. Perfusion maps: blood volume BV (A), blood flow BF (B), mean transit time MTT (C) and permeability surface PS (D). In all presented maps the right ROI represents manually outlined enhancement (prostate cancer). The left ROI represents normal prostatic tissue

thick). For antigen unmasking, after deparaffinization and rehydration, we applied heating of slides in Target Retrieval Solution (TRS) (DakoCytomation Denmark A/S, Glostrup, Denmark): (i) for VEGF – pH 9, temperature 95-99°C, 20 min., (ii) for CD34 – pH 6, temperature 95-99°C, 40 min. For quenching of the activity of endogenous peroxidases, slides were incubated in 0.3% H₂O₂ diluted in methanol for 20 min. Then, after 20 min. incubation with 10% normal goat serum, sections were incubated overnight at 4°C with: (i) anti-CD34 mouse anti-human monoclonal antibody, diluted 1 : 200, (ii) anti-VEGF a mouse monoclonal antibody, diluted 1 : 25 (DakoCytomation Denmark A/S, Glostrup, Denmark). Visualization was

carried out using: DAKO EnVision visualisation system (37°C, 1 h incubation), and VECTOR ImmPRESS Reagent Kit, for CD34 and VEGF respectively. Finally, the sections were incubated with 3,3'-diaminobenzidine (DAB) and counterstained with hematoxylin. For the negative control primary antibodies were omitted.

Cytoplasmic VEGF expression was counted as percentage of positively immunostained cells in 500-1000 tumour cells (VEGF labelling Index – VEGFLI).

Microvascular density (MVD) was assessed in 7-10 tumour fields (0.292 mm²), and expressed as the mean number of vessels per 1 mm². Both individual CD34-immunopositive endothelial cells and large vessels with lumen were included.

Statistical analysis

A one-sided Student's *t*-test (2 groups) and ANOVA (for a larger number of groups) were used to analyse differences in mean values of continuous (perfusion parameters, MVD and VEGFLI) and categorical variables (grade and TNM). Pearson's correlation coefficient was applied to measure of the strength and direction of the linear relationship between two continuous variables. A Receiver Operating Characteristic (ROC) analysis was conducted to find which perfusion parameters reveal the best diagnostic accuracy level in tumour staging differentiation. The size of the area under the ROC curve was examined using the Z-test. The limit of statistical variation was accepted at the level of $p < 0.05$. The calculations were performed using the STATISTICA 10.0 software (StatSoft, Inc., Tulsa, OK, USA).

Results

Perfusion computed tomography results

The mean values of perfusion parameters for prostate cancer and normal tissue are presented in Table I. Significantly higher values of BF, BV, MTT and PS were found for tumours than for normal tissue

($p < 0.05$) (Table I). All perfusion parameters were correlated with each other ($p < 0.05$), apart from BF and MTT (Table II).

The mean value of BF was significantly lower in low grade than in high grade carcinomas (Table I, $p < 0.05$). Similarly, the mean values of PS were lower for the G1 tumours than for G3 tumours, but this difference did not reach statistical significance (Table I). On the other hand no difference between the mean values of BV or MTT and tumour histological grading were observed ($p > 0.05$) (Table I).

The ROC curve analysis showed that BF and BV may be used to distinguish between well-, moderately and poorly differentiated tumours (Table III). The areas under the ROC curve (AUC) in these cases were significantly higher than 0.5 ($p = 0.05$ for BF and 0.01 for BV) and therefore 0.6 ml/min/100 g for BF and 0.62 ml/100 g for BV may be used as a classifiers for prostate tissues of different degree of malignancy (Table III).

In the case of BF, the threshold value for more and less aggressive tumours was 41.7 ml/min/100 g, with the test sensitivity of 67%, specificity 54% and accuracy 59%. In the case of BV, the optimal threshold value was 4.55 ml/100 mg, with 71% sensitivity, 52% specificity and 48% accuracy (Fig. 2). In

Table II. The correlation between microvessel density, VEGF expression and perfusion parameters in prostate cancer

	BV (ML/100 G)	MTT (s)	PS (ML/MIN/100 G)	MVD	VEGRLI
BF	$p = 0.000$ $r = 0.61$	$p = 0.515$ $r = 0.06$	$p = 0.000$ $r = 0.56$	$p = 0.290$ $r = 0.10$	$p = 0.795$ $r = 0.03$
BV		$p = 0.000$ $r = 0.58$	$p = 0.000$ $r = 0.55$	$p = 0.035$ $r = 0.20$	$p = 0.155$ $r = 0.14$
MTT			$p = 0.001$ $r = 0.30$	$p = 0.026$ $r = 0.21$	$p = 0.288$ $r = 0.10$
PS				$p = 0.022$ $r = 0.22$	$p = 0.616$ $r = 0.05$
MVD					$p = 0.761$ $r = 0.03$

r – coefficients of correlation; *p* – probability

BF – blood flow, BV – blood volume, MTT – mean transit time, PS – permeability-surface area product, MVD – microvessel density, VEGFLI – vascular endothelial growth factor labelling index

Table III. The results of the ROC curve analysis

	BF (ML/MIN/100 G)	BV (ML/100 MG)	MTT (s)	PS (ML/MIN/100 G)
The area under the curve	0.60 ± 0.06	0.62 ± 0.05	0.58 ± 0.06	0.57 ± 0.06
AUC ± SE				
p	0.05	0.01	0.09	0.12
Threshold value	41.7	4.55	8.71	20.71

BF – blood flow, BV – blood volume, MTT – mean transit time, PS – permeability-surface area product, MVD – microvessel density

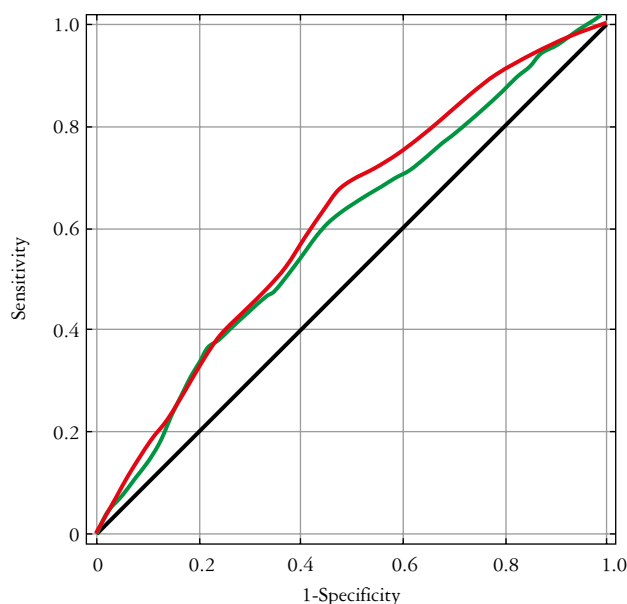


Fig. 2. The ROC curves for PC perfusion parameters: BF (green colour); BV (red colour); reference line (black colour). The relationship between sensitivity and specificity of the parameters was shown

the case of MTT and PS, no cut-off values have been obtained both for either well differentiated or poorly differentiated tumours.

The correlation between perfusion computed tomography results and tumour vascular density and expression of VEGF

In the analysed group of tumours, mean microvessel density was 100.1 ± 2.7 vessels/mm², while the mean value of VEGFLI was 14.8 ± 1.4 . No correlation was found between MVD and VEGFLI (Table II, $p > 0.05$).

Microvessel density and VEGFLI were correlated neither with TNM nor with grade (Table I, $p > 0.05$).

The tumour MVD was significantly positively correlated with BV, MTT and PS ($p < 0.05$, Table II). Correlation coefficients were 0.20, 0.21 and 0.22 for BV, MTT and PS respectively (Table II). There was no correlation between microvessel density and BF ($p > 0.05$, Table II). The immunohistochemical expression of VEGF protein did not correlate with any of the perfusion parameters ($p > 0.05$) (Table III).

Discussion

In the case of prostate cancer MRI is a gold diagnostic standard. On the other hand computed tomography (CT) was not considered as such, and hence in the literature there are few reports referring to application of this method in prostate cancer.

Application of a 64-section MDCT scanner in PCT of patients with prostate carcinoma, by Osimani *et al.* [15] confirmed that, PCT parameters correlate

well with microvessel density. Moreover, by applying the above-mentioned technique, the authors [15] obtained the visualization of malignant foci in 22 from 24 tumours, and demonstrated substantial differences in mean values of BV, MTT and PS between prostate cancer, benign prostatic hyperplasia (BPH) chronic prostatitis and healthy tissue. The ROC curve showed 100% sensitivity and specificity for BV and MTT to discriminate benign and malignant lesions of the prostate gland [15].

Similarly to the aforementioned results, but in a larger patients' group (110 patients) we observed: significant differences between mean values of BV, BF, MTT and PS in normal tissue and prostate cancer, a significant positive correlation between BV, MTT and PS and MVD, and additionally a relationship between BF and grade. Blood flow and BV may be used to distinguish between well-, moderately and poorly differentiated tumours. This result suggests that, all the above-mentioned CTP parameters may be of diagnostic, prognostic and predictive value.

A increase in BF values, described by us in neoplastic tissue compared to healthy areas, may be explained by the opening of arterio-venous collateral circulation within the tumour. These branches are characterized by low resistance to the changes in blood pressure, which results in an increase in the blood flow within the capillaries [19, 20].

A higher BV value in the tumour than in healthy tissue may reflect increased microvasculature due to formation of new vessels [21]. This hypothesis might be confirmed by the correlation between BV and MVD, which was found in the present study.

Lastly, a higher PS value in the tumour than in healthy tissue as well as its correlation with MVD, could be indicator of greater permeability of the wall of the newly formed vessels compared with the normal microvasculature. In 2010, Bellomi [14] wrote that "if CTP were able to reliably identify foci in the prostate, it would theoretically be possible to target radiation therapy and minimize radiation dose to surrounding healthy tissue" [22, 23].

As described before, similarly to Osimani *et al.* [15] we found a significant correlation between microvascular density and three parameters assessed in CTP: BV, MTT and PS. This result might suggest that CTP is useful in assessment of prostate cancer angiogenesis (the process of tumour-induced growth of new blood vessels) and an important factor indicating disease-specific survival and the risk of progression after therapy [24-26].

The predictive value of CTP parameters is highly possible because differences in vascular permeability and architecture between tumour and normal tissues (detected with CTP) may contribute to differences in oxygenation or gene expression and therefore influ-

ence the response to an anti-cancer therapy (radiotherapy, chemotherapy, targeted therapy etc.) [27-29].

In our study BV and PS not only allowed for distinguishing between affected and normal tissue, but also significantly correlated with MVD and insignificantly increased with high histological grade. Hence, both BV and PS seem to be the important perfusion parameters in prostate cancer, which are not only potential diagnostic parameters but also indicators of tumour angiogenesis and malignancy.

The MTT is the least useful parameter. This indicates that cell division entails the formation of elongated vascular shoots, whose ends join together to form capillary loops. The endothelial cells in newly created vascular loops of tumour have abnormal shape and size. They have wide intercellular connections, are irregular and have a leaky basement membrane. The above-mentioned hypothesis might be confirmed by correlation between MTT and MVD [30], which was noted in our study.

High BF values, which were significantly related to high histological grade, but not correlated with MVD, might have a diagnostic utility, be a marker of tumour malignancy, but not an indicator of tumour angiogenesis.

Conclusions

1. Based on CTP parameters it is possible to reveal neoplastic foci within the prostate. Hence the application of this method will allow for diagnosis of prostate cancer and for focusing of radiotherapy into the foci and sparing healthy tissue.
2. Existence of a positive correlation between MVD and BV, MTT and PS, as well as relationship between high BF and high tumour grade may facilitate pretreatment indication of more aggressive carcinomas and hence, application of more aggressive treatment schedules/targeted therapies/anti-vascular therapy.

The authors declare no conflict of interest.

References

1. Albertsen PC, Hanley JA, Penson DE, Fine J. Validation of increasing prostate specific antigen as a predictor of prostate cancer death after treatment of localized prostate cancer with surgery or radiation. *J Urol* 2004; 171 (6 Pt 1): 2221-2225.
2. Bill-Axelsson A, Holmberg L, Ruutu M, et al. Radical prostatectomy versus watchful waiting in early prostate cancer. *N Engl J Med* 2005; 352: 1977-1984.
3. Heidenreich A, Aus G, Bolla M, et al. EAU guidelines on prostate cancer. *Eur Urol* 2008; 53: 68-80.
4. Sotomayor P, Godoy A, Smith GJ, Huss WJ. Oct4 A is expressed by a subpopulation of prostate neuroendocrine cells. *Prostate* 2009; 69: 401-410.
5. Folkman J. Angiogenesis-dependent diseases. *Semin Oncol* 2001; 28: 536-542.
6. Liekens S, De Clercq E, Neyts J. Angiogenesis: regulators and clinical applications. *Biochem Pharmacol* 2001; 61: 253-270.
7. Bostwick DG, Pacelli A, Blute M, et al. Prostate specific membrane antigen expression in prostatic intraepithelial neoplasia and adenocarcinoma: a study of 184 cases. *Cancer* 1998; 82: 2256-2261.
8. Lissbrant IF, Lissbrant E, Damber JE, Bergh A. Blood vessels are regulators of growth, diagnostic markers and therapeutic targets in prostate cancer. *Scand J Urol Nephrol* 2001; 35: 437-452.
9. de la Taille A, Katz AE, Bagiella E, et al. Microvessel density as a predictor of PSA recurrence after radical prostatectomy. A comparison of CD34 and CD31. *Am J Clin Pathol* 2000; 113: 555-562.
10. Stefanou D, Batistatou A, Kamina S, et al. Expression of vascular endothelial growth factor (VEGF) and association with microvessel density in benign prostatic hyperplasia and prostate cancer. *In Vivo* 2004; 18: 155-160.
11. Longo R, Sarmiento R, Fanelli M, et al. Anti-angiogenic therapy: rationale, challenges and clinical studies. *Angiogenesis* 2002; 5: 237-256.
12. Russo G, Mischi M, Scheepens W, et al. Angiogenesis in prostate cancer: onset, progression and imaging. *BJU Int* 2012; 110 (11 Pt C): E794-808.
13. Petralia G, Bonello L, Viotti S, et al. CT perfusion in oncology: how to do it. *Cancer Imaging* 2010; 10: 8-19.
14. Bellomi M, Viotti S, Preda L, et al. Perfusion CT in solid body-tumours. Part II: Clinical applications and future development. *Radiol Med* 2010; 115: 858-874.
15. Osimani M, Bellini D, Di Cristofano C, et al. Perfusion MDCT of prostate cancer: correlation of perfusion CT parameters and immunohistochemical markers of angiogenesis. *AJR Am J Roentgenol* 2012; 199: 1042-1048.
16. Gleason DF, Mellinger GT. Prediction of prognosis for prostatic adenocarcinoma by combined histological grading and clinical staging. *J Urol* 2002; 111: 58-64.
17. Edition S. Cancer Staging Manual. Greene F, Page D, Fleming I, Fritz A, Balch C, Haller D, et al. (eds.). *Cancer* 2010; 20-22.
18. Petralia G, Preda L, D'Andrea G, et al. CT perfusion in solid-body tumours. Part I: Technical issues. *Radiol Med* 2010; 115: 843-857.
19. Miles KA, Griffiths MR. Perfusion CT: a worth while enhancement? *Br J Radiol* 2003; 76: 220-231.
20. Garcia-Figueiras R, Goh VJ, Padhani AR, et al. CT perfusion in oncologic imaging: a useful tool? *AJR Am J Roentgenol* 2013; 200: 8-19.
21. Chen Y, Zhang J, Dai J, et al. Angiogenesis of renal cell carcinoma: perfusion CT findings. *Abdom Imaging* 2010; 35: 622-628.
22. Kambadakone AR, Sahani DV. Body perfusion CT: technique, clinical applications, and advances. *Radiol Clin North Am* 2009; 47: 161-178.
23. Harvey CJ, Blomley MJ, Dawson P. Functional CT imaging of the acute hyperemic response to radiation therapy of the prostate gland: early experience. *J Comput Assist Tomogr* 2001; 25: 43-49.
24. Schlemmer HP, Merkle J, Grobholz R, et al. Can pre-operative contrast-enhanced dynamic MR imaging for prostate cancer predict microvessel density in prostatectomy specimens? *Eur Radiol* 2004; 14: 309-317.
25. Hlatky L, Hahnfeldt P, Folkman J. Clinical application of anti-angiogenic therapy: microvessel density, what it does and doesn't tell us. *J Natl Cancer Inst* 2002; 94: 883-893.
26. Goh V, Halligan S, Daley F, et al. Colorectal tumor vascularity: quantitative assessment with multidetector CT – do tumor perfusion measurements. *Radiology* 2008; 249: 510-517.
27. Izawa JI, Dinney CP. The role of angiogenesis in prostate and other urologic cancers: a review. *CMAJ* 2001; 164: 662-670.

28. Strohmeier D, Rössing C, Strauss F, et al. Tumor angiogenesis is associated with progression after radical prostatectomy in pT2/pT3 prostate cancer. *Prostate* 2000; 42: 26-33.
29. Ferrer FA, Miller LJ, Andrawis RI, et al. Angiogenesis and prostate cancer: in vivo and in vitro expression of angiogenesis factors by prostate cancer cells. *Urology* 1998; 51: 161-167.
30. Łuczyńska E, Gasińska A, Wilk W. Microvessel density and expression of vascular endothelial growth factor in clinically localized prostate cancer. *Pol J Pathol* 2013; 64: 33-38.

Address for correspondence

Elzbieta Łuczyńska MD, PhD
Radiology Department
Center of Oncology, M. Skłodowska-Curie Memorial Institute
Cracow Branch
Garncarska 11
31-115 Krakow, Poland
tel. +48 12 422 99 00
fax +48 12 421 23 25
e-mail: z5luczyn@cyfronet.pl