

# Leptospira spp. infection in wild ruminants: a survey in Central Italian Alps

Elena Andreoli<sup>1\*</sup>, Enrico Radaelli<sup>1</sup>, Irene Bertoletti<sup>2</sup>, Alessandro Bianchi<sup>2</sup>, Eugenio Scanziani<sup>1</sup>, Silvia Tagliabue<sup>3</sup> & Silvana Mattiello<sup>1</sup>

<sup>1</sup> Università degli Studi di Milano, Dipartimento di Scienze Veterinarie e Sanità Pubblica, Via Celoria 10, 20133 Milano, Italy.

<sup>2</sup> Istituto Zooprofilattico Sperimentale della Lombardia e dell'Emilia Romagna 'Bruno Ubertini', Sezione Diagnostica di Sondrio, Via Bormio 30, 23100 Sondrio, Italy.

<sup>3</sup> Istituto Zooprofilattico Sperimentale della Lombardia e dell'Emilia Romagna 'Bruno Ubertini', Dipartimento di Sanità e Benessere Animale, Via Bianchi 7/9, 25124 Brescia, Italy.

\* Corresponding author at: Università degli Studi di Milano, Dipartimento di Scienze Veterinarie e Sanità Pubblica, Via Celoria 10, 20133 Milano, Italy. Tel.: +39 02 503 18041, e-mail: Elena.Andreoli@unimi.it.

Veterinaria Italiana 2014, 50 (4), 285-291. doi: 10.12834/VetIt.1309.06

Accepted: 05.10.2014 | Available on line: 29.12.2014

## Keywords

Central Italian Alps,  
*Leptospira* spp. infection,  
Red deer,  
Renal lesion,  
Serology,  
Wild ruminants.

## Summary

Leptospirosis is an important zoonotic disease diffused worldwide, and wildlife species are commonly considered to be important epidemiological carriers. Four-hundred and forty-one serological and 198 renal samples from red deer, roe deer and chamois collected in the Province of Sondrio were analysed using the microscopic agglutination test and histopathologic examination. Positive serological findings were found only in 15 red deer and 19 positive serologic reactions were recorded. The most frequent serovars were Bratislava and Grippotyphosa, followed by Pomona, Hardjo and Copenhageni. Twenty-two per cent of renal samples from seropositive red deer were affected by mild to moderate multifocal chronic lymphoplasmacytic and fibrosing tubulo-interstitial nephritis, mainly involving the cortical parenchyma. In this study, antibodies to *Leptospira* spp. were infrequent in wild ruminants, and only red deer seemed to be sensitive to the infection. Given the low presence and the fact that there was no record of *Leptospira* spp. infections in cattle, sheep, goats and also hunters in area during the study period, wild ruminants in Alpine environments cannot be considered as reservoirs or important sources of *Leptospira* spp. infection for humans or domestic animals.

## Infezione da *Leptospira* spp. in ruminanti selvatici: indagine nelle Alpi Centrali italiane

## Parole chiave

Alpi Centrali italiane,  
Cervo,  
Infezione da *Leptospira* spp.,  
Lesioni renali,  
Ruminanti selvatici,  
Sierologia.

## Riassunto

La leptospirosi è un'importante zoonosi presente in tutto il mondo e gli animali selvatici sono considerati importanti vettori epidemiologici. Per indagare la presenza dell'infezione *Leptospira* spp. nei ruminanti allo stato brado delle Alpi Centrali Italiane, in provincia di Sondrio sono stati prelevati 441 campioni sierologici e 198 campioni renali da cervi, caprioli e camosci analizzati, rispettivamente, con il test di agglutinazione microscopica e l'esame istopatologico. Sono state riscontrate 19 reazioni sierologiche positive in 15 cervi. I sierotipi più frequenti sono risultati Bratislava e Grippotyphosa, seguiti da Pomona, Hardjo e Copenhageni. Nel 22% dei campioni renali appartenenti ai cervi risultati sieropositivi è stata riscontrata una nefrite tubulo-interstiziale multifocale cronica linfoplasmacitica e fibrotica da lieve a moderata. Nel presente studio, gli anticorpi per *Leptospira* spp. sono risultati infrequenti nei ruminanti selvatici e solo il cervo sembra essere sensibile all'infezione da *Leptospira* spp. Data la contenuta sieroprevalenza e il fatto che non sono state segnalate infezioni da *Leptospira* spp. in bovini, ovini, caprini e cacciatori nella area di studio durante il periodo di indagine, i ruminanti selvatici in ambiente alpino non possono essere considerati come *reservoirs* o importante fonte di infezione da *Leptospira* spp. per l'uomo o gli animali domestici.

## Introduction

Leptospirosis is an important zoonotic disease diffused worldwide (Bharti *et al.* 2003) and is considered by the OIE as one of the most important re-emerging human health hazards (Bengis *et al.* 2004). In Italy, the disease is included in the Official Regulation of Animal Health<sup>1</sup>, and the infection in domestic animals (such as cattle, sheep and goats) and humans is subject to mandatory reporting to the competent authorities<sup>2</sup>, although there are no detailed control plans at the present moment.

Leptospirosis is caused by infection with more than 250 *Leptospira* serovars (Higgins 2004), each tending to be maintained by a host group, which carries and spreads the disease (reservoir or maintenance host) (Adler and de la Peña Moctezuma 2004). Several species of water plants contaminated by leptospires are the main sources of all serogroups (Mailloux 1980); the primary reservoirs for infection are microtine rodents (Aguirre *et al.* 1995, Treml *et al.* 2002, Koizumi *et al.* 2008) and various game species (Gillespie & Ryno 1963, Mailloux 1980, Bondarenko *et al.* 2002, Koizumi *et al.* 2008).

Wildlife species are commonly considered to be important epidemiological carriers, mainly because of their frequent reactivity to *Leptospira* serovars native to their habitat (Lins *et al.* 2008, Espí *et al.* 2010). So far, few serologic studies have evaluated the incidence of the infection in wild ruminants in Italy (Corradini and Pecorari 1981, Lanfranchi *et al.* 1985, Tolari 1991, Tagliabue and Farina 1995), where the infection in wild ruminants mostly occurs when these species are in contact with domestic cattle.

This study reports the results of a serological and histological survey among various wild ruminant species in the Central Italian Alps, in order to provide updated epizootiological data on *Leptospira* spp. infection in wild ruminant species in this area and to ascertain whether wild ruminants are a source of *Leptospira* spp. infection in humans or domestic animals in Alpine environments.

## Materials and Methods

### Study area

Data were collected over a 7-year period (2001-2007) in the Province of Sondrio (surface area 3,212 km<sup>2</sup>, E 9°14' - 10°37'; N 45°47' - 46°22'), in the Central Italian Alps. The Province of Sondrio is divided

into 5 Hunting Management Districts, where wild ungulate and domestic species may share the same areas during Summer.

The study area contains 3,619 red deer (*Cervus elaphus*, Linnaeus, 1758), 7,996 chamois (*Rupicapra rupicapra*, Linnaeus, 1758), 2,570 roe deer (*Capreolus capreolus*, Linnaeus, 1758) and 1,507 ibex (*Capra ibex*, Linnaeus, 1758). The estimated pre-reproductive densities of red deer, chamois and roe deer are respectively 2.15 head /100 hectares, 3.85 head/100 hectares and 2.56 head/100 hectares of suitable surface area. Wild boars (*Sus scrofa*, Linnaeus, 1758) were illegally introduced into some areas in 2006, but no information is available about their number and/or density (Ferloni 2007). In addition to wild ungulates, about 11,000 cattle (*Bos taurus*, Linnaeus, 1758), 17,000 sheep (*Ovis* sp., Linnaeus, 1758) and goats (*Capra* spp., Linnaeus, 1758), and 600 horses (*Equus caballus*, Linnaeus, 1758) and donkeys (*E. asinus*, Linnaeus, 1758) were present in the mountain ranges during Summer.

### Sample collection

Blood and kidney samples came from hunted and found carcasses of red deer, roe deer and chamois. A total of 441 serological samples (237 red deer, 66 roe deer, 138 chamois) were collected, together with 198 renal samples (120 red deer, 16 roe deer, 62 chamois). Dead animals were collected in collaboration with field veterinarians, forest guards and hunters over a 7-year period (2001-2007) and were delivered to the control centre of the Hunting Management District of Sondrio (Italy). For found carcasses, blood samples were collected by cardiac puncture at the centre. In shot animals, samples were collected by hunters immediately after death. All samples were later centrifuged at 2000 rpm for 10 minutes and sera were stored at -20°C. When at least 1 kidney was present in the carcass, representative renal samples of both cortical and medullary portions were also collected and fixed in 10% buffered formalin. Hunters sometimes delivered carcasses completely eviscerated, resulting in a lower number of renal than serologic samples.

### Laboratory tests

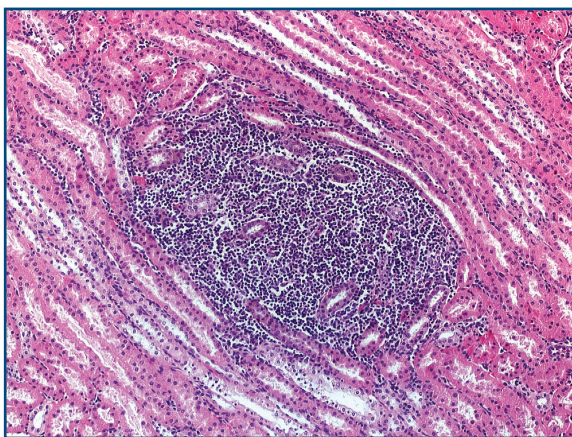
The microagglutination test (MAT) (OIE 2013) was used to verify the presence of antibodies against 8 serovars of *Leptospira* currently used in Italy to check for infection in animals: Canicola, Pomona, Ballum, Hardjo, Copenhageni, Bratislava, Tarassovi and Grippotyphosa. Minimum serum dilution was 1:100. A titer of 100, usually considered as evidence of past exposure (Levett 2001), was set as the end-point value. Titration with a geometric dilution serial from 1:100 to 1:6400 was performed.

<sup>1</sup> Decreto Ministeriale of December the 1<sup>st</sup> 1990. "Sistema informativo delle malattie infettive e diffusive". *Off J*, **6**, 08.01.1991.

<sup>2</sup> Decreto del Presidente della Repubblica of February the 8<sup>th</sup> 1954, n. 320. "Regolamento di polizia veterinaria". *Off J*, **142**, 24.06.1954.

For histopathologic examination, fixed renal samples were progressively dehydrated in graded alcohols and xylene and embedded in paraffin blocks. Four- $\mu$ m serial sections were then stained with hematoxylin-eosin and examined under a light microscope. Renal lesions were classified histopathologically according to Maxie and Newman (Maxie and Newman 2007). An identification number matched each sample to its carcass.

To avoid any influence of serologic results on histological analysis (and *vice versa*), tests were carried out in 2 laboratories and results were compared at the end of the analysis. Serologic



**Figure 1.** Chronic tubulo-interstitial nephritis characterized by dense nodular infiltrate of lymphocytes and plasma cells replacing renal tubules, 100x, as showed by one of the samples collected from red deer between 2001-2007 in the Province of Sondrio, Italy.

analyses were performed by *Istituto Zooprofilattico Sperimentale dell'Emilia e della Romagna*, Diagnostic Section of Sondrio, Italy and histological analyses by the *Dipartimento di Scienze Veterinarie e Sanità Pubblica* of University of Milan, Italy.

## Results

### Serology

Of the total number of 441 serological samples (237 red deer, 66 roe deer, 138 chamois), positive findings were ascertained only in red deer. Of the 237 samples, 15 (6.33%) red deer were found to be positive, with 19 serologic reactions, including 5 *Leptospira* serovars (Bratislava, Grippytyphosa, Pomona, Hardjo, Copenhageni). Three animals were positive to more than 1 serovar (20% of cross-reactions between differing leptospiral serovars). No positive serologic reactions were found for *Leptospira* serovars Ballum, Canicola or Tarassovi in any species. Of the samples that showed positive serological reactions 5 samples had reciprocal antibody titers of 100 (26.3%), 8 of 200 (42.1%), 2 of 400 (10.5%), 1 of 800 (5.3%), 1 of 1600 (5.3%), and 2 of 3200 (10.5%). The most frequent serovars were Bratislava (9/19, 47.4%) and Grippytyphosa (5/19, 26.3%), followed by Pomona (2/19, 10.5%), Hardjo (2/19, 10.5%) and Copenhageni (1/19, 5.3%).

Leptospiral antibodies were not found in the sera of roe deer or chamois.

**Table I.** Results of MAT to *Leptospira* serovars and presence of histopathologic renal lesions in red deer, samples collected from red deer between 2001-2007 in the Province of Sondrio, Italy.

Sample ID	Bratislava	Grippytyphosa	Hardjo	Pomona	Copenhageni	Renal lesions
1	100					n.a.
2	200					n.a.
3	200					n.a.
4	3200			100		no
5			100			no
6		200				no
7		400				n.a.
8	200					yes
9		400			200	n.a.
10	100					no
11		3200				no
12		1600				n.a.
13	100					no
14	200					no
15	200		200	800		yes

n.a. = renal sample not available.

## Histology

Histopathologic examination of renal samples was performed in 9 of the 15 seropositive and in 111 of the 222 seronegative red deer, 16 of 66 seronegative roe deer, and 62 of 138 seronegative chamois. Two of the 9 seropositive animals examined (22.2%) were affected by mild to moderate multifocal chronic lymphoplasmacytic and fibrosing tubulo-interstitial nephritis, mainly involving the cortical parenchyma (Figure 1). No renal lesions were recorded in seronegative animals.

Details of serovars, antibody titers and renal lesions are listed in Table I.

## Discussion

In this study, only red deer had positive titers to *Leptospira* spp. infection and revealed renal lesions. This may be the consequence of some behavioural traits typical of this species. One type of behaviour that may contribute to the spread of infection within this species is the habit of wallowing in mud or water pools during hot weather, to get rid of external parasites and, in the case of adult males, to mark their territory during the mating season (Clutton-Brock *et al.* 1982). Since the infection can be transmitted via contaminated water (Johnson *et al.* 2004), wallowing may also facilitate transmission in red deer. In addition, during the summer grazing period, red deer share the same feeding areas with domestic species (cattle, sheep, goats, horses, dogs), which may carry the bacteria and infect watercourses and pools; red deer may even interact directly with the above animals (Mattiello *et al.* 2002).

In the present study, roe deer seemed to be resistant to infection. This finding matches the results of Hausle (1987), who did not find any positive reaction in roe deer in Germany. However, there is evidence that this species is sensitive to leptospiral infection. Weber and Christoph (1981) and Witt and colleagues (Witt *et al.* 1988) reported 1.8% and 2% of positive serologic responses to *Leptospira* spp. in roe deer in Germany, and Slavica and colleagues (Slavica *et al.* 2008) found 6.07% positive roe deer in Croatia. The present negative results are probably due to the low level of infection in the study area and to the habits of roe deer, a solitary and territorial species. Mothers with kids or subadults are usually small and do not share their habitat with other species, either wild or domestic (Boitani *et al.* 2003).

Like roe deer, chamois had neither positive MAT titers nor did they show renal lesions. To our knowledge, leptospiral infection in this species has never been reported, and the only study on chamois in the Italian Gran Paradiso National Park produced negative results (Tolari 1991), suggesting that

chamois are not sensitive. However, negative results may also be due to the habitat preferences of this mountain-dwelling species, such as areas with low environmental temperatures, low vegetation, little water, and few other domestic and/or wild animals. These conditions do not allow for leptospiral survival. This hypothesis is supported by the fact that either the infection has not been recorded, or has only been recorded with low prevalence in other ungulate species living in similar mountain habitats, such as the alpine ibex (*Ibex ibex*) in Italy (no seropositive animals; Tolari 1991) and Switzerland (7.9% seropositive animals; Marreros *et al.* 2011) and the mouflon (*Ovis musimon*) in Germany and Croatia (no seropositive animals in either study; Weber and Christoph 1981, Slavica *et al.* 2008).

During the study period, the most prevalent serovars in red deer were Bratislava (47.4%) and Grippytyphosa (26.3%), followed by Pomona (10.5%), Hardjo (10.5%) and Copenhageni (5.3%).

Past serological studies in various parts of Italy show diverse situations: Corradini and colleagues (Corradini and Pecorari 1981) did not find any positive results in the red deer population of Bosco della Mesola (Ferrara, Italy). In 'La Mandria' Park (Turin, Italy) Lanfranchi and colleagues (Lanfranchi *et al.* 1985) found a low seroprevalence of sv. Hardjo (8.4%) in red deer sharing the same habitat with a herd of cattle with an endemic leptospiral infection due to the same serovar (81.9% of the herd); sv. Bratislava and Copenhageni were also recorded at low prevalence. Five deer positive to sv. Bratislava were found in a deer farm in Tuscany (5.1% of the herd) (Tolari 1991); serogroup Australis has been reported as the most prevalent in red deer (88.2%) (Tagliabue and Farina 1995), followed by Ballum (5.9%) and Icterohaemorrhagiae (5.9%).

Serovar Bratislava is the most prevalent serovar in horses in Italy (Andreani *et al.* 1993, Tagliabue and Farina 1995). In our study area, during the Summer grazing period, horses may share the same mountain habitat with deer and contribute toward spreading the infection to red deer, although the number of horses is very low and their role in the epidemiology of the disease is probably less important than that of wild species such as hedgehogs (*Erinaceus europaeus*), muroids, badgers (*Meles meles*) and foxes (*Vulpes vulpes*), common in the area and sharing the same habitat with red deer (Ferloni 2007). Isolation of leptospires belonging to the Australis group from these wild species has in fact been reported frequently (Farina and Andreani 1970, Tolari 1991).

The above results represent the first report of Sv. Grippytyphosa MAT reactions in red deer in Italy. The reservoir of this serovar is the common vole (*Microtus arvalis*) and the infection seems to be more common in dogs and horses (Tagliabue and



Farina 1995, Tengelsen *et al.* 1997, Barr *et al.* 2005), which roam the area during summer grazing. Serovar Grippotyphosa has also been found in white-tailed deer (*Odocoileus virginianus*; Michigan DNR 2007) and Iberian red deer (*Cervus elaphus hispanicus*; Espí *et al.* 2010). No information is available about the presence of this serovar in species (wild or domestic) other than red deer in our study area, and no data are available about pathogenicity for deer. Although, *Leptospira* spp. is known to cause severe infections, with clinical signs of illness in cattle (Özdemir and Erol 2002), we found no renal lesions, even at titers of 3200. Pomona and Hardjo, the most important serovars in New Zealand deer farms (Ayenegui-Alcerreca *et al.* 2007), appear occasionally in wild red deer, and the infection is probably due to the use of the same area by domestic animals, mostly cattle (Lanfranchi *et al.* 1985, Aguirre *et al.* 1995, Cantu *et al.* 2008).

Red deer also appear to be accidental hosts of sv. Copenhageni, whose the is the Norway rat (*Rattus norvegicus*), uncommon in Italian mountain habitats.

While renal histopathology in seronegative red deer was unremarkable, 22.2% of the seropositive animals (2 of the 9 examined) were affected by chronic tubulo-interstitial nephritis. Although too few cases were examined to draw final conclusions, these observations indicate that leptospirosis is a probable cause of chronic-progressive renal inflammation in red deer in Northern Italy. This hypothesis is further supported by previous studies demonstrating that chronic nephritic changes in red deer often result from subclinical or silent infections caused by sv. Pomona and Hardjo (Ayenegui-Alcerreca *et al.* 2007). We only found 2 red deer with renal lesions and, although the possibility of leptospiruria (Prescott 2007) cannot be excluded, this aspect needs further investigation.

In this study, antibodies to *Leptospira* spp. were infrequent in wild ruminants, and only red deer seemed to be susceptible to *Leptospira* spp.

infection, indicating that these species do not play an important role in the epizootiology of these pathogens. *Leptospira* spp. infection in wild red deer appears occasionally and may occur when other infected species share the same area. In view of the infrequent findings and the fact that in the study area no mandatory reporting of infection by *Leptospira* spp. in domestic animals (cattle, sheep, goats) or hunters has been notified to the competent authorities during the study period, it is assumed that wild ruminants in Alpine environments cannot be considered as reservoirs or important sources of *Leptospira* spp. infection for humans or domestic animals. In any case, to complete data on the epizootiology of *Leptospira* spp. infection in the study area, the occurrence of this infection in humans, farmed animals and other wild species needs to be investigated in greater detail in the future.

### Acknowledgments

We are grateful to all the hunters and students who were actively involved in sample collection. We wish to thank Dr Maria Ferloni, of the Province of Sondrio, and Dr Fabio Orsi, of the Official Veterinary Service of Sondrio (ASL), for their kind collaboration and for providing data on the local wild and domestic populations. Our gratitude also goes to Prof. Diane Frank and Ms. Gabriel Walton for assistance with the English language.

### Grant support

This research was partially funded by the Sondrio Hunting Management Committee and by the Lombardy Region within the project '*Piano di monitoraggio sanitario della fauna selvatica dell'arco alpino lombardo e presenza di agenti zoonosici su carcasse conferite alle Sezioni Diagnostiche IZSLER delle province di Bergamo, Brescia, Como-Varese e Sondrio-Lecco*'.

## References

- Adler B. & de la Peña Moctezuma A. 2004. *Leptospira*. In Pathogenesis of bacterial infections of animals (C. Gyles, J. Prescott, G. Songer & C. Thoen, eds). Blackwell Publishing, Iowa, 385-396.
- Adler H., Vonstein S., Deplazes P., Steiger C. & Frei R. 2002. Prevalence of *Leptospira* spp. in various species of small mammals in an inner-city area in Switzerland. *Epidemiol Infect*, **128**, 107-109.
- Aguirre A.A., Hansen D.E., Starkey E.E. & McLean R.G. 1995. Serologic survey of wild cervids for potential disease agents in selected national parks in the United States. *Prev Vet Med*, **21**, 313-322.
- Andreani E., Pedrini A. & Cerri D. 1993. Leptosirosi equina. Con particolare riguardo all'aborto nella cavalla. *Obiettivi e Documenti Veterinari*, **14**, 19-23.
- Ayenequi-Alcerreca M.A., Wilson P.R., Mackintosh C.G., Collins-Emerson J.M., Heuer C., Midwinter A.C. & Castillo-Alcala F. 2007. Leptospirosis in farmed deer in New Zealand: a review. *N Z Vet J*, **55**, 102-108.
- Barr S.C., McDonough P.L., Scipioni-Ball R.L. & Starr J.K. 2005. Serologic responses of dogs given a commercial vaccine against *Leptospira interrogans* serovar pomona and *Leptospira kirschneri* serovar grippotyphosa. *Am J Vet Res*, **66**, 1780-1784.
- Bengis R.G., Leighton F.A., Fischer J.R., Artois M., Mörner T. & Tate, C.M. 2004. The role of wildlife in emerging and re-emerging zoonoses. *Revue Scientifique et Technique OIE*, **23**, 497-511
- Bharti A.R., Nally J.E., Ricaldi J.N., Matthias M.A., Diaz M.M., Lovett M.A., Levett P.N., Gilman R.H., Willig M.R., Gotuzzo E. & Vinetz J.M. 2003. Leptospirosis: a zoonotic disease of global importance. *Lancet Infect Dis*, **3**, 757-771.
- Boitani L., Lovari S. & Vigna Taglianti A. 2003. Fauna d'Italia, Vol. 38, Mammalia III. Carnivora – Artiodactyla (L. Boitani, S. Lovari & A. Vigna Taglianti, eds). Officine Grafiche Calderini, Ozzano dell'Emilia, Italy, 314-323.
- Bondarenko A.L., Utenkova E.O., Russkikh G.A. & Khmeleveskaia N.S. 2002. Epidemiology of leptospirosis in the Kirov region. *Zh Mikrobiol Epidemiol Immunobiol*, **3**, 27-30.
- Cantu A., Ortega-S J.A., Mosqueda, J. Garcia-Vazquez Z., Henke S.E. & George J.E. 2008. Prevalence of infectious agents in free-ranging white-tail deer in north-eastern Mexico. *J Wildl Dis*, **44**, 1002-1007.
- Clutton-Brock T.H., Guinness F.E. & Albon S.D. 1982. Red deer: behaviour and ecology of two sexes. (T.H. Clutton-Brock, F.E. Guinness & S.D. Albon, eds). Edinburgh University Press, Edinburgh, UK.
- Corradini L. & Pecorari S. 1981. Ricerche sierologiche per brucellosi, leptosirosi, listeriosi, febbre Q, toxoplasmosi e tularemia sugli ungulati (*Cervus elaphus* e *Dama dama*) del boscone della Mesola. Atti della Società Italiana delle Scienze Veterinarie, 35, 706-707.
- Espi A., Prieto J.M. & Alzaga V. 2010. Leptospiral antibodies in Iberian red deer (*Cervus elaphus hispanicus*), fallow deer (*Dama dama*) and European wild boar (*Sus scrofa*) in Asturias, Northern Spain. *Vet J*, **183**, 226-227.
- Farina R. & Andreani E. 1970. Leptosirosi degli animali selvatici in Italia. *Archivio Veterinario Italiano*, **21**, 127-141.
- Ferloni M. 2007. Piano Faunistico Venatorio della Provincia di Sondrio (Provincia di Sondrio, ed). Sondrio, Italy, 33-34.
- Gillespie R.W.H. & Ryno J. 1963. Epidemiology of leptospirosis. *Am J Public Health*, **53**, 950-959.
- Hausle R. 1987. Hygienic status of roe deer in the north-eastern county of Raversburg. Thesis Dissertation, Tierärztliche Fakultät der Ludwig-Maximilians-Universität, München, German Federal Republic, 92 pp.
- Higgins R. 2004. Emerging or re-emerging bacterial zoonotic diseases: bartonellosis, leptospirosis, Lyme borreliosis, plague. *Revue Scientifique et Technique OIE*, **23**, 569-581.
- Johnson M., Smith H., Joseph P., Gilman R., Bautista C., Campos K., Cespedes M., Klatsky P., Vidal C., Terry H., Calderon M., Coral C., Cabrera L., Parmar P. & Vinetz J. 2004. Environmental exposure and leptospirosis, Peru. *Emerg Infect Diseases*, **10**, 1016-1022.
- Koizumi N., Muto M., Yamada A. & Wanatabe H. 2009. Prevalence of *Leptospira* spp. in the kidneys of wild boars and deer in Japan. *J Vet Med Sci*, **71**, 797-799.
- Koizumi N., Muto M., Yamamoto S., Baba Y., Kudo M., Tamae Y., Shimomura K., Takatori I., Iwakiri A., Ishikawa K., Soma H. & Wanatabe H. 2008. Investigation of reservoir animals of *Leptospira* in northern part of Miyazaki Prefecture. *Jpn J Infect Dis*, **61**, 465-468.
- Lanfranchi P., Tolari F., Forlett R., Meneguz P.G. & Rossi L. 1985. The red deer as reservoir of parasitic and infectious pathogens for cattle. *Annali della Facoltà di Medicina Veterinaria di Torino*, **30**, 3-17.
- Levett P.N. 2001. Leptospirosis. *Clin Microbiol Rev*, **14**, 296-326.
- Lins Z.C. & Lopes M.L. 1984. Isolation of *Leptospira* from wild forest animals in Amazonian Brazil. *Trans R Soc Trop Med Hyg*, **78**, 124-126.
- Mailloux M. 1980. Leptosirosi et environnement. *Rev Epidemiol Sante Publique*, **28**, 323-327.
- Marreros N., Hussy D., Albini S., Frey C.F., Abril C., Vogt H.R., Holzwarth N., Wirz-Dittus S., Friess M., Engels M., Borel N., Willisch C.S., Signer C., Hoelzle L.E. & Ryser-Degiorgis M.P. 2011. Epizootiologic investigations of selected abortive agents in free-ranging Alpine ibex (*Capra ibex ibex*) in Switzerland. *J Wildl Dis*, **47**, 530-543.
- Mattiello S., Redaelli W., Carenzi C. & Crimella C. 2002. Effect of dairy cattle husbandry on behavioural patterns of red deer (*Cervus elaphus*) in the Italian Alps. *Appl Anim Behav Sci*, **79**, 299-310.
- Maxie M.G. & Newman S.J. 2007. Kidney. In Jubb, Kennedy & Palmer's Pathology of Domestic Animals, Vol. 2, 5 Ed. (M.G. Maxie, ed). Saunders Elsevier, Philadelphia, 426-503.
- Michigan DNR 2007. Leptospirosis ([http://www.michigan.gov/dnr/0,1607,7-153-10370\\_12150\\_12220-26943--,00.html](http://www.michigan.gov/dnr/0,1607,7-153-10370_12150_12220-26943--,00.html) accessed on 05.09.2007).
- Özdemir V. & Erol E. 2002. Leptospirosis in Turkey. *Vet Rec*, **150**, 248-249.

- Prescott J.F. 2007. Leptospirosis. In Jubb, Kennedy & Palmer's Pathology of Domestic Animals, Vol. 2, 5 Ed. (M.G. Maxie, ed). Saunders Elsevier, Philadelphia, 481-490.
- Slavica A., Cvetnić Ž., Milas Z., Janicki Z., Turk N., Konjević D., Severin K., Tončić J. & Lipej Z. 2008. Incidence of leptospiral antibodies in different game species over a 10-year period (1996-2005) in Croatia. *Eur J Wildlife Res*, **54**, 305-311.
- Tagliabue S. & Farina R. 1995. Inchiesta sieroepidemiologica sulla diffusione delle leptospirosi tra gli animali domestici ed alcune specie selvatiche. *Selezione Veterinaria*, **36**, 941-952.
- Tengelsen L.A., Yamini B., Mullaney T.P., Bell T.G., Render J.A., Patterson J.S., Steficek B.A., Fitzgerald S.D., Kennedy F.A., Slanker M.R. & Ramos-Vara J.A. 1997. A 12-year retrospective study of equine abortion in Michigan. *J Vet Diagn Invest*, **9**, 303-306.
- Tolari F. 1991. Ruolo degli animali selvatici nell'epidemiologia della leptospirosi. In Atti del I e II Corso di Aggiornamento in Gestione e Protezione del Patrimonio Faunistico, Brescia 1989-1990. Istituto per la qualificazione e l'aggiornamento tecnico-professionale in agricoltura, Brescia, 213-215.
- Tremel F., Pejcoch M. & Holesovska Z. 2002. Small mammals - natural reservoirs of pathogenic leptospires. *Vet Med-Czec*, **47**, 309-311.
- Weber A. & Christoph H. 1981. Seroepidemiological investigations on the incidence of leptospirosis in cloven-hoofed game in the Federal Republic of Germany. *Z Jagdwiss*, **27**, 283-287.
- Witt W., Dedek J. & Loepelmann H. 1988. Occurrence of *Leptospira* antibodies in red, roe and fallow deer and mouflon. *Monatsh Veterinarmed*, **43**, 65-68.
- World Organisation for Animal Health (OIE). 2013. Manual of Diagnostic Tests and Vaccines for Terrestrial Animals. Chapter 2.1.9: 251-264. Office International des Epizooties, Paris, France. (<http://www.oie.int/en/international-standard-setting/terrestrial-manual/access-online/> accessed on 22.03.2014).