

## Extensive small-bowel Crohn's disease detected by the newly introduced 360° panoramic viewing capsule endoscopy system

Chronic, nonbloody diarrhea may represent a diagnostic challenge in patients with inconclusive findings after standard clinical work-up [1]. In this setting, small-bowel capsule endoscopy (SBCE) has high sensitivity and a favorable clinical impact in assessing the presence of small-bowel

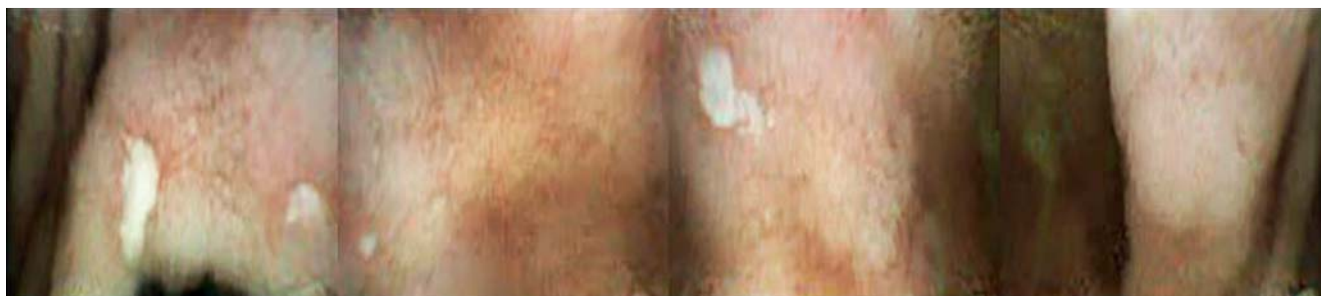mucosal lesions in patients with suspected Crohn's disease and no obstructive symptoms [1–3].

Very recently, the CapsoCam SV-1 (CapsoVision, Inc. Saratoga, California, USA) has been introduced as a new standard in SBCE. The system allows lateral panora-

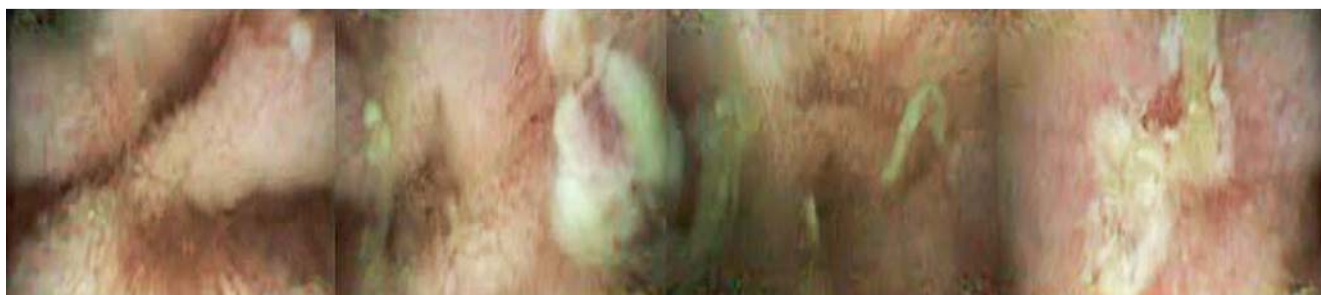
mic 360° viewing with wire-free technology, longlasting battery life, and 12–20 frames per second captured by four high-resolution cameras located on the capsule sides and facing the four quadrants of the digestive wall [4,5]. To the best of our knowledge, there is no published report on the use of this new technique in patients with suspected small-bowel Crohn's disease. Here, the case of a 51-year-old woman with a 2-year history of chronic, nonbloody diarrhea is presented. Physical examination was unremarkable and laboratory parameters were within the reference ranges, with the exception



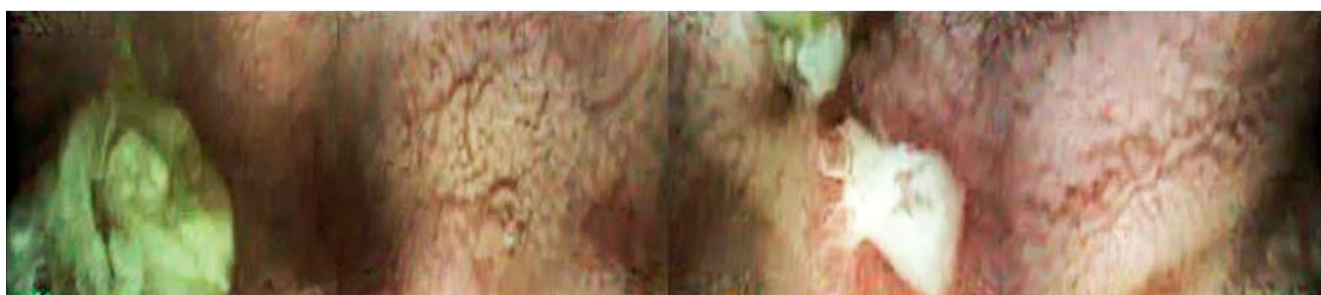**Fig. 1** Two superficial jejunal ulcers in the second and fourth quadrants.



**Fig. 2** Multiple superficial ulcers in the proximal ileum, quadrants 1–3.



**Fig. 3** Two deep ulcers (quadrants 2 and 4) and one small, superficial ulcer (quadrant 3) in the distal ileum.



**Fig. 4** Large and deep ulcer of the distal ileum (quadrant 3).

of a low albumin level (3 g/dL). Nonsteroidal anti-inflammatory drug use, infectious disorders, and gluten and lactose intolerance were ruled out. Previous upper and lower endoscopy with biopsies and abdominal cross-sectional imaging did not reveal any lesions. A second ileocolonoscopy showed subtle ileal erosions with histopathological evaluation that was inconclusive for Crohn's disease. It was decided that SBCE with CapsoCam SV-1 should be performed.

The patient swallowed the capsule as directed and retrieved it 52 hours later. The wire-free capsule system was then inserted into the bench storage device and the on-board data were downloaded using a standard computer. The SBCE video record provided high quality, four-quadrant images (n=3650) for the whole duration of the recording (total recording duration 14 hours; transit time, gastric 57 minutes, small bowel 202 minutes).

An impressive number of erosions (n=27) and ulcers (n=97) from the distal duodenum to the terminal ileum were observed (Figs. 1–4; Video 1). All lesions occurred among normal-appearing mucosa, with no trace of strictures. The 360° panoramic view, together with the high rate of recorded frames, allowed for a clear characterization of each lesion. A remarkable number of frames were recorded per erosion or ulcer (mean 7 frames [range 2–14] per erosion, 9 frames [range 3–33] per ulcer), and distinct perspectives of lesions were captured by each camera (mean number of cameras capturing the lesion, 1.5 [range 1–3]). This feature represents a tangible improvement in lesion classification and differential diagnosis (i.e. for classification of the lesion type or distinction between different or redundant findings). Based on these findings, the diagnosis of extensive small-bowel Crohn's disease was made and the patient improved with specific therapy.

This case is interesting for several reasons. First, an unusual case of extensive luminal small-bowel Crohn's disease was identified in a patient with a long history of chronic, nonbloody diarrhea. Second, the report adds to the growing literature on advanced endoscopic imaging techniques for the small bowel [1–3]. Finally, the performance of a new standard for SBCE has been described, providing multiple, high resolution images and visualizing different aspects of each lesion, which have the potential to improve both the diagnostic yield and the confidence of the operator in assessing the diagnosis and the differential diagnosis.

#### Video 1

CapsoCam SV-1 short video of the distal ileum, characterized by several ulcers of different sizes and depths in a patient with suspected Crohn's disease.

Endoscopy\_UCTN\_Code\_TTT\_1AP\_2AB

Competing interests: None

**Gian Eugenio Tontini<sup>1</sup>,  
Flaminia Cavallaro<sup>1</sup>,  
Helmut Neumann<sup>2</sup>, Luca Pastorelli<sup>1,3</sup>,  
Markus F. Neurath<sup>2</sup>, Luisa Spina<sup>1</sup>,  
Maurizio Vecchi<sup>2,3</sup>**

<sup>1</sup> Gastroenterology and Digestive Endoscopy Unit, IRCCS Policlinico San Donato, San Donato Milanese, Italy

<sup>2</sup> Department of Medicine I, University of Erlangen-Nuremberg, Erlangen, Germany

<sup>3</sup> Department of Biomedical Sciences for Health, University of Milan, Milan, Italy

#### References

- 1 ASGE Standards of Practice Committee, Shen B, Khan K et al. The role of endoscopy in the management of patients with diarrhea. *Gastrointest Endosc* 2010; 71: 887–892
- 2 Fry LC, Vormbrock K, Olano C et al. Small-bowel endoscopy. *Endoscopy* 2011; 43: 978–984
- 3 Tontini GE, Vecchi M, Neurath MF et al. Advanced endoscopic imaging techniques in Crohn's disease. *J Crohns Colitis* 2014; 8: 261–269
- 4 Friedrich K, Gehrke S, Stremmel W et al. First clinical trial of a newly developed capsule endoscope with panoramic side view for small bowel: a pilot study. *J Gastroenterol Hepatol* 2013; 28: 1496–1501
- 5 Pioche M, Vanbervliet G, Jacob P et al. Prospective randomized comparison between axial- and lateral-viewing capsule endoscopy systems in patients with obscure digestive bleeding. *Endoscopy* 2014; 46: 479–484

#### Bibliography

DOI <http://dx.doi.org/10.1055/s-0034-1377358>  
Endoscopy 2014; 46: E353–E354  
© Georg Thieme Verlag KG  
Stuttgart · New York  
ISSN 0013-726X

#### Corresponding author

**Gian Eugenio Tontini, MD, PhD**  
Gastroenterology and Digestive Endoscopy Unit  
IRCCS Policlinico San Donato  
Via Morandi 30  
20097, San Donato Milanese (MI)  
Italy  
Fax: +39-02-52774655  
[gianeugeniotontini@libero.it](mailto:gianeugeniotontini@libero.it)