

CASE REPORT

Open Access

Linear asymptomatic pneumatosis as an unexpected finding of computed tomography colonography: a case report

Nicola Flor^{1,2*}, Paola Pricolo², Antonio Rovere², Miriam Mezzanzanica², Mauro Peri² and Gianpaolo Cornalba^{1,2}

Abstract

Introduction: We discuss asymptomatic colonic pneumatosis, an unexpected finding of computed tomography colonography that we must see as distinct from perforation. Among the papers detailing complications with computed tomography colonography, we found only one report focusing on linear pneumatosis.

Case presentation: We report the case of a 75-year-old Caucasian woman who had a high level of carcinoembryonic antigen, and who underwent computed tomography colonography. Our patient accidentally fell from a chair in the radiology department just before the examination, experiencing a right hip trauma. The examination was negative for colonic lesions but revealed the presence of some air bubbles in her right colon. Our patient remained asymptomatic throughout the procedure and afterwards; no intervention or treatment was necessary.

Conclusion: Radiologists should consider colonic linear pneumatosis among the potential complications of computed tomography colonography, even if it is a rare event, to avoid unnecessary therapy and anxiety for the patient.

Introduction

Computed tomography colonography (CTC) is a valid alternative to optical colonoscopy (OC), sharing its high rates of accuracy in diagnosis of polyps and colon cancers [1-5]. Part of the success of the method is due to its low invasiveness, which is clearly lower than OC [6-8]. Complications are quite rare, and amongst these the most feared is intestinal perforation. The report we present here concentrates on an unexpected CTC imaging finding, which must be seen as distinct from perforation: intestinal pneumatosis.

Case presentation

We present the case of a 75-year-old Caucasian woman with an increase of carcinoembryonic antigen three months after an incomplete OC, who underwent CTC to exclude the presence of colonic lesions. The OC was

incomplete and interrupted at her sigmoid colon because of inadequate bowel cleansing. Our patient was being followed-up for lung cancer. She had carried out intestinal preparation in the days preceding the CTC with a mild laxative associated with a low fiber diet. On the morning of the examination, just before taking the oral contrast medium for fecal tagging, our patient accidentally fell from a chair in the radiology department, experiencing a right hip trauma. Because of the persistent pain, she immediately underwent a pelvis X-ray, which excluded fractures.

The CTC was performed as usual, using an automated insufflator for colon distension that administered about 2.6L of carbon dioxide, which was well tolerated. We did not use a hypotonic drug. The scans were obtained at end expiration with our patient in the supine position and in the right lateral decubitus position; the prone decubitus was not possible because of the difficulties our patient had in keeping that position. There were no lesions in her colon but numerous tiny air bubbles were present in her right colon (Figure 1), and in particular in her cecum, ileocecal valve and ascending colon, as in cases of intestinal linear pneumatosis, without free

* Correspondence: nicola.flor@unimi.it

¹Unità Operativa Radiologia Diagnostica e Interventistica, Azienda Ospedaliera San Paolo, via A di Rudini 8, 20142 Milano, Italy

²Dipartimento di Scienze della Salute, Università degli Studi di Milano, Milano, Italy

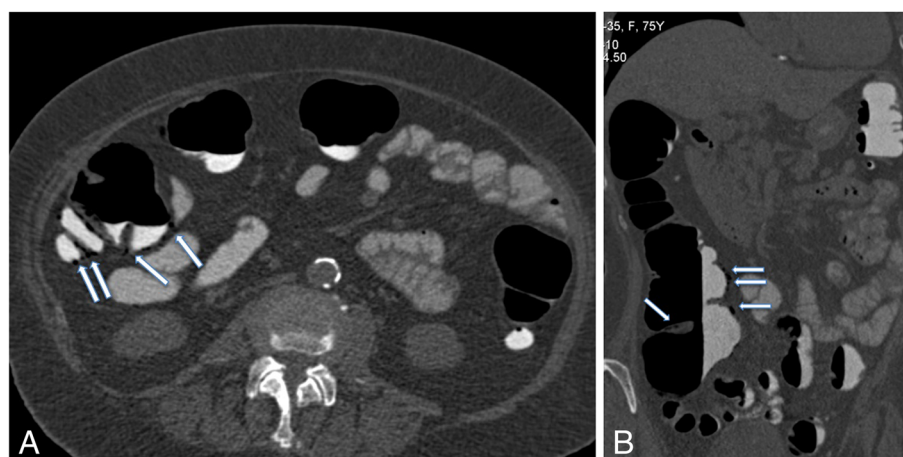


Figure 1 Two-dimensional computed tomography colonography images. (A) Supine axial and (B) right lateral coronal images show tiny curvilinear pneumatisis (arrows) involving the ascending colon, ileocecal valve and cecum without involvement of the transverse and left colon.

intra-peritoneal gas. Pneumatisis was already evident at the first scan and no deterioration was shown in the second scan of the lateral decubitus, taken two or three minutes after the first. Our patient was asymptomatic after the examination and went home; she was contacted by telephone that evening and in the following days, never reporting symptoms. She underwent no further medical treatment.

Discussion

Asymptomatic colonic pneumatisis is a rare potential CTC complication. Among papers discussing CTC complications, there is one report dealing with pneumatisis cystoides coli [9] and only one, by Pickhardt *et al.* [10], focusing on linear pneumatisis. Pickhardt *et al.* described six cases of linear colonic pneumatisis in 5,368 patients who underwent CTC examination for screening purposes, with a prevalence of 0.11%. They reported that pneumatisis was always asymptomatic and correlated with the use of automated insufflators of carbon dioxide. Our case has some analogies with that report [10]. Our patient was also asymptomatic; the pneumatisis was detected at the end of the examination, during the first review of the images, and represented a surprising finding due to the absolute absence of symptoms during the CTC and immediately after the procedure. Moreover, our patient judged the examination as absolutely not painful in her questionnaire after the CTC. This unexpected finding also occurred using a carbon dioxide automated insufflator for colonic distention. We have used this device for 15 months instead of room air insufflation: this is the only case of pneumatisis that occurred out of a total of almost 800 CTC examinations (0.1%) performed with the use of an automated insufflator. In almost 700 examinations performed with room air, a similar event had never occurred.

The cause of this event is unclear. Some authors [11-14] have postulated the role of different factors including intraluminal pressure, mucosal integrity, bacterial flora and intraluminal gas. Pickhardt *et al.* hypothesized a potential role for cathartic bowel preparation [10].

We cannot exclude that linear pneumatisis in our case resulted from the traumatic event, which may have caused an acute increase in intraluminal pressure and, subsequently, a mucosal laceration.

Kelly *et al.* [15] described a case of portal venous air embolism and extensive pneumatisis cystoides intestinalis secondary to blunt abdominal trauma, diagnosed by conventional CT.

These findings are not the sole prerogative of CTC; it is likely that such asymptomatic findings occur more frequently on OC, but are not recognized without CT imaging.

Linear pneumatisis should not be confused with perforation and with so-called primary pneumatisis cystoides coli, which typically manifests itself as a cluster of air-filled cysts usually involving the left colon, and resembling polyposis on endoluminal evaluation.

Conclusion

Radiologists dealing with CTC have to consider linear colonic pneumatisis as a potential complication, even if it represents a rare event, to avoid unnecessary therapy and anxiety for the patient. We therefore suggest this unexpected imaging finding be included in the patient's information sheet.

Consent

Written informed consent was obtained from the patient for publication of this case report and accompanying images. A copy of the written consent is available for review by the Editor-in-Chief of this journal.

Competing interests

The authors declare that they have no competing interests.

Authors' contributions

PP and AR performed the CTC examination and were involved in drafting and revising the manuscript; MM, MP and GC were involved in drafting and revising the manuscript. NF was a major contributor in writing the manuscript. All authors read and approved the final manuscript.

Received: 14 January 2013 Accepted: 20 June 2013

Published: 14 August 2013

References

1. Pickhardt PJ, Hassan C, Halligan S, Marmo R: **Colorectal cancer: CT colonography and colonoscopy for detection—systematic review and meta-analysis.** *Radiology* 2011, **259**:393–405.
2. Kim DH, Pickhardt PJ, Taylor AJ, Leung WK, Winter TC, Hinshaw JL, Gopal DV, Reichelderfer M, Hsu RH, Pfau PR: **CT colonography versus colonoscopy for the detection of advanced neoplasia.** *N Engl J Med* 2007, **357**:1403–1412.
3. Johnson CD, Chen MH, Toledano AY, Heiken JP, Dachman A, Kuo MD, Menias CO, Siewert B, Cheema JI, Obregon RG, Fidler JL, Zimmerman P, Horton K M, Coakley K, Iyer RB, Hara AK, Halvorsen RA Jr, Casola G, Yee J, Herman BA, Burgart LJ, Limburg PJ: **Accuracy of CT colonography for detection of large adenomas and cancers.** *N Engl J Med* 2008, **359**:1207–1217.
4. Regge D, Laudi C, Galatola G, Della Monica P, Bonelli L, Angelelli G, Asnaghi R, Barbaro B, Bartolozzi C, Bielen D, Boni L, Borghi C, Bruzzi P, Cassinis MC, Galia M, Gallo TM, Grasso A, Hassan C, Laghi A, Martina MC, Neri E, Senore C, Simonetti G, Venturini S, Gandini G, Regge D, Laudi C, Galatola G, Della Monica P, Bonelli L, et al: **Diagnostic accuracy of computed tomographic colonography for the detection of advanced neoplasia in individuals at increased risk of colorectal cancer.** *JAMA* 2009, **301**:2453–2461.
5. Graser A, Stieber P, Nagel D, Schäfer C, Horst D, Becker CR, Nikolaou K, Lottes A, Geisbüsch S, Kramer H, Wagner AC, Diepolder H, Schirra J, Roth HJ, Seidel D, Göke B, Reiser MF, Kolligs FT: **Comparison of CT colonography, colonoscopy, sigmoidoscopy and faecal occult blood tests for the detection of advanced adenoma in an average risk population.** *Gut* 2009, **58**:241–248.
6. Pickhardt PJ: **The incidence of colonic perforation at CT colonography: review of the existing data and the implications for screening of asymptomatic adults.** *Radiology* 2006, **239**:313–316.
7. Burling D, Halligan S, Slater A, Noakes MJ, Taylor SA: **Potentially serious adverse events associated with CT colonography performed in symptomatic patients: a national survey of the UK.** *Radiology* 2006, **239**:464–471.
8. Sosna J, Blachar A, Amitai M, Barmer E, Peled N, Goldberg SN, Bar-Ziv J: **Assessment of the risk of colonic perforation at CT colonography in a multi-center large cohort.** *Radiology* 2006, **239**:457–463.
9. Hachlander T, Wenger H: **Pneumatosis intestinalis coli – a rare find in CT-colonoscopy.** *Rofo* 2005, **177**:759–761.
10. Pickhardt PJ, Kim DH, Taylor AJ: **Asymptomatic pneumatosis at CT colonography: a benign self-limited imaging finding distinct from perforation.** *AJR* 2008, **190**:W112–W117.
11. Pear BL: **Pneumatosis intestinalis: a review.** *Radiology* 1998, **207**:13–19.
12. St Peter SD, Abbas MA, Kelly KA: **The spectrum of pneumatosis intestinalis.** *Arch Surg* 2003, **138**:68–75.
13. Soyer P, Martin-Grivaud S, Boudiaf M, Malzy P, Duchat F, Hamzi L, Pocard M, Vahedi K, Rymer R: **Linear or bubbly: a pictorial review of CT features of intestinalis pneumatosis adults.** *J Radiol* 2008, **89**:1907–1920.
14. Ho LM, Paulson EK, Thompson WM: **Pneumatosis intestinalis in the adult: benign to life-threatening causes.** *AJR* 2007, **188**:1604–1613.
15. Kelly BS Jr, Meyers P, Choe KA, Hurst J, Luchette FA: **Traumatic pneumatosis cystoides intestinalis with portal venous air embolism.** *J Trauma* 1997, **42**:112–113.

doi:10.1186/1752-1947-7-205

Cite this article as: Flor et al.: Linear asymptomatic pneumatosis as an unexpected finding of computed tomography colonography: a case report. *Journal of Medical Case Reports* 2013 **7**:205.

Submit your next manuscript to BioMed Central and take full advantage of:

- Convenient online submission
- Thorough peer review
- No space constraints or color figure charges
- Immediate publication on acceptance
- Inclusion in PubMed, CAS, Scopus and Google Scholar
- Research which is freely available for redistribution

Submit your manuscript at
www.biomedcentral.com/submit

