



Original article

Ring chromosome 20

Robert D. Daber^a, Laura K. Conlin^a, Laura D. Leonard^a, Maria P. Canevini^b, Aglaia Vignoli^c, Syed Hosain^d, Lawrence W. Brown^{e,f}, Nancy B. Spinner^{a,f,*}

^a Department of Pathology and Laboratory Medicine, University of Pennsylvania, 1007A Abramson Research Center, 3615 Civic Center Boulevard, The Children's Hospital of Philadelphia, PA 19104, USA

^b Dipartimento Medicina Chirurgia e Odontoiatria, Università degli Studi, Azienda Ospedaliera San Paolo, Milano

^c Epilepsy Centre, San Paolo Hospital, University of Milan, Italy

^d University of Medicine and Dentistry New Jersey, Robert-Wood Johnson Medical School, NJ, USA

^e Division of Neurology, Department of Pediatrics, The Children's Hospital of Philadelphia, PA, USA

^f The Perelman School of Medicine, University of Pennsylvania, PA, USA

ARTICLE INFO

Article history:

Received 26 October 2011

Accepted 13 February 2012

Available online 22 February 2012

Keywords:

Ring chromosome

Seizures

Mosaicism

ABSTRACT

Ring Chromosome 20 syndrome is a rare chromosomal disorder characterized by refractory epilepsy, with seizures in wakefulness and sleep, behavioral problems and mild to severe cognitive impairment. Facial dysmorphism or other congenital malformations are rarely reported making it difficult to diagnose the syndrome based on clinical findings alone. Therefore, diagnosis requires cytogenetic testing. More than 100 cases have been published since the initial report in 1972. In some patients, the ring (20) is found in all cells analyzed and in these cases, the ring is almost always accompanied by deletions of 20pter and/or 20qter. However, in the majority of cases the ring is present in only a proportion of cells, with two normal 20's in the remaining cells (mosaicism), and in these cases, no deletions of chromosome 20 have been observed. Patients with supernumerary r(20) chromosomes have also been identified, but these individuals do not generally have seizures and are not discussed in this review. Characterization by fluorescence *in situ* hybridization and array-based analysis has shed insight into the molecular composition and possible mechanisms of ring formation, in both the mosaic and non-mosaic patients. The age of onset of seizures correlates with the percentage of cells with the ring in mosaic patients. While the underlying etiology of the phenotype is still not understood, evidence is accumulating which suggests the deletion of candidate genes on chromosome 20 is not responsible. Cytogenetic analysis, rather than chromosomal microarray analysis is recommended for diagnosis of this syndrome, as the mosaic cases do not have copy number alterations and are therefore not identified by array-based analysis.

© 2012 Elsevier Masson SAS. All rights reserved.

1. Introduction

Constitutional ring chromosomes have been identified for each of the human chromosomes, and the overall frequency is estimated at 1 in 30,000 to 60,000 births [1]. Rings result from rare intra-chromosomal fusions although mechanism(s) underlying chromosomal ring formation are not completely understood. These fusion events are hypothesized to arise from either unstable telomeres, which directly fuse, or from chromosomal breaks that resolve by fusion of the two chromosomal arms. The latter are often accompanied by additional aberrations including terminal arm

deletions, duplications and/or inversions [2–4]. The timing of the fusion event determines how many cells are affected, and ring formation can occur in either the germ line or somatic cells. Ring formation in germ line cells results in patients who have the ring chromosome present in every cell (non-mosaic) while post-zygotic fusions affect only a subset of cells (mosaicism) [5–7]. Familial transmission of ring chromosomes has been reported, however, most cases are sporadic with no gender or ethnicity bias [5,6,8,9].

While this review focuses only on ring chromosome 20, there is suggestion that there may be phenotypic overlap with ring other chromosomes, resulting in what has been coined a 'ring syndrome'. This commonality across ring syndromes led to the hypothesis that the ring itself, irrespective of the specific sequences involved, may cause clinical abnormalities [10]. However, evidence is conflicting. It has been hypothesized that the growth failure associated with 'ring syndrome' is related to haploinsufficiency due to specific deletions within ring chromosomes, rather than the ring itself

* Corresponding author. Department of Pathology and Laboratory Medicine, University of Pennsylvania, 1007A Abramson Research Center, 3615 Civic Center Boulevard, The Children's Hospital of Philadelphia, PA 19104, USA. Tel.: +215 590 4177; fax: +215 590 3850.

E-mail address: spinner@mail.med.upenn.edu (N.B. Spinner).

[8,11–16]. This argument is disputed by the demonstration that not all rings have associated deletions, even if the phenotype compares to the deletion-associated ring [8,16,17]. In addition, not all patients with a ring chromosome have growth deficiency (including patients with ring chromosome 20). Currently, based on variability in phenotypes of different ring chromosomes, there is limited support for the existence of a ring syndrome [8,17–21]. Work is ongoing to determine how the presence of a ring chromosome alters expression of genes on the ring and elsewhere in the genome; comparison of this data for different rings will provide information on similarities in genomic effects of different ring chromosomes.

Ring chromosome 20 was first reported in 1972 in a patient with epilepsy, intellectual disability and abnormal behavior [22]. Additional case reports of individuals presenting with epilepsy led to the description of a ring chromosome 20 syndrome [23,24]. Since then, nearly 100 patients in 70 reports on have been described, most with intractable epilepsy, variable cognitive impairment and/or behavioral problems [1,8,9,12,16,17,25–31]. In some of these cases, development was normal until seizure onset, suggesting that the syndrome be considered an epileptic encephalopathy. To date, the pathogenic etiology underlying the seizure phenotype is still unknown. Here we review the published cases, and detail both the clinical phenotype and what is currently known about the underlying genetics.

2. Clinical phenotype

Ring chromosome 20 syndrome is characterized by medically intractable focal epilepsy with seizure onset in childhood and an electroencephalogram (EEG) demonstrating long epochs of bilateral high amplitude slow activity with intermixed frontal spikes [8]. Seizures are typically partial complex in nature with altered consciousness including staring, automatisms, and focal motor symptoms [8,13,25,32,33]. Patients may describe periods of intense fear and sometimes prolonged, confusional states lasting for minutes to hours (non-convulsive status epilepticus), which appears to be a characteristic seizure type in r(20) patients [13]. Ictal visual hallucinations have also been described [8,32,33]. In addition, subtle nocturnal seizures with behavioral changes such as stretching, rubbing and turning have been observed which resemble normal arousal behavior or mistaken for non-epileptic events [25,32]. Video-EEG monitoring can be performed to distinguish epileptic from non-epileptic events. Seizures are typically difficult to control with antiepileptic medications and patients are subjected to epilepsy surgery workup and unnecessary investigations unless the diagnosis of r(20) has been made [8,13,25,33].

Unlike other chromosomal aberrations, dysmorphisms are uncommon and most patients appear phenotypically normal [17]. Normal development prior to seizures is common [8,13,25,30,32,34,35]. After onset, varying degrees of intellectual impairment and behavioral problems have been reported. Seizure onset is typically between ages 1 and 24 years, with an average of 7–9 years in mosaic patients and 2.5 years for patients with the ring in all cells [17,32]. Earlier seizure onset is associated with more severe intellectual impairment [36,37]. While the age of onset and severity are variable, seizure semiology is consistent, as described above.

A wide spectrum of EEG abnormalities is seen in r(20) patients. Interictal EEG background may be normal to mildly slow or demonstrate bursts of sharply contoured theta activity. Runs of bi-frontal spike and wave activity have been reported as a distinct pattern in r(20)syndrome (Fig. 1B) [8,13,36,38]. Ictal EEGs point to frontal onset, prolonged runs of diffuse slowing with frontal dominance intermixed with bi-frontal sharp wave

discharge are seen with non-convulsive status epilepticus (Fig. 1C) [8,13,25,32,35]. Magnetoencephalography in one patient confirmed frontal lobe involvement [39]. The lack of dysmorphic abnormalities and the fact that frontal lobe epilepsy is not specific to the r(20) syndrome presents a challenge for the timely diagnosis of this rare disorder.

2.1. Neuroimaging

A wide spectrum of structural and functional neuroimaging studies have been performed in patients with r(20) syndrome. Structural abnormalities are not seen in the majority of the patients, although minor structural abnormalities have been occasionally reported. A [18F] fluoro-L-DOPA PET study in patients with r(20) showed decreased uptake in the basal ganglia, emphasizing the importance of subcortical structures in epileptic mechanisms [40]. A recent SPECT study supported the role of the dopaminergic system in epilepsy in patients with r(20) syndrome [41].

2.2. Differential diagnosis

Both clinical and electroencephalographic findings in patients with r(20) syndrome can be confused with other refractory epilepsy syndromes. Lennox–Gastaut syndrome (LGS), is characterized by medically refractory mixed intractable seizures but the tonic and atonic seizures (drop attacks) characteristic of LGS are rarely seen in r(20) syndrome. Frontal lobe epilepsy of any etiology has seizure phenomenology and EEG similarities with r(20) syndrome. The nocturnal EEG pattern in r(20) may also have features of Continuous Spike and Wave discharges in Slow Wave Sleep (CSWS) [32].

2.3. Treatment and outcome

Management of children with r(20) is based on each child's symptoms. The percentage of cells with the ring(20) in mosaic patients appears to be inversely correlated with response to anti-epileptic drugs [17,42]. From the review of published literature, no single drug is most effective, and medical intractability frequently leads to multiple antiepileptic drug exposure. Some authors report more favorable outcome with a combination of valproate and lamotrigine [8,9,32].

Epilepsy in r(20) syndrome is not amenable to resective surgery [13,43]. There are reports of improvement with vagus nerve stimulation (VNS) [44]. There are no published reports on the use of a ketogenic diet in patients with r(20) syndrome.

The long-term outcome of the syndrome is not well documented. However, r(20) patients, are at high risk of other complications of epilepsy including lethal status epilepticus [45]. There are no reported cases of sudden unexpected death in epilepsy in r(20) patients, even though it is a possible occurrence in all drug resistant epilepsies [46].

3. Genetics

3.1. Developmental origins and ring morphology

The diagnosis of ring chromosome 20 syndrome requires identification of the ring chromosome by cytogenetic techniques (as opposed to array-based studies), as not all rings are associated with deletions or duplications. In each case, the ring chromosome replaces one of the normal chromosome 20s and has been found in patients in both a mosaic and non-mosaic form. Supernumerary ring chromosome 20s (with two normal 20's in addition to the ring), have also been reported. However, these patients present with growth

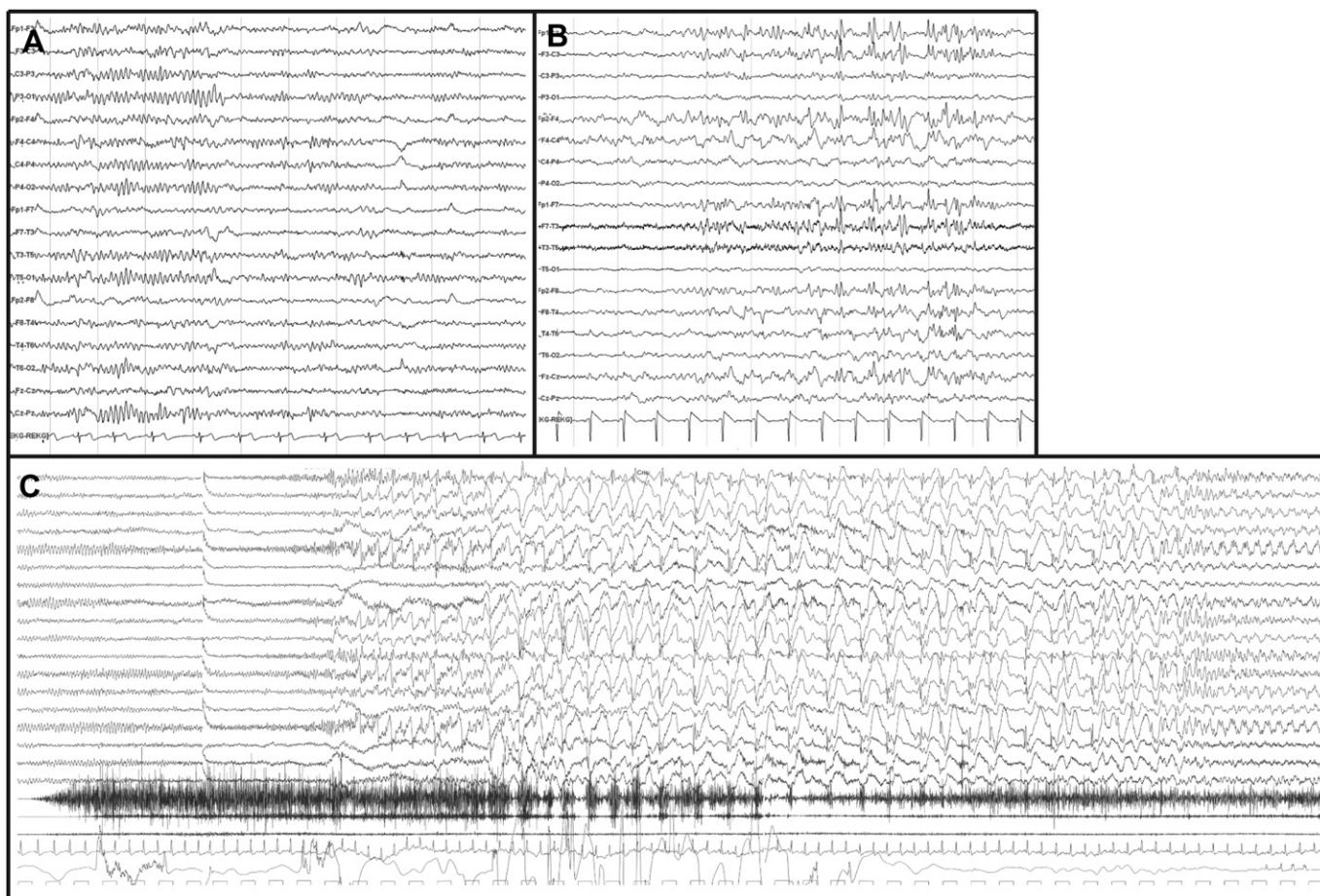


Fig. 1. (A) Normal waking EEG. (B) Typical finding of bi-frontal sharp waves in the interictal EEG of a r(20) patient. (C) Ictal EEG recording during non-convulsive status epilepticus characterized by diffuse low voltage activity following by recruiting rhythm over the frontal areas. After 15–20 s there is appearance of discharges of sharp and slow waves with anterior predominance. Clinically, the patient showed motor ictal semiology (tonic contraction of both arms followed by a clonic phase with right predominance).

retardation, hand and foot abnormalities and other non-specific dysmorphic features, but they do not have seizures [47].

In ring chromosome 20 syndrome, the ring chromosomes have been reported in multiple tissues and have been seen prenatally in both amniotic fluid and chorionic villous samples, as well as in post-natal blood, lymphocytes and skin. The percentage of cells containing the ring in patients described in the literature ranges from a few percent up to 100%. Initial attempts to better understand the link between the ring chromosome and the clinical phenotype looked for correlations between ring percentage and different clinical features such as age of onset of seizures, frequency of seizures and resistance to antiepileptic drugs. From these early reports, trends began to emerge suggesting that the age of seizure onset and resistance to drugs inversely correlated with the percentage of cells containing the ring chromosome [9,30]. Recent molecular characterizations of two larger cohorts of r(20) patients with array-based technologies has added further support to these trends (Fig. 2) while also demonstrating that seizure frequency has no dependence on ring load in the tissues studied [17,48]. In addition, these recent studies have begun to unravel details about the mechanism of ring formation, suggesting that two distinct classes of ring 20 chromosomes exist with different developmental origins and ring molecular structure (Fig. 3).

The majority of patients present with a mosaic chromosomal composition by karyotype with some percentage of cells having two normal chromosome 20s and the other cells with one chromosome 20 replaced by a ring (Fig. 3). Note that this definition of mosaicism

should be contrasted with the phenomenon of “dynamic mosaicism” in which secondary abnormalities are a common observation [1,49]. These secondary abnormalities include metaphases that may display duplicated rings, broken rings with altered chromosomal banding as well as loss of the ring chromosome (Fig. 4). While these abnormalities represent a form of mosaicism, they are found in all patients with rings, and the additional abnormalities stem from

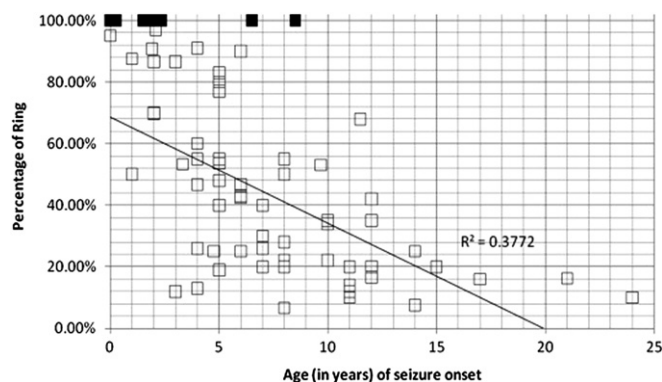


Fig. 2. Correlation of age of seizure onset and percentage of abnormal cells detected cytogenetically. Mosaic patients (□) were reported with an abnormal karyotype that contained some metaphases with two normal chromosome 20s, while non-mosaic (■) patients were reported with an abnormal karyotype containing no detectable normal cells.

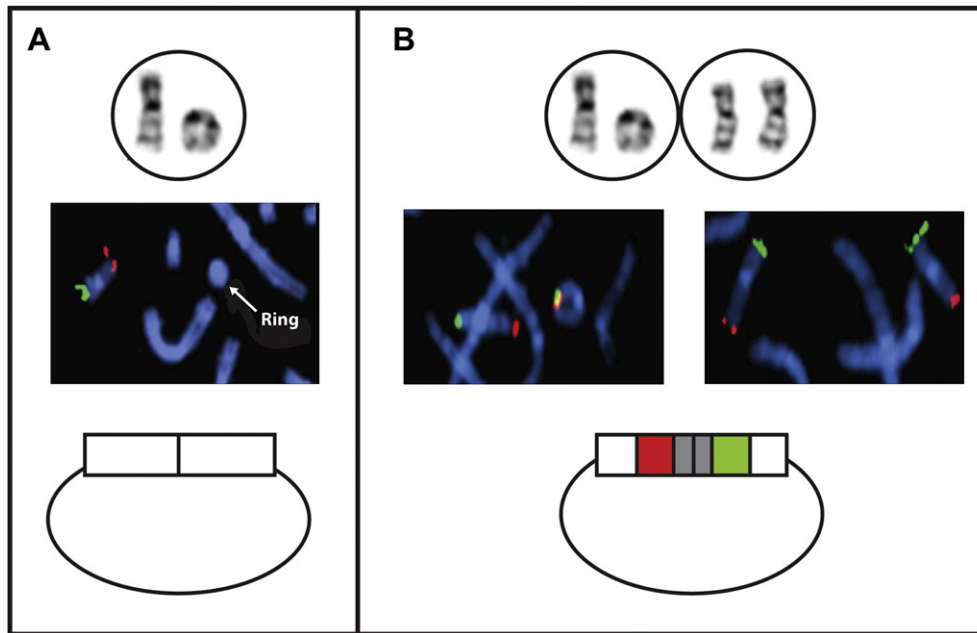


Fig. 3. (A) Non-mosaic ring sample with no normal cells present. Fluorescence *in situ* hybridization (FISH) with subtelomere probes (green = 20p, red = 20q) demonstrates that this non-mosaic ring has subtelomere deletions at one or both arms. (B) Mosaic ring sample with subtelomere repeats intact.

abnormal replication of the ring chromosomes. A true mosaic is an individual who contains a cell line with two normal chromosome 20s, while a non-mosaic is an individual who lacks a normal cell line. Individuals without a normal cell line have a more severe phenotype.

In two independent studies using chromosomal microarray analysis, individuals who were found to be mosaic by conventional cytogenetics, had no detectable terminal deletions on the array [8,17]. The absence of subtelomere repeat deletions via FISH further suggests that these rings were formed by direct telomere–telomere fusions [8,9,12,16,17,25,28,31,48]. The lack of deletions in mosaic patients is also supported by earlier cases in which FISH was carried out using subtelomere and telomere probes [16]. Two different developmental mechanisms can explain mosaicism with a cell line with two normal 20s. The first involves post-zygotic fusion of telomeres in a single cell, with all descendants of that cell inheriting the aberration, while the second posits the presence of the ring chromosome from fertilization with subsequent ring opening or ring loss followed by monosomy rescue. Given data generated using genotyping markers, both Conlin et al. (2010) and Giardino et al. (2010) were able to rule out uniparental disomy caused by the latter, suggesting that *de novo* rings in mosaic patients form post-zygotically after fertilization [17,48]. R(20) syndrome appears *spontaneously* in most individuals; however, there have been a few exceptional families reported where a mosaic ring is passed from one generation to the next [5,8,9]. This has also been shown for rings of other chromosomes besides chromosome 20, and it has been hypothesized that there may be an inherited instability of the chromosome involved leading either to *de novo* reformation of the ring or to opening of the ring in the second generation [6,17].

In contrast to those patients with mosaicism for the ring chromosome, a second group of patients presents with an abnormal karyotype containing a ring chromosome in every cell analyzed. Developmentally, the uniform presence of cells containing two normal chromosome 20s implies that the rings formed at the single cell stage, or earlier during meiosis (i.e. in the egg or sperm prior to fertilization). The rings in all of these patients were found to have

a deletion of either the p or q subtelomere (or both) [17,26,27,29]. Since no consensus breakpoint has been found for patients analyzed by chromosomal microarray analysis, it suggests that random chromosomal breakage and fusion and not sequence-mediated fusion is the underlying mechanism of ring formation. Non-mosaic patients present with seizures earlier in childhood and often with more severe phenotypes consistent with the correlation between ring percentage and age of seizure onset [17,48]. Since these patients also have deleted genomic content, the more severe phenotypes, including some minor dysmorphisms, may be associated with haploinsufficiency of genes in the deleted regions.

3.2. Molecular etiology

Despite the strong relationship between the presence of the ring chromosome and the seizure phenotype, the biological mechanism by which the ring chromosome causes seizures has remained elusive. Several hypotheses have been proposed including: (1) the deletion of candidate genes near the telomeres, (2) epigenetic silencing of gene expression through a telomere position effect, (3) uniparental disomy for chromosome 20 and (4) the deleterious effect of ring instability on cellular function and proliferation. The presence of two known epilepsy genes, *CHRNA4* and *KCNQ2*, within 1.0 Mb of the telomere of the long arm of chromosome 20 at band 20q13.3 led to the early suggestions that the seizures were due to alterations of these candidate genes; however, current data does not support this for several reasons. Mutations in *KCNQ2* (potassium voltage gated channel, KQT-like subfamily, member 2), have been associated with benign familial, neonatal seizures (BFNS; OMIM#: 602235). In this disorder, seizures develop a few hours to a few days after birth, and the seizures resolve spontaneously, although affected individuals may be at higher risk for the development of secondary epilepsies. The *KCNQ2* mutations identified include missense, nonsense, and insertions and deletions, consistent with haploinsufficiency as the mechanism of disease causation [50]. Mutations in *CHRNA4* (Acetylcholine receptor, neuronal nicotinic, alpha-4 subunit) have been associated with autosomal

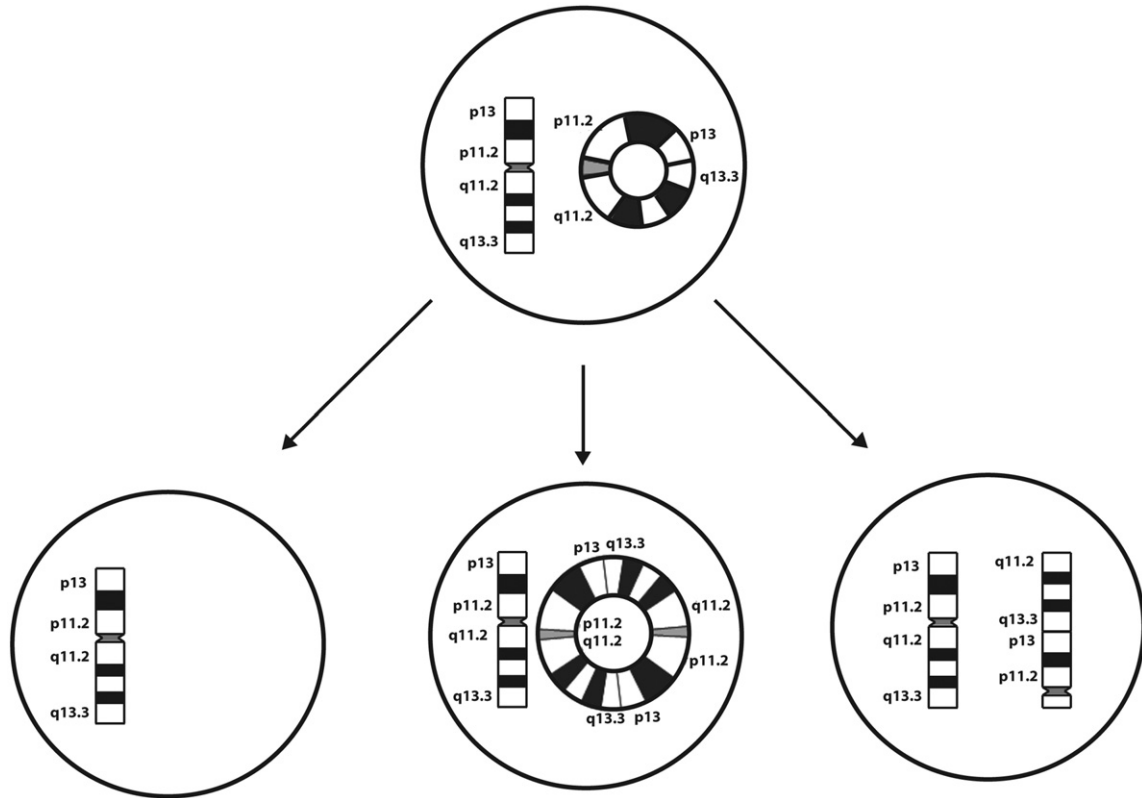


Fig. 4. Dynamic mosaicism is illustrated, with secondary findings such as monosomy 20, dicentric rings and opened rings.

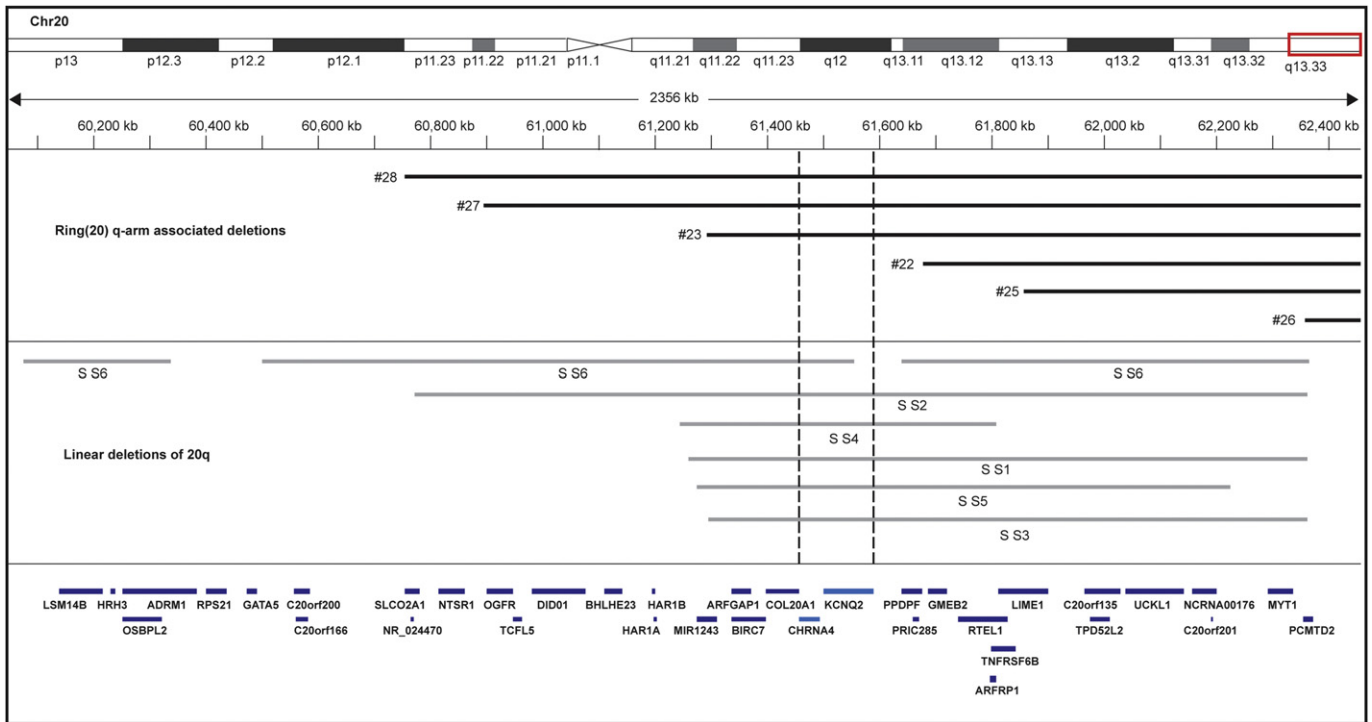


Fig. 5. Array results from patients with deletions of 20q. Deletions present on ring chromosomes [17] (black) and deletions from patients with terminal deletions [55] (gray) are both presented. Unique genes in the subtelomeric regions are shown below (RefSeq;hg18). Patient identifiers were conserved from the original publications. The CHRNA4 and KCNQ2 genes are presented in a lighter color, it is notable that not all ring chromosome 20 patients have deletions of these genes, although they all have seizures [17].

dominant frontal lobe epilepsy (ADNFLE; OMIM#:600513). Associated mutations are either missense, or in-frame insertions, which have been hypothesized to cause disease via a dominant-negative mechanism [51,52]. Although neither of these phenotypes is consistent with that seen in ring 20 patients, the severe epileptic phenotype was hypothesized to result from haploinsufficiency of both genes. However, a report of 2 patients with deletions involving both KCNQ2 and CHRNA4 has shown that affected individuals had BFNS, but did not show signs of ADNFLE or the seizure types typical of r(20) syndrome [50].

Furthermore, mapping of multiple ring 20 chromosomes has demonstrated that no consensus deletion is shared among r(20) patients (Fig. 5) [12,17]. In fact, a majority of the patients have apparently intact ring chromosomes without detectable deletions by FISH analysis; this suggests that the ring forms as a result of a direct telomere–telomere fusion [17]. Furthermore, patients with terminal deletions of either 20p or 20q do not share the phenotype associated with the ring chromosome 20 [53]. These cases also weaken the argument for a telomere position effect reducing expression of genes near the telomeres, since this form of haploinsufficiency should manifest in patients with complete loss of the terminal genes. Nonetheless, it can be argued that the effect of the ring structure on transcriptional regulation may be different from terminal chromosome deletions. Molecular analysis has also ruled out uniparental disomy for chromosome 20 as a cause of the r(20) associated seizures [17,48].

Future work characterizing expression levels from genes on the ring chromosome, now possible by RNA sequencing technologies, will provide the greatest insight into the effect chromosome structure on gene expression. In addition to interrogating the expression patterns from genes on the ring chromosome, RNA sequencing may also shed insight into global expression changes induced by cells possessing a ring chromosome. RNA sequencing may also address the hypothesis that there is a deleterious effect of ring instability on cellular function and proliferation, as we may learn that gene expression is not altered on the ring chromosome itself, but rather there may be perturbations of genes associated with cell growth and division.

4. Conclusion

Ring chromosome 20 syndrome is a rare disorder, but it is undoubtedly under-diagnosed due to the lack of a distinct clinical phenotype and absence of systemic malformations or dysmorphic features. The r(20) chromosome is best diagnosed by chromosome analysis in peripheral blood, as array-based techniques will not diagnose ring 20 in the two thirds of cases which are mosaic and do not have associated deletions or duplications [54]. Therefore, we recommend that chromosomal studies be carried out in all pediatric cases of epilepsy of frontal lobe origin, especially those with intractable seizures, behavioral disorders or cognitive impairment. While recent studies have begun to shed light on the structure of the ring chromosomes associated with this rare disorder, the underlying etiology of the clinical features associated with the presence of the ring chromosome 20 remains uncertain. New technologies associated with next generation sequencing of both DNA and RNA hold great promise to elucidate the precise structure of the ring chromosomes, and the changes in gene expression that are associated with the clinical symptoms of the ring chromosome 20.

Acknowledgments

We thank the Ring Chromosome 20 Foundation and all of the participating families for their support and involvement in our work. We are grateful to the Ring Chromosome 20 Foundation and

The Children's Hospital of Philadelphia Research Foundation for funding. R.D. was supported by Award number T32NS007413 from the National Institutes of Neurological Disorders and Stroke (NINDS). The content is the sole responsibility of the authors and does not necessarily represent the official views of the NINDS of the National Institutes of Health.

References

- [1] G. Kosztolanyi, The genetics and clinical characteristics of constitutional ring chromosomes, *J. Assoc. Genet. Technol.* 35 (2009) 44–48.
- [2] M.J. McGinniss, H.H. Kazazian Jr., G. Stetten, M.B. Petersen, H. Boman, E. Engel, F. Greenberg, J.M. Hertz, A. Johnson, Z. Laca, et al., Mechanisms of ring chromosome formation in 11 cases of human ring chromosome 21, *Am. J. Hum. Genet.* 50 (1) (1992) 15–28.
- [3] E. Rossi, M. Riegel, J. Messa, S. Gimelli, P. Maraschio, R. Ciccone, M. Stroppi, P. Riva, C.S. Perrotta, T. Mattina, L. Memo, A. Baumer, V. Kucinskas, C. Castellan, A. Schinzel, O. Zuffardi, Duplications in addition to terminal deletions are present in a proportion of ring chromosomes: clues to the mechanisms of formation, *J. Med. Genet.* 45 (3) (2008) 147–154.
- [4] A. Vazna, M. Havlovicova, Z. Sedlacek, Molecular cloning and analysis of breakpoints on ring chromosome 17 in a patient with autism, *Gene* 407 (1–2) (2008) 186–192.
- [5] E. Back, I. Voiculescu, M. Brunger, G. Wolff, Familial ring (20) chromosomal mosaicism, *Hum. Genet.* 83 (2) (1989) 148–154.
- [6] G. Kosztolanyi, K. Mehes, E.B. Hook, Inherited ring chromosomes: an analysis of published cases, *Hum. Genet.* 87 (3) (1991) 320–324.
- [7] M.D. Speevak, C. Smart, L. Unwin, M. Bell, S.A. Farrell, Molecular characterization of an inherited ring (19) demonstrating ring opening, *Am. J. Med. Genet. A* 121A (2) (2003) 141–145.
- [8] M.P. Canevini, V. Sgro, O. Zuffardi, R. Canger, R. Carrozzo, E. Rossi, D. Ledbetter, F. Minicucci, A. Vignoli, A. Piazzini, L. Guidolin, A. Saltarelli, B. dalla Bernardina, Chromosome 20 ring: a chromosomal disorder associated with a particular electroclinical pattern, *Epilepsia* 39 (9) (1998) 942–951.
- [9] E. Herrgard, T. Mononen, E. Mervaala, L. Kuusela, M. Aikia, U. Stenback, L. Paakkonen, R.L. Airaksinen, R. Kalviainen, More severe epilepsy and cognitive impairment in the offspring of a mother with mosaicism for the ring 20 chromosome, *Epilepsy Res.* 73 (1) (2007) 122–128.
- [10] G. Kosztolanyi, Does "ring syndrome" exist? An analysis of 207 case reports on patients with a ring autosome, *Hum. Genet.* 75 (2) (1987) 174–179.
- [11] M. Beri-Deixheimer, M.J. Gregoire, A. Toutain, K. Brochet, S. Briault, J.L. Schaff, B. Leheup, P. Jonveaux, Genotype–phenotype correlations to aid in the prognosis of individuals with uncommon 20q13.33 subtelomere deletions: a collaborative study on behalf of the 'association des Cytogeneticiens de langue Francaise', *Eur. J. Hum. Genet.* 15 (4) (2007) 446–452.
- [12] H. Elghezal, H. Hannachi, S. Mougou, H. Kammoun, C. Triki, A. Saad, Ring chromosome 20 syndrome without deletions of the subtelomeric and CHRNA4–KCNQ2 genes loci, *Eur. J. Med. Genet.* 50 (6) (2007) 441–445.
- [13] Y. Inoue, T. Fujiwara, K. Matsuda, H. Kubota, M. Tanaka, K. Yagi, K. Yamamori, Y. Takahashi, Ring chromosome 20 and nonconvulsive status epilepticus. A new epileptic syndrome, *Brain* 120 (Pt 6) (1997) 939–953.
- [14] A. Ottaviani, E. Gilson, F. Magdinier, Telomeric position effect: from the yeast paradigm to human pathologies? *Biochimie* 90 (1) (2008) 93–107.
- [15] E. Rossi, J. Messa, O. Zuffardi, Ring syndrome: still true? *J. Med. Genet.* 45 (11) (2008) 766–768.
- [16] Y.S. Zou, D.L. Van Dyke, E.C. Thorland, H.S. Chhabra, V.V. Michels, J.G. Keefe, M.A. Lega, M.A. Feely, T.S. Uphoff, S.M. Jalal, Mosaic ring 20 with no detectable deletion by FISH analysis: characteristic seizure disorder and literature review, *Am. J. Med. Genet. A* 140 (15) (2006) 1696–1706.
- [17] L.K. Conlin, W. Kramer, A.L. Hutchinson, X. Li, H. Riethman, H. Hakonarson, J.C. Mulley, I.E. Scheffer, S.F. Berkovic, S.A. Hosain, N.B. Spinner, Molecular analysis of ring chromosome 20 syndrome reveals two distinct groups of patients, *J. Med. Genet.* 48 (1) (2010) 1–9.
- [18] M. Gahr, F. Kerling, A. Ludolph, P. Plener, Cognitive impairment and abnormal Behaviour related to ring Chromosome 20 aberration, *J. Autism Dev. Disord.* (2011).
- [19] S. Giovannini, D. Frattini, A. Scarano, C. Fusco, G. Bertani, E. Della Giustina, P. Martinelli, D. Orteschi, M. Zollino, G. Neri, G. Gobbi, Partial epilepsy complicated by convulsive and nonconvulsive episodes of status epilepticus in a patient with ring chromosome 14 syndrome, *Epileptic Disord.* 12 (3) (2010) 222–227.
- [20] A.L. Nucaro, M. Falchi, T. Pisano, R. Rossino, F. Boscarelli, G. Stoico, A. Milia, C. Montaldo, C. Cianchetti, D. Pruna, Ring chromosome 14 mosaicism: an unusual case associated with developmental delay and epilepsy, characterized by genome array-CGH, *Am J Med. Genet. A* 152A (1) (2010) 234–236.
- [21] L.P. Tsai, K.F. Lee, J.S. Fang, I.Y. Liu, Molecular cytogenetic analysis and clinical manifestations of a case with de novo mosaic ring chromosome 7, *Mol. Cytogenet.* 4 (1) (2011) 5.
- [22] L. Atkins, W.L. Miller, M. Salam, A ring-20 chromosome, *J. Med. Genet.* 9 (3) (1972) 377–380.
- [23] R. Herva, I. Saarinen, L. Leikkonen, The r(20) syndrome, *J. Med. Genet.* 14 (4) (1977) 281–283.

- [24] P. Jalbert, H. Jalbert, B. Sele, D. Tachker, M. Bost, R. Meynard, H. Pison, Ring-20 chromosome: a new syndrome, *Ann. Genet.* 20 (4) (1977) 258–262.
- [25] P.B. Augustijn, J. Parra, C.H. Wouters, P. Joosten, D. Lindhout, W. van Emde Boas, Ring chromosome 20 epilepsy syndrome in children: electroclinical features, *Neurology* 57 (6) (2001) 1108–1111.
- [26] C.A. Brandt, O. Kierkegaard, J. Hindkjaer, P.K. Jensen, S. Pedersen, A.J. Therkelsen, Ring chromosome 20 with loss of telomeric sequences detected by multicolour PRINS, *Clin. Genet.* 44 (1) (1993) 26–31.
- [27] F.A. de Falco, P. Olivieri, A. de Falco, D. Concolino, F. Battaglia, R. Verardi, G. Grande, M. Stabile, Electroclinical evolution in ring chromosome 20 epilepsy syndrome: a case with severe phenotypic features followed for 25 years, *Seizure* 15 (6) (2006) 449–453.
- [28] F. Fortin, M. Beaulieu Bergeron, R. Fetni, N. Lemieux, Frequency of chromosome healing and interstitial telomeres in 40 cases of constitutional abnormalities, *Cytogenet. Genome Res.* 125 (3) (2009) 176–185.
- [29] D. Garcia-Cruz, A.I. Vasquez, D. Perez-Rulfo, N.O. Davalos, J. Penalzoza, J.E. Garcia-Ortiz, B. Patino-Garcia, J. Sanchez-Corona, Ring-20-syndrome and loss of telomeric regions, *Ann. Genet.* 43 (3–4) (2000) 113–116.
- [30] T. Nishiwaki, M. Hirano, M. Kumazawa, S. Ueno, Mosaicism and phenotype in ring chromosome 20 syndrome, *Acta Neurol. Scand.* 111 (3) (2005) 205–208.
- [31] A. Pezzolo, G. Gimelli, A. Cohen, A. Lavaggetto, C. Romano, G. Fogu, O. Zuffardi, Presence of telomeric and subtelomeric sequences at the fusion points of ring chromosomes indicates that the ring syndrome is caused by ring instability, *Hum. Genet.* 92 (1) (1993) 23–27.
- [32] A. Vignoli, M.P. Canevini, F. Darra, L. La Selva, E. Fiorini, A. Piazzini, F. Lazzarotto, C. Zucca, B. Dalla Bernardina, Ring chromosome 20 syndrome: a link between epilepsy onset and neuropsychological impairment in three children, *Epilepsia* 50 (11) (2009) 2420–2427.
- [33] D. Ville, A. Kaminska, N. Bahi-Buisson, A. Biraben, P. Plouin, L. Telvi, O. Dulac, C. Chiron, Early pattern of epilepsy in the ring chromosome 20 syndrome, *Epilepsia* 47 (3) (2006) 543–549.
- [34] J.S. MacLeod, J.K. Austin, Stigma in the lives of adolescents with epilepsy: a review of the literature, *Epilepsy Behav.* 4 (2) (2003) 112–117.
- [35] A. Roubertie, J. Petit, P. Genton, Ring chromosome 20: an identifiable epileptic syndrome, *Rev. Neurol. (Paris)* 156 (2) (2000) 149–153.
- [36] K. Kobayashi, M. Inagaki, M. Sasaki, K. Sugai, S. Ohta, T. Hashimoto, Characteristic EEG findings in ring 20 syndrome as a diagnostic clue, *Electroencephalogr. Clin. Neurophysiol.* 107 (4) (1998) 258–262.
- [37] J. Petit, A. Roubertie, Y. Inoue, P. Genton, Non-convulsive status in the ring chromosome 20 syndrome: a video illustration of 3 cases, *Epileptic Disord.* 1 (4) (1999) 237–241.
- [38] M. Gonzalez-Delgado, J. Salas, I. Hernando, S. Calleja, C. Hernandez, Ring chromosome 20: a distinctive syndrome identifiable by electroclinical diagnosis, *Neurologia* 19 (4) (2004) 215–219.
- [39] N. Tanaka, K. Kamada, F. Takeuchi, Ictal magnetoencephalographic study in a patient with ring 20 syndrome, *J. Neurol. Neurosurg. Psychiatry* 75 (3) (2004) 488–490.
- [40] A. Biraben, F. Semah, M.J. Ribeiro, G. Douaud, P. Remy, A. Depaulis, PET evidence for a role of the basal ganglia in patients with ring chromosome 20 epilepsy, *Neurology* 63 (1) (2004) 73–77.
- [41] A. Del Sole, V. Chiesa, G. Lucignani, A. Vignoli, L. Giordano, M. Lecchi, M.P. Canevini, Exploring dopaminergic activity in ring chromosome 20 syndrome: a SPECT study, *Q. J. Nucl. Med. Mol. Imaging* 54 (5) (2010) 564–569.
- [42] D. Giardino, A. Vignoli, L. Ballarati, M.P. Recalcati, S. Russo, N. Camporeale, M. Marchi, P. Finelli, P. Accorsi, L. Giordano, F. La Briola, V. Chiesa, M.P. Canevini, L. Larizza, Genetic investigations on 8 patients affected by ring 20 chromosome syndrome, *BMC Med. Genet.* 11 (2010) 146.
- [43] Personal Communication.
- [44] J.R. Parr, K. Pang, A. Mollett, Z. Zaiwalla, R. Selway, D. McCormick, S. Jayawant, Epilepsy responds to vagus nerve stimulation in ring chromosome 20 syndrome, *Dev. Med. Child. Neurol.* 48 (1) (2006) 80 Author reply 80.
- [45] J. Jacobs, G. Bernard, E. Andermann, F. Dubeau, F. Andermann, Refractory and lethal status epilepticus in a patient with ring chromosome 20 syndrome, *Epileptic Disord.* 10 (4) (2008) 254–259.
- [46] L.J. Hirsch, E.J. Donner, E.L. So, M. Jacobs, L. Nashef, J.L. Noebels, J.R. Buchhalter, Abbreviated report of the NIH/NINDS workshop on sudden unexpected death in epilepsy, *Neurology* 76 (22) (2011) 1932–1938.
- [47] N. Guediche, S. Brisset, J. J. Benichou, N. Guerin, P. Mabboux, M. L. Maurin, C. Bas, M. Laroudie, O. Picone, D. Goldszmidt, S. Prevot, P. Labrune, G. Tachdjian, Chromosomal breakpoints characterization of two supernumerary ring chromosomes 20, *Am. J. Med. Genet. A* 152A (2) 464–471.
- [48] D. Rusconi, E. Valtorta, O. Rodeschini, D. Giardino, I. Lorenzo, B. Predieri, M. Losa, L. Larizza, P. Finelli, Combined characterization of a pituitary adenoma and a subcutaneous lipoma in a MEN1 patient with a whole gene deletion, *Cancer Genet.* 204 (6) 309–315.
- [49] G. Kosztolanyi, Decreased cell viability of fibroblasts from two patients with a ring chromosome: an in vitro reflection of growth failure? *Am. J. Med. Genet.* 28 (1) (1987) 181–184.
- [50] H. Kurahashi, J.W. Wang, A. Ishii, T. Kojima, S. Wakai, T. Kizawa, Y. Fujimoto, K. Kikkawa, K. Yoshimura, T. Inoue, S. Yasumoto, A. Ogawa, S. Kaneko, S. Hirose, Deletions involving both KCNQ2 and CHRNA4 present with benign familial neonatal seizures, *Neurology* 73 (15) (2009) 1214–1217.
- [51] O.K. Steinlein, A. Magnusson, J. Stoodt, S. Bertrand, S. Weiland, S.F. Berkovic, K.O. Nakken, P. Propping, D. Bertrand, An insertion mutation of the CHRNA4 gene in a family with autosomal dominant nocturnal frontal lobe epilepsy, *Hum. Mol. Genet.* 6 (6) (1997) 943–947.
- [52] O.K. Steinlein, J.C. Mulley, P. Propping, R.H. Wallace, H.A. Phillips, G.R. Sutherland, I.E. Scheffer, S.F. Berkovic, A missense mutation in the neuronal nicotinic acetylcholine receptor alpha 4 subunit is associated with autosomal dominant nocturnal frontal lobe epilepsy, *Nat. Genet.* 11 (2) (1995) 201–203.
- [53] R. N. Traylor, D. L. Bruno, T. Burgess, R. Wildin, A. Spencer, D. Ganesamoorthy, D. J. Amor, M. Hunter, M. Caplan, J. A. Rosenfeld, A. Theisen, B. S. Torchia, L. G. Shaffer, B. C. Ballif, H. R. Slater, A genotype-first approach for the molecular and clinical characterization of uncommon de novo microdeletion of 20q13.33, *PLoS One* 5 (8) e12462.
- [54] D. T. Miller, M. P. Adam, S. Aradhya, L. G. Biesecker, A. R. Brothman, N. P. Carter, D. M. Church, J. A. Crolla, E. E. Eichler, C. J. Epstein, W. A. Faucett, L. Feuk, J. M. Friedman, A. Hamosh, L. Jackson, E. B. Kaminsky, K. Kok, I. D. Krantz, R. M. Kuhn, C. Lee, J. M. Ostell, C. Rosenberg, S. W. Scherer, N. B. Spinner, D. J. Stavropoulos, J. H. Tepperberg, E. C. Thorland, J. R. Vermeesch, D. J. Waggoner, M. S. Watson, C. L. Martin, D. H. Ledbetter, Consensus statement: chromosomal microarray is a first-tier clinical diagnostic test for individuals with developmental disabilities or congenital anomalies, *Am. J. Hum. Genet.* 86(5), 749–764.
- [55] R. Traylor, D. Bruno, T. Burgess, R. Wildin, A. Spencer, D. Ganesamoorthy, D. Amor, M. Hunter, M. Caplan, J. Rosenfeld, A. Theisen, B. Torchia, L. Shaffer, B. Ballif, H. Slater, A genotype-first approach for the molecular and clinical characterization of uncommon de novo microdeletion of 20q13.33, *PLoS One* 5 (8) (2010).