

Mild head injury increasing the brain's vulnerability to a second concussive impact

HELMUT L. LAURER, M.D., FLORENCE M. BAREYRE, VIRGINIA M. Y. C. LEE, PH.D., JOHN Q. TROJANOWSKI, M.D., PH.D., LUCA LONGHI, M.D., RACHEL HOOVER, KATHRYN E. SAATMAN, PH.D., RAMESH RAGHUPATHI, PH.D., SHIGERU HOSHINO, M.D., M. SEAN GRADY, M.D., AND TRACY K. MCINTOSH, M.D., PH.D.

The Head Injury Center, Department of Neurosurgery, and Department of Pathology and Laboratory Medicine, University of Pennsylvania School of Medicine; and The Veterans Administration Medical Center, Philadelphia, Pennsylvania

Object. Mild, traumatic repetitive head injury (RHI) leads to neurobehavioral impairment and is associated with the early onset of neurodegenerative disease. The authors developed an animal model to investigate the behavioral and pathological changes associated with RHI.

Methods. Adult male C57BL/6 mice were subjected to a single injury (43 mice), repetitive injury (two injuries 24 hours apart; 49 mice), or no impact (36 mice). Cognitive function was assessed using the Morris water maze test, and neurological motor function was evaluated using a battery of neuroscore, rotarod, and rotating pole tests. The animals were also evaluated for cardiovascular changes, blood–brain barrier (BBB) breakdown, traumatic axonal injury, and neurodegenerative and histopathological changes between 1 day and 56 days after brain trauma. No cognitive dysfunction was detected in any group. The single-impact group showed mild impairment according to the neuroscore test at only 3 days postinjury, whereas RHI caused pronounced deficits at 3 days and 7 days following the second injury. Moreover, RHI led to functional impairment during the rotarod and rotating pole tests that was not observed in any animal after a single impact. Small areas of cortical BBB breakdown and axonal injury, observed after a single brain injury, were profoundly exacerbated after RHI. Immunohistochemical staining for microtubule-associated protein-2 revealed marked regional loss of immunoreactivity only in animals subjected to RHI. No deposits of β -amyloid or tau were observed in any brain-injured animal.

Conclusions. On the basis of their results, the authors suggest that the brain has an increased vulnerability to a second traumatic insult for at least 24 hours following an initial episode of mild brain trauma.

KEY WORDS • axonal injury • blood–brain barrier • cognition • dendritic injury • histology • neurodegeneration • mouse

AN estimated 2 million cases of TBI occur in the United States every year, with approximately 500,000 cases sufficiently serious to require hospitalization.⁹⁶ The majority of patients do not seek professional medical help or are discharged immediately after examination with their injuries classified as mild or minor TBI;^{38,64} however, a number of patients complain of persisting postconcussive symptoms beyond the first few weeks of recovery.^{7,50} Many are likely to incur a second

TBI,^{8,13} particularly those who engage in contact/collision sports, such as boxing, football, soccer, and ice hockey,^{8,56,95} as well as victims of domestic spousal violence⁸¹ or child abuse.^{18,49}

Interest in RHI has increased markedly because authors of a growing number of studies have suggested cumulative effects following RHI. An increasing body of evidence indicates that sports in addition to boxing may carry the potential risk for permanent damage due to repetitive injuries of mild severity to the brain.^{24,56,57} Additionally, the risk of developing neurodegenerative disease later in life (for example, dementia pugilistica) is increased after repetitive brain trauma, even when the initial injury was not severe enough to result in long-lasting disability or impairment.^{26,43,73} A number of clinical investigations have described the pathological sequelae of mild RHI.^{4,30,56,95} To date, however, only two experimental studies of repetitive TBI have been published, and their authors have reported increased vascular permeability, behavioral dysfunction,

Abbreviations used in this paper: A- β = β -amyloid peptide; ANOVA = analysis of variance; β -APP = β -amyloid precursor protein; BBB = blood–brain barrier; BP = blood pressure; DABP = diastolic arterial BP; IgG = immunoglobulin G; MABP = mean arterial BP; MAP-2 = microtubule-associated protein 2; MWM = Morris water maze; NHS = normal horse serum; PBS = phosphate-buffered saline; RHI = repetitive head injury; RP = rotating pole; SABP = systolic BP; SEM = standard error of the mean; TAI = traumatic axonal injury; TBI = traumatic brain injury.

and cytoskeletal abnormalities in rabbits and in rats.^{45,72} Several recent clinical reports have led to an enhanced recognition of the potential risks associated with RHI as a result of participating in contact/collision sports. The shortcomings of existing epidemiological and clinical investigations, however, warrant a comprehensive experimental investigation to characterize pathophysiological changes and elucidate mechanisms underlying the sequelae of RHI. Current guidelines permit reentry of players into sporting events within 24 hours after an initial concussion. To address this and specifically investigate the possible cumulative effects of multiple traumatic insults to the brain, we subjected mice to a single mild TBI and subjected a subgroup of these animals to a second mild injury 24 hours later. We used clinically relevant outcome measurements, such as cardiovascular parameters; neurobehavioral tests of memory, learning, and neurological motor function; and detailed histological evaluation of BBB integrity, cell death, traumatic axonal and dendritic injury, and pathological changes associated with neurodegenerative diseases. We have developed an experimental model that can be used to facilitate our understanding of the molecular and cellular sequelae of repetitive, mild brain injury.

Materials and Methods

Animal Preparation

A total of 137 8- to 10-week-old adult male C57BL/6 mice were used in all experiments. The animals were housed in cages of four in an animal housing unit for at least 1 week before the experiments commenced. The mice were maintained at a constant temperature with a 12-hour light/12-hour dark cycle and were given unlimited access to food and water. After injury or neurobehavioral testing, which were performed during the light-on period, the animals were returned to their home cages.

Surgical Procedure

All animal procedures were conducted in strict accordance with the National Institutes of Health Guide for the Care and Use of Laboratory Animals⁶⁹ and were approved by the Institutional Animal Care and Use Committee of the University of Pennsylvania. One hundred twenty-eight animals were initially anesthetized with pentobarbital (65 mg/kg body weight administered intraperitoneally) and placed on a heating pad to maintain body temperature during surgery. Each animal was placed in a stereotactic frame, and ointment was applied to the eyes to protect vision during surgery. A skin incision was performed and the skull was exposed. One group of 92 animals remained in the stereotactic head frame and was subjected to a single impact, which was delivered by a pressure-driven injury device that was mechanically identical to a previously described controlled cortical impact device.^{16,88} The impounder was rigidly mounted at an angle 20° from the vertical plane. Because no trephination of the skull was performed, the impactor tip was modified to reduce the incidence of skull fracture for this study. Material constants of the impactor and the diameter of the contact area determine the fracture threshold;⁶² therefore, the diameter of the impactor tip was increased to 6 mm and covered with rubber. Using these modifications we achieved a very low fracture rate after concussive TBI in our set of animals (three of 92 traumatized mice).

To obtain a zero point, the impactor tip was carefully lowered until it touched the intact skull in the left parietotemporal region, midway between the lambda and bregma. During impact the tip was driven pneumatically 1 mm farther than the zero point, which caused a nonpenetrating blow to the exposed skull. The duration of impact was kept constant and velocity ranged from 4.8 to 5.6 m/second. The animal's head was fixed in a stereotactic frame. Although

head movements have been shown to influence the type of injury,^{54,77} concussive-like TBI can be produced with the head immobilized.^{91,92} The procedure was completed with closure of the incision, which was performed using No. 4-0 silk sutures. Each animal was removed from the stereotactic frame, placed in a heated cage, and following recovery from anesthesia (as evidenced by ambulation), returned to its home cage.

Twenty-four hours after the first injury, a subgroup of 49 animals was again anesthetized by intraperitoneal administration of the same anesthetic agent (pentobarbital, 65 mg/kg body weight) and subjected to a second mild concussive brain injury in the identical location over the left parietotemporal region (RHI group). Thirty-six sham-injured animals were anesthetized and placed in the stereotactic frame, where the skull was exposed and the skin incision was sutured closed without brain injury.

Cardiovascular Measurements

A group of nine additional mice was subjected to a single TBI followed 24 hours later by a second mild TBI and evaluated for changes in BP after each brain injury to monitor whether the mice may have been exposed to secondary insults such as hypotension, which could influence our results. We chose to monitor arterial BP by using a noninvasive computerized tail-cuff system. The BP was recorded by placing one occlusion cuff (proximal) and one sensor cuff (distal) at the base of the tail. The cuffs were connected to a computer via a monitor interface. Individual BP measurements were made using this system over a 15-second period, which included inflation of the occlusion cuff, during which the tail blood flow was progressively reduced and stopped. The sensor cuff was used to detect the signal from the blood flow in the tail, which was sent to the computer to display the measured SABP, DABP, and the calculated MABP according to the following formula: $MABP = DABP + (SABP - DABP)/3$.

During all cardiovascular studies, tail temperature was maintained at 38°C by using a specific warmer and thermometer. Blood pressure was monitored in the anesthetized mice before the first head injury and at regular 5-minute intervals following brain injury over a 1-hour observation period. Twenty-four hours later, at the time of the second injury, BP was again measured after induction of anesthesia and prior to injury, to evaluate whether the second dose of anesthetic agent could cause hypotension. Blood pressure was then measured at regular intervals of 5 minutes throughout a 1-hour postinjury study period. This paradigm allowed us to repeat BP measurements in the same group of animals (paired analysis) before and after the first and second injuries.

Using this method, noninvasive measurement of BP in mice is reproducible and the data obtained have been shown to correlate with data obtained using intraarterial BP measurements.⁴⁸ One advantage of this noninvasive monitoring system is that it permits monitoring of BP without the necessity of maintaining the animals in a forced supine position, because it has been reported that detrimental effects of hypotension following mild concussion can persist for as long as 45 to 60 minutes postinjury.⁴¹

Assessment of Cognitive Function

The training and memory testing paradigm afforded by the MWM used in this study has been previously described in detail for the mouse following TBI.^{66,85,87,88} Briefly, the MWM is a circular pool 1 m in diameter that is painted white inside.⁶⁵ The water (16–18°C) filling the pool is made opaque by adding nontoxic, water-soluble white paint. Fifty mice were trained during 10 trials per day for 2 consecutive days prior to injury to locate a stationary, submerged platform (0.5 cm below the surface) by using external cues. The essential feature of the maze is that animals can escape from the cold water onto the platform after being placed randomly at one of four sites in the pool. Only mice demonstrating the ability to find the platform (average latency < 20 seconds in nine of 10 training trials on Day 2) were used in the experiments. Using this criterion, five animals were excluded from further assessment of posttraumatic cognitive function. At 7 days following head injury, 11 sham-injured animals, 17 animals subjected to a single TBI, and 17 animals that received RHI were tested for memory retention of the visuo-

Repetitive head injury in the mouse

spatial task. The platform was removed, and all mice were given 1 minute to swim in the MWM while a computer-video unit recorded their swimming patterns. Scores were assigned according to time spent in various zones of the MWM, and a memory score was calculated weighting the time spent in each zone according to the proximity to the previous platform site.^{66,85,87,88}

To test for impairment of learning ability, a separate group of mice (15 sham-injured animals, 16 animals subjected to a single TBI, and 16 animals subjected to an RHI) received no training in the MWM prior to injury. At 56 days postinjury, these animals were tested for their ability to learn the visuospatial task in the MWM over a 2-day period, following the identical protocol described earlier, and were tested the following day (Day 58) for retention of the learned task (probe trial), details of which were originally described in the rat.^{1,75}

Motor Function

To avoid the possibility of fatigue contributing to results in the multiple tests used for evaluation of neurological motor function, we restricted the number of tests to two for each animal. Therefore, animals were randomly assigned to different tests prior to injury or sham (control) surgery.

Composite Neuroscore. The composite neuroscore includes the results of a battery of tests that previously was used to detect motor function impairment following TBI in the rat^{60,61} and, after modification, in the mouse.^{66,88,85} It consists of the following: 1) forelimb flexion response during suspension by the tail; 2) resistance to lateral pulsion; and 3) response of the hindlimb and toes (hindlimb flexion) when raised by the tail. At 3 days and 7 days (23 sham-injured mice, 25 mice with a single TBI, and 27 mice with RHI), and at 14, 21, 28, and 56 days postinjury (14 sham-injured mice, 16 mice with a single TBI, and 16 mice with RHI), an investigator blinded to the injury status of the animal gave each animal a score ranging from 4 (preinjury control status) to 0 (afunctional). The neuroscore assessment also included the ability of the animal to stand in place in each of four directions (facing up, down, to the right, and to the left) on an inclined plane (angle board) as the height of the board (angle) was decreased. The maximum angle at which the animal could stand for a duration of 5 seconds was recorded before and after injury, and the animal was given a score based on the difference between preinjury and postinjury performance, where 0° = 4, 2.5° = 3, 5° = 2, 7.5° = 1, and 10° or more = 0. Scores for all four directions were averaged and summed with other test scores for a maximum possible composite neuroscore of 15 points.

Rotarod Performance Test. The rotarod performance test is a reliable indicator of motor deficits after experimental TBI in rats³³ and has been modified for evaluation of motor deficits in mice.^{21,22,66,78,85} Motor function was assessed by recording the latency period during which the animal remained on a rotating rod. The rod (36-mm outer diameter) had a rubber surface and rotated with an initial velocity of 1 cm/second and an acceleration of 1.75 rpm/second. Animals were acclimated to the rotarod test prior to injury, and the trial was terminated if the animal fell completely off the rod or gripped the device and spun around past the lowest point. Four trials were performed at intervals of 5 minutes each, and the two middle latencies measured at 3, 7, 14, 21, 28, and 56 days after injury were averaged to yield a performance value for each animal over the entire evaluation period (11 sham-injured mice, 12 mice with a single TBI, and 12 mice with RHI), according to previously published protocols.³³

Rotating Pole Test. The RP device was previously developed and characterized to evaluate motor dysfunction following cerebral ischemia⁴² or TBI in rats.⁵⁸ To acclimate mice prior to injury, animals were placed onto the platform of the device and kept there for 10 minutes. Then the mice were trained to walk across a wooden pole, 3 cm in diameter and 85 cm in length, while the pole was stationary or rotating at 1, 3, or 5 rpm in either direction, and the animal's faulty steps, or footfaults, were recorded. Following brain injury, the RP test was assessed at 3 days and 7 days (12 sham-injured mice, 15 mice with a single TBI, and 16 mice with RHI), and at 14, 21, 28, and 56 days (nine sham-injured mice, 10 mice

with a single TBI, and 11 mice with RHI) by recording the number of footfaults (slips) during two trials, which were performed with the pole stationary or rotating at each of the training speeds (1, 3, and 5 rpm) in either direction (left and right). Because the previously described scoring method⁵⁸ was not applicable to the mouse, the count of footfaults in all these trials was made and the raw data were summed for each mouse and then statistically compared.

Histological Analysis. A broad variety of studies investigating posttraumatic sequelae in mouse models in our laboratory and others have been conducted with a planned animal survival time of 1 week after TBI.^{11,66,67,78,87} It therefore seemed reasonable to begin a thorough investigation for transient histological effects at that specific time point. Authors of other studies, however, have pointed out that trauma-induced neurodegeneration seems to be an ongoing process, revealed by an increase in cortical damage over time^{10,12,85} and axonal damage occurring for weeks.^{10,51,75} To assess more slowly developing histological alterations, a time point 8 weeks postinjury was also chosen. At either time point, the animals (seven–nine/time point/group) were given an overdose of anesthetic agent (sodium pentobarbital, 200 mg/kg) and were perfused intracardially with heparinized saline followed by 4% paraformaldehyde in 0.1 M phosphate buffer (pH 7.4). The mice were decapitated and their brains were stored overnight at 4°C in fixative. The following day the brains were removed, cut into 2-mm-thick coronal blocks, transferred to 0.1 M phosphate buffer (pH 7.4), processed in an automated tissue processor, and embedded in paraffin. Six-micron-thick coronal sections were cut on a microtome and stained with cresyl violet. The results of previous experimental studies have suggested that the hippocampal CA3 region and the apex of the hilum of the dentate gyrus are selectively vulnerable to TBI in mice.^{66,67,87,88} Therefore, cell counts were performed at a site 1.8 mm posterior to bregma in these regions with damaged neurons identified by criteria previously established in the rat.^{52,98} One slide per animal was randomly chosen, and cell counts were performed at a magnification of × 200. Starting at the junction of CA2 and CA3,²³ three consecutive microscopic fields were counted in the hippocampal CA3 pyramidal layer. To count cells in the hilum of the dentate gyrus of the hippocampus, the medial end of the CA3 cell layer was located on the identical slide, and all cells between the upper and the lower blade of the dentate gyrus were counted according to a protocol established for the rat.^{52,98} All cell counting was performed by one investigator (S.H.) who was blinded to the injury status of each animal.

Immunohistochemical Analysis

Integrity of the BBB. Immunohistochemical analysis for mouse IgG was used to assess the integrity of the BBB. Because disruption of the BBB is an early event after TBI,⁹³ the animals were given an overdose of sodium pentobarbital (200 mg/kg administered intraperitoneally) 1 day or 2 days after a single TBI (five mice/time point), sham injury (two mice/time point), or 1 day after RHI (that is, 2 days after the first injury, five mice). The animals were killed by intracardiac perfusion with 4% paraformaldehyde in 0.1 M phosphate buffer (pH 7.4). The brains were removed and placed in fixative for 1 hour. Coronal sections (50 μm thick) were cut from the level of the anterior caudate to the lower medulla oblongata on a vibratome. Immunoglobulin G immunoreactivity was detected using a previously described protocol⁸⁸ with biotinylated horse anti-mouse IgG (concentration 1:100) as the primary antibody, followed by avidin-biotin-horseradish peroxidase complex (concentration 1:1000; ABC Elite kit), and *p*-dimethylaminoazobenzene as the chromogen. Adjacent sections incubated with NHS/PBS instead of primary antibody served as negative controls.

Traumatic Axonal Injury. Immunostaining for β-APP has been shown to be a sensitive indicator of TAI after mild head injury.^{6,59} Immunohistochemical analysis for β-APP was performed on paraffin-embedded, 6-μm-thick sections taken from a site 1.8 mm posterior to bregma. Brains from animals killed at 7, 28, or 56 days after sham surgery, single TBI, or RHI (four–seven mice/time

point/group). After deparaffinization, sections were heated in a microwave oven for 5 minutes for antigen retrieval and incubated with mouse anti- β -APP (concentration 1:40), as previously described.⁷⁶ Adjacent slides incubated with NHS/PBS instead of primary antibody served as immunological negative controls.

Because gross observations of our slides indicated that the ipsilateral thalamus displayed the greatest level of β -APP accumulation, this region was chosen for quantification. Therefore, images of the ipsilateral thalamus located 1.8 mm posterior to bregma were captured for each animal by using an image analysis system. Threshold optical density was obtained to discriminate background from positive immunoreactivity, and the total area of β -APP immunoreactivity was measured by an investigator blinded to the injury status of the animals.

Acute Neurodegenerative Changes

Staining for A- β . Immunostaining for A- β was performed using antibody 2332, a rabbit polyclonal antibody raised against amino acids 1 through 17 of A- β at a dilution of 1:4000. Sections were immunostained after the slides were boiled in sodium citrate (10 mM, pH 6.5) for 10 minutes for antigen retrieval, and biotinylated goat anti-rabbit IgG (concentration 1:1000) was used as a secondary antibody. Adjacent slides incubated with NHS/PBS instead of primary antibody served as negative controls.

Staining for MAP-2. Because changes in immunoreactivity for MAP-2 are considered a sensitive indicator for cytoskeletal damage following TBI,^{20,51,82} sections adjacent to those used for A- β and tau were deparaffinized and immunostained with anti-MAP-2 (concentration 1:1000) following a protocol recently established.⁸²

Staining for Tau. Because aggregation of tau has been described following repetitive head injury,^{24,25} immunostaining for tau was performed. Antibody 17026, a rabbit polyclonal phosphorylation-independent antibody capable of "recognizing" both soluble and insoluble mouse endogenous tau³⁹ was used in a concentration of 1:10,000 following an established protocol.³⁹

Statistical Analysis

Learning latencies determined by the MWM, animal body weight, and RP scores are parametric data and are presented as means \pm SEM. These data were compared using multivariate ANOVA for repeated measurements, followed by Newman-Keuls post hoc tests. Rotarod performance, histological cell counts, area of β -APP immunoreactivity, and memory and probe trial scores obtained during the MWM testing are given as means \pm SEM and were compared using a one-way ANOVA with Newman-Keuls post hoc comparisons where appropriate. Comparisons of neuroscores were performed using nonparametric tests (Kruskal-Wallis ANOVA followed by Mann-Whitney U-tests for individual comparisons). In all comparisons, a probability value less than 0.05 was considered statistically significant.

Sources of Supplies and Equipment

The C57BL/6 mice were obtained from Jackson Laboratory (Bar Harbor, ME) and were housed in units available from Thoren (Hazleton, PA). Columbus Instruments (Columbus, OH) manufactured the noninvasive computerized tail-cuff system (Columbus NIBP) used to obtain cardiovascular measurements. The Hypercenter XP automated tissue processor was purchased from Shandon Scientific Instruments (Cheshire, UK). Biotinylated horse anti-mouse IgG and the ABC Elite kit were acquired from Vector Laboratories (Burlingame, CA). The mouse anti- β -APP (No. 22C11) and anti-MAP-2 (clone AP20) were purchased from Boehringer Mannheim (Indianapolis, IN) and the biotinylated goat anti-rabbit IgG from Jackson ImmunoResearch (West Grove, PA). The MCID M4 image analysis system was obtained from Imaging Research (St. Catharines, ON, Canada).

Results

Measurements of body weight in subgroups of animals

(25/group) prior to surgery revealed no significant differences. Both sham- and brain-injured animals gained weight over the entire study period, indicating that neither a single TBI nor RHI had a negative influence on body weight (data not shown). A brief period of apnea (3–19 seconds) was observed in 15 animals after the first impact; this was transient in 14 animals but was prolonged and resulted in the death of one mouse. After the second impact, nine mice displayed transient apnea (6–21 seconds) and two animals experienced prolonged apnea and later died.

No overt seizures were observed after a single TBI or RHI, and the animals regained ambulatory function within 90 to 120 minutes after induction of anesthesia regardless of the particular injury status. Three animals sustaining skull fractures at the impact site were excluded from the study.

No evidence of subarachnoid hemorrhage was observed following a single TBI in any animal evaluated. Subsequent histological analysis confirmed the observation; however, the presence of slight pial hemorrhage and a thin film of hemorrhage over the cortical surface was documented in 5% of animals subjected to RHI, suggesting that surface venules may have been damaged in a small subpopulation of animals. It is unlikely, therefore, that subarachnoid hemorrhage contributed significantly to the histological changes observed in the present study.

Cardiovascular Function

Following a single concussion, mean BP values over the 1-hour monitoring period were as follows: SABP 114 ± 2 mm Hg; DABP 83 ± 2 mm Hg; and MABP 93 ± 5 mm Hg. Twenty-four hours later, following induction of anesthesia for the second injury, BP values were slightly decreased: SABP 98 ± 27 mm Hg; DABP 71 ± 27 mm Hg; and MABP 83 ± 27 mm Hg. The second concussive injury did not cause any additional hypotension, however, and, during the 1-hour postinjury monitoring period, the mean recorded BP values following RHI were SABP 113 ± 2 mm Hg, DABP 83 ± 2 mm Hg, and MABP 93 ± 2 mm Hg. The temporal curves of SABP, DABP, and MABP are illustrated in Fig. 1. No hypotension was detected during the entire period of monitoring following either a single TBI or RHI.

Cognitive Function

All animals (sham-injured control mice and mice receiving a single TBI or RHI) were able to swim without any sign of functional motor impairment, based on similar swim distances and mean swim speeds during the memory and probe trials (data not shown). Seven days after surgery, sham-injured animals were able to locate the hidden platform site, indicating that the mice had retention of the water maze visuospatial task. Memory scores of animals subjected to either a single TBI or RHI were not significantly different from those of sham-injured animals, indicating that a single TBI or RHI did not influence memory retention of the water maze spatial task at 7 days postinjury (Fig. 2A).

Sham-injured animals demonstrated the ability to learn a visuospatial task 56 days and 57 days after undergoing surgery (Fig. 2B), and the latencies recorded for these mice were similar to those recorded for naïve animals (data not

Repetitive head injury in the mouse

1st

Characteristics and severity of hydrocephalus

Characteristic	Group A (67 patients)
presentation	
mean age (yrs)	6.6
age range	46 days–15.1 y
metastases	24%
severity of hydrocephalus (%)	
normal ventricles	0
mild	9
moderate	31
severe	60

FIG. 1. Graphs demonstrating systemic BP changes measured in mice subjected to a single concussive brain injury (A) and to a second concussion 24 hours later (B). The mice were evaluated at 5-minute intervals over a 1-hour observation period. In both cases, a progressive increase in BP was observed over time during recovery from anesthesia. Neither a single TBI nor RHI was associated with hypotension. Data are presented as means \pm SEM.

shown). Animals subjected to either a single TBI or RHI demonstrated a similar ability to learn the new visuospatial task when evaluated 56 days and 57 days postinjury, with latencies that were not significantly different from sham-injured animals (Fig. 2B), indicating that neither a single TBI nor RHI influenced learning ability assessed during the chronic postinjury period. Performance in the probe trial conducted 58 days postinjury was similar across all groups, again indicating that neither a single TBI nor RHI significantly impaired the ability of those animals to remember the learned task (Fig. 2C).

Neurological Motor Function

Composite Neuroscore. Sham-injured animals displayed no impairment in neurological motor function after anesthesia and surgery. Although a mild, but significant deficit in neurological motor function was observed at 3 days postinjury in animals subjected to a single TBI (Fig. 3A; median score 14.5, $p < 0.05$ compared with sham-injured control group), by 7 days postinjury, neurological motor function had recovered to values of sham-injured control animals. Nevertheless, impairment in neurological motor function was significantly more pronounced in animals subjected to RHI 3 days after the first injury when compared with results obtained from animals that received a single TBI or animals that were uninjured (Fig. 3A; median score 13.75, $p < 0.001$ compared with sham-injured group,

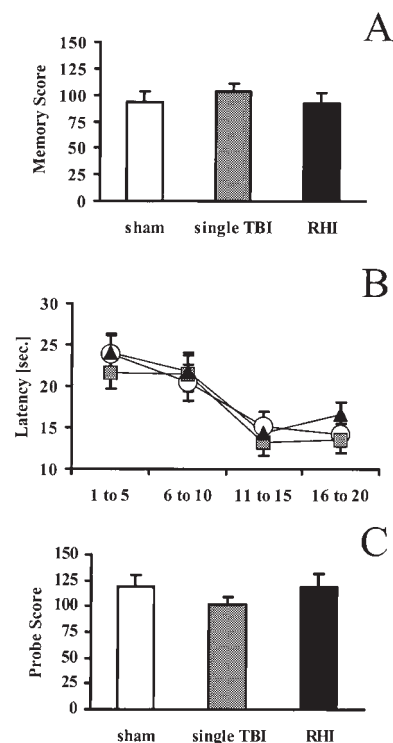


FIG. 2. Bar graphs depicting cognitive function during the MWM tests. Memory scores (A) obtained 7 days after sham injury, single TBI, or RHI are not significantly different among groups. Learning latencies at 56 days and 57 days after injury (five trials averaged, B) show a similar ability among groups of animals to learn the visuospatial task. Scores in the probe trial on Day 58 (C) revealed no significant differences among groups. Data are presented as means \pm SEM. The sham-injured group is represented by open bars or circles, single TBI by gray bars or squares, and RHI by black bars or triangles.

and $p < 0.05$ compared with mild TBI group). Moreover, this neurological motor function impairment persisted in animals subjected to RHI up to 7 days after injury (Fig. 3A; median score 14.25, $p < 0.001$ compared with sham-injured group, and $p < 0.05$ compared with mild TBI group). By 14 days postinjury, the neuroscore in both injured groups was equivalent to those of sham-injured groups (Fig. 3A) and remained unchanged for the remaining observation period (data not shown).

Rotarod Performance Test. During the acclimation period prior to injury, all animals showed similar latencies in rotarod test performance (data not shown). Animals subjected to a single TBI exhibited performance scores equivalent to sham-injured control animals (Fig. 3B). In contrast, animals subjected to RHI were impaired in their ability to stay on the rotarod, resulting in a significant deficit in their performance scores compared with control (uninjured) animals ($p < 0.05$) and animals subjected to a mild TBI ($p < 0.05$; Fig. 3B).

Rotating Pole Test. Naïve mice displayed few, if any, footfaults during the training period prior to operation (data not shown). No increase in footfaults on the RP test indicative of motor dysfunction was observed in either sham-in-

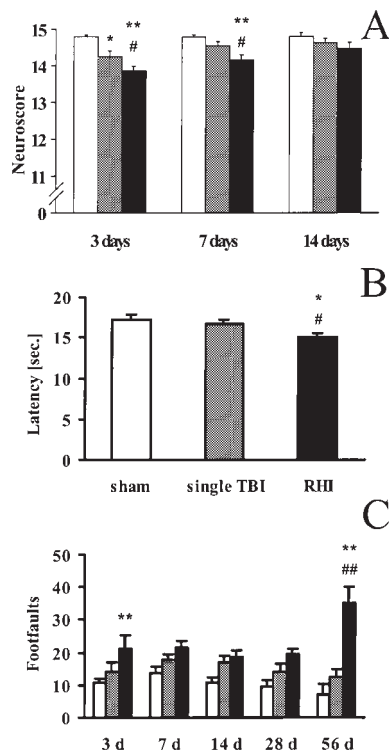


FIG. 3. Bar graphs depicting neurological motor function determined using a composite neuroscore (A), results of the rotarod test (B), and results of the RP test (C) following sham injury (open bars), single TBI (gray bars), or RHI (black bars). Mice subjected to a single TBI exhibited mild impairment in the neuroscore when compared with sham-injured mice at 3 days postinjury but recovered within 1 week. The RHI caused a more pronounced and prolonged deficit, as detected by significantly lower composite neuroscores (A). The average time remaining on the rotarod over the entire investigation period was significantly lower in animals subjected to RHI (B), whereas no significant deficit could be detected in animals that received a single impact (B). The number of footfaults made while traversing the RP was not significantly different between control animals and mice subjected to a single TBI (C). Animals subjected to RHI showed an increase in footfaults at 3 days and 56 days after the second impact (C). Data are presented as means \pm SEM. * $p < 0.05$ compared with sham-injured animals, ** $p < 0.001$ compared with sham-injured animals, # $p < 0.05$ compared with a single TBI; ## $p < 0.001$ compared with animals with a single TBI.

jured animals or animals subjected to a single TBI during the entire observation period (Fig. 3C). Nevertheless, animals subjected to RHI showed a marked increase in footfaults by 3 days after injury, which was significantly different from sham-injured animals ($p < 0.001$). After an intermediate period of recovery, animals subjected to RHI showed a profound second increase in the number of footfaults while crossing the pole. This delayed neurological impairment was found to be highly significant at 56 days compared with animals subjected to sham injury ($p < 0.001$) or a single mild TBI ($p < 0.001$; Fig. 3C).

Evaluation of Histological Cell Loss

Examination of coronal brain sections stained using the

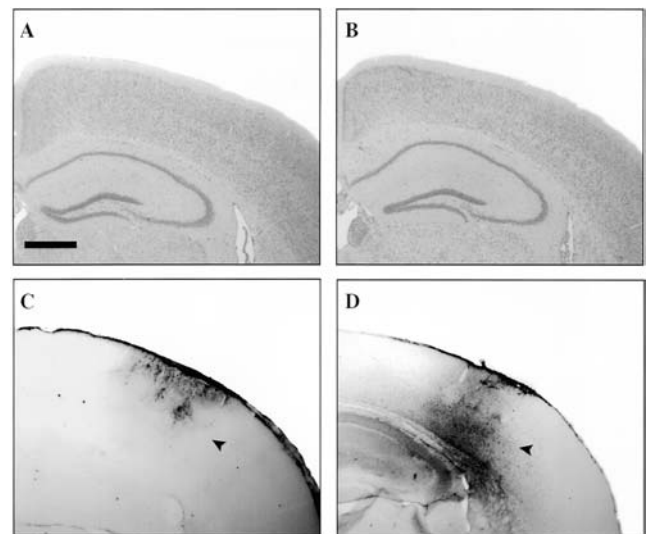


FIG. 4. Photomicrographs of histopathological specimens following single TBI or RHI. Nissl staining revealed no overt histological damage or focal lesions in the cortex or hippocampus in animals subjected to either a single TBI (A) or RHI (B) 56 days after injury. Immunostaining for mouse IgG revealed a small area of immunoreactivity restricted to the cortex (arrowhead) in three of five animals subjected to single TBI (C) 48 hours after trauma. Immunoglobulin G immunoreactivity was observed in the cortex, subcortical matter, and hippocampus of four of five animals 1 day after RHI (D, arrowhead). Scale bar = 1 mm.

Nissl method revealed no overt histological damage or focal lesions in the cortex, hippocampus, or hilum of the dentate gyrus in animals subjected to sham injury (data not shown) or animals subjected to either a single mild TBI (Fig. 4A) or RHI (Fig. 4B) 56 days after injury. Quantification of hippocampal neurons revealed no overt cell loss in the CA3 subregion of the hippocampus (Fig. 5A) or at the apex of the hilum of the dentate gyrus (Fig. 5B) in the left (injured) or right (uninjured) hemisphere in sham-injured animals or animals subjected to a mild single TBI or RHI at either 7 days or 56 days postinjury.

Integrity of the BBB. Immunohistochemical testing for IgG revealed no specific staining in sham-injured control animals (data not shown). A small area of immunoreactivity for mouse IgG was observed in three of five animals subjected to a single mild TBI at 24 hours and 48 hours after trauma (Fig. 4C). In contrast, a pronounced and widespread area of IgG immunoreactivity, suggestive of a substantial breakdown of the BBB, was observed in four of five animals subjected to RHI 1 day after the second impact. This area included the cortical regions directly beneath the impact site and the underlying white matter and adjacent cortical areas (Fig. 4D).

Examination for TAI. Immunohistochemical testing for β -APP revealed no specific staining in sham-injured animals (data not shown). Animals subjected to a single TBI displayed no immunoreactivity for β -APP at 7 days postinjury, and mild β -APP immunoreactivity was observed in the external capsule or lateral thalamus at both 28 days and 56 days after trauma (Fig. 6A–C). Similarly, animals sub-

Repetitive head injury in the mouse

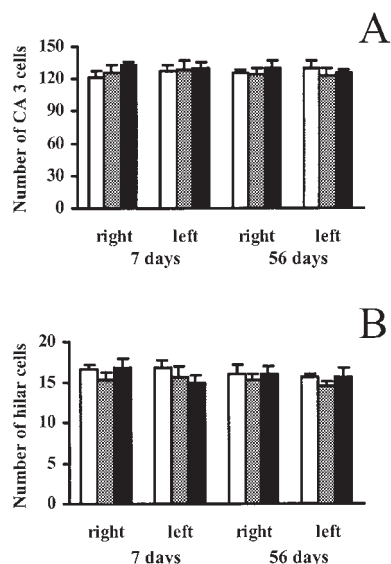


FIG. 5. Bar graphs demonstrating numbers of cells in the CA3 subfield of the hippocampus (A) and the apex of the hilum of the dentate gyrus (B) following sham injury (open bars), single TBI (gray bars), and RHI (black bars). No significant cell loss could be detected in either the left (injured) or right (contralateral) hemisphere in either group or at any time point investigated. Data are presented as means + SEM.

jected to RHI displayed no β -APP immunoreactivity at 7 days postinjury; however, pronounced β -APP immunoreactivity was detected at both 28 days and 56 days postinjury in animals subjected to RHI in the ipsilateral lateral thalamus (Fig. 6D–F). Quantification of the area of β -APP immunoreactivity in the ipsilateral (left) thalamus revealed no significant changes in animals subjected to sham injury at any time point investigated (7, 28, and 56 days; Fig. 7). Animals subjected to a single TBI exhibited small increases in the area of thalamic β -APP immunoreactivity at 28 days and 56 days after trauma, which were not significantly different from sham levels (Fig. 7). In contrast, animals subjected to RHI showed a marked increase in the thalamic area of β -APP immunoreactivity at 28 days postinjury ($p < 0.005$ compared with the sham-injured group; $p < 0.005$ compared with animals subjected to a single TBI), which had subsided by 56 days postinjury (Fig. 7).

Evaluation of MAP-2 Immunoreactivity. No regional loss of MAP-2 immunoreactivity in the cortex was detected in animals subjected to sham (control) procedures (Fig. 8A) or a single mild TBI (Fig. 8B). In contrast, more than half of the animals subjected to RHI revealed shrunken or irregular MAP-2 immunoreactive dendritic processes directly beneath the impact site 7 days after RHI (Fig. 8C). By 28 days after RHI a regional loss of MAP-2 immunoreactivity was observed (Fig. 8D), which was sustained to 56 days (data not shown).

Examination for Tau and A- β . Immunohistochemical labeling for A- β or tau did not reveal any deposits or plaques containing A- β or tau in any group investigated (sham-injury, single TBI, and RHI groups) up to 56 days after injury (data not shown).

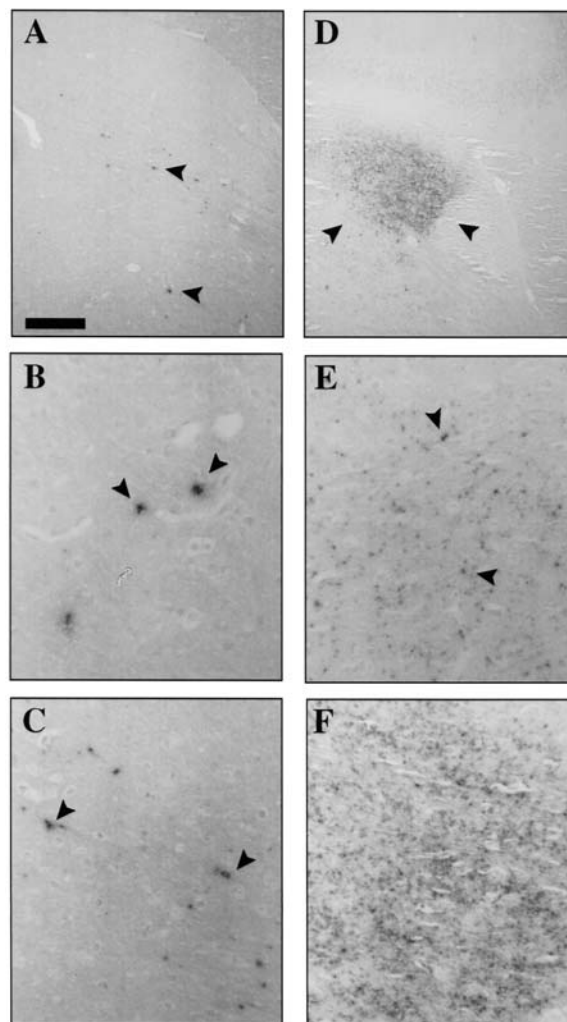


FIG. 6. Photomicrographs demonstrating the results of immunohistochemical testing for β -APP following a single TBI or RHI. A–C: Immunoreactivity (arrowheads) was observed in the left (ipsilateral) thalamus 28 days after a single TBI. D–F: Tissue from animals subjected to RHI showed pronounced immunoreactivity in the left thalamus 28 days after RHI. Scale bar = 400 μ m for A and D, 100 μ m for B, C, E, and F.

Discussion

In the present study, we observed important cumulative effects of two episodes of mild TBI leading to pronounced and prolonged functional neurological deficits and histopathological damage compared with animals who sustained only a single mild TBI. To our knowledge, this is the first experimental study in mice to demonstrate exacerbated functional impairment and neuropathological changes after RHI. In contrast with recent reports indicating that ischemic preconditioning leads to tolerance against a second ischemic insult^{2,89} or moderate TBI,⁷⁴ our data indicate that the brain may acquire an increased vulnerability to a second mild traumatic injury for at least 24 hours following an initial episode of mild TBI. In view of the high incidence of mild TBI and the subsequent risk of repetitive TBI, these novel observations have important implications

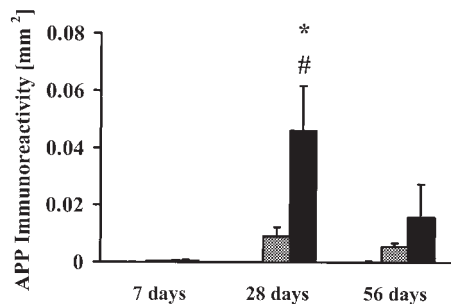


FIG. 7. Bar graph showing quantification of β -APP immunoreactivity in the left (ipsilateral) thalamus following sham injury (initial bars [barely visible]), single TBI (gray bars), or RHI (black bars). Immunoreactivity was not significantly different between control animals and mice subjected to a single TBI. Tissue from animals subjected to RHI showed an increase in immunoreactivity 28 days after RHI. Data are presented as means \pm SEM. * $p < 0.005$ compared with sham-injured animals, # $p < 0.005$ compared with animals subjected to a single TBI.

for understanding the pathobiology and consequences of repetitive brain injuries as well as for developing more effective treatments.

Mild human TBI is not typically associated with macroscopic structural central nervous system lesions,²⁸ but post-traumatic edema formation⁹⁴ or changes in cerebral blood flow and metabolic rates^{55,70} have been reported. Additionally, authors of a number of studies have suggested that TAI results from TBI over a wide range of severity in humans.^{6,64} Because a single episode of mild TBI in mice subjected to our experimental paradigm did not result in overt neuronal loss but did induce a small focal breach of the BBB as well as mild TAI, our experimental model appears to reproduce several features of mild TBI in humans. Moreover, a second episode of mild TBI within 24 hours after the initial insult caused a marked and widespread breakdown of the BBB, with intraparenchymal extravasation of serum constituents. These results are consistent with those of a previous report that experimental RHI caused a pronounced disturbance in the BBB,⁷² and studies in humans showing that repetitive TBI is associated with swelling and edema in a high percentage of cases.^{9,46} Taken together, these findings suggest that BBB breakdown might be associated with the detrimental sequelae observed after RHI.

It is important to note that the neither a single TBI nor RHI was associated with any decrease or alteration in systemic BP, indicating that it is unlikely that the effects of the second impact are due to secondary hypotension. Previously it was shown that hypotension following concussive brain injury exacerbates minor head injury.⁴¹ In our studies, the induction of anesthesia produced a slight reduction in BP, with a progressive increase over time during recovery from the anesthesia to values consistent with those observed in naïve animals (SABP 125 ± 6 mm Hg, DABP 82 ± 6 mm Hg, and MABP 97 ± 5 mm Hg) and in agreement with BP measurements previously described when this method was used.⁴⁸ These data indicate that the detrimental effects observed following a second impact are due to the secondary traumatic event rather than to superimposed hypotension.

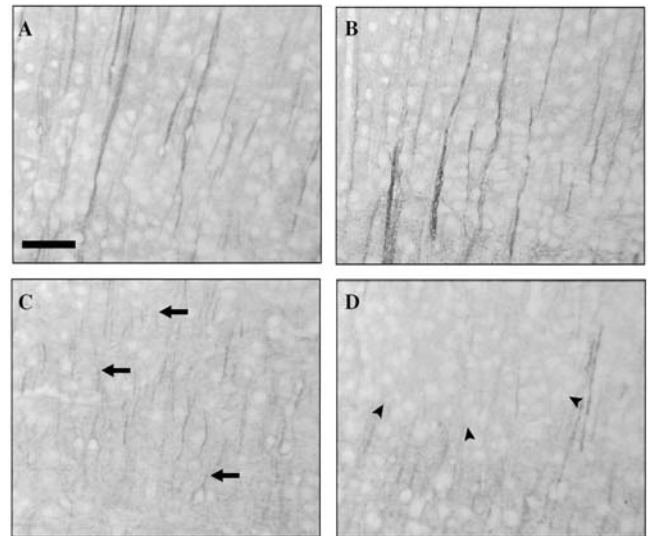


FIG. 8. Photomicrographs showing results of immunohistochemical testing for MAP-2 in the left (ipsilateral) cortex. Tissue from sham-injured (control) animals (A) and animals subjected to mild TBI (B) showed long immunoreactive dendrites through the cortex. An RHI resulted in irregular MAP-2 staining in dendritic processes (arrows) 7 days following trauma (C) that developed into an area of MAP-2 loss (arrowheads) by 28 days (D). Scale bar = 100 μ m.

Several investigators have reported that impairments in learning and memory are common sequelae of mild-to-moderate brain injury in humans,^{79,90} although in other clinical neuropsychological investigations researchers could not detect differences in a comparison of patients suffering from mild TBI⁷¹ or RHI with patients in an appropriate control group.^{4,44} Cognitive deficits in experimental moderate-to-severe TBI models correlate with hippocampal damage,^{32,34,52,88} although some authors have reported cognitive deficits in the absence of overt hippocampal cell loss.^{16,53,84} In the present study, it was somewhat disappointing that we could neither detect cognitive dysfunction after a single TBI nor after RHI. It is possible that neither a single mild impact nor RHI in our experimental setting leads to cognitive dysfunction. Alternatively, the MWM paradigm used in the current study, which has been predominantly used to evaluate cognitive function after moderate-to-severe experimental head trauma, may not be sensitive enough to detect subtle cognitive alterations after a single or repetitive experimental mild head injury. Indeed, cognitive deficits have not been observed in other studies of mild experimental TBI in rodents in which the MWM was used.^{17,21}

After a single mild TBI, the composite neuroscore test of neurological motor function revealed a transient and minimal impairment, whereas the rotarod and RP tests did not show deficits. This is consistent with reports of selective behavioral deficits after mild TBI in experimental³⁵ and clinical^{31,47} investigations. Remarkably, we observed that a second mild injury that occurred 24 hours later led to significantly greater impairment in each of the three tests of neurological function up to 8 weeks postinjury. Although the magnitude of neurological motor dysfunction was not

identical for all neurological tests employed, this was not surprising because certain tests (such as the RP test) are used to evaluate primarily vestibulomotor function, whereas others (such as the rotarod test) are used to assess coordinated movements and endurance. The histological basis for the significant increase in the number of RP footfaults at 56 days postinjury is unknown and should be further investigated. Although a confounding effect of the additional injection of pentobarbital for induction of the second brain injury cannot be completely ruled out, the long interval between this additional injection and the first behavioral testing period (48 hours after injection) in combination with the known half-life of the drug in mice (60 minutes),³ makes this possibility unlikely. Therefore, the observation of an exacerbated neurological impairment is likely due to the effects of RHI. These results are similar to those reported following sequential mild fluid-percussion brain injury in rats⁴⁵ and to clinical reports of exacerbation of behavioral deficits in cases of multiple concussions.^{15,56} These findings, taken together with reports of increased neurological impairment and histological damage after TBI and posttraumatic ischemia and hypoxia,^{14,40,41} are suggestive of an increased vulnerability of the brain after mild TBI. Although a number of mechanisms are likely to contribute to this impairment and dysfunction following mild TBI, the exact mechanism for this increased vulnerability and an understanding of this posttraumatic pathobiology remain speculative. Nevertheless, the results of experimental studies have indicated that ion dyshomeostasis^{19,83} and metabolic alterations^{36,37,97} persist for days following concussive TBI, without creating overt morphological damage, and may represent the pathological basis for an increased vulnerability.

Despite robust epidemiological data indicating an increased risk for neurodegenerative disease after TBI^{29,73} and reports of A- β and tau pathological conditions in the brains of patients who sustain repetitive TBI such as boxing injuries,^{24,80} there are no published studies showing that multiple episodes of TBI induce specific neurodegenerative conditions in an experimental model. Although the rapid and pronounced accumulation of β -APP induced by repetitive mild head injury, in our paradigm, prompts us to hypothesize that this may reflect an early stage of a neurodegenerative process, because β -APP might give rise to subsequent accumulations of A- β ,^{5,26,27,63} we did not detect A- β deposits or tau pathological conditions by 56 days after either a single mild TBI or RHI in the mice studied here. In other experimental TBI studies of rodents, however, researchers have also failed to observe acute or chronic A- β accumulation.^{75,76,87} Although the lack of observable brain deposits of A- β after experimental TBI contrasts with findings of a recent study of diffuse brain injury in pigs,⁸⁶ this might be due to differences in the experimental paradigms of the two studies, the severity of the TBI, or the species studied. The observation that β -APP is significantly increased following RHI at 28 days but not 56 days may be due to a slowing of axonal transport at 28 days postinjury, to increased clearance of β -APP by Day 56, or to increased cell death of neurons over time following brain injury. Further investigation is warranted to elucidate the mechanisms underlying the increased risk for neurodegenerative disease in patients who sustain TBIs many years before the onset of a neurodegenerative disorder.

Recent reports have revealed the potential risks associated with RHI as a result of participation in contact/collision sports. We believed that the inherent limitations of existing clinical investigations warranted a comprehensive experimental evaluation of the cellular and behavioral sequelae of RHI. Our model does appear to reproduce certain specific features of mild, repetitive concussive brain injury, including disorientation and alterations in vestibulomotor function. We were disappointed not to discern the transient cognitive deficits that have been reported clinically.^{7,50} Researchers from other laboratories have reported the occurrence of transient cognitive deficits following mild concussive brain injury in mice⁹¹ and rats⁸⁴ in the absence of histological changes in the hippocampus. It is possible that our MWM test paradigm was not sensitive enough to assess very transient or subtle cognitive behavioral changes induced in this model. Taken together, we have shown that RHI in mice leads to long-lasting alterations in neurological motor function and neuropathological changes that were not observed after a single mild TBI. It is important to note that the effects of the second impact are not merely additive but may be multiplicative with respect to its effects on physiological processes and neurobehavioral deficits. Because the pathological cascade induced by repetitive mild TBI has not been completely elucidated, the new model system described here will facilitate further research to investigate neurobehavioral and histopathological changes after minor, repetitive head trauma, and to develop strategies to attenuate "second impact syndrome," a devastating complication associated with a second episode of mild TBI in humans.

Acknowledgments

The authors thank Jeanne Marks for careful preparation of the manuscript, and Jessica A. Cheney for statistical assistance. Additionally, we thank James P. Kelly, M.D., for helpful suggestions on the manuscript, and David F. Meaney, Ph.D., and Susan S. Margulies, Ph.D., for expert technical advice related to the biomechanics of injury.

References

1. Bareyre FM, Saatman KE, Helfaer MA, et al: Alterations in ionized and total blood magnesium after experimental traumatic brain injury: relationship to neurobehavioral outcome and neuroprotective efficacy of magnesium chloride. **J Neurochem** **73**: 271–280, 1999
2. Barone FC, White RF, Spera PA, et al: Ischemic preconditioning and brain tolerance: temporal histological and functional outcomes, protein synthesis requirement, and interleukin-1 receptor antagonist and early gene expression. **Stroke** **29**: 1937–1951, 1998
3. Beck WT, Mandel HG, Fabro S: Physiological disposition of pentobarbital in tumor-bearing mice. **Cancer Res** **35**: 1333–1340, 1975
4. Bijur PE, Haslum M, Golding J: Cognitive outcomes of multiple mild head injuries in children. **J Dev Behav Pediatr** **17**: 143–148, 1996
5. Blasko I, Marx F, Steiner E, et al: TNF α plus IFN γ induce the production of Alzheimer β -amyloid peptides and decrease the secretion of APPs. **FASEB J** **13**:63–68, 1999
6. Blumbergs PC, Scott G, Manavis J, et al: Topography of axonal injury as defined by amyloid precursor protein and the sec-

- tor scoring method in mild and severe closed head injury. **J Neurotrauma** **12**:565–572, 1995
7. Bohnen N, Jolles J: Neurobehavioral aspects of postconcussive symptoms after mild head injury. **J Nerv Ment Dis** **180**: 683–692, 1992
 8. Cantu RC: Return to play guidelines after a head injury. **Clin Sports Med** **17**:45–60, 1998
 9. Cantu RC, Voy R: Case report: second impact syndrome: a risk in any contact sport. **Physician Sportsmed** **23**:27–34, 1995
 10. Carbonell WS, Grady MS: Regional and temporal characterization of neuronal, glial, and axonal response after traumatic brain injury in the mouse. **Acta Neuropathol** **98**:396–406, 1999
 11. Carbonell WS, Maris DO, McCall T, et al: Adaptation of the fluid percussion injury model to the mouse. **J Neurotrauma** **15**:217–229, 1998
 12. Chen Y, Constantini S, Trembovler V, et al: An experimental model of closed head injury in mice: pathophysiology, histopathology, and cognitive deficits. **J Neurotrauma** **13**:557–568, 1996
 13. Chorley JN: Sports-related head injuries. **Curr Opin Pediatr** **10**:350–355, 1998
 14. Clark RS, Kochanek PM, Dixon CE, et al: Early neuropathologic effects of mild or moderate hypoxemia after controlled cortical impact injury in rats. **J Neurotrauma** **14**:179–189, 1997
 15. Collins MW, Grindel SH, Lovell MR, et al: Relationship between concussion and neuropsychological performance in college football players. **JAMA** **282**:964–970, 1999
 16. Dixon CE, Clifton GL, Lighthall JW, et al: A controlled cortical impact model of traumatic brain injury in the rat. **J Neurosci Methods** **39**:253–262, 1991
 17. Dixon CE, Hamm RJ, Taft WC, et al: Increased anticholinergic sensitivity following closed skull impact and controlled cortical impact traumatic brain injury in the rat. **J Neurotrauma** **11**: 275–287, 1994
 18. Duhaime AC, Christian CW, Rorke LB, et al: Nonaccidental head injury in infants—the “shaken-baby syndrome.” **N Engl J Med** **338**:1822–1829, 1998
 19. Fineman I, Hovda DA, Smith M, et al: Concussive brain injury is associated with a prolonged accumulation of calcium: a ⁴⁵Ca autoradiographic study. **Brain Res** **624**:94–102, 1993
 20. Folkerts MM, Berman RF, Muizelaar JP, et al: Disruption of MAP-2 immunostaining in rat hippocampus after traumatic brain injury. **J Neurotrauma** **15**:349–363, 1998
 21. Fox GB, Fan L, Levasseur RA, et al: Sustained sensory/motor and cognitive deficits with neuronal apoptosis following controlled cortical impact brain injury in the mouse. **J Neurotrauma** **15**:599–614, 1998
 22. Fox GB, Levasseur RA, Faden AI: Behavioral responses of C57BL/6, FVB/N, and 129/SvEMS mouse strains to traumatic brain injury: implications for gene targeting approaches to neurotrauma. **J Neurotrauma** **16**:377–389, 1999
 23. Franklin KBJ, Paxinos G: **The Mouse Brain in Stereotaxic Coordinates**. San Diego, CA: Academic Press, 1997
 24. Geddes JF, Vowles GH, Nicoll JA, et al: Neuronal cytoskeletal changes are an early consequence of repetitive head injury. **Acta Neuropathol** **98**:171–178, 1999
 25. Geddes JF, Vowles GH, Robinson SF, et al: Neurofibrillary tangles, but not Alzheimer-type pathology, in a young boxer. **Neuropathol Appl Neurobiol** **22**:12–16, 1996
 26. Gentleman SM, Graham DI, Roberts GW: Molecular pathology of head trauma: altered β APP metabolism and the aetiology of Alzheimer’s disease. **Prog Brain Res** **96**:237–246, 1993
 27. Gervais FG, Xu D, Robertson GS, et al: Involvement of caspases in proteolytic cleavage of Alzheimer’s amyloid-beta precursor protein and amyloidogenic A beta peptide formation. **Cell** **97**:395–406, 1999
 28. Gordon WA, Brown M, Sliwinski M, et al: The enigma of “hidden” traumatic brain injury. **J Head Trauma Rehabil** **13**: 39–56, 1998
 29. Graves AB, White E, Koepsell TD, et al: The association between head trauma and Alzheimer’s disease. **Am J Epidemiol** **131**:491–501, 1990
 30. Green GA, Jordan SE: Are brain injuries a significant problem in soccer? **Clin Sports Med** **17**:795–809, 1998
 31. Guskiewicz KM, Riemann BL, Perrin DH, et al: Alternative approaches to the assessment of mild head injury in athletes. **Med Sci Sports Exerc** **29** (Suppl 7):S213–S221, 1997
 32. Hamm RJ, Dixon CE, Gbadebo DM, et al: Cognitive deficits following traumatic brain injury produced by controlled cortical impact. **J Neurotrauma** **9**:11–20, 1992
 33. Hamm RJ, Pike BR, O’Dell DM, et al: The rotarod test: an evaluation of its effectiveness in assessing motor deficits following traumatic brain injury. **J Neurotrauma** **11**:187–196, 1994
 34. Hicks RR, Smith DH, Lowenstein DH, et al: Mild experimental brain injury in the rat induces cognitive deficits associated with regional neuronal loss in the hippocampus. **J Neurotrauma** **10**: 405–414, 1993
 35. Hogg S, Moser PC, Sanger DJ: Mild traumatic lesion of the right parietal cortex of the rat: selective behavioral deficits in the absence of neurological impairment. **Behav Brain Res** **93**: 143–155, 1998
 36. Hovda DA, Becker DP, Katayama Y: Secondary injury and acidosis. **J Neurotrauma** **9** (Suppl 1):S47–S60, 1992
 37. Hovda DA, Yoshino A, Kawamata T, et al: Diffuse prolonged depression of cerebral oxidative metabolism following concussive brain injury in the rat: a cytochrome oxidase histochemistry study. **Brain Res** **567**:1–10, 1991
 38. Hsiang JN, Yeung T, Yu AL, et al: High-risk mild head injury. **J Neurosurg** **87**:234–238, 1997
 39. Ishihara T, Hong M, Zhang B, et al: Age-dependent emergence and progression of a tauopathy in transgenic mice overexpressing the shortest human tau isoform. **Neuron** **24**:751–762, 1999
 40. Jenkins LW, Lu Y, Johnston WE, et al: Combined therapy affects outcomes differentially after mild traumatic brain injury and secondary forebrain ischemia in rats. **Brain Res** **817**: 132–144, 1999
 41. Jenkins LW, Moszynski K, Lyeth BG, et al: Increased vulnerability of the mildly traumatized rat brain to cerebral ischemia: the use of controlled secondary ischemia as a research tool to identify common or different mechanisms contributing to mechanical and ischemic brain injury. **Brain Res** **477**:211–224, 1989
 42. Johansson BB, Ohlsson AL: Environment, social interaction, and physical activity as determinants of functional outcome after cerebral infarction in the rat. **Exp Neurol** **139**:322–327, 1996
 43. Jordan BD, Relkin NR, Ravdin LD, et al: Apolipoprotein E ϵ 4 associated with chronic traumatic brain injury in boxing. **JAMA** **278**:136–140, 1997
 44. Jordan SE, Green GA, Galanty HL, et al: Acute and chronic brain injury in United States National Team soccer players. **Am J Sports Med** **24**:205–210, 1996
 45. Kanayama G, Takeda M, Niigawa H, et al: The effects of repetitive mild brain injury on cytoskeletal protein and behavior. **Methods Find Exp Clin Pharmacol** **18**:105–115, 1996
 46. Kelly JP, Nichols JS, Filley CM, et al: Concussion in sports. Guidelines for the prevention of catastrophic outcome. **JAMA** **266**:2867–2869, 1991
 47. Koelfen W, Freund M, Dinter D, et al: Long-term follow up of children with head injuries-classified as “good recovery” using the Glasgow Outcome Scale: neurological, neuropsychological and magnetic resonance imaging results. **Eur J Pediatr** **156**:230–235, 1997
 48. Kregel JH, Hodgins JB, Hagaman JR, et al: A noninvasive computerized tail-cuff system for measuring blood pressure in mice. **Hypertension** **25**:1111–1115, 1995
 49. Lancon JA, Haines DE, Parent AD: Anatomy of the shaken baby syndrome. **Anat Rec** **253**:13–18, 1998

Repetitive head injury in the mouse

50. Levin HS, Mattis S, Ruff RM, et al: Neurobehavioral outcome following minor head injury: a three-center study. **J Neurosurg** **66**:234–243, 1987
51. Lewen A, Li GL, Olsson Y, et al: Changes in microtubule-associated protein 2 and amyloid precursor protein immunoreactivity following traumatic brain injury in rat: influence of MK-801 treatment. **Brain Res** **719**:161–171, 1996
52. Lowenstein DH, Thomas MJ, Smith DH, et al: Selective vulnerability of dentate hilar neurons following traumatic brain injury: a potential mechanistic link between head trauma and disorders of the hippocampus. **J Neurosci** **12**:4846–4853, 1992
53. Lyeth BG, Jenkins LW, Hamm RJ, et al: Prolonged memory impairment in the absence of hippocampal cell death following traumatic brain injury in the rat. **Brain Res** **526**:249–258, 1990
54. Marmarou A, Foda MA, van den Brink W, et al: A new model of diffuse brain injury in rats. Part I: Pathophysiology and biomechanics. **J Neurosurg** **80**:291–300, 1994
55. Masdeu JC, Van Heertum RL, Kleiman A, et al: Early single-photon emission computed tomography in mild head trauma. A controlled study. **J Neuroimaging** **4**:177–181, 1994
56. Matser EJ, Kessels AG, Lezak MD, et al: Neuropsychological impairment in amateur soccer players. **JAMA** **282**:971–973, 1999
57. Matser JT, Kessels AG, Jordan BD, et al: Chronic traumatic brain injury in professional soccer players. **Neurology** **51**:791–796, 1998
58. Mattiasson GJ, Philips MF, Tomasevic G, et al: The rotating pole test: evaluation of its effectiveness in assessing functional motor deficits following experimental head injury in the rat. **J Neurosci Methods** **95**:75–82, 2000
59. Maxwell WL, Povlishock JT, Graham DL: A mechanistic analysis of nondisruptive axonal injury: a review. **J Neurotrauma** **14**:419–440, 1997
60. McIntosh TK, Noble L, Andrews B, et al: Traumatic brain injury in the rat: characterization of a midline fluid-percussion model. **Cent Nerv Syst Trauma** **4**:119–134, 1987
61. McIntosh TK, Vink R, Noble L, et al: Traumatic brain injury in the rat: characterization of a lateral fluid-percussion model. **Neuroscience** **28**:233–244, 1989
62. Melvin JW, Evans FG: A strain energy approach to the mechanics of skull fracture: 710871, in Backaitis SH (ed): **Bio-mechanics of Impact Injury and Injury Tolerances of the Head-Neck Complex: PT-43**. Warrendale, PA: SAE, 1993, pp 661–680
63. Mills J, Reiner PB: Regulation of amyloid precursor protein cleavage. **J Neurochem** **72**:443–460, 1999
64. Mittl RL, Grossman RI, Hiehle JF, et al: Prevalence of MR evidence of diffuse axonal injury in patients with mild head injury and normal head CT findings. **AJNR** **15**:1583–1589, 1994
65. Morris RG, Garrud P, Rawlins JN, et al: Place navigation impaired in rats with hippocampal lesions. **Nature** **297**:681–683, 1982
66. Murai H, Pierce JE, Raghupathi R, et al: Twofold overexpression of human β -amyloid precursor proteins in transgenic mice does not affect the neuromotor, cognitive, or neurodegenerative sequelae following experimental brain injury. **J Comp Neurol** **392**:428–438, 1998
67. Nakamura M, Raghupathi R, Merry DE, et al: Overexpression of Bcl-2 is neuroprotective after experimental brain injury in transgenic mice. **J Comp Neurol** **412**:681–692, 1999
68. Nakamura M, Saatman KE, Galvin JE, et al: Increased vulnerability of NFH-LacZ transgenic mouse to traumatic brain injury-induced behavioral deficits and cortical damage. **J Cereb Blood Flow Metab** **19**:762–770, 1999
69. National Research Council: **Guide for the Care and Use of Laboratory Animals**. Washington, DC: National Academy Press, 1996
70. Nedd K, Sfakianakis G, Ganz W, et al: 99mTc-HMPAO SPECT of the brain in mild to moderate traumatic brain injury patients: compared with CT—a prospective study. **Brain Inj** **7**:469–479, 1993
71. Newcombe F, Rabbitt P, Briggs M: Minor head injury: pathophysiological or iatrogenic sequelae? **J Neurol Neurosurg Psychiatry** **57**:709–716, 1994
72. Olsson Y, Rinder L, Lindgren S, et al: Studies on vascular permeability changes in experimental brain concussion. 3. A comparison between the effects of single and repeated sudden mechanical loading of the brain. **Acta Neuropathol** **19**:225–233, 1971
73. O'Meara ES, Kukull WA, Sheppard L, et al: Head injury and risk of Alzheimer's disease by apolipoprotein E genotype. **Am J Epidemiol** **146**:373–384, 1997
74. Perez-Pinzon MA, Alonso O, Kraydieh S, et al: Induction of tolerance against traumatic brain injury by ischemic preconditioning. **Neuroreport** **10**:2951–2954, 1999
75. Pierce JE, Smith DH, Trojanowski JQ, et al: Enduring cognitive, neurobehavioral and histopathological changes persist for up to one year following severe experimental brain injury in rats. **Neuroscience** **87**:359–369, 1998
76. Pierce JE, Trojanowski JQ, Graham DI, et al: Immunohistochemical characterization of alterations in the distribution of amyloid precursor proteins and β -amyloid peptide after experimental brain injury in the rat. **J Neurosci** **16**:1083–1090, 1996
77. Piper IR, Thomson D, Miller JD: Monitoring weight drop velocity and foam stiffness as an aid to quality control of a rodent model of impact acceleration neurotrauma. **J Neurosci Methods** **69**:171–174, 1996
78. Raghupathi R, Fernandez SC, Murai H, et al: BCL-2 overexpression attenuates cortical cell loss after traumatic brain injury in transgenic mice. **J Cereb Blood Flow Metab** **18**:1259–1269, 1998
79. Rimel RW, Giordani B, Barth JT, et al: Moderate head injury: completing the clinical spectrum of brain trauma. **Neurosurgery** **11**:344–351, 1982
80. Roberts GW, Allsop D, Bruton C: The occult aftermath of boxing. **J Neurol Neurosurg Psychiatry** **53**:373–378, 1990
81. Roberts GW, Whitwell HL, Acland PR, et al: Dementia in a punch drunk wife. **Lancet** **335**:918–919, 1990
82. Saatman KE, Graham DI, McIntosh TK: The neuronal cytoskeleton is at risk after mild and moderate brain injury. **J Neurotrauma** **15**:1047–1058, 1998
83. Samii A, Badie H, Fu K, et al: Effects of an N-type calcium channel antagonist (SNX 111; Ziconotide) on calcium-45 accumulation following fluid-percussion injury. **J Neurotrauma** **16**:879–892, 1999
84. Scheff SW, Baldwin SA, Brown RW, et al: Morris water maze deficits in rats following traumatic brain injury: lateral controlled cortical impact. **J Neurotrauma** **14**:615–627, 1997
85. Scherbel U, Raghupathi R, Nakamura M, et al: Differential acute and chronic responses of tumor necrosis factor-deficient mice to experimental brain injury. **Proc Natl Acad Sci USA** **96**:8721–8726, 1999
86. Smith DH, Chen XH, Nonaka M, et al: Accumulation of amyloid β and tau and the formation of neurofilament inclusions following diffuse brain injury in the pig. **J Neuropathol Exp Neurol** **58**:982–992, 1999
87. Smith DH, Nakamura M, McIntosh TK, et al: Brain trauma induces massive hippocampal neuron death linked to a surge in β -amyloid levels in mice overexpressing mutant amyloid precursor protein. **Am J Pathol** **153**:1005–1010, 1998
88. Smith DH, Soares HD, Pierce JS, et al: A model of parasagittal controlled cortical impact in the mouse: cognitive and histopathologic effects. **J Neurotrauma** **12**:169–178, 1995
89. Stagliano NE, Perez-Pinzon MA, Moskowitz MA, et al: Focal ischemic preconditioning induces rapid tolerance to middle cerebral artery occlusion in mice. **J Cereb Blood Flow Metab** **19**:757–761, 1999
90. Strugar J, Sass KJ, Buchanan CP, et al: Long-term consequenc-

- es of minimal brain injury: loss of consciousness does not predict memory impairment. **J Trauma** **34**:555–559, 1993
91. Tang YP, Noda Y, Hasegawa T, et al: A concussive-like brain injury model in mice (I): impairment in learning and memory. **J Neurotrauma** **14**:851–862, 1997
 92. Tang YP, Noda Y, Hasegawa T, et al: A concussive-like brain injury model in mice (II): selective neuronal loss in the cortex and hippocampus. **J Neurotrauma** **14**:863–873, 1997
 93. Tanno H, Nockels RP, Pitts LH, et al: Breakdown of the blood-brain barrier after fluid percussive brain injury in the rat. Part 1: Distribution and time course of protein extravasation. **J Neurotrauma** **9**:21–32, 1992
 94. Tokutomi T, Hirohata M, Miyagi T, et al: Posttraumatic edema in the corpus callosum shown by MRI. **Acta Neurochir Suppl** **70**:80–83, 1997
 95. Tysvaer AT, Storli OV, Bachen NI: Soccer injuries to the brain. A neurologic and electroencephalographic study of former players. **Acta Neurol Scand** **80**:151–156, 1989
 96. Waxweiler RJ, Thurman D, Sniezek J, et al: Monitoring the impact of traumatic brain injury: a review and update. **J Neurotrauma** **12**:509–516, 1995
 97. Yoshino A, Hovda DA, Kawamata T, et al: Dynamic changes in local cerebral glucose utilization following cerebral conclusion in rats: evidence of a hyper- and subsequent hypometabolic state. **Brain Res** **561**:106–119, 1991
 98. Zhang C, Raghupathi R, Saatman KE, et al: Riluzole attenuates cortical lesion size, but not hippocampal neuronal loss, following traumatic brain injury in the rat. **J Neurosci Res** **52**:342–349, 1998

Manuscript received October 30, 2000.

Accepted in final form July 17, 2001.

This work was supported by a grant from the National Football League Charities and by Grant Nos. NINDS P50-NS08803, NINDS R01-NS40978, NIGMS R01-GM34690, NIA P01-AG11542, and P30-AG10124 from the National Institutes of Health, as well as a Veteran's Administration merit review grant.

Address reprint requests to: Tracy K. McIntosh, M.D., Department of Neurosurgery, University of Pennsylvania School of Medicine, 105 Hayden Hall, 3320 Smith Walk, Philadelphia, Pennsylvania 19104–6316. email: mcintosh@seas.upenn.edu.