



THE ANNALS OF THORACIC SURGERY



A new approach for proximal anastomosis in type "A" acute aortic dissection: prosthesis eversion

Andrea Rignano, Guido C. Keller, Michele Carmo, Giovanni B. Anguissola and
Piergiorgio G. Settembrini
Ann Thorac Surg 2003;76:949-951

The online version of this article, along with updated information and services, is
located on the World Wide Web at:

<http://ats.ctsnetjournals.org/cgi/content/full/76/3/949>

The Annals of Thoracic Surgery is the official journal of The Society of Thoracic Surgeons and the Southern Thoracic Surgical Association. Copyright © 2003 by The Society of Thoracic Surgeons. Print ISSN: 0003-4975; eISSN: 1552-6259.

A New Approach for Proximal Anastomosis in Type "A" Acute Aortic Dissection: Prosthesis Eversion

Andrea Rignano, MD, Guido C. Keller, MD, Michele Carmo, MD, Giovanni B. Anguissola, MD, and Piergiorgio G. Settembrini, MD

Department of Vascular Surgery, Ospedale S. Carlo Borromeo, University of Milan, Milan, and Department of Intensive Care Therapy, Ospedale Maggiore di Milano-IRCCS, University of Milan, Milan, Italy

One of the crucial aspects of surgical repair of type A aortic dissection is to achieve hemostasis of the anastomosis. Furthermore, the possibility of improving the suture with additional stitches is often technically demanding. We, therefore, describe a new surgical technique for the proximal anastomosis, positioning the prosthesis within the left ventricle. We present our series

of 6 patients treated with this new technique. The immediate results confirmed the efficacy, speed, and simplicity of the technique. During long-term follow-up no patient showed significant residual aortic valve incompetence.

(Ann Thorac Surg 2003;76:949–51)

© 2003 by The Society of Thoracic Surgeons

Type A aortic dissection is one of the most dramatic and acute cardiovascular emergencies. Since 1955, when DeBakey and associates [1] first attempted to resolve this problem surgically, numerous techniques have been proposed given that this pathology involves not only the ascending aorta but often the aortic valve and coronary arteries as well.

Clearly, to operate correctly on the ascending aorta, thorough knowledge of the different reconstructive techniques used in both conservative repair and prosthetic substitution is essential. Problems associated with this surgery are mainly caused by the laxity of aortic tissues involved by dissection and by the difficulties in obtaining sufficient mechanical strength and hemostasis in the reconstruction. Furthermore, the dissection causes prolapse of the tunica media-intima that in the aortic bulb causes prolapse of the aortic valve cusps and valvular regurgitation, sometimes with subsequent inadequate perfusion of the coronary arteries. Another important factor to consider during surgery is time: since the operation is carried out with the use of extracorporeal circulation, the procedure must be performed in a short time.

In this first experience we enrolled patients with type A acute aortic dissection who did not require reconstruction of the sinus of Valsalva, because they did not present any indication for a more extensive and complex surgery [2, 3] or valve substitution [4, 5].

We used as background the surgical techniques described by Sakamoto and colleagues ("Calla flower tech-

nique") [6] and Borst and associates ("elephant trunk technique") [7], and devised a new surgical procedure for proximal reconstruction of the ascending aorta. We report our experience in a series of 6 patients.

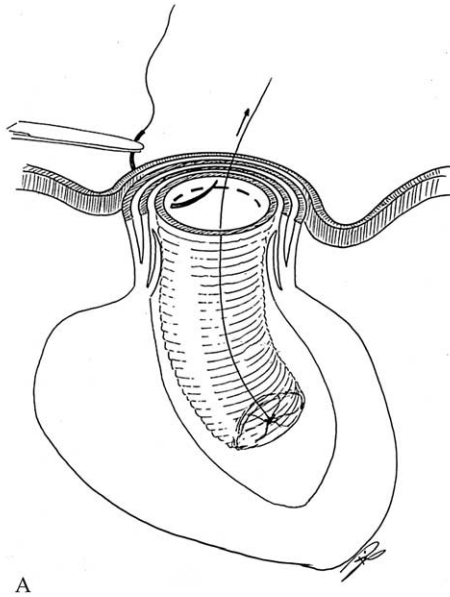
Technique

From January 1998 to December 2000 we selected 6 patients with acute dissection of the ascending aorta (Type "A" according to Stanford) with similar characteristics requiring reconstruction the ascending aorta alone. All patients had a history of hypertension, interscapular and precordial chest pain, and chest roentgenogram findings indicative of mediastinal enlargement. All the patients underwent echocardiographic investigation using a transesophageal probe that showed dissection of ascending aorta, with the primary laceration at least 2 cm above the plane of the valve, and moderate-to-severe valvular incompetence as a consequence of prolapsing of one of the aortic valve cusps. No other valvular disease was present. Surgery immediately followed the diagnostic echocardiographic investigation.


Patients were placed in a supine position, sternotomic and left or right inguinal access created, and extracorporeal circulation established through the common femoral artery-right atrium (monocannula). The real efficacy of supraaortic trunk perfusion was checked and controlled hypothermia was induced. Left ventricular aspiration was performed through the right superior pulmonary vein. The ascending aorta was carefully and widely isolated from the origin to the emergence of the supraaortic trunks and the distal aorta clamped after the brachiocephalic trunk. Aortotomy was performed and crystalloid cardioplegic solution selectively infused in the

Accepted for publication Feb 14, 2003.

Address reprint requests to Dr Carmo, Department of Vascular Surgery, Ospedale S. Carlo Borromeo, via Pio II, 3, 20153 Milan, Italy; e-mail: michele.carmo@unimi.it.



A



B

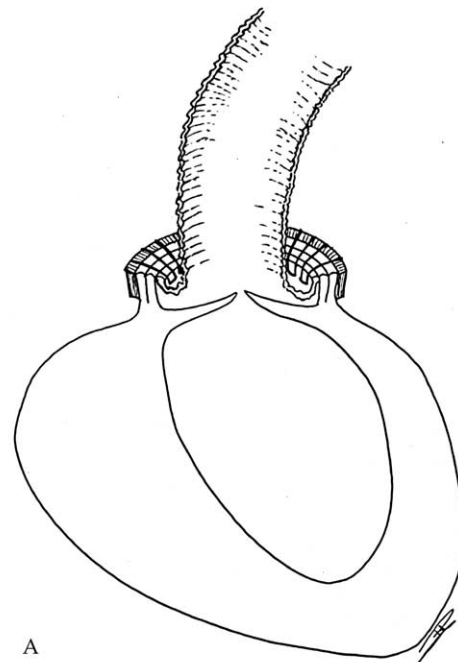
Fig 1. (A) After the prosthesis is completely inverted, it is inserted into the ventricle through the aortic valve. The free margin of the prosthesis matches the border of the previously prepared aortic stump. (B) The anastomosis is performed with a double suture: first a circular suture and then whipstitches with the same polypropylene 3-0 thread.

coronary arteries. Ice was introduced into the mediastinum after positioning of a felt patch to protect the left phrenic nerve.


The aortic wall was excised from 0.5 cm above the valve cusps. The prosthesis was chosen according to the diameter of the tunica intima of the aortic wall and, as in the "elephant trunk" technique, its distal part fixed with a thread and then completely introverted. Paying attention on the valve flaps, the prosthesis is then inserted into the residual stump of the aorta and the ventricle through the aortic valve in such a way that the free margin of the prosthesis matches the border of the previously prepared aortic stump. The aortic wall is then supported by the prosthesis, which, being introverted, is more rigid and allows perfect exposure of the aortic wall layers to be

sutured and excellent cross-sectional vision of the intima, which can therefore be positioned correctly to restore perfect valve competence. On the external border of the aorta the wall is supported, as in the traditional technique, by a Teflon (DuPont, Parkersburg, WV) ribbon. A double suture was used: first a circular suture and then whipstitches with the same polypropylene 3-0 thread (Fig 1). This was followed by eversion of the prosthesis with traction on the thread previously fixed on the distal end of the prosthesis (Fig 2).

In all 6 cases the distal anastomosis was achieved using the traditional technique with double reinforcement felt patches; in 4 patients the anastomosis was carried out at the level of the brachiocephalic trunk during moderate



A



B

Fig 2. (A) The eversion of the prosthesis is obtained by tracting on the thread previously fixed. (B) The addition of hemostatic stitches after completion of the anastomosis is easy as the anastomosis itself is completely external.

hypothermia, while in the other 2 the right hemi-arch was substituted during profound hypothermia with circulatory arrest.

All patients survived surgery. They were monitored by echocardiography and showed good valve function with minimal residual regurgitation.

In 1 patient, who also required reconstruction of the aortic arch, extensive cerebral damage developed and the patient died from massive neurologic damage 60 days later. Pulmonary consolidation secondary to staphylococcal infections was described in 2 patients with subsequent delayed extubation. Two patients developed pericardial/pleural effusion.

The 5 surviving patients underwent echocardiographic control examinations 3, 6, and 12 months after surgery and then annually. Results were excellent: good valve function with minimal stable, residual regurgitation that was unchanged since the operation.

Computed tomography scan 1 year after the operation did not show significant changes in the sinus of Valsalva or the substituted segment of the aorta in any of the patients.

Comment

The technique of "prosthetic eversion" was shown to be effective and not harmful. Data analysis did not demonstrate any lesion within the aorta, the valve cusps, or left ventricle secondary to maneuvers for prosthesis placement. This technique allows perfect vision of the structures to be repaired, because the prosthesis is inserted into the aorta and the left ventricle, allowing a direct view of all the structures. This technique can be performed quickly: the mean time necessary for the proximal recon-

struction was 12 minutes, with a minimum of 9 and a maximum of 19 minutes. The addition of hemostatic stitches after completion of the anastomosis is easy as the anastomosis itself is completely external. This opportunity makes the technique simple and safe.

Follow-up results were excellent, encouraging us to continue using this technique (perhaps extending it to the distal anastomosis) in substitutions of the ascending aorta and aortic arch where the reconstruction must be achieved quickly.

This paper is dedicated to Prof Alberto Arpesani, our friend and master of vascular surgery. The authors are grateful to Raffaella Colombo for her drawings.

References

1. DeBakey ME, Cooley DA, Creech O Jr. Surgical considerations of dissecting aneurysm of the aorta. *Ann Surg* 1955;142:586-612.
2. Pepper J, Yacoub M. Valve conserving operation for aortic regurgitation. *J Cardiac Surg* 1997;12(suppl):151-6.
3. David TE, Feindel CM. An aortic valve sparing operation for patients with aortic incompetence and aneurysm of the ascending aorta. *J Thorac Cardiovasc Surg* 1992;103:617-21.
4. Bentall H, De Bono A. A technique for complete replacement of the ascending aorta. *Thorax* 1968;23:338-9.
5. Cabrol C, Pavie A, Mesnildrey P, et al. Long-term results with total replacement of the ascending aorta, and reimplantation of the coronary arteries. *J Thorac Cardiovasc Surg* 1986;91:17-25.
6. Sakamoto T, Yoshida T, Sugano T, et al. Simplified technique for hemi-arch replacement during open distal anastomosis: the "Calla" method. *Ann Thorac Surg* 1996;61:1021-3.
7. Borst HG, Walterbush G, Schaps D. Extensive aortic replacement using "elephant trunk" prosthesis. *J Thorac Cardiovasc Surg* 1983;31:37-40.

**A new approach for proximal anastomosis in type "A" acute aortic dissection:
prosthesis eversion**

Andrea Rignano, Guido C. Keller, Michele Carmo, Giovanni B. Anguissola and
Piergiorgio G. Settembrini

Ann Thorac Surg 2003;76:949-951

**Updated Information
& Services**

including high-resolution figures, can be found at:
<http://ats.ctsnetjournals.org/cgi/content/full/76/3/949>

References

This article cites 7 articles, 4 of which you can access for free at:
<http://ats.ctsnetjournals.org/cgi/content/full/76/3/949#BIBL>

Citations

This article has been cited by 5 HighWire-hosted articles:
<http://ats.ctsnetjournals.org/cgi/content/full/76/3/949#otherarticles>

Subspecialty Collections

This article, along with others on similar topics, appears in the
following collection(s):

Great vessels

http://ats.ctsnetjournals.org/cgi/collection/great_vessels

Permissions & Licensing

Requests about reproducing this article in parts (figures, tables) or
in its entirety should be submitted to:

<http://www.us.elsevierhealth.com/Licensing/permissions.jsp> or

email: healthpermissions@elsevier.com.

Reprints

For information about ordering reprints, please email:
reprints@elsevier.com



**THE ANNALS OF
THORACIC SURGERY**

