

# Hypovolemic shock due to severe gastrointestinal bleeding in a child taking an herbal syrup

Paola Angela Moro<sup>(a)</sup>, Valerio Flacco<sup>(b)</sup>, Federica Cassetti<sup>(a)</sup>, Valentina Clementi<sup>(a)</sup>,  
Maria Laura Colombo<sup>(c)</sup>, Giulia Maria Chiesa<sup>(d)</sup>, Francesca Menniti-Ippolito<sup>(e)</sup>,  
Roberto Raschetti<sup>(e)</sup> and Carmela Santuccio<sup>(f)</sup>

<sup>(a)</sup>Centro Antiveleni, Ospedale Niguarda Ca' Granda, Milan, Italy

<sup>(b)</sup>Dipartimento Pediatrico, "Ospedale Civile", Lanciano (Chieti), Italy

<sup>(c)</sup>Dipartimento di Scienza e Tecnologia del Farmaco, Facoltà di Farmacia,  
Università di Torino, Turin, Italy

<sup>(d)</sup>Dipartimento di Scienze Farmacologiche, Università degli Studi di Milano, Milan, Italy

<sup>(e)</sup>Centro Nazionale di Epidemiologia, Istituto Superiore di Sanità, Rome, Italy

<sup>(f)</sup>Unità di Farmacovigilanza, Agenzia Italiana del Farmaco, Rome, Italy

**Summary.** We report the case of a 4-years-old boy who was admitted with hypovolemic shock due to a severe gastrointestinal bleeding. The esophagogastroduodenoscopy (EGDS) showed hiatus hernia, erosions and ulcerations of the lower esophagus, possibly due to a gastroesophageal reflux, and a small duodenal erosion. The child was previously healthy and he had never shown any symptoms related to this condition. The only product taken by the child in the previous days was a syrup containing several herbs, among which *Filipendula ulmaria* (L.) Maxim. and *Salix* spp. (known to contain salicylates), marketed as food and prescribed by his paediatrician to treat a mild cold accompanied by fever. Quali-quantitative analysis confirmed the presence of salicylates in the syrup. Naranjo algorithm showed a probable correlation between the onset of symptoms and the consumption of the herbal remedy. The child recovered after receiving intensive care. The product was withdrawn from Italian market.

**Key words:** medicine, herbal, complementary therapies, phytotherapy, salicylates, adverse effects, gastrointestinal hemorrhage.

**Riassunto** (*Shock ipovolemico dovuto ad un grave sanguinamento gastrointestinale in un bambino che aveva assunto uno sciroppo a base di erbe*). Segnaliamo il caso di un bambino di 4 anni giunto in ospedale con un quadro di shock ipovolemico a causa di un grave sanguinamento gastrointestinale. L'esofagogastroduodenoscopia (EGDS) mostrava un'ernia iatale, erosioni ed ulcerazioni dell'esofago inferiore, probabilmente a causa di un reflusso gastroesofageo, ed una piccola erosione duodenale. Il bambino, precedentemente in buona salute, non aveva mai mostrato alcun sintomo correlato a questa condizione. L'unico prodotto assunto dal paziente nei giorni precedenti era uno sciroppo a base d'erbe, tra le quali *Filipendula ulmaria* (L.) Maxim. e *Salix* spp. (specie note per contenere salicilati), commercializzato come alimento e prescritto dal suo pediatra per curare una lieve sintomatologia da raffreddamento con febbre. L'analisi quali-quantitativa confermava la presenza di salicilati nello sciroppo. L'algoritmo di Naranjo mostrava una correlazione probabile tra l'esordio dei sintomi e l'assunzione del prodotto. Il bambino, si è rapidamente ristabilito senza sequele dopo essere stato sottoposto a cure intensive. Il prodotto è stato ritirato dal mercato italiano.

**Parole chiave:** fitoterapia, salicilati, effetti avversi, emorragia gastrointestinale, terapie complementari, medicina naturale.

## INTRODUCTION

Widespread opinion that natural remedies are completely harmless lead parents to use them instead of conventional drugs to treat their children diseases [1-4].

Nevertheless, safe and confident use of herbal supplements is an issue gaining more and more attention as they can lead to mild-to-severe adverse reactions [4, 5].

Moreover, physicians and paediatricians do not usually undergo adequate training for prescribing Complementary and Alternative Medicines (CAM)

remedies, evaluating their clinical effects and assisting families in using them wisely [4, 6].

The case we report shows the potential harm of herbal supplements if incorrectly used in paediatric patients.

## CASE REPORT

A 4-years-old boy weighting 17 kg was admitted to the hospital for sudden gastrointestinal bleeding leading to hypovolemic shock. The day before the child

had evacuated dark stool and had some episodes of hematemesis during the night. At the admission he was drowsy, pale, hypotensive (BP = 60/40 mmHg) and anemic (Hb = 6.4 g/dL). Blood test showed RBC (red blood cells)  $2.4 \times 10^{12}/L$ , MCV (mean cell volume) 78.4 fL, MCH (mean cell hemoglobin) 26.4 pg/cell, MCHC (mean corpuscular hemoglobin concentration) 33.7 g/dL, Plt (platelets)  $280\,000 \times 10^9/L$ , WBC (white blood cells)  $9.3 \times 10^9/L$  with normal formula. The patient was admitted to the paediatric intensive care unit (ICU), where emergency treatment was provided and stabilization achieved.

Esophagogastroduodenoscopy (EGDS) showed hiatus hernia, erosions and ulcerations of the lower esophagus (possibly related to a gastroesophageal reflux) and a small duodenal erosion; about 150 ml of coagulated blood were removed from the stomach. Since the boy had not previously shown any symptoms of gastroesophageal reflux, the disease had never been investigated.

Two days before the child had shown fever and a mild cold likely due to a viral respiratory infection, not accompanied by any gastrointestinal manifestation.

On the first day of illness a single rectal dose of acetaminophen, 250 mg, was administered; the next day he was treated with 15 ml (5 ml for three times) of an herbal syrup and he started bleeding on the night. The syrup, containing ribwort plantain (*Plantago lanceolata* L.), liquorice (*Glycyrrhiza glabra* L.), willow (*Salix* spp.), black elder (*Sambucus nigra* L.), meadowsweet (*Filipendula ulmaria* (L.) Maxim.), and propolis, was prescribed by his paediatrician and never taken before.

No other drugs had been administered in the previous twenty days, but thirty days before he was treated for five days with 285 mg/day of niflumic acid without showing any adverse effects. The herbal product was discontinued and the patient recovered.

The case was evaluated according to the Naranjo causality algorithm scale [7].

The probability determination score was 7, which means that the reaction was probably caused by the syrup.

### SALICYLATE QUALI-QUANTITATIVE ANALYSIS

The herbal remedy was tested for salicylate (salts and esters of salicylic acid) content, at first applying the colourimetric method reported in the *European Pharmacopoeia* 5<sup>th</sup> ed. [8].

According to this method, the addition of 0.5 ml of  $FeCl_3$  to 1 ml of Freddobaby syrup produced a highly colored (violet) iron (III)-salicylate that persisted after the addition of 0.1 ml acetic acid, thus confirming the presence of salicylic acid in the product.

High performance liquid chromatography (HPLC) qualitative and quantitative analysis was subsequently performed. Sample preparation: to the diluted syrup (1:1 v/v) in MeOH, 50  $\mu$ l resorcinol so-

lution as internal standard (5 mg/ml) were added. Salicylates were monitored by reversed phase high performance liquid chromatography (RP-HPLC).

Reference standard: salicin, saligenin (salicyl alcohol), salicylic acid and methyl salicylate were obtained from Sigma Chemical Co., St. Louis, MO., USA. Ethanol reference solution was a pool: salicin (0.56 mg/ml) + saligenin (0.86 mg/ml) + salicylic acid (1.33 mg/ml), and methyl salicylate (0.5 ml/ml).

HPLC chromatographic system was a Jasco instrument, equipped with a detector: UV 975 Intelligent UV/VIS Detector; Intelligent Fluorescence Detector FP-1520; pump PU-980 Intelligent HPLC Pump; injection valve manual, Rheodyne mod. 7725 Catati, California; column LC-18 Supelco 150 mm x 4.6 mm (*i.d.*), 5  $\mu$ m particle size. Eluent A =  $K_3PO_4$  15 mM in  $H_2O$ : ACN (95:5, v/v) at pH = 3 with concentrated  $H_3PO_4$ ; eluent B =  $K_3PO_4$  15 mM in  $H_2O$ : ACN (50:50, v/v) at pH = 3 with concentrated  $H_3PO_4$ . Gradient elution: 5 min 100% A, 20 min 50% A, 5 min 0% A, 10 min isocratic elution 0% A. Flow 0.5 ml/min, UV detection  $\lambda = 303$  nm, Fluorescence detection (exc)  $\lambda = 299$  nm and (em)  $\lambda = 409$  nm. A fixed loop 20  $\mu$ l was used.

HPLC profiles of the standard solution (*Figure 1*) and of the FreddoBaby syrup (*Figure 2*) are reported.

The salicylic acid content, the most active salicylate, was determined and quantified by fluorimetry in acidic solution where efficient fluorescence of this compound is usually observed. This method can be of significant importance in the determination of the extent of hydrolysis of salicylate. Fluorescence-based quantitation is more sensitive than that obtained with the UV test and it is specific for the compound of interest (*i.e.* salicylic acid).

The quantitative analysis of salicylates, performed according to the internal standard method, revealed 0.4 mg/ml of salts and esters of salicylic acid (expressed as salicin, salicylic acid, salicyl alcohol and esters of salicylic acid, and their methylated derivatives) in the FreddoBaby syrup. The HPLC results well correlate with the colourimetric reaction by means of ferric chloride.

### DISCUSSION

The product label reported the name but no the percentage content of the ingredients; technical data sheet was achieved but titration of active extract was not available.

MEDLINE, EMBASE and MICROMEDEX searches were performed to find articles related to gastrointestinal bleeding associated to *Plantago lanceolata*, *Glycyrrhiza glabra*, *Salix* spp., *Sambucus nigra*, *Filipendula ulmaria*, propolis, salicylates, niflumic acid and acetaminophen internal use.

No reports of gastric damage related to use of *Plantago lanceolata*, *Sambucus nigra*, and propolis were found.

Some studies showed a possible anti-inflammatory and anti-ulcer action of *Glycyrrhiza glabra* and its

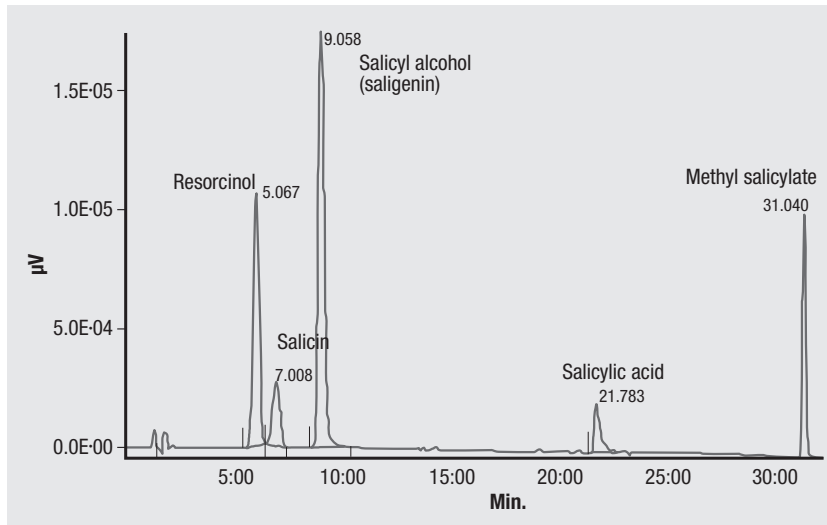


Fig. 1 | HPLC profile of the salicylate standard solution.

extracts [9, 10]; on the other hand, licorice root is thought to contain coumarins or coumarin derivatives that demonstrated antiplatelet activity *in vitro* [11]. Therefore, it may theoretically increase the risk of bleeding especially if taken with antiplatelet drug [12]. Nevertheless, it is really difficult to ascertain pharmacological interactions between licorice and salicylates or other components of the herbal remedy, while it is unlikely any interaction with acetaminophen due to the short half-life of this drug [13] and the time elapsed (20 hours) between the suppository administration and the consumption of the syrup.

Surprisingly, one case of gastrointestinal bleeding related to *Filipendula ulmaria* and *Salix* spp. in a dog that ate a dietary supplement containing both the plants [14] was described; although this was a veterinary report, the progression of the illness and the clinical picture closely resembles the event we observed.

*Filipendula ulmaria* (L.) Maxim. (Fam. Rosaceae)

and *Salix* spp. (Fam. Salicaceae) are known to contain various salicylates. In particular, Meadowsweet contains a minimum of 0.1% v/w of steam-volatile substances (dried drug), among which gaultherin (glycoside of methyl salicylate); *Salix* contains not less than 1.5% of salicylic derivatives, mainly as salicin (an alcoholic beta-glucoside) [15-18].

*In vitro*, it is possible to obtain the hydrolysis of salicin by alkaline saponification according to the *European Pharmacopoeia* 6<sup>th</sup> ed. or by means of enzymatic reaction, according to Association of Agricultural Chemists (AOAC) International [19]. The result of the hydrolysis is the loss of the glucose moiety and the discharge of the alcoholic genin saligenin (phenolic alcohol called also salicyl alcohol). *In vivo* pharmacological studies in rats indicate that salicin acts as a pro-drug which is transformed into its active metabolite, salicylic acid, via saligenin formation [20, 21]. Both gaultherin and salicin are supposed to have less gastric ulcerogenic effect compared to aspirin [22, 23].

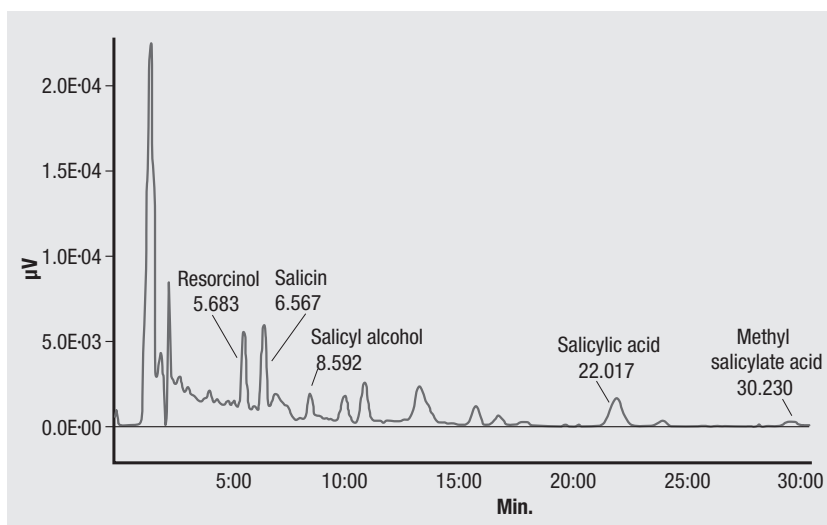


Fig. 2 | HPLC profile of the FreddoBaby syrup.

Nevertheless, the strong colourimetric response to the addition of ferric chloride revealed the presence of free salicylates in the syrup. The quali-quantitative analysis confirmed the presence of methyl salicylic and salicylic acid derived by hydrolysis of natural occurring glycoside compounds (Figure 2).

This spontaneous hydrolysis reaction shows up that pharmacological activity of multiple ingredients natural preparations may be unpredictable and should be assessed by testing the final product.

Methyl salicylic and salicylic acid are not intended for oral consumption because of their irritative action on the mucosae and for their high salicylate potency (which is almost 1.4 times the potency of acetylsalicylic acid) [24].

Salicylates are strong analgesic and antipyretic derivatives of salicylic acid often prescribed or used as self-medication to relieve fever and mild pain, especially headache and arthromyalgia; although these compounds are OTC drugs, they can be used in children only under medical prescription.

Salicylates have often been implicated in the development of gastrointestinal damages [2, 13, 25].

Their gastrointestinal toxicity can be ascribed to two distinct mechanisms:

- a) *indirect action*: salicylates act mainly by inhibiting the enzyme prostaglandin endoperoxide synthase (or cyclooxygenase or COX), which exists in two isoforms (COX1, constitutive, and COX2, induced during inflammation) and converts arachidonic acid to several prostanoids. The unspecific inhibition of both COX1 and COX2 results in attenuation of pain, fever and other symptoms of inflammation (mediated by the prostaglandins produced by COX2), and in weakening of several defensive mechanisms in the tissues that express COX1 (including the gastrointestinal tract) [13];
- b) *direct action*: most salicylates, when ingested, increase by topic contact the gastric mucosa permeability to hydrogen ions, mainly by reducing its hydrophobicity; this leads to an inflammatory response that enhances the epithelial damage [13, 26-29].

According to the literature, upper gastrointestinal complications associated with several NSAIDs in children can be expected; in particular, several cases of gastrointestinal bleeding, both in adults and children, related to the administration of salicylates are reported [2, 25, 26].

On the other hand, only mild effects but no serious events (hemorrhage, hypovolemic shock) connected to the use of niflumic acid are described [30] and there is a general agreement about the safety of therapeutic doses of acetaminophen compared to aspirin and other NSAIDs [31, 32] unless it is taken at high doses together with other analgesic/antipyretic agents [33, 34].

In the present case, the child took about 15ml of the herbal syrup, containing 0.4 mg/ml of salicylates, corresponding to a total dose of 6 mg (0.35 mg/kg), an amount far from being a toxic dose.

It is not clear whether the reaction observed resulted from the exacerbation of an existing pathology or was the first manifestation of a disease just developed, but several factors suggest that the symptoms were probably caused by the herbal remedy.

The child was previously healthy, and had already taken both acetaminophen and niflumic acid in the past without any side effects; moreover, the time elapsed between the last administration of niflumic acid and the accident makes the correlation unlikely, while there is a close temporal association between the consumption of the syrup and the onset of the symptoms. Naranjo score confirmed this hypothesis.

Besides causing gastrointestinal injuries, salicylates have been reported to cause allergic reactions (in some cases even anaphylaxis) in sensitive subjects [35, 36].

Furthermore, they are suspected to act as co-factors in the development of Reye's syndrome (acute non-inflammatory encephalopathy accompanied by selective hepatic abnormalities and metabolic decompensation) in children affected by viral infections [1, 37, 38]; for this reason, starting from 1986 several alerts were issued against the use of salicylates-containing medications in children and teenagers affected by or recovering from chicken pox or flu, and mandatory warning labels were instituted in many countries [1, 37-40].

Apart from medical and pharmacological considerations, it seems important to highlight some other aspects of this event.

The syrup involved in our case was marketed as "food", therefore, according to the European law (89/395/CEE, 2000/13/CE), it should have been free from any therapeutic activity; for this reason its label reported all the constituents but not their active principles (salicylates were not mentioned) and it did not undergo the notification procedure that is mandatory for supplements. Nevertheless, its name ("FreddoBaby" in Italian; literally translated "ColdBaby" into English) suggested that the syrup could be useful in the treatment of cold states in children and it could be bought without medical prescription.

On the other hand, the remedy was prescribed by a paediatrician, unaware of pharmacological properties of herbal ingredients and of possible presence of salicylates.

This explains why our patient was treated with this remedy despite the known risks connected with the use of salicylates in children with febrile illnesses.

The spreading use of natural remedies is strongly related to the common opinion, frequently diffused through the mass media, that they are suitable for subjects in any age group and health condition because they always are beneficial and harmless [41].

Our report shows that this misconception can lead both common people and health practitioners to use carelessly such remedies without regard to any possible adverse effects.

## CONCLUSIONS

Herbs contain several constituents that may exert a pharmacological activity, in the same way as conventional medicines do. Therefore they can not be claimed as absolutely safe and free from adverse effects. Products containing salicylates can be highly hazardous if used by children or aspirin-sensitive subjects. Natural remedies should be used under the supervision of adequately trained practitioners and administered cautiously to paediatric patients, unless reliable evidence of their safety is provided. Spontaneous reporting can contribute to improve

knowledge about potential adverse reactions to medicinal plants and increase awareness among health personnel and public about their benefit–harm assessment.

### Conflict of interest statement

There are no potential conflicts of interest or any financial or personal relationships with other people or organizations that could inappropriately bias conduct and findings of this study.

Received on 23 March 2011.

Accepted on 4 July 2011.

## References

- Kamiensky MC. Reye Syndrome. *AJN* 2003;103(7):54-7.
- Karademir S, Oğuz D, Senocak F, et al. Tolmetin and salicylate therapy in acute rheumatic fever: Comparison of clinical efficacy and side-effects. *Ped Int* 2003;45(6):676-9.
- Lim A, Cranswick N, Skull S, et al. Survey of complementary and alternative medicine use at a tertiary children's hospital. *J Paediatr Child Health* 2005;41:424-7.
- Woolf AD. Herbal remedies and children: do they work? Are they harmful? *Pediatrics* 2003;112:240-6.
- Ernst E. Serious adverse effects of unconventional therapies for children and adolescents: a systematic review of recent evidence. *Eur J Pediatr* 2003;162:72-80.
- Brown J, Cooper E, Frankton L, et al. Complementary and alternative therapies: Survey of knowledge and attitudes of health professionals at a tertiary paediatric/women's care facility. *Complement Ther Clin Pract* 2007;13(3):194-200.
- Naranjo CA, Busto U, Sellers EM, Sandor P, Ruiz I, Roberts EA, Janecek E, Domecq C, Greenblatt DJ. A method for estimating the probability of adverse drug reactions. *Clin Pharmacol Ther* 1981;30(2):239-45.
- European Directorate for the Quality of Medicines & HealthCare. *European Pharmacopoeia 5<sup>th</sup> ed.* Strasbourg: EDQM; 2004.
- Adel M. Aly, Laith Al-Alousi, Hatem A. Salem. Licorice. A possible anti-inflammatory and anti-ulcer drug. *AAPS PharmSciTech* 2005;6(1):E74-82.
- Dehpour AR. The protective effect of licorice components and their derivatives against gastric ulcer induced by aspirin in rats. *J Pharm Pharmacol* 1994;46:148-52.
- Francischetti IM, Monteiro RQ, Guimaraes JA, et al. Identification of glycyrrhizin as a thrombin inhibitor. *Biochem Biophys Res Commun* 1997;235(1):259-63.
- Norred CL, Brinker F. Potential coagulation effects of pre-operative complementary and alternative medicines. *Alt Ther* 2001;7(6):58-67.
- Burke A, Smyth EM, Fitzgerald GA. Analgesic-antipyretic and anti-inflammatory agents; pharmacotherapy of gout. In: Brunton LL, Laxo JS, Parke KL (Ed.). *Goodman & Gilman's the pharmacologic basis of therapeutics, 11<sup>th</sup> ed.* New York: McGraw-Hill; 2006.
- Rohner Mächler M, Glaus TM, Reusch CE. Life threatening intestinal bleeding in a Bearded Collie associated with a food supplement for horses. *Schweiz Arch Tierheilkd* 2004; 146(10):479-82.
- European Scientific Cooperative on Phytotherapy (ESCO). *Filipendulae ulmariae herba*. In: *ESCO Monographs. The Scientific Foundation for Herbal Medicinal Products 2nd ed.* New York: Thieme Medical Publishers; 2003. p. 157-161.
- European Scientific Cooperative on Phytotherapy (ESCO). *Salicis cortex*. ESCO Monographs. *The Scientific Foundation for Herbal Medicinal Products, 2nd ed.* New York: Thieme Medical Publishers; 2003. p. 445-51.
- European Directorate for the Quality of Medicines & HealthCare. Monograph 1868: Meadowsweet (*Filipendulae ulmariae herba*). In: *European Pharmacopoeia, 5<sup>th</sup> ed.* Stuttgart: EDQM; 2006. p. 1980-1.
- European Directorate for the Quality of Medicines & HealthCare. Monograph 1583: Willow Bark (*Salicis cortex*). In: *European Pharmacopoeia, 5<sup>th</sup> ed.* Stuttgart: EDQM; 2006. p. 2702-3.
- European Directorate for the Quality of Medicines & HealthCare. *European Pharmacopoeia 6<sup>th</sup> ed.* Strasbourg: EDQM; 2007.
- Luo, Wenhong; Ang, Catharina YW, Schmitt, Thomas C.; Betz, Joseph M. Determination of salicin and related compounds in botanical dietary supplements by liquid chromatography with fluorescence detection. *J AOAC Inter* 1998; 81(4):757-62.
- Meier B, Sticher O, Julkunen-Tiitto R. Pharmaceutical aspects of the use of willows in herbal remedies. *Planta Med* 1988;54:559-60.
- Akao T, Yoshino T, Kobashi K, Hattori M. Evaluation of salicina as an antipyretic prodrug that does not cause gastric injury. *Planta Med* 2002;68:714-8.
- Zhang B, He XL, Ding Y, Du GH. Gaultherin, a natural salicylate derivative from Gaultheria. Towards a better non-steroidal anti-inflammatory drug. *Eur J Pharmacol* 2006;530: 166-71.
- Vandenberg SA, Smolinske SC, Spoerke DG. Non-aspirin salicylates: conversion factors for estimating aspirin equivalency. *Vet Hum Toxicol* 1989;31:49-50.
- Hirschowitz BI, Lanos A. Atypical and aggressive upper gastrointestinal ulceration associated with aspirin abuse. *J Clin Gastroenterol* 2002;34(5):523-8.
- Fernández AG, Salcedo C, Palacios JM. Aspirin, salicylate and gastrointestinal injury. *Nat Med* 1995;1(7):602-3.
- Fromm D. Gastric mucosal defense mechanism: effects of salicylate and histamine. *Am J Surg* 1978;135(3):379-84.
- Rainsford KD. Anti-inflammatory drugs and the gastrointestinal mucosa. *Gastroenterol Clin Biol* 1985;9(12 Pt 2):98-101.
- Whittle BJR. Gastrointestinal effects of nonsteroidal anti-inflammatory drugs. *Fundam Clin Pharmacol* 2003;17(3):301-13.
- Autret-Leca E, Bensouda-Grimaldi L, Maurage C, et al. Upper gastrointestinal complications associated with NSAIDs in children. *Therapie* 2007;62(2):173-6.
- Ivey RJ, Silvano GR, Krause WJ. Effect of paracetamol on gastric mucosa. *BMJ* 1978;17(1):1586-8.
- Peura DA, Goldkind L. Balancing the gastrointestinal benefits and risks of nonselective NSAIDs. *Arthritis Res Ther* 2005; 7(Suppl. 4):S7-13.

33. Anon. *Press Release: FDA announces new alcohol warnings for pain relievers and fever reducers*. United States Food and Drug Administration, US Department of Health and Human Services, Rockville, MD (cited 10/22/98). Available from: [www.fda.gov](http://www.fda.gov). October 21, 1998.
34. Rahme E, Barkun A, Nedjar H, *et al*. Hospitalizations for upper and lower GI events associated with traditional NSAIDs and acetaminophen among the elderly in Quebec, Canada. *Am J Gastroenterol* 2008;103:872-82.
35. Lim YL, Thirumoorthy T. Serious cutaneous adverse reactions to traditional Chinese medicines. *Singapore Med J* 2005; 46(12):714-7.
36. Boullata JI, McDonnell PJ, Oliva CD. Anaphylactic reaction to a dietary supplement containing willow bark. *Ann Pharmacother* 2003;37(6):832-5.
37. Glasgow JF. Reye's syndrome: the case for a causal link with aspirin. *Drug Saf* 2006;29(12):1111-21.
38. Autret-Leca E, Jonville-Béra AP, Llau ME, *et al*. Incidence of Reye's syndrome in France. A hospital-based survey. *J Clin Epidemiol* 2001;54(8):857-62.
39. Dyer C. Government sued for 11 week delay in warning about aspirin. *BMJ* 2002;324(19):134.
40. Food and Drug Administration, HHS. Labeling for oral and rectal over-the-counter drug products containing aspirin and nonaspirin salicylates; Reye's Syndrome warning. Final rule. *Fed Reg* 2003;68(74):18861-9.
41. Menniti-Ippolito F, Forcella E, Bologna E, *et al*. Use of unconventional medicine in children in Italy. *Eur J Pediatr* 2002;161:690.