



Università degli Studi di Milano

**GRADUATE SCHOOL OF VETERINARY SCIENCES
FOR ANIMAL HEALTH AND FOOD SAFETY**

Director: Prof. Vittorio Dell'Orto

Doctoral Program in Veterinary Clinical Sciences

Academic Year: 2009-2010

**EVALUATION OF ELECTROMYOGRAPHIC
ACTIVITY OF THYROHYOIDEUS (TH) MUSCLE
AND ULTRASONOGRAPHIC ASSESSMENT OF
THE POSITION OF THE HYOID APPARATUS AT
REST AND THEIR POSSIBLE ROLE IN THE
PATHOGENESIS OF INTERMITTENT DORSAL
DISPLACEMENT OF THE SOFT PALATE (DDSP)
IN RACEHORSES**

Giovanni Stancari

Tutor:

Prof. Francesco Ferrucci

Co-Tutor:

Prof. Norm G. Ducharme

Coordinator:

Prof. Angelo Belloli

Index

1. Foreword	5
2. Objectives	9
3. Evaluation of electromyographic activity of thyrohyoideus (TH) muscle and ultrasonographic assessment of the position of the hyoid apparatus at rest and their possible role in the pathogenesis of intermittent dorsal displacement of the soft palate (DDSP) in racehorse	13
3.1 Introduction	15
3.1.1 <i>The Nasopharynx</i>	17
3.1.2 <i>Dorsal displacement of the soft palate(DDSP)</i>	22
3.1.3 <i>Electromyography</i>	30
3.1.4 <i>Ultrasonography of the laryngo-hyoid region</i>	33
3.2 Materials and Methods	36
3.3 Results	40
4. General discussion	43
4.1 Discussion	44
4.2 Conclusions	48
4.3 References	49
5. Summary	61
6. Acknowledgements	69

CHAPTER 1

Foreword

1. Foreword

The horse is an extraordinary athlete, a characteristic that is the result of the evolution of horses as grazing animals on the ancient prairies. Survival in these open lands was enhanced by speed, to escape predators, and endurance, required to travel long distances in search of feed and water. The equid characteristics of speed and endurance were subsequently modified or enhanced by selective breeding by humans (Hinchcliff and Geor, 2008). Horses are able to increase their heart rate nearly 10 folds and their minute ventilation nearly 50-folds during exercise. Regardless of their size, provenance or intended use, all horses have in common an ability to perform physical activities, including running or jumping, at a level that surpasses that of most other animals of similar body size (Hinchcliff and Geor, 2008). However, this wonderful “racing machine” could present some diseases that could reduce its performance.

Horses with poor performance may have multiple concurrent problems, affecting different body systems, which usually appear only at medium or high speed exercise (Martin et al, 2004). These problems could affect different body's apparatuses, such as the muscular-skeletal system, the respiratory tract, the cardiovascular system, and the gastrointestinal tract (Martin et al., 2004). The diseases affecting the respiratory system could also be differentiated between upper respiratory tract (URT) and lower respiratory tract (LRT) dysfunction. URT disease could be structural or functional (Lane et al., 2006). The functional alteration could be also divided in permanent and intermittent dysfunctions. The latter frequently require endoscopy during strenuous exercise for the definitive diagnosis (Lane et al 2006). This can be achieved overground during strenuous exercise with a wireless system or by means of an high speed treadmill (HST). Dynamic obstructive disorders may affect different structures of the URT. Among them the nasopharynx present some peculiarities. It hasn't a really

structural support like bone or cartilage, and the stability of this region is correlated with neuromuscular function and muscle contraction (Holcombe and Ducharme 2004). Horses increase enormously their minute ventilation during exercise and the nasopharynx have to become more and more stiff to resist the increased airway pressures. Whenever this system “fails” several dynamic alterations may appear. The most common intermittent dysfunctions of the nasopharynx are pharyngeal collapse and dorsal displacement of the soft palate (DDSP) (Holcombe and Ducharme, 1999).

CHAPTER 2

Objectives

2. Objectives

Many authors claim that DDSP could be correlated with neuromuscular dysfunction and also with the lower position of the hyoid apparatus. Few investigations have been conducted to evaluate extrinsic factors relating to pharyngeal stability, but it is known that resection of the thyrohyoideus muscles (TH) leads to exercise-induced DDSP in some horses (Ducharme et al 2003; Morello et al 2008). The good outcome obtained with the tie forward surgical procedure could create more doubt about the role of TH in DDSP etiopathogenesis. The purpose of the present work is to investigate TH activity at rest in horses affected with DDSP using surface electromyography (EMG) and correlate the results with the position of hyoid apparatus using ultrasonographic scan of the laryngo-hyoid region.

CHAPTER 3

EVALUATION OF ELECTROMYOGRAPHIC ACTIVITY OF THYROHYOIDEUS (TH) MUSCLE AND ULTRASONOGRAPHIC ASSESSMENT OF THE POSITION OF THE HYOID APPARATUS AT REST AND THEIR POSSIBLE ROLE IN THE PATHOGENESIS OF INTERMITTENT DORSAL DISPLACEMENT OF THE SOFT PALATE (DDSP) IN RACEHORSES

3. EVALUATION OF ELECTROMYOGRAPHIC ACTIVITY OF THYROHYOIDEUS (TH) MUSCLE AND ULTRASONOGRAPHIC ASSESSMENT OF THE POSITION OF THE HYOID APPARATUS AT REST AND THEIR POSSIBLE ROLE IN THE PATHOGENESIS OF INTERMITTENT DORSAL DISPLACEMENT OF THE SOFT PALATE (DDSP) IN RACEHORSES

3.1 Introduction

DDSP is a common disorder causing poor performance in horses; it presents a prevalence ranging from 1.3 to 20% in racehorses (Morris and Seeherman, 1991; Ducharme, 2006). The etiopathogenesis is, still today, not clearly understood (Ducharme et al 2003; Chalmers et al 2009; Holcombe et al 2007; Barakzai et al. 2009; Ortvad et al 2010), as can be drawn by the number of different treatments proposed by many authors (Heffron and Baker 1979; Cook 1981; Zertuche *et al* 1990; Tulleners and Hamir 1991; Carter *et al.* 1993; Ahern 1993; Anderson *et al.* 1995; Llewellyn 1997). There are two major groups of aetiologies that seem to be able to induce DDSP and these are correlated with intrinsic and extrinsic factors. The former affecting the nasopharynx morphologically or functionally. The extrinsic factors are related to the respective position of the hyoid apparatus, larynx and soft palate (Ducharme, 2009). The possible influence of extrinsic factor in stabilizing nasopharynx were proposed in 1994 when Holcombe et al.

found that the sternothyroideus muscle was able to reduce airway resistance during exercise. Recently, Ducharme et al (2003), induced DDSP in horses during exercise after bilateral resection of thyrohyoideus (TH) muscles. Furthermore, during the same study the authors reduced the prevalence of DDSP with a surgical mobilization of the larynx in a more forward and dorsal position, termed “laryngeal tie-forward” procedure. TH contraction seems to be able to pull the larynx cranially and dorsally and/or the basihyoid bone caudally (Sisson, 1975). How this action or its surgical enhancement (i.e. tie forward) can reduce the prevalence of DDSP isn’t perfectly understood (Chalmers et al. 2009). Probably it could change the relationship between larynx and basihyoid bone, reducing the nasopharynx collapsibility and probably the tendency to displace the soft palate (Ducharme 2006).

A more ventral position of the basihyoid bone, using ultrasonographic scan of the larynx, was found in horses with DDSP compared with controls (Chalmers et al 2009). This situation is similar to that found in humans with sleep apnea who presented increased collapsibility of the nasopharynx (Sforza et al 2000; Cuccia et al 2007). The cause of a more ventral position of the hyoideus apparatus is not perfectly understood, and Chalmers et al. 2009 hypothesized that it could be correlated with the phenotype variation or with a dysfunction of several muscles such as TH, genioglossus, geniohyoideus, sternothyroideus or sternohyoideus. In a follow-up study, Ducharme et al. (2003) demonstrated that transection of the TH muscle alone was able to induce DDSP during exercise. Furthermore, one study reports a reduced electromyographic (EMG) activity of TH immediately prior to DDSP in one horse (Ducharme 2001). These authors supposed a possible dysfunction of TH in etiopathogenesis of DDSP.

EMG represents a reliable procedure to investigate neuromuscular function. This is an electrodiagnostic test useful in investigating alterations affecting motor units (Chrisman et al 1972; Sustronck 1994; Andrews 1998; Wijnberg et al 2004).

EMG was introduced in human medicine in 1930 (Chrisman et al 1972), and thereafter in equine medicine with many applications (Ferrucci et al. 1999; Peham et al 2001; Platt 2002; Licka et al 2004). Nowadays EMG is widely accepted as an important tool to investigate muscle function in horses (van Wessum et al 1999), and several studies have reported the use of invasive and non invasive EMG techniques (Cheung et al 1998; Wijnberg et al. 2002; Licka et al 2004; Wijnberg et al. 2008).

The purpose of the present work is to investigate TH activity at rest in horses affected with DDSP using surface electromyography (EMG) and correlate the results with the position of hyoid apparatus using ultrasonographic scan of the laryngo-hyoid region

3.1.1. The Nasopharynx

Horses are obligate nasal breather, this permit to a “fight or flight creature” to graze and masticate while moving air through the nasal passages, maintaining olfaction and the ability to sense predators (Negus, 1929). This kind of animals present the soft palate tightly apposed to the base of the larynx, such that there is no communication between the oropharynx and the nasopharynx, as exist in people (Holcombe and Ducharme, 2004). This is a peculiarity of equine but also of rabbits and rodents. Horses maintain nasal breathing not only at rest, like several other animals and humans, but also during strenuous exercise (Holcombe and Ducharme, 2004; Cheetham et al, 2009). In people the switch point of passage to oral breathing is determinate by the flow resistance in nasal airway and the turbulence of the airflow (Fregosi and Lansing 1995). Horses maintain nasal breathing using capacitance vessel constriction and contraction of upper airway dilating muscles to minimize airflow resistance (Robinson and Sorenson, 1978). In resting horses, two thirds of the total resistance to airflow resides in the upper airway and during exercise the resistance ascribing to this portion of the

respiratory tract increase to the 80% of total airway resistance. The resistance increase because during inspiration the tissues of the URT tend to collapse dynamically as airway pressure become more negative (Robinson and Sorenson, 1978). URT consist of different portions, few of those have structural support of bone and cartilage, but some (i.e. nares, nasopharynx and larynx) rely only on muscular contraction to resist against the increased negative pressure (Holcombe and Ducharme, 2004).

The pharynx could be simply conceptualized as a muscular tube (Holcombe and Ducharme, 2007), but this tract of URT is important for multiple distinct physiologically functions. A carefully orchestrated action of the pharyngeal muscles controls not only the ventilation but also the deglutition and the vocalization. This different actions, contracting the pharyngeal walls during swallowing and dilating the airway during breathing, seems contradictory. But these muscles are uniquely situated to perform both activities, because the pharynx is a conduit for both food and air.

The pharynx is equally divided by the soft palate to form the nasopharynx dorsally and the oropharynx ventrally (Odeh et al, 1993). Nasopharynx is, anatomically, attached to the pterygoid, palatine and hyoid bone, and to the arytenoids, cricoids and thyroid cartilages by muscles that cause pharyngeal dilation and constriction (Sisson, 1975).

Muscles responsible for altering the size and configuration of the nasopharynx include the muscles that alter the shape and position of the tongue, the muscles that control the position of the hyoid apparatus, a constrictor group of muscles located in the dorsal pharynx, and a group of muscles that regulate the position of the soft palate (Holcombe and Ducharme, 2008).

The musculature acting on the nasopharynx can be classified as *intrinsic* or *extrinsic* (Holcombe and Ducharme, 2001). The *intrinsic* muscles, which include those of soft palate and the nasopharyngeal musculature, insert on the mucosa

or the confined walls and roof of the nasopharynx. The *extrinsic* muscles affect either the position of the basihyoid bone or larynx and include those of the larynx and the hyoid apparatus.

The intrinsic musculature contributes to the stability of the nasopharynx mainly by timely muscular contractions that tense and dilate the pharyngeal wall. The floor of the nasopharynx is formed by the soft palate extending caudally from the hard palate to the base of the larynx (Ducharme, 2006). Holcombe et al 1998 identified four intrinsic muscles that act dilating and stabilizing the nasopharynx through neuromuscular activation coordinated with breathing. The most part of these muscles control also the position of the soft palate and are: the tensor veli palatini, levator veli palatini, palatinus, and palatopharyngeus muscles (Holcombe et al 1999). The pharyngeal branch of the vagus nerve innervates all of the muscles controlling the soft palate, except for the tensor veli palatini innerved by the mandibular branch of the trigeminal nerve. Blockade of the pharyngeal branch of the vagus nerve with a local anesthetic agent results in DDSP in horses at rest (Holcombe et al, 1998). This demonstrates that coordinated activity of these muscles is necessary to stabilize the soft palate during breathing. The final intrinsic muscle of the nasopharynx is the stylopharyngeus, which is divided in rostralis and caudalis. The first is a pharyngeal constrictor that is not stimulated during exercise. The caudalis is a pharyngeal dilator muscle innervated by the glossopharyngeal nerve and is responsible for tension on the roof of the nasopharynx that helps it resist collapsing with inspiratory pressure (Ducharme 2006).

The extrinsic muscles contribute to the respiratory patency of the nasopharynx by increasing its diameter or by increasing the stability of the soft palate, or both (Ducharme 2006). All these muscles insert on hyoid apparatus. This is a very important structure that supports the pharynx as well as the root of the tongue and the larynx (Derksen 2006). The hyoid apparatus in horses consists of an

assembly of bony rods, some of which articulate together. These bones are the paired stylohyoid, epihyoid, ceratohyoid, and thyrohyoid bones, and the central basihyoid bone. The stylohyoid bone articulates with the petrous part of the temporal bone, allowing the stylohyoid bones to move cranial to caudal, in a pendulous manner. The ceratohyoid bone attaches to the distal end of the stylohyoid bone (by way of the epihyoid bone), and movement at this articulation lengthens the stylohyoid–ceratohyoid unit. Finally, the thyrohyoid connect the hyoid apparatus with the larynx. Several muscles are attached to this apparatus and their contraction alters its shape and position, changing, finally, the position and shape of the larynx and nasopharynx (Van de Graaf et al 1984; Fregosi and Fuller, 1997). These muscles are the genioglossus, hyoglossus, geniohyoideus, styloglossus, omohyoideus, sternohyoideus, sternothyroideus and TH.

The genioglossus and geniohyoideus are rostrohyoid muscles exerting rostral forces on the hyoid apparatus. They act draw the hyoid apparatus rostrally. The geniohyoideus and genioglossus muscles are innervated by the hypoglossal nerve.

The omohyoideus, sternohyoideus and sternothyroideus muscles are, instead, caudohyoid muscles that originate from the medial aspect of the shoulder fascia and from the sternal manubrium and extend cranially. They insert on the hyoid bones and on the thyroid cartilage of the larynx. These muscles exert a caudal traction on the hyoid apparatus and larynx. Omohyoideus, sternohyoideus and sternothyroideus muscles receive motor innervation from branches of the first and second cervical nerves (Hare, 1975).

Rostrohyoid and caudohyoid muscles work in a coordinated fashion causing a more cranioventral position of basihyoid bone and an increase in the diameter and stability of the nasopharynx in exercising horses (Castro et al 1999, Tessier et al 2004). In horses dysfunction of caudohyoid muscles have been shown

experimentally to increase the upper airway pressure at exercise (Holcombe et al, 1994).

The hyoepiglotticus muscle is another extrinsic muscle known to increase the patency of the nasopharynx. This muscle, during its contraction, pulls the epiglottis ventrally toward the base of the tongue, preventing epiglottic retroversion and increasing the ventral dimension of the rima glottidis (Holcombe et al, 2002). The hyoepiglotticus is innervated by the hypoglossal nerve (Hare, 1975).

The last extrinsic muscle is the TH which is a flat rectangular muscle extends from the lateral lamina of the thyroid cartilage to the caudal aspect of the thyrohyoid bone. Activity of the thyrohyoid muscle is predominantly linked with elevation of the larynx during swallowing (Fukushima et al, 2003; Humbert et al 2006) but it seems also very important for nasopharynx stability. The mechanism of action of the thyrohyoideus muscle is to move the larynx rostrally. With TH contraction the thyroid cartilage rests more dorsal and rostral in relation to the basihyoid and this enhance soft palate stability during exercise (Ducharme et al 2003). Resection of this muscle disrupts the normal stability of the nasopharynx during exercise, resulting in DDSP in exercising horses. Additionally, the insertion of a TH muscle prosthesis (laryngeal tie forward procedure) returned airway function to normal such that DDSP no longer occurred in any of these horses (Ducharme et al 2003). About TH innervation, some authors identified that branch of the hypoglossal nerve reach TH muscle (Cheetham et al 2009), but others suggest that the pharyngeal branch of the vagus is responsible for its innervation (Fukushima et al, 2003). Probably more study needed to better understand the innervation of TH.

In horses with normal function of the nasopharynx and larynx, rostral and caudal hyoid muscles have activity during exercise in phase with respiration.

Furthermore, muscles expected to increase the diameter of the pharynx or rima glottidis (genioglossus, geniohyoideus, and hyoepiglotticus muscles) have increasing activity with increases in exercise intensity, whereas the caudal hyoid muscles have electrical activity that is stable during exercise regardless of the exercise intensity (Morello et al 2008).

Arterial blood supply to the pharynx is provided by the common and external carotid arteries and the linguofacial trunk. Venous drainage is provided by the accompanying veins (Hare, 1975).

3.1.2 Dorsal Displacement Of The Soft Palate (DDSP)

It has been recognized for centuries that upper respiratory tract (URT) obstructions compromise exercise capacity in the equine athlete (Lane et al 2006a). ‘Roaring’ was described during the late 1800s as “a noise emitted from the horse during the effort of inspiration, which is produced owing to the existence of some obstruction in the air passages, either in the nostril, wind pipe or larynx”. Even in those times it was recognized “that which impedes the free passage of air to the lungs must be a rather serious detriment to exertion” (Lupton 1901).

Intermittent dorsal displacement of the soft palate (DDSP) is one of the most common cause of dynamic nasopharyngeal instability identified during treadmill exercise causing poor performance in racehorses (Morris and Seeherman 1991; Hackett *et al.* 1994; Kannegieter and Dore 1995; Lumsden *et al.* 1995; Martin *et al.* 2000; Lane *et al.* 2006). Thoroughbred and Standardbred present the largest prevalence of DDSP varying from 1,3 to 20% (Morris and Seeherman, 1991; Ducharme, 2006). DDSP is an uncommon disease of show hunters and western pleasure horses but does affect horses that carry head and neck in a flexed position, such as upper level dressage horses and saddlebreds (Holcombe and

Ducharme, 2007). Horses with DDSP are exercise intolerant (Derksen 2001) because this affection cause increased expiratory impedance, decreased minute ventilation, hypoxia, and hypercarbia (Rehder et al 1995; Holcombe et al 1998). DDSP is characterized by the displace of the caudal edge of the soft palate over the epiglottis cartilage. Physiologically, the normal epiglottis is positioned dorsal to the soft palate and contacts the caudal free margin, forming a tight seal around the base of the soft palate. The pillars of the soft palate converge dorsally, forming the palatopharyngeal arch. When the soft palate displaces dorsally, the epiglottis cannot be seen in the nasopharynx and is positioned in the oropharynx. The caudal free margin of the soft palate billows across the rima glottidis (Fig. 1) during exhalation, creating airway obstruction (Ducharme 2006). This obstruction causes a reduced airflow during expiration and increase expiratory impedance (Rheder et al 1995; Holcombe et al 1998).

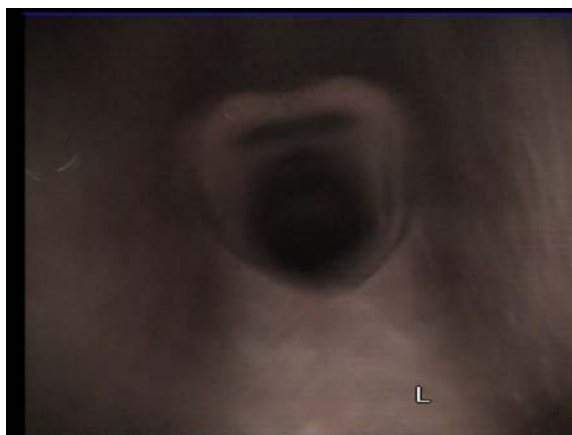


Figure 1 DDSP during exercise

In the major part of cases, DDSP interferes only with ventilation during exercise, producing also an upper respiratory noise. However in some cases, there is also a digestive disturbance that leads to feed, water, and saliva contamination, predominately of the upper airways. The latter generally indicates a more advanced neuromuscular dysfunction of the *palatinus* muscle or an anatomic deficit (such as cleft palate or an acquired deficit of the caudal free edge of the

soft palate—i.e., staphylectomy or loss of epiglottic cartilage secondary to septic epiglottitis or surgical resection) that allows feed contamination of the nasopharynx from the oropharynx (Ducharme, 2006).

The real etiopathogenesis of DDSP is still unknown, and several factors have been implicated supporting the hypothesis of a multifactorial condition (Rehder et al 1995; Holcombe and Ducharme 2007; Chalmers et al, 2009; Ducharme 2009). The causes are divided in two major groups, correlated with intrinsic and extrinsic factors acting on the nasopharynx (Holcombe et al., 1999; Ducharme et al 2003). The studies about the intrinsic factors was realized first and knowledge about those are more developed (Morello et al 2008). The intrinsic factors comprise disorders affecting the nasopharynx morphologically or functionally (Ducharme 2009). The morphological alterations correlated with mechanical factors are all supported only by clinical association and not by experimental investigations (Ducharme, 2006). Some physical alteration are proposed more than fifty years ago, in fact the condition was initially attributed to an overly long soft palate (Quinlan et al, 1949). No data support the overly long soft palate hypothesis except perhaps in rare cases in foals (Shappel et al 1989). Other anatomical alteration are involving the dimension, conformation and stiffness of the epiglottic cartilage (Linford et al 1983; Tulleners and Hamir 1991). Equine practitioners have noted that some horses affected with intermittent DDSP have what appears to be a hypoplastic or “flaccid” epiglottis. Endoscopy during exercise over treadmill showed an appearance of increased “flaccidity” and billowing of the soft palate followed by DDSP (Ducharme 2006). Anyway, a statistical analysis fail to demonstrate a correlation between endoscopic appearance of epiglottic cartilage in horses exhibiting DDSP with horses that didn’t displace their soft palate (Rehder et al 1995). This study showed that epiglottic appearance may not directly act in occurrence of DDSP. These elements reduce, probably, the relevance of epiglottic augmentation in treatment

of DDSP. Ducharme (2006) supposed that the “flaccidity” could be a result of the musculature actions rather than a cause of DDSP. However, epiglottic malformation or condritis have been reported to result in permanent or persistent DDSP (Holcombe and Ducharme, 2007).

Several structural alteration interesting the larynx and pharynx may also participate in DDSP etiology. Any mass or swelling that interferes with the laryngopalatal seal is likely to facilitate dorsal displacement of the soft palate (Ducharme 2009). Cysts of the free border of the soft palate or at the base of the epiglottic cartilage probably interfere with normal subepiglottic position of the soft palate causing a mechanical action and or irritation and pain that stimulates DDSP (Ducharme 2006; Holcombe and Ducharme, 2007). The surgical treatment of the cysts results in immediate postoperative correction of the DDSP (Ducharme 2006). The epiglottic entrapment with epiglottic deformity can also cause intermittent or persistent DDSP (Holcombe and Ducharme, 2007). The epiglottic entrapment is primarily a disease of racing thoroughbreds and standardbreds (Epstein and Parente, 2007) and seem correlated with epiglottic hypoplasia (Linford et al 1983; Tulleners 1991). The entrapment results in the aryepiglottic membrane enveloping the rostral aspect of the epiglottis, covering its physiologically vascular pattern and scalloped edge (Epstein and Parente, 2007). Relieving the epiglottic entrapment will correct the DDSP in some horses (Holcombe and Ducharme, 2007).

Other factors considered are relative to the position of the tongue. The base of the tongue could, during retraction, push the soft palate dorsally inducing DDSP. This hypothesis suggested the use of a tongue tie to pull the tongue out of the mouth exerting a traction on the hyoid apparatus too. Recent experimental studies demonstrated the inefficacy of tongue tie in modifying the pharyngeal morphology and physiology (Beard et al 2001; Cornelisse 2001; Cornelisse 2001a). Other author proposed the excitement or nervousness during

raising as possible cause of DDSP, proposing that this altered behavior may cause an excessive contraction of the caudohyoid muscles that lead to caudal traction of the larynx and consecutive DDSP (Cook, 1981). This hypothesis led to sedation or to surgical transaction of some caudohyoid muscle to correct the retraction of the larynx. Other cause hypothesized is related to the opening of the mouth during exercise. This action permits air to enter the oropharynx disturbing the stabilizing effect of the subatmospheric pressure on the ventral surface of the soft palate (Odeh, 1993). This has led to the use of a dropped or figure-eight nose band to prevent DDSP during exercise. There is no experimental data investigating this hypothesis (Ducharme 2006).

Other studies to investigate the role of intrinsic and extrinsic factors in the etiopathogenesis of DDSP was realized on an experimental-based model. These studies evaluate the neuromuscular control of the nasopharynx, and its role in DDSP appearance. Some studies involved the evaluation of the activity of the muscles controlling the soft palate position. These muscles act dilating and stabilizing the nasopharynx though neuromuscular activation coordinated with breathing (Ducharme 2009). The soft palate position is controlled by the coordinated action of four muscles in people and, probably, in horses (Holcombe et al 1997). They are the *levator veli palatini*, *tensor veli palatini*, *palatinus* and *palatopharyngeus* muscles (Kuehn *et al.* 1982; Moon *et al.* 1994). Particularly, the pharyngeal branch of the vagus nerve, a purely motor nerve, innervates the *palatinus*, *palatopharyngeus* and *levator veli palatini* muscles which control the position of the caudal half of the soft palate. Holcombe et al (1998) blocked the pharyngeal branch of the vagus nerve bilaterally in horses. The objective was to evaluate the possible effect of the muscular block in etiopathogenesis of DDSP. Their contraction shortens the soft palate and depresses its caudal portion toward the tongue. The block of these nerves induced permanent DDSP in horses at rest. The authors concluded that a possible neuromuscular dysfunction

of these structures could induce DDSP. They supposed that every inflammation and or infection interesting the tissues around the nerve may cause a neuritis follow by neuromuscular dysfunction that could take part in the DDSP appearance. However, the clinicians have to consider that these muscles could also present a lack of fitness and/or immaturity which could causes intrinsic nasopharyngeal weakness (Ducharme 2009). Particularly, in a recent study Holcombe et al (2007) evaluate the EMG activity of the *palatinus* and *palatopharyngeus* muscles in horses not affected with DDSP. The authors identified a respiratory related activity of these muscles in exercising horses, principally expiratory, and the activity increases with exercise intensity. The authors demonstrated that these muscles function to support soft palate position during breathing, especially during intense exercise. They supposed that a lack of function of these muscles could participate in DDSP. A reduced EMG activity of the palatinus muscle was identified in horses with DDSP and the activity of this muscle didn't increase as treadmill speed increased (Holcombe et al 1998). Other study involved the pathologic evaluation of the same muscle in horses with intermittent DDSP and were identified abnormalities consistent with chronic denervation in this muscle (Holcombe 2001).

The *levator veli palatini* is innervated by the pharyngeal branch of the vagus nerve too and act elevating the soft palate during swallowing, vocalization and eructation facilitating oral ventilation in nonobligate nasal breathers (Kuehn et al 1982; Moon et al 1994). However, this muscle appears to have little value in stabilizing the soft palate during exercise (Ducharme 2009).

The *tensor veli palatini* is innervated by the mandibular branch of the trigeminal nerve, and act principally by tenses the rostral aspect of the soft palate during exercise depressing this portion toward the tongue (Moon et al 1994; Ducharme 2009). The EMG activity of this muscle, in dogs and human subject, increase during exercise in relation with the increased negative pressure in the pharynx

and with the associated hypoxic hypercapnia (Van der Touw et al 1994a; Van der Touw et al 1994b). Transecting its tendon prior to ramification in the palatine aponeurosis causes the rostral half of the soft palate to become flaccid. This situation causes the soft palate to billow dorsally during inspiration and it's depressed toward the tongue, by the positive pressure during the expiration, but DDSP does not occur. So, the real action of this muscle seems to be to support and dilate the nasopharynx during intense inspiratory efforts in the horse by tensing the rostral soft palate (Holcombe et al 1997).

Few investigations were realized, instead, to evaluate the role of extrinsic factors in etiopathogenesis of DDSP (Morello et al., 2008). The extrinsic muscles contribute to the respiratory patency of the nasopharynx by increasing its diameter or by increasing the stability of the soft palate, or both (Ducharme 2006). The studies about the role of extrinsic factors in stabilizing the nasopharynx started with Holcombe et al (1994). These authors identified an increased inspiratory tracheal pressure after transection of the *sternohyoideus* muscle. They correlated this result with an inspiratory nasopharyngeal collapse compared after this procedure, identifying a possible role of the *sternohyoideus* muscle in nasopharyngeal stability. Recently, EMG evaluation of the *sternohyoideus* and *sternothyroideus* showed an increased activity only at the onset of the exercise, but not with increased speed. These results suggest that the role of the *sternohyoideus* and *sternothyroideus* muscles in maintaining airway patency during exercise are modest (Morello et al., 2008).

After that, few studies was realized to investigate the role of the extrinsic factors in nasopharynx stability.

The *stylopharyngeus* muscle seems to take part in dilating and stabilizing the nasopharynx (Tessier et al 2004). The glossopharyngeal nerve supply motor fiber to the *stylopharyngeus* muscle. Bilateral glossopharyngeal nerve block resulted in dynamic collapse of the dorsal nasopharynx, both at rest occluding horses' nares

and during exercise on a treadmill. An EMG study identified a phasic inspiratory and tonic activity of the *stylopharyngeus* muscle that increase with speed in exercising horse (Tessier et al, 2005). This result seems to confirm the action of this muscle in nasopharynx patency counteracting the increased negative pressures during exercise (Tessier et al, 2005).

The *hyoepiglotticus* muscle is another extrinsic muscle acting on the nasopharynx. This muscle is the only one attaches to the epiglottis (Sisson 1975). The *hyoepiglotticus* muscle has respiratory-related EMG activity that increase with the increase of the speed during exercise. This activity is related also with a depression of the epiglottis over the soft palate increasing the dimension of the *aditus laryngis*, stabilizing the epiglottis during inspiration and preventing its retroversion during exercise (Holcombe et al 2002; Morello et al 2008).

Thyrohyoideus (TH) is another extrinsic muscle that seems to have an important role in nasopharynx stability and particularly in the pathogenesis of DDSP (Ducharme et al 2003; Ducharme 2009). TH is a paired flat muscle inserting on thyroid cartilage of the larynx and on the caudal border of the thyrohyoid bone of the hyoid apparatus. The tight connection between hyoid apparatus and thyroid cartilage was identified, during exercise, when it was noted that basihyoid bone and thyroid cartilage moved in unison caudally during inspiration and rostrally during exhalation (Tsukroff et al 1998). The transection of TH muscle could broke this connection causing DDSP in horses during exercise (Ducharme et al 2003). TH seems to have an important role during swallowing, causing larynx to move cranially and dorsally. In rabbit TH fire during the first phases of swallowing (McFarland and Lund 1993). Instead, its exact role during respiration isn't still perfectly understood (Ducharme et al 2003). EMG evaluation of TH muscle, in normal horses, showed an increased activity at the beginning of the exercise, but without improve with increased velocity (Morello et al 2008). Interestingly, in one horses was identified a reduced EMG activity immediately

prior to DDSP (Ducharme et al 2003). TH seems to have an important role in positioning the larynx rostrally and dorsally to the basihyoid bone during exercise (Ducharme et al 2003). Then, TH could alter the relationship between basihyoid bone and larynx. Moreover, a more ventral position of the basihyoid bone was identified during ultrasonographic evaluation in horses with DDSP (Chalmers et al 2009). The importance of TH in regulate the relationship between hyoid apparatus and larynx was also confirmed when in subject with sperimentally induced DDSP this condition was corrected by placement of sutures replacing the function of the TH muscles, named subsequently “tie forward procedure” (Ducharme *et al.* 2003). The proposed mechanism of this procedure is to mimic the action of the TH muscles and prevents ventral descent and caudal retraction of the larynx (Woodie *et al.* 2005). Particularly, it moves the basihyoid bone dorsally and caudally, and the larynx rostrally and dorsally (Cheetham et al 2008). Further studies validated the efficacy of this surgical procedure in correcting natural occurring DDSP (Woodie et al 2005; Cheetham et al 2008). Then, a possible TH neuromuscular dysfunction could be implicate in DDSP pathogenesis.

3.1.3 Electromyography

The term electromyography (EMG) was first coined by Weddell et al., in 1943, who pioneered the clinical use of needle electrode examination of muscles (Katirji B. 2002).

EMG is a widely used technique for clinical purpose and research in human and veterinary medicine.

Clinical EMG, also known as electrodiagnostic study, is the electrophysiological examination of peripheral nerve and muscle. It is a distinct discipline and plays a pivotal role in the evaluation and management of patients with neuromuscular disorders. Clinical EMG best serves as an extension of the neurologic

examination. It is well suited to diagnose disorders of the peripheral nervous system, including the sensory nerves, the dorsal root ganglia, and the motor unit (Katirji, 2002).

The EMG is, in fact, an evaluation of the electrical activity of the motor unit, which is composed by: motor neuron cell body, its axon, axon terminals, myoneural junctions and the muscle fibers that it innervates (Sustronck, 1994). EMG was introduced around the 1930 in human medicine for the evaluation of the motor unit activity (Chrisman et al 1972) and around 1970 in veterinary medicine, first in small animals and then also in horses. It has become very useful as an aid to the clinical diagnosis of many peripheral nerve diseases in dogs, cats and man which result in functional denervation of muscle fiber and myopathies. The accumulated experience of recent years has shown that electrophysiological methods have a definite place in the investigation and diagnosis of certain categories of clinical weakness disorders. In addition, these methods have enabled the physiological characteristics of muscle and the peripheral nervous system to be studied in health and disease (Platt, 2002)

The essential components of the electromyograph comprise electrodes for recording potentials, an amplifier to enlarge the small electric potential, a filter to reduce unwanted noise, and a data recording device (Loeb and Gans, 1986). Data are transferred from the electrodes to the amplifier through wires or via telemetry. The data are usually converted from analog to digital format and stored in a computer. Special software is used to process the information and to measure variables such as the amplitude and frequency of the spikes, to rectify the output, to construct an envelope that touches the peaks of the spikes, and to measure the areas under the resulting curves. The electrodes function as the antenna to pick up the electrical signal in the muscle. They may be placed on the skin surface, inserted percutaneously into the muscle, or implanted surgically. The last one provides the best results in terms of electrical and mechanical

reliability but it's a more complex, time-consuming and potentially damaging procedure (van Wessum et al. 1999).

The probes inserted percutaneously are generally needles which are invasive and their used in exercising animals are, at the moment, difficult. Moreover two competing influences make the needle EMG study especially demanding: first, many of the abnormalities on the needle study are subtle. At the same time, however, the range of normal findings is quite large and varies with age and the muscle being studied (Preston and Shapiro, 2002).

The surface electrodes have the advantage of being non-invasive but provide only a gross estimation of muscle activity in the large superficial muscle groups (van Wessum et al. 1999). However studies which used surface electrodes found the technique to be reliable and to produce more reproducible and consistent data than electrodes positioned intramuscularly (Viitasalo and Komi 1975; Kabada et al 1985; Jansen et al 1992).

Surface EMG (sEMG) is a physiological method which functions very much like an electrocardiogram (EKG) and can be recorded the same way. In both sEMG and EKG, sensors are used to detect the low amplitude changes in electric potential that occur with the activation of the muscle tissue (Vaiman et al 2004).

During sEMG testing, there is a certain amount of impedance noise that arises directly from the resistance of the electrodes' connection to the skin. This feature makes skin resistance a significant factor when working with the low level EMG signals typical of the small muscles involved in swallowing. Wiping the skin with isopropyl alcohol in a water solution has proven in human medicine to be the best form of preparation for most situations. The alcohol removes the dead skin and surface oils, and the water moistens the skin and provides improved ion flow (Vaiman 2007).

In human medicine sEMG is widely used and provides information on the timing of selected muscle contraction patterns during swallowing (Perlmann

1993; Logemann 1994). Between the different patterns the EMG amplitude, however, remains an important aspect in the relationship between muscle force and the associated electric activity, although there is no simple relationship between a sEMG signal and muscle force. When all the different types of neuromuscular disorders are considered collectively, amplitudes are by far the most informative features (Vaiman 2007). Indeed, some authors argue that amplitudes are the only components that have a direct relationship to clinical symptoms (muscle weakness) in neurogenic lesions (Wilbourn 2002).

Surface EMG is thus a valid technique for assessing and quantifying whole muscle function according to statistical criteria (Hermens et al 1984). Surface EMG is a highly reliable measure of muscle activity across repetitions and testing days, obtaining reliability coefficients superior to that of invasive wire EMG recordings, showing greater stability, and providing more information about the activity level (Cooper and Perlman 1996). In addition to these advantages, sEMG is a diagnostic procedure rapid, simple, and easily performed (Vaiman et al 2004).

3.1.4 Ultrasonography Of The Laryngohyoid Region

Clinical evaluation of the upper airway of horses with the presenting complaint of poor performance or abnormal respiratory noise is typically initiated with a thorough physical examination. The latter may be normal or, in many instances, might not fully characterize the problem, necessitating further diagnostic tests (Chalmers and Ducharme, 2009). Between them, videoendoscopy is commonly used to evaluate the function and the stability of the equine upper airway, either at rest or during treadmill exercise (Hackett et al 1991; Parente et al 2002). However videoendoscopy has limitations too. The upper airway anatomy can only be assessed from the lumen and thus non-luminal structures including the intrinsic and extrinsic laryngeal muscles and hyoid bones are not evaluated.

Therefore although the function of the larynx can be determined, many anatomic components of the larynx and related structures are largely not assessed except by gross palpation. For some conditions, such as DDSF, videendoscopy at rest has been found to have a poor correlation with the diagnosis of DDSF made during treadmill exercise, and therefore the latter is often required to make a definitive diagnosis. (Parente et al 2002). Anyway, also videendoscopy during exercise present several limitation, including the cost of treadmill examination and limited availability of treadmill facilities. Laryngeal ultrasound was introduced as an added diagnostic technique for the equine upper airways to address some of these limitations (Chalmers and Ducharme, 2009).

The use of ultrasound in the evaluation of the human, feline, and canine larynx has been described (Friedman 1997; Rudorf, 1997). Ultrasound has been used to diagnose laryngeal paralysis in dogs and laryngeal masses in dogs and cats (Rudorf, 1997 and 2001). In humans, sonography has been used to evaluate vocal fold function in infants and adults, and in some instances may be preferred over endoscopy as it is less invasive and can be performed at the bedside (Friedman 1997; Schade et al 2003).

In equine species ultrasound examination of the larynx was described by Chalmers et al 2006 and Chalmers and Ducharme 2009. The exam can be performed on the standing horse, yields both structural and functional information, and allows the nonluminal aspect of the upper airway to be evaluated. Specifically one can assess the following structures: portions of the hyoid apparatus, laryngo-hyoid position, strap muscles of the neck, laryngeal and perilaryngeal musculature and laryngeal cartilage (except the epiglottis). The examination is performed with high resolution transducers and to evaluate all the structures two different transducer are needed. Particularly during a systematic laryngeal examination the best option is to use 12.5 MHz linear array and a 8.5

MHz convex (14-mm) transducer. Is preferable to examine the horse restrained in stocks wearing a standard halter. The examination is performed with the horse unsedated; hair clipping is not generally required and alcohol is usually used as coupling agent. The authors described four acoustic windows: rostroventral, midventral, caudoventral, and right and left caudolateral. These are scanned on longitudinal and transverse planes for the ventral windows and in a longitudinal plane for the lateral windows. The rostroventral window is defined as the region between the rostral tip of the lingual process of the basihyoid bone and the body of the basihyoid bone. The midventral window (fig. 2) is defined as the region between the basihyoid bone and the thyroid cartilage and is identified in the longitudinal plane with the probe directly on the midline.

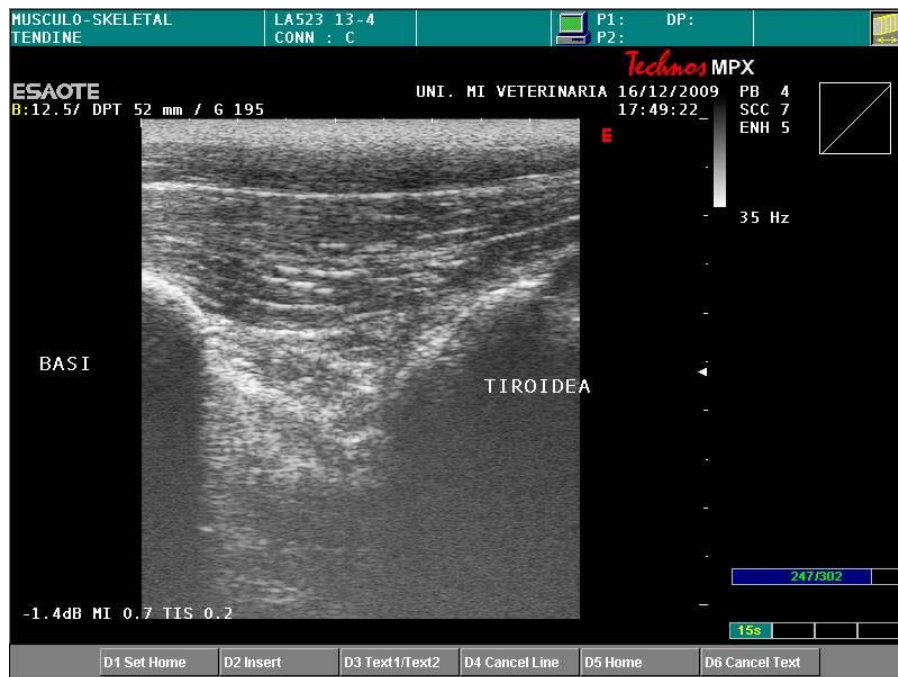

Figure 2: Midventral window

The caudoventral window is defined as the cricothyroid notch, easily identified by palpation. The caudolateral windows (right and left) is identified by following

the cricoid cartilage dorsolaterally from the caudoventral window (Chalmers et al 2006).

The midventral window is useful for evaluating the laryngo-hyoid relationship. Clinical interest in this region stems from investigations of the TH muscles' role in laryngo-hyoid position and DDSP (Chalmers and Ducharme, 2009). Possibly, the anatomic and spatial relationships of the larynx and the basi-hyoid bone are important in the collapsibility of the nasopharynx, and therefore the tendency for dorsal displacement of the soft palate (Ducharme, 2006). Horses with dorsal displacement of the soft palate may have a more caudally positioned larynx (Woodie et al 2005). In humans with sleep apnea, a ventral/caudal position of the hyoid bone is predictive of increased tendency for airway collapse, likely due to increased nasopharyngeal compliance (Sforza et al 2000; Cuccia et al 2007). Therefore, the relationship of the larynx and the basi-hyoid bone may be important in predisposing horses to dorsal displacement of the soft palate (Chalmers et al 2009).

3.2 Materials and methods

12 racehorses (10 Standardbreds and 2 Thoroughbreds), were selected between the patients referred to the Department of Clinical Sciences - Internal Medicine and Sport Medicine Section - of the Large Animal Hospital, University of Milan in the period between September 2009 to December 2010, with history of poor performance. They ranged in age between 2 and 4 years (mean age $3.1 \pm 0,7$ years) with a mean body weight of $468,9 \pm 52,3$ kg. All horses underwent a thorough diagnostic protocol, including a general physical examination, routine laboratory evaluation, metabolic evaluation during exercise, cardiocirculatory and respiratory tract examination at rest and during exercise, gastroscopy, ultrasonographic scan of the laryngeal-hyoid portion and EMG evaluation of TH

muscles. Exercise tests were realized using an high-speed treadmill (SATO-I, Sweden). (Fig. 3).



Figure 3: High speed treadmill in a dedicated room with controlled environment

The horses were acclimatized to work on the treadmill by two daily training sessions. During each sessions and during the tests all horses were tacked with the same harness used for racing, and a heart rate meter (Polar Horsetrainer) was used to determine heart rate (HR) during exercise at different speeds. On day 3 was performed the metabolic test and on day 4 the treadmill endoscopy was performed for evaluate upper airways for any dynamic obstruction. The latter was performed with a standardized protocol with a warm up of 4 min walking (1.5 m/s) and 5 min trotting (4.5 m/s for Thoroughbreds and 6 m/s for Standardbreds) with 3°slope for Standardbreds and 6°slope for Thoroughbreds. Then the horse was stopped and a videoendoscope (Stortz®-Germany) was introduced into the nasopharynx and held in position with Velcro straps. The treadmill was then rapidly accelerated up to the selected speed, corresponding to maximal HR (≥ 220 bpm), for a distance ranging from 1600 m to 2100 m or until

the horse was no longer able to maintain the belt speed. Upper airways images were visualized on a digital monitor and recorded by a DVD recorder on digital supports for later slow-motion analysis and storage. For the purpose of this study horses were classified into one of two groups based on treadmill videoendoscopy: DDSP with the caudal border of the epiglottis situated dorsal to the epiglottis for a minimum of 8 s and horses without DDSP.

On day 5 the patients underwent endoscopy of the respiratory tract and gastroscopy.

When the patients recovered completely from sedation was performed ultrasonographic scan of the laryngo-hyoid region using Technos MPX (Esaote biomedical) ultrasonographic machine with a linear array transducer (7.0-14.0 MHz) set on 12.5 MHz. The examination was performed on each horse in the same manner. Horses were restrained in stock and alcohol was used as an acoustic coupling agent. With the horse head in neutral position were evaluated two acoustic windows: rostroventral and midventral, in longitudinal and transverse planes according with Chalmers et al 2006. The rostroventral window corresponding to the region between the rostral tip of the lingual process of the basi-hyoid bone and the body of the basi-hyoid bone. At this region was measured the depth of the basi-hyoid bone at the base of lingual process on transverse plane. The midventral window is the region between the basi-hyoid bone and the thyroid cartilage and was evaluated in the longitudinal plane with the probe directly on the midline. The measures made were the depth of the caudal aspect of the basi-hyoid bone, the depth of the rostral aspect of the thyroid cartilage, and the distance from the caudal aspect of the basi-hyoid bone to the rostral aspect of the thyroid cartilage. All measurements were made at least three times on three separate images using electronic calipers on the ultrasound machine.

After that was evaluated the EMG activity of the TH muscles using a



Figure 4 EMG Machine.

Keypoint® portable (Medtronic, Denmark) EMG machine connected to a laptop (fig. 4) with installed a dedicated software (Keypoint®.Net, Medtronic, Denmark) for visualization and subsequent analysis and storage of the signals.

The TH muscles were evaluated with surface electrodes (Tyco, Kendall Care (Ag/AgCl, dim 2,5x2,3) connected to the EMG machine by wire (HUSH Clip Cable, Medtronic, Denmark). Ground was obtained by a needle (Ambu® Neuroline subdermal, 12x 0,040mm, 0,5x27 G) inserted subcutaneously near the surface electrodes. The evaluation was made first on the left side and then on the right side. The topographic area corresponding to the TH muscle, which is cranially to thyrohyoid cartilage identified by palpation of the larynx, was clipped and cleaned with alcohol to permit a better contact of the electrodes and reducing interference. TH activity was measured during deglutition obtained following administration of 50 ml of water in the mouth using a 50 ml syringe. This operation was repeated at least five time for each side and every activity connected with deglutition recorded. Electromyographic signals were processed through a sixth-order Butterworth filter (common mode rejection ratio, >100 dB; band pass, 100 to 3,000 Hz), amplified, rectified, and processed to yield a moving-time-averaged (time constant, 50 milliseconds) value. The moving-time-

averaged EMG was quantified by use of a method described by Ledlie et al 1983. The digitized area of the moving-time-averaged signal was divided by the duration of activity to define the raw MEA. This value was then adjusted by dividing each signal by its appropriate gain (which had been used earlier to amplify the signal) to define the adjusted MEA. The MEA identified for each sides was obtained by the mean value of the MEA measured for every deglutition.

The statistical analysis of the results was made comparing the two groups, horses with DDSP (wDDSP) and without DDSP (nDDSP), considering all the measures of the laryngohyoid position, the MEA of TH muscle on the left side (MEAl), the MEA of TH muscle on the right side (MEAr) and mean MEA obtained from the two sides (MEArL) for every horse. The analysis was realized with a statistical software SIGMAPlot®12. For all statistical analysis, values were considered significant at $P \leq 0.05$.

Using SIGMAPlot®12 was realized a Shapiro-Wilk test to assess the normal distribution of the data followed by a t-test to compare every data between the group wDDSP and nDDSP. Next a Pearson Product Moment Correlation was used to evaluate the correlation between the different data in nDDSP and wDDSP groups. Finally the relationship between age, sex and weight on MEAr, MEAl, MEArL and laryngohyoid measures was analyzed using a linear regression test.

3.4 Results

Every procedures were well tolerated by the horses. The videoendoscopy of the upper airways during exercise on a high speed treadmill permitted to diagnose DDSP in 5 horses (4 standardbred and 1 Thoroughbred), pharyngeal collapse in 1 horse, pharyngeal collapse associated with axial deviation of the aryepiglottic

folds (ADAF) in 2 horses and no dynamic abnormality of the upper respiratory tract (URT) in 4 horses. The measures of the laryngochoyoid region in wDDSP patients and nDDSP are reported in Tab. 1 and 2.

deep BH bone at BLP	deep T	deep BH bone	dist BH-T
29,90	30,4	19,8	15,4
26,3	32,8	26,4	16,6
19,6	25,3	15,1	16,0
34,9	37,4	20,1	25,0
22	30,7	23,4	14,4
22,6	34,7	22,2	15,7
25	29,8	14,2	24,9

Table 1. Laryngochoyoid measures in nDDSP. BH=basihyoid bone; BLP=base of lingual process; T=thyroid cartilage

deep BH bone at BLP	deep T	deep BH bone	dist BH-T
24,1	33,0	26,0	17,0
31,1	40,1	30,4	16,4
22,3	30,2	24,1	16,2
23,4	30,1	25,0	20,1
21,3	28,4	21,3	16,7

Table 2. Laryngochoyoid measures in wDDSP. BH=basihyoid bone; BLP=base of lingual process; T=thyroid cartilage

The values of the MEAr, MEAl and MEArI in the two groups are reported in Tab. 3 and 4.

MEA l	MEA r	MEA rl
6,59	5,10	5,85
4,28	5,40	4,84
5,43	5,67	5,55
5,69	6,28	5,99
5,24	6,69	5,97
5,57	5,30	5,44
4,78	6,04	5,41

Table 3. Activity of thyrohyoideus muscles in nDDSP.

MEA l	MEA r	MEA rl
8,74	8,25	8,50
4,74	4,21	4,48
7,97	8,23	8,10
4,26	4,24	4,25
4,35	4,85	4,60

Table 4. Activity of thyrohyoideus muscles in wDDSP.

The statistical analysis, using Pearson Product Moment Correlation test, showed only in the wDDSP group some relationship between the data analyzed. A strong relationship (p. 0,0019) was found between the depth of the basihyoid bone at the base of lingual process and depth of the rostral aspect of the thyroid cartilage on the midventral window. Another strong relationship (p. 0,0092) was found between depth of the rostral aspect of the thyroid cartilage and depth of the caudal aspect of the basihyoid bone in the midventral window. Finally, strong correlations were found between MEAr and MEAl (p. 0,0039), MEAr and MEArI (p. 0,0005) and MEAl and MEArI (p. 0,0004).

CHAPTER 5

General Discussion

4. 1 Discussion

The etiopathogenesis of DDSP is still today not fully understood and it was supposed it may be multifactorial (Chalmers 2009). Study about the role of extrinsic factors started in 1994 when it was found that the sternothyroideus muscles play a role in reducing airway resistance on the upper airways (Holcombe et al 1994). Recently, it was found that a bilateral resection of TH muscle was able to induce DDSP during exercise (Ducharme et al 2003). Following this result, the surgical mobilization of the larynx in a more forward and dorsal position, termed a laryngeal tie-forward procedure, showed to improve upper airway stability and reduce the prevalence of DDSP at exercise (Woodie et al 2005). The mechanism by which the TH muscles, or their surgical enhancement, exert a stabilizing effect on the soft palate is unknown. Possibly, the anatomic and spatial relationships of the larynx and the basihyoid bone are important in the collapsibility of the nasopharynx, and therefore the tendency for dorsal displacement of the soft palate (Ducharme et al 2006). It has recently been shown that a more dorsally positioned basihyoid bone is associated with improved performance following surgery for DDSP in horses and that horses with DDSP during exercise have a more ventral position of the basihyoid bone at rest (Chalmers et al 2009).

Our results didn't identify any statistical difference in laryngo-hyoid measures between nDDSP and wDDSP groups. Anyway, in wDDSP groups we found a high correlation between depth of the basihyoid bone and the depth of the thyroid cartilage. It is likely, therefore, that in wDDSP group, with the increase in depth of the basihyoid bone there's a correlated increase in depth of the thyroid cartilage. This correlation would be consistent with the finding that the dorsal movement of the larynx after laryngeal tie forward procedure is more important than rostrocaudal movement to return performance (Cheetham et al 2008). Besides, the physiological activity of TH muscle is to move the larynx in

the same way (Ducharme et al 2003). The existence of a direct correlation between depth of thyroid cartilage and basihyoid bone may suggest the occurrence of an improper alignment between hyoid apparatus and larynx, and thus a greater muscular effort of the TH muscles in the upward movement of the larynx in DDSP patients.

Our results showed in wDDSP group a good correlation between the MEA of left and right TH muscles and the mean value of MEA. So, probably, the MEA on one side could be related to the MEA of the TH on the other side.

However we didn't find any statistical difference between the MEA values in wDDSP and nDDSP group. However, this result does not come totally unexpected. Probably, our results are directly conditioned by several factors like the number of subjects included and the type of test realized. In fact, our goal was to evaluate the possible difference in the TH MEA at rest in patients with DDSP compared with those without DDSP. Statistical analysis confirmed the absence of any difference between MEA in nDDSP and WDDSP patients at rest. The group of wDDSP is composed by subject with intermittent DDSP, so normal at rest, but with DDSP only during exercise. We evaluate TH MEA at rest, so in our test there's only brief bursts of activity during swallowing and not a continuous activity like during exercise. Probably more information regarding the activity of TH muscles could be obtained with the evaluation during exercise. In fact recent study demonstrated that frequency of swallowing increases immediately prior to the onset of DDSP (Pigott et al 2010). Particularly, this reflex could be caused by the sensory input from the horse's nasopharynx which may detect instability and trigger a swallowing reaction to stabilize the nasopharynx. During deglutition the larynx is pulled dorsally and cranially by the action of TH muscles. Some authors also hypothesized that the critical respiratory role of the TH muscles in horses is to position the larynx rostrally and dorsally to the basihyoid bone during exercise. In addition, the more ventral

position of the larynx, in line with the basihyoid bone, would result in alignment of the vector of forces of 1) omohyoid and sternohyoid muscles, 2) action of sternothyroid muscles and 3) the caudal descent of the larynx associated with the tracheal pull due to pulmonary inflation. The alignment of these 3 vectors would increase their synergistic action and lead to a more caudal position of the basihyoid bone further displacing the larynx caudally and facilitating DDSP (Ducharme et al 2003). Probably DDSP horses are unable to maintain a correct position of the larynx during exercise due to fatigue of TH muscles. Fatigue could be defined as a “failure to maintain the required or expected force” (Edwards 1981). Relative to our results we found also a good correlation between the activity of both TH muscles in wDDSP group. The explanation for the results obtained is quite difficult to explain. It may be hypothesized that the activity of both TH muscles of both sides in wDDSP could be similar, whereas in nDDSP horses a difference between the two muscles may exist or they could function without any correlation at rest. During exercise this could mean that fatigue could occur at the same level of increased activity bilaterally with a possible “total” dysfunction of TH and further caudal position of the larynx facilitating DDSP during exercise. Obviously, more study about the activity of TH muscle during exercise are needed to better explain its role in intermittent DDSP.

We consider that the absence of any statistical differences in the data measured between the nDDSP and wDDSP groups could be related to the small number of cases included in this study. Also the analysis of the effect of age, sex and weight on the activity, using linear regression didn't show any statistical difference between nDDSP and wDDSP.

The study in fact had a number of limitations which probably influenced the efficacy of the statistical analysis. First, the number of horses was really limited, but this was related to the typology of the case load referred to the Hospital.

Probably larger number of horses could give more detailed results and also more statistical differences between wDDSP and nDDSP horses. Second, the ideal control population would be a group with no history of poor performance. Unfortunately this was not practicable and control horses were selected from a population referred with a history of poor performance.

The results obtained in this study have to be considered as preliminary. Anyway, even when the small number of horses is considered, these results allow to rule out any difference in activity of TH at rest in horses with intermittent DDSP. Another point to be considered is the very well tolerated technique used. In fact, we were able to study activity of TH muscles with completely non-invasive technique. This is particularly important when operating on privately owned horses.

4.2 Conclusions

The results obtained did not show any functional abnormality at rest of TH in horses with intermittent DDSP. According to this preliminary results it can be hypothesized that any possible functional alteration should necessarily occur under particularly condition such as maximal or submaximal exercise. The occurrence of DDSP under exercise condition may suggest that fatigue may play an important role in the onset of DDSP. Further investigation are necessary to evaluate TH function under exercise condition and this should be correlated with several parameter related to fatigue such as blood lactate evaluated during treadmill exercise test. Eventually, it appears important to evaluate the reported method in horses with permanent DDSP in which a possible abnormality in TH activity might be detected even under resting conditions.

The results obtained provide several information regarding the pathogenesis of intermittent DDSP. Future results obtained with the evaluation of the same parameters under exercise conditions may aid the clinician to identify the actual

causes for DDSP and to establish new prophylactic and therapeutic protocol in order to prevent the occurrence of this important disorder.

4.3 References

Ahern TJ (1993) *Oral palatopharyngoplasty; a survey of one hundred post-operative raced horses*. Journal of equine veterinary Sciences 1: 3; 670-672

Anderson JD, Tulleners EP, Johnston JK and Reeves MJ (1995) *Sternothyrohyoideus myectomy or staphylectomy for treatment of intermittent dorsal displacement of the soft palate in racehorses: 209 cases (1986-1991)*. Journal of the American Veterinary Medical Association (JAVMA) **206**, 1909-1912.

Andrew F.M. (1998) *“Electrodiagnostic Aids and Selected Neurologic Disease”*. In: Reed S.M and Bayly W.M. (eds): Equine Internal Medicine II ed, Saunders Co., Philadelphia, pag. 438-451

Barakzai SZ, Boden LA , Hillyer MH, Marlin DJ and Dixon PM (2009) *Efficacy of thermal cautery for intermittent dorsal displacement of the soft palate as compared to conservatively treated horses: Results from 78 treadmill diagnosed horses* Equine Veterinary Journal 41 (1) 65-69

Beard WL, Holcombe SJ, Hinchcliff KW (2001) *Effect of a tongue-tie on upper airway mechanics during exercise following sternothyrohyoid myectomy in clinically normal horses*, Am J Vet Res;62:779-782.

Carter, B., Robertson, J., Beard, W. and Moore, R.M. (1993) *Sternothyroideus myectomy, tenectomy and staphylectomy for treatment of dorsal displacement of the soft palate in horses*. Veterinary Surgery **22**, 374.

Castro HA, Resende LA, Bérzin F, König B. (1999) *Electromyographic analysis of the superior belly of the omohyoid muscle and anterior belly of the digastric muscle in tongue and head movements*. J Electromyogr Kinesiol. Jun;9(3):229-32

Chalmers H. J., Cheetham J., Yeager A. E., Ducharme N. G. (2006) *Ultrasonography of the equine larynx* Veterinary Radiology & Ultrasound, Vol. 47, No. 5, , pp 476–481

Chalmers HJ and Ducharme NG (2009) *Ultrasonographic Examination of the Upper Airway* in: Robinson NE and Sprayberry KA (eds): *Current Therapy in Equine Medicine* 6, St. Louis, Missouri, Saunders Elsevier, p243-249

Chalmers HJ, Yeager AE and Ducharme NG (2009) *Ultrasonographic assessment of laryngohyoid position as a predictor of dorsal displacement of the soft palate in horses*. *Veterinary Radiology & Ultrasound* 50 1 91-96

Cheetham J, Pigott JH, Thorson LM, Mohammed HO, Ducharme NG. (2008) *Racing performance following the laryngeal tie-forward procedure: a case-controlled study*. *Equine Vet J* 40: 501–507.

Cheetham J, Pigott JH, Hermanson JW, Campoy L, Soderholm LV, Thorson LM and Ducharme NG. (2009) *Role of the hypoglossal nerve in equine nasopharyngeal stability*. *J Appl Physiol*. Aug;107(2):471-7.

Cheung TK, Warren LK, Lawrence LM and Thompson KN (1998) *Electromyographic activity of the long digital extensor muscle in the exercising Thoroughbred horse* *Equine Veterinary Journal* 30: 251-255

Chrisman C.L., Burt J.K., Wood P.K., Johnson E.W. (1972) *Electromyography in Small Animal Clinical Neurology* *Journal of the American Veterinary Medical Association* 160 (3) 311-318

Cooper DS and Perlman AL. (1996) *Electromyography in the functional and diagnostic testing of deglutition*. In: Perlman AL, Schulze-Delrieu KS, eds. *Deglutition and its disorders*. London: Singular;. p. 255-85.

Cornelisse CJ, Rosenstein DS, Derksen FJ and Holcombe SJ. (2001) *Computed tomographic study of the effect of a tongue-tie on hyoid apparatus position and nasopharyngeal dimensions in anesthetized horses*, *Am J Vet Res*;62:1865-1869.

Cornelisse CJ, Holcombe SJ, Derksen FJ, Berney C, Jackson CA (2001a) *Effect of a tongue-tie on upper airway mechanics in horses during exercise*, *Am J Vet Res*;62:775-778.

Cook, W.R. (1981) *Some observations on form and function of the equine upper airway in health and disease: I. The pharynx*. *Proc. Am. Ass. equine Practnrs*. **27**,355-391.

Cuccia AM, Campisi G, Cannavale R, Colella G. *Obesity and craniofacial variables in subjects with obstructive sleep apnea syndrome: comparisons of cephalometric values.* Head Face Med 2007;22:41.

Derksen FJ, Holcombe SJ, Hartmann W, Robinson NE and Stick JA. (2001) *Spectrum analysis of respiratory sounds in exercising horses with experimentally induced laryngeal hemiplegia or dorsal displacement of the soft palate.* Am J Vet Res. May;62(5):659-64.

Derksen FJ (2006) *Overview of Upper Airway Function* In: Auer JA, Stick JA (eds): Equine surgery III ed. St-Louis: WB Saunders/Elsevier; p. 516-522

Ducharme, N.G. (2001) *The function of the extrinsic musculature in stabilising the upper airways.* In: Proceedings of WEAS 2001 CD. Lifelearn, Guelph, Canada.

Ducharme NG, Hackett RP, Woodie JB, Dykes N, Erb HN, Mitchell LM, Soderholm LV (2003) *Investigations into the role of the thyrohyoid muscles in the pathogenesis of dorsal displacement of the soft palate in horses.* Equine Veterinary Journal 35:258–263.

Ducharme NG (2006). *Pharynx.* In: Auer JA, Stick JA (eds): Equine surgery III ed. St-Louis: WB Saunders/Elsevier; p. 544–565

Ducharme (2009) *Etiopathogenesis of nasopharyngeal instability with focus on DDSP and its diagnosis.* In: Proceedings of 4th Skyve Resort Meeting, December 10-12, p 41-44

Edwards RHT (1981) *Human muscle function and fatigue.* In: Porter R, Whelan J (eds), Human muscle fatigue: Physiological mechanisms. Pitman medical, London

Epstein KL and Parente EJ (2007) *Epiglottic fold entrapment* : McGorum BC, Dixon PM, Robinson NE and Schumacher J (eds) Equine respiratory medicine and surgery Saunders/Elsevier Ltd. p 459-465

Ferrucci F, Zucca E, Croci C, Scaioli V, Daniel S, Albertini M and Costanzi M (1999) *“Muscle biopsy and electromyographic findings in five mares with clinical diagnosis of Equine Motor Neuron Disease”.* Journal of Equine Veterinary Science, 19(9), 568-569 (Proceedings of the 6th WEVA Congress, Paris, September-October 1999). Wildomar, California, USA

Fregosi RF, Lansing RW (1995) *Neural Drive to nasal dilator muscles: influence of exercise intensity and oronasal flow partitioning*. Journal of Applied Physiology 79 (4): 1330-1337

Fregosi RF, Fuller DD. (1997) *Respiratory-related control of extrinsic tongue muscle activity*. Respir Physiol; 110:295–306.

Friedman EM (1997) *Role of ultrasound in the assessment of vocal cord function in infants and children*. Ann Otol Rhinol Laryngol;106:199–209.

Fukushima S, Shingai T, Kitagawa J, Takahashi Y, Taguchi Y, Noda T, Yamada Y (2003) *Role of the pharyngeal branch of the vagus nerve in laryngeal elevation and UES pressure during swallowing in rabbits*, Dysphagia 18:58-63.

Hare WCD (1975) *Equine respiratory system*. In Getty R, editor: Sisson and Grossman's The Anatomy of Domestic Animal, ed 5, Philadelphia, WB Saunders.

Hackett RP, Ducharme NG, Fubini SL, Erb HN (1991). *The reliability of endoscopic examination in assessment of arytenoid cartilage movement in horses. Part I: subjective and objective laryngeal evaluation*. Vet Surg;20:174–179.

Hackett, R.P., Ducharme, N.G. and Mitchell, L. (1994) *The role of treadmill endoscopy in diagnosis of dynamic obstruction of the upper airway*. Proc. Am. Ass. equine Practnrs. 40, 83.

Heffron CJ and Baker, C.W. (1979) *Observations on the mechanism of functional obstruction of the nasopharyngeal airway in the horse*. Equine Veterinary Journal 11, 142-147

Hermens HJ, Boon KL and Zilvold G. (1984) *The clinical use of surface EMG*. Electromyogr Clin Neurophysiol 24:243-65.

Hinchcliff WH and Geor RJ (2008) *The horse as an athlete: a physiological overview* in: Hinchcliff WH, Geor RJ and Kaneps AJ (eds): Equine exercise physiology. Philadelphia: Saunders/Elsevier 2-11

Holcombe SJ, Beard WL, Hinchcliff KW, Robertson JT (1994). *Effect of sternothyrohyoid myectomy on upper airway mechanics in normal horses*. Journal of Applied Physiology 77:2812–2816.

Holcombe SJ, Derksen FJ, Stick JA and Robinson NE (1997) *Effects of bilateral hypoglossal and glossopharyngeal nerve blocks on epiglottic and soft palate position in exercising horses*. Am J Vet Res 58:1022–1026

Holcombe S.J., Derksen F.J., Stick J.A. e Robinson N.E. (1997a) *Effect of bilateral tenectomy of the tensor veli palatini muscle on soft palate function in horses* Am J vet res; 58: 317-321

Holcombe SJ, Derksen FJ, Stick JA, Robinson NE (1998) *Effect of bilateral blockade of the pharyngeal branch of the vagus nerve on soft palate function in horses*. Am J Vet Res. Apr;59(4):504-8.

Holcombe e Ducharme (1999) in: Auer JA, Stick JA (eds): *Equine surgery II* ed. St-Louis: WB Saunders/Elsevier; p. 340

Holcombe SJ, Derksen FJ, Stick JA, Robinson NE (1999). *Pathophysiology of dorsal displacement of the soft palate in horses*. Equine Vet J Suppl. Jul;30:45-8.

Holcombe SJ (2001) *New thoughts on URT anatomy: Relevancy*. Proceedings of the 29th annual surgical forum, American College of Veterinary Surgeons, Chicago, IL; 59-62

Holcombe SJ and Ducharme NG (2001) *The function of extrinsic and intrinsic musculature in stabilizing the upper airway*. In Proc World Equine Airway Symposium, CD Edinburg, Scotland.

Holcombe SJ, Cornelisse CJ, Berney C, and Robinson NE (2002) *Electromyographic activity of the hyoepiglotticus muscle and control of epiglottis position in horses*, Am J Vet Res;63:1617-1621

Holcombe and Ducharme (2004) *Upper airway function of normal horses during exercise*. In: Hinchcliff K, Kaneps A, Geor R (eds): *Equine Sports Medicine and Surgery*, Saunders/Elsevier Ltd. p. 541-557

Holcombe SJ, Derksen FJ and Robinson NE (2007) *Electromyographic activity of the palatinus and palatopharyngeus muscles in exercising horses*. Equine Veterinary Journal 39 (5) 451-455

Holcombe SJ and Ducharme NG (2007) *Disorders of the nasopharynx and soft palate* in: McGorum BC, Dixon PM, Robinson NE and Schumacher J (eds) *Equine respiratory medicine and surgery* Saunders/Elsevier Ltd. P. 437-457

- Holcombe SJ and Ducharme NG (2008) *Upper airway function of normal horses during exercise* in: Hinchcliff WH, Geor RJ and Kaneps AJ (eds): *Equine exercise physiology*. Philadelphia: Saunders/Elsevier 170-192
- Humbert IA, Poletto CJ, Saxon KG, Kearney PR, Crujido L, Wright-Harp W, Payne J, Jeffries N, Sonies BC and Ludlow CL (2006) *The effect of surface electrical stimulation on hyolaryngeal movement in normal individuals at rest and during swallowing*. *J Appl Physiol*;101:1657–1663.
- Jansen MO, Raay JAGM van, Bogert AJ van den, Schamhardt HC and Hartman W (1992) *Quantitative analysis of computer-averaged electromyographic profiles of intrinsic limb muscles in ponies at walk*. *Am j vet res*; 53(12) 2343-2349
- Kadaba MP, Wootten ME and Gainey (1985) *Repeatability of phasic muscle activity: performance of surface and intramuscular wire electrodes in gait analysis* *J. Ortop. Res*;3: 350-359
- Kannegieter, N.J. and Dore, M.L. (1995) *Endoscopy of the upper respiratory tract during treadmill exercise: a clinical study of 100 horses*. *Aust. vet. J.* **72**, 101-107
- Katirji B. (2002) *The clinical electromyography examination An overview* *Neurol Clin N Am* 20 291–303
- Katirji B. (2002) *Clinical electromyography* *Neurol Clin N Am* 20 (2002a) xi–xii
- Kuehn, D.P., Folkins, J.W. and Cutting, C.B. (1982) *Relationships between muscle activity and velar position*. *Cleft Palate J.* 19, 25-35
- Lane, J.G., Bladon, B., Little, D.R.M., Naylor, J.R.J. and Franklin, S.H. (2006a) *Dynamic obstructions of the equine upper respiratory tract 1: observations during high-speed treadmill endoscopy in 600 Thoroughbred racehorses*. *Equine vet. J.* 38, 393-399.
- Lane, J.G., Bladon, B., Little, D.M., Naylor, J.R. and Franklin, S.H. (2006) *Dynamic obstructions of the equine upper respiratory tract. Part 2: Comparison of endoscopic findings at rest and during high-speed treadmill exercise of 600 Thoroughbred racehorses*. *Equine Veterinary Journal* 38, 401-408.
- Ledlie JF, Pack AI, Fishman AP. (1983) *Effects of hypercapnia and hypoxia on abdominal expiratory nerve activity*. *J Appl Physiol* 55:1614–1622

Licka T.F., Peham C., Frey A. (2004) "Electromyographic activity of the longissimus dorsi muscles in horses during trotting on a treadmill" American Journal of Veterinary Research 65(2) 155-158

Linford RL, O'Brien TR, Wheat JD and Meagher DM (1983) Radiographic assessment of the epiglottic length and pharyngeal and laryngeal diameters in the Thoroughbred Am J Vet Res;44:1660.

Loeb GE and Gans C (1986) Electromyography for experimentalists. The University of Chicago Press, Chicago

Logemann JA. (1994) *Nonimaging techniques for the study of swallowing*. Acta Otorhino Laryngol Belg;48:139-42

Llewellyn, H.R. (1997) *Sternothyroideus myotomy for the treatment of dorsal displacement of the soft palate*. Proc. Am. Ass. equine Practnrs. 43, 239-243.

Lumsden, J.M., Stick, J.A., Caron, J.J., Nickels, F.A., Brown, C.M., Godber, L.M. and Derksen, F.J. (1995) *Upper airway function in performance horses: Videoendoscopy during high-speed treadmill exercise*. Comp. cont. Educ. pract. Vet. 17, 1134-1143

Lupton, J.I. (1901) *Mayhew's Illustrated Horse Doctor*. New Edition. William Glaiser, London.

Martin, B.B. Jr., Reef, V.B., Parente, E.J. and Sage, A.D. (2000) *Causes of poor performance of horses during training, racing, or showing: 348 cases (1992- 1996)*. J. Am. vet. med. Ass. 216, 554-558.

Martin Jr. BB, Davidson EJ, Durando MM and Birks EK (2004) *Clinical exercise testing: overview of causes of poor performance*. In: Hinchcliff K, Kaneps A, Geor R (eds) Equine Sports Medicine and Surgery Saunders/Elsevier Ltd. P. 32-41

Moon, J.B., Smith, A.E., Folkins, J.W., Lemke, J.H. and Gartian, M. (1994) *Coordination of velopharyngeal muscle activity during positioning of the soft palate*. Cleft Palate Craniofac. J. 31, 45-55.

Morello SL, Ducharme NG, Hackett RP, Warnick LD, Mitchell LM Soderholm LV (2008) *Activity of selected rostral and caudal hyoid muscles in clinically normal horses during strenuous exercise* American Journal of Veterinary Research, 69, 5, 682–689

Morris EA and Seeherman HJ. (1991) *Clinical evaluation of poor performance in the racehorse: the results of 275 evaluations*. Equine Veterinary Journal 23: 169–174.

- Negus VE (1929) *The function of the epiglottis*. J anat; 62:1-8
- Odeh M, Schall R, Gavriely N and Oliven A (1993) *Effect of upper airway muscle contraction on supraglottic resistance and stability*. Respir Physiol;56:139.
- Ortved KF, Cheetham J, Mitchell LM and Ducharme NG (2010) *Successful treatment of persistent dorsal displacement of the soft palate and evaluation of laryngohyoid position in 15 racehorses* Equine Veterinary Journal 42 (1) 23-29
- Parente EJ, Martin BB, Tulleners EP, Ross MW (2002) *Dorsal displacement of the soft palate in 92 horses during high-speed treadmill examination (1993–1998)*. Vet Surg;31:507–512.
- Peham C., Licka T.F., Scheidl M. (2001) *“Evaluation of a signal-adapted filter for processing of periodic electromyography signals in horses walking on a treadmill”* American Journal of Veterinary Research 65(11) 1687-1689
- Perlman AL. (1993) *Electromyography and the study of oropharyngeal swallowing*. Dysphagia 8:351-5.
- Pigott JH, Ducharme NG, Mitchell LM, Soderholm LV and Cheetham J (2010) *Incidence of swallowing during exercise in horses with dorsal displacement of the soft palate* Equine Veterinary Journal 42 (8) 732-737
- Platt S.R. (2002) *“Advancing the role of electrodiagnostic techniques in equine neuromuscular disease”* Equine Veterinary Journal 34 (6) 538-539
- Preston D. C. and Shapiro B. E. (2002) *Needle electromyography Fundamentals, normal and abnormal patterns* Neurol Clin N Am 20 361–396
- Quinlan J, Van Rensburg SWJ, Starke NC (1949) *The soft palate (palatinum molle) as a cause of dyspnoea in two racehorses*, J South Afr Vet Assoc;20:125-127.
- Rehder RS, Ducharme NG, Hackett RP, Nielan GJ. (1995) *Measurement of upper airway pressures in exercising horses with dorsal displacement of the soft palate*. Am J Vet Res. Mar;56(3):269-74.
- Robinson NE and Sorenson PR (1978). *Pathophysiology of airway obstruction in horses: a review*. J Am Vet Med Assoc 172(3):299–304.
- Rudorf H. (1997) *Ultrasound imaging of the tongue and larynx in normal dogs*. J Small Anim Pract;38:439–444.

Rudorf H, Barr FJ, Lane JG. (2001) *The role of ultrasound in the assessment of laryngeal paralysis in the dog*. Vet Radiol Ultrasound 42: 338–343.

Sforza E, Bacon W, Weiss T, Thibault A, Petiau C, Krieger J. (2000). *Upper airway collapsibility and cephalometric variables in patients with obstructive sleep apnea*. Am J Respir Crit Care Med 161: 347–352.

Schade C, Kothe C, Leuwer R. (2003) [*Sonography of the larynx—an alternative to laryngoscopy*] Abstract (Article in German). HNO;51:585–590.

Shappel KK, Caron JP, Stick JA (1989) *Staphylectomy for treatment of dorsal displacement of the soft palate in two foals*, J Am Vet Med Assoc;195:1395

Sisson S (1975) *Equine myology*. In: Getty R. Sisson and Grossman's eds in: The Anatomy of domestic animals 5th Ed., Philadelphia: WB Saunders; 386-388

Sisson S. (1975a) *Equine digestive system*. In: Getty R, ed. Sisson and Grossman's The anatomy of domestic animals. 5th edn. Philadelphia: WB Saunders 471–475.

Sustronck B. (1994) *Electromyographic examination in the horse*. Veterinary Annual 34 97-106

Tessier C, Holcombe SJ, Derksen FJ, Berney C and Boruta D. (2004) *Effects of stylopharyngeus muscle dysfunction on the nasopharynx in exercising horses*. Equine Veterinary Journal May;36(4):318-23

Tessier C., Holcombe S. J., Stick J.A., Derksen F. J. and Boruta D. (2005) *Electromyographic activity of the stylopharyngeus muscle in exercising horse* Equine Veterinary Journal 37(3) 232-235

Tsukroff S., Ducharme NG, Bertram JE, and Hackett RP (1998) *Relationship of basihyoid bone and thyroid cartilage in exercising horse*. In: CD Proceedings of 1st Meeting of the World Equine Airway Symposium

Tulleners E (1991) *Correlation of performance with endoscopic and radiographic assessment of epiglottic hypoplasia in racehorses with epiglottic entrapment corrected by use of contact neodymium:yttrium aluminum garnet laser*. J Am Vet Med Assoc. Feb 15;198(4):621-6

Tulleners E. and Hamir A. (1991) *Evaluation of epiglottic augmentation by use of polytetrafluoroethylene paste in horses*. American Journal of Veterinary Research 52, 1908-1916.

Vaiman M, Eviatar E and Segal S (2004) *Surface electromyographic studies of swallowing in normal subjects: A review of 440 adults. Report 3. Quantitative data*. Otolaryngology-Head and neck Surgery 131:6 977-985

Vaiman M, Eviatar E and Segal S (2004a) *Surface electromyographic studies of swallowing in normal subjects: A review of 440 adults. Report 1. Quantitative data: Timing measures*. Otolaryngology- Head and neck Surgery 131:4 549-555

Vaiman M (2007) *Standardization of surface electromyography utilized to evaluate patients with dysphagia* Head & Face Medicine 6; 3:26

Van de Graaff WB, Gottfried SB, Mitra J, van Lunteren E, Cherniack NS, Strohl KP. (1984) *Respiratory function of hyoid muscles and hyoid arch*. J Appl Physiol. Jul;57(1):197-204.

Van der Touw T, O'neil N., Brancatisano A., Amis T, Wheatley J, Engel LA (1994a) *Respiratory related activity of soft palate muscles: augmentation by negative upper airway pressure* J Appl Physiol 76: 424-432

Van der Touw T, O'neil N., Amis T., Wheatley J, Brancatisano A (1994b) *Soft palate muscle activity in response to hypoxic hypercapnia* J Appl Physiol 77: 2600-2605

van Wessum R., Sloet van Oldruitenborgh-Oosterbaan M.M., Clayton H .M. (1999) *Electromyography in the horse in veterinary medicine and in Veterinary research- a review* The Veterinary Quarterly, 21 (1) 3-7

Viitasalo JHT and Komi PV (1975) *Signal characteristics of EMG with special reference to reproducibility of measurements* Acta Physiol Scand 93: 531-539

Wijnberg ID, Franssen H, van der Kolk JH and Breukink HJ (2002) *Quantitative motor unit action potential analysis of skeletal muscles in the Warmblood horse* Equine veterinary Journal 34; 556-561

Wijnberg I.D., Back W., de Jong M., Zuidhof M.C., van den Belt A.J.M., van der Kolk J.H (2004) *The role of electromyography in clinical diagnosis of neuromuscular locomotor problems in the horse*. Equine Veterinary Journal 36(8) 718-722

Wijnberg ID, van Dam KG, Graaf-Roelfsema E, Keizer HA, van Ginneken MM, Barneveld A, Breda E and van der Kolk JH (2008) *(Over)training effects on quantitative electromyography and muscle enzyme activities in standardbred horses*. J Appl Physiol. Dec;105(6):1746-53.

Wilbourn AJ (2002) *Nerve conduction studies: types, components, abnormalities, and value in localization* Clinical electromyography. Neurol Clin, 20:310-11.

Woodie JB, Ducharme NG, Kanter P, Hackett RP, Erb HN. (2005) *Surgical advancement of the larynx (laryngeal tie forward procedure) as a treatment for dorsal displacement of the soft palate in horses: a prospective study 2001–2004*. Equine Vet J 37:418–423

Zertuche, J.M.L., Turner, T.A. and Colahan, P.T. (1990) *Strap muscle myectomy for treatment of idiopathic intermittent dorsal displacement of the soft palate in racing Thoroughbreds*. Veterinary Surgery 12, 182. (Abstr.)

CHAPTER 6

Summary

6. Summary

Introduction

Horses with poor performance may have multiple concurrent problems, affecting different body systems, which usually appear only at medium or high speed exercise. Between them, particularly interesting are the intermittent dynamic diseases affecting the upper respiratory tract (URT). Dorsal displacement of the soft palate (DDSP) is one of the most common intermittent dysfunctions of the nasopharynx presenting a prevalence ranging from 1.3 to 20% in racehorses. The DDSP etiopathogenesis is, still today, not clearly understood. Recently was induced DDSP in horses during exercise after bilateral resection of thyrohyoideus (TH) muscles. DDSP was also correlated to a more ventral position of the basioid bone evaluated using ultrasonographic scan of the laryngooid region.

Objectives

The purpose of the present work is to investigate TH activity at rest in horses affected with DDSP using surface electromyography (EMG) and correlate the results with the position of hyoid apparatus using ultrasonographic scan of the laryngooid region.

Materials and method

12 racehorses (10 Standardbreds and 2 Thoroughbreds), were selected between the patients referred to the Department of Clinical Sciences - Internal Medicine and Sport Medicine Section - of the Large Animal Hospital, University of Milan in the period between September 2009 to December 2010, with history of poor performance. They ranged in age between 2 and 4 years (mean age $3.1 \pm 0,7$ years) with a mean body weight of $468,9 \pm 52,3$ kg. All horses underwent a thorough diagnostic protocol, including a general physical examination, routine laboratory evaluation, metabolic evaluation during exercise, cardiocirculatory and respiratory tract examination at rest and during exercise, gastroscopy, ultrasonographic scan of the laryngeal-hyoid portion and EMG evaluation of TH

muscles. Exercise tests were realized using an high-speed treadmill (SATO-I, Sweden) and all the exercise tests was performed using a standardized protocol. On day 4 the treadmill endoscopy using a videoendoscope (Stortz®-Germany) held in position with Velcro straps was performed. For the purpose of this study horses were classified into one of two groups based on treadmill videoendoscopy results: DDSP when the caudal border of the epiglottis was situated dorsal to the epiglottis for a minimum of 8 s and horses without DDSP if DDSP wasn't discovered..

On day 5 the patients underwent ultrasonographic scan of the laryngo-hyoid region using Technos MPX (Esaote biomedical) ultrasonographic machine with a linear array transducer (7.0-14.0 MHz) set on 12.5 MHz. Two acoustic windows were evaluated: rostroventral and midventral, in longitudinal and transverse planes. Using the electronic caliper of the machine were measured the depth of the basihyoid bone at the base of lingual process, the depth of the caudal aspect of the basihyoid bone, the depth of the rostral aspect of the thyroid cartilage, and the distance from the caudal aspect of the basihyoid bone to the rostral aspect of the thyroid cartilage.

The EMG activity of the TH muscles was evaluated at rest with surface electrodes (Tyco, Kendall Care (Ag/AgCl, dim 2,5x2,3) connected by wire (HUSH Clip Cable, Medtronic, Denmark) with a Keypoint® portable (Medtronic, Denmark) EMG machine connected to a laptop with installed a dedicated software (Keypoint®.Net, Medtronic, Denmark) for visualization and subsequent analysis and storage of the signals.

Ground was obtained by subcutaneous needle (Ambu® Neuroline subdermal, 12x 0,040mm, 0,5x27 G). The evaluation was made on both sides at the level of the topographic area corresponding to the TH muscle, which was clipped and cleaned with alcohol.. TH activity was measured during deglutition obtained following administration of 50 ml of water in the mouth using a 50 ml syringe.

This operation was repeated at least five times for each side and every activity connected with deglutition recorded. Electromyographic signals were processed through a sixth-order Butterworth filter (common mode rejection ratio, >100 dB; band pass, 100 to 3,000 Hz), amplified, rectified, and processed to yield a moving-time-averaged (time constant, 50 milliseconds) value. The digitized area of the moving-time-averaged signal was divided by the duration of activity to define the raw MEA. This value was then adjusted by dividing each signal by its appropriate gain (which had been used earlier to amplify the signal) to define the adjusted MEA. The MEA identified for each side was obtained by the mean value of the MEA measured for every deglutition.

The statistical analysis of the results was made comparing the two groups, horses with DDSP (wDDSP) and without DDSP (nDDSP), considering all the measures of the laryngohyoid position, the MEA of TH muscle on the left side (MEAL), the MEA of TH muscle on the right side (MEAR) and mean MEA obtained from the two sides (MEARL) for every horse. The analysis was realized with a statistical software SIGMAPlot®12.

Using SIGMAPlot®12 was realized a Shapiro-Wilk test to assess the normal distribution of the data followed by a t-test to compare every data between the group wDDSP and nDDSP. Next a Pearson Product Moment Correlation was used to evaluate the correlation between the different data in nDDSP and wDDSP groups. Finally the relationship between age, sex and weight on MEAR, MEAL, MEARL and laryngohyoid measures was analyzed using a linear regression test. For all statistical analysis, values were considered significant at $P \leq 0.05$.

Results

The videoendoscopy of the upper airways during exercise on a high speed treadmill permitted to diagnose DDSP in 5 horses (4 standardbred and 1

Throughbred), pharyngeal collapse in 1 horse, pharyngeal collapse associated with axial deviation of the aryepiglottic folds (ADAF) in 2 horses and no dynamic abnormality of the upper respiratory tract (URT) in 4 horses. The statistical analysis, using Pearson Product Moment Correlation test, showed only in the wDDSP group some correlation between the data analyzed. A strong correlation ($p = 0,0019$) was found between the depth of the basihyoid bone at the base of lingual process and depth of the rostral aspect of the thyroid cartilage on the midventral window. Another strong correlation ($p = 0,0092$) was found between depth of the rostral aspect of the thyroid cartilage and depth of the caudal aspect of the basihyoid bone in the midventral window. Finally, strong correlations were found between MEAr and MEAl ($p = 0,0039$), MEAr and MEArI ($p = 0,0005$) and MEAl and MEArI ($p = 0,0004$). No other difference or correlation were found.

Discussion and conclusion:

Our results didn't identify any statistical difference in laryngo-hyoid measures between nDDSP and wDDSP groups. Anyway, in wDDSP groups we found a high correlation between depth of the basihyoid bone and the depth of the thyroid cartilage. This strong relationship may confirm the importance of the connection between hyoid apparatus and larynx in DDSP patients. We didn't find any difference between MEA in nDDSP and wDDSP patients at rest. Probably, our results are directly conditioned by the type of test realized. The group of wDDSP is composed by subject with intermittent DDSP, so normal at rest, but with DDSP only during exercise. Probably more information regarding the activity of TH muscles could be obtained with the evaluation during exercise. The results obtained provide informations regarding the pathogenesis of intermittent DDSP. Future results obtained with the evaluation of the same

parameters under exercise conditions may aid the clinician to identify the actual causes for DDSP.

CHAPTER 7

Acknowledgements

7. Acknowledgements

I would like to express my gratitude first of all to my family, to Prof Ferrucci, Prof Ducharme, Dr. Zucca, Dr. Conturba, all the staff and the students attending the Equine section of the Large Animal Hospital of Lodi, to all my friends and particularly to Rosanna.

Thank you very much!!