

Tiziano Testori  
 Massimo Del Fabbro  
 Matteo Capelli  
 Francesco Zuffetti  
 Luca Francetti  
 Roberto L. Weinstein

# Immediate occlusal loading and tilted implants for the rehabilitation of the atrophic edentulous maxilla: 1-year interim results of a multicenter prospective study

## Authors' affiliation:

Tiziano Testori, Massimo Del Fabbro, Matteo Capelli, Francesco Zuffetti, Luca Francetti, Roberto L. Weinstein, Istituto Ortopedico Galeazzi IRCCS, Department of Odontology, Milan University, Milan, Italy

## Correspondence to:

Massimo Del Fabbro  
 Istituto Ortopedico Galeazzi IRCCS  
 Department of Odontology  
 Milan University  
 Via R. Galeazzi 4  
 20161 Milan  
 Italy  
 Tel.: +39 02 50319950  
 Fax: +39 02 50319960  
 e-mail: massimo.delfabbro@unimi.it

**Key words:** dental implants, edentulous maxilla, immediate loading, tilted implants

## Abstract

**Objectives:** The aims of this prospective study were to assess the treatment outcome of immediately loaded full-arch fixed bridges anchored to both tilted and axially placed implants for the rehabilitation of fully edentulous maxillae and to compare the outcome of axial vs. tilted implants.

**Material and methods:** Forty-one patients with edentulous maxillae were included in the study. Each patient received a full-arch fixed bridge supported by four axial implants and two distal tilted implants. Loading was applied within 48 h from surgery. Patients were scheduled for follow-up at 6 months, 1 year and annually up to 5 years. Radiographic evaluation of marginal bone-level change was performed at 1 year.

**Results:** One patient died 4 months after surgery. Thirty patients were followed for a minimum of 1 year (range 3–42 months, mean 22.1 months). Three failures were recorded at 1-year follow-up (two axial implants and one tilted). Two more implants (one tilted and one axially placed) were lost within 18 months of loading. The 1-year implant survival rate was 98.8% for both axial and tilted implants. Prosthesis success rate was 100% at 1 year. Marginal bone loss around axial and tilted implants at 12-month evaluation was similar, being, respectively,  $0.9 \pm 0.4$  (standard deviation) mm and  $0.8 \pm 0.5$  mm.

**Conclusions:** The present preliminary data suggest that immediate loading associated with tilted implants could be considered to be a viable treatment modality for the atrophic maxilla and that there does not seem to be a different clinical outcome between tilted and axial implants.

The rehabilitation of edentulous jaws with osseointegrated implants has been proven to be a predictable treatment over time (Adell et al. 1990). However, rehabilitation of the edentulous maxilla is associated with anatomical limitations due to the reduced bone volume particularly in the premolar–molar region.

Distal cantilevers for positioning teeth in the absence of a distal implant have been suggested; however, the survival rates for this type of treatment with distal extensions longer than 15 mm are lower than

with shorter cantilevers (Shackleton et al. 1994).

Short implants (<8 mm long) could be an alternative but a minimum amount of at least 7 mm vertical bone height should exist (Goene et al. 2005; Renouard & Nisand 2005).

Bone grafting and sinus elevation via the crestal or the lateral approach are other treatment options (Wallace & Froum 2003; Del Fabbro et al. 2004) but patient acceptance of these types of procedures could be low due to the invasive nature of the

## Date:

Accepted 7 March 2007

## To cite this article:

Testori T, Del Fabbro M, Capelli M, Zuffetti F, Francetti L, Weinstein RL. Immediate occlusal loading and tilted implants for the rehabilitation of the atrophic edentulous maxilla: 1-year interim results of a multicenter prospective study. *Clin. Oral Impl. Res.*  
 doi: 10.1111/j.1600-0501.2007.01472.x

surgical procedure associated with an increased risk of morbidity and high costs.

Pterigoid (Balshi et al. 1999) and tuberosity (Bahat 1992; Khayat & Nader 1994; Venturelli 1996) implants represent other treatment options to restore the edentulous maxilla; however, these treatments could also be associated with increased morbidity. Zygomatic (Brånemark et al. 2004) implants in some clinical situations could represent another possibility, especially in extremely atrophic maxilla, but considerable surgical experience is needed.

The technique of tilting implants in order to improve bone anchorage reducing the need for bone grafting has been recently advocated by many authors (Krekmanov 2000; Krekmanov et al. 2000; Aparicio et al. 2001, 2002; Fortin et al. 2002; Calandriello & Tomatis 2005) and could provide a viable, minimally invasive treatment modality, leading to high patients acceptance.

Patients seeking replacement of a denture with an implant-supported prosthesis are mainly interested in a fixed restoration. If, after the diagnostic phase, a fixed prosthesis could provide optimal lip support esthetic and phonetics without compromising oral hygiene and without the need for bone grafting, then patient satisfaction can be achieved at its highest level.

The aims of this study were to evaluate the treatment outcome and patients' satisfaction with immediately loaded full-arch fixed prostheses anchored to both axial and tilted implants in the upper jaw and to compare the clinical outcome of tilted (test) vs. axial (control) implants in the same patients up to 5 years.

This report presents preliminary 12-month data on the implant survival and on peri-implant marginal bone-level changes around tilted and axial implants. A survival analysis is also presented considering the overall loading time for all the patients.

## Material and methods

### Inclusion criteria

- Patients with totally edentulous maxilla.
- Male and female of all races 18 years or older.
- Patients with severely resorbed maxilla with at least 4 mm height and 6 mm

width in the first premolar region that would have needed bone augmentation for placing implants in a more posterior location (Fig. 1a and b).

- Patients for whom a decision has already been made to use dental implants but expressed strong reluctance for any kind of bone augmentation.
- Patients physically and psychologically able to tolerate conventional implant dentistry.
- Patients who agreed to sign an informed consent form.
- All implants were to be seated with a torque  $\geq 30$  N cm.

In case one or two axial implants could not be inserted with a torque  $\geq 30$  N cm, immediate loading was still allowed because those implants were splinted to adjacent stable implants. In case either one of the tilted implants or three or more axial implants did not achieve the required primary stability, immediate loading was not applied and implants were left to heal for at least 2 months before the prosthetic phase.

Participants were informed about the nature of the study and signed an informed consent.

### Exclusion criteria

- Presence of active infection or inflammation in the areas intended for implant placement.
- Presence of systemic diseases such as uncontrolled diabetes.
- Patients irradiated in the head and neck regions within 12 months before surgery.
- Presence of previous unresorbed allograft at the implant site.
- Severe bruxism or clenching habits.
- Pregnancy.
- Poor oral hygiene and motivation.

Patients were recruited and treated in three dental clinics located in North of Italy, with specific expertise in the treatment of patients by means of immediate loading procedures. One surgeon with considerable clinical experience in implant dentistry performed all surgical procedures at each center. For this specific type of treatment, no randomization was possible between the test (tilted implants) and the control group (axially positioned implants).

### Surgical procedure

Antibiotic prophylaxis was prescribed, consisting of amoxicillin and clavulanic acid (Augmentin<sup>®</sup>, Roche, Milan, Italy) 2 g 1 h before surgery. A sedative pre-medication [Diazepam (Valium<sup>®</sup>) Roche] was administered to anxious patients.

A local anesthetic agent containing articaine 1:100 (Ultracain<sup>®</sup> D-S forte, Aventis Pharma Deutschland GmbH, Frankfurt, Germany) was used.

A crestal incision was made starting in the first molar, with a vertical-releasing incision at the midline. A mucoperiosteal buccal flap was raised and the facial bony wall was exposed. A small antrostomy using a piezosurgery unit with a diamond round insert was performed to determine the position of the anterior sinus wall. Each patient received six implants in the maxilla. The posterior tapered implant was placed first (Osseotite NT Implant, 3i Implant Innovations, Palm Beach, FL, USA); it was tilted distally approximately 30–35° relative to the vertical plane parallel to the anterior sinus wall. Visual observation through lateral antrostomy allowed the surgeon to insure that the implant did not protrude into the sinus.

The two axially oriented anterior implants were then placed in the pre-maxilla, parallel to the midline. At first, the most mesial implant was inserted at the level of the central incisor; finally, the third implant was placed about halfway between the other two.

Careful site preparation was followed in order to obtain high primary stability; a 30 N cm insertion torque was validated by the drilling unit torque indication (W&H Elcomed, W&H Dental Werk, Burmoos GmbH, Austria). The drilling protocol for NT-tapered implants was followed. In soft bone, under-preparation was performed using a shaping drill one size smaller than the final implant diameter.

In most of the cases, the implant shoulder was placed at the crest. All of the posterior tilted implants required bone contouring on the distal aspect, allowing for proper seating of the prosthesis.

The surgical procedure was repeated in the contra-lateral side.

At the end of the surgical phase, an impression was taken utilizing a pick-up technique and a novel radiopaque sterile impression material, recently approved by

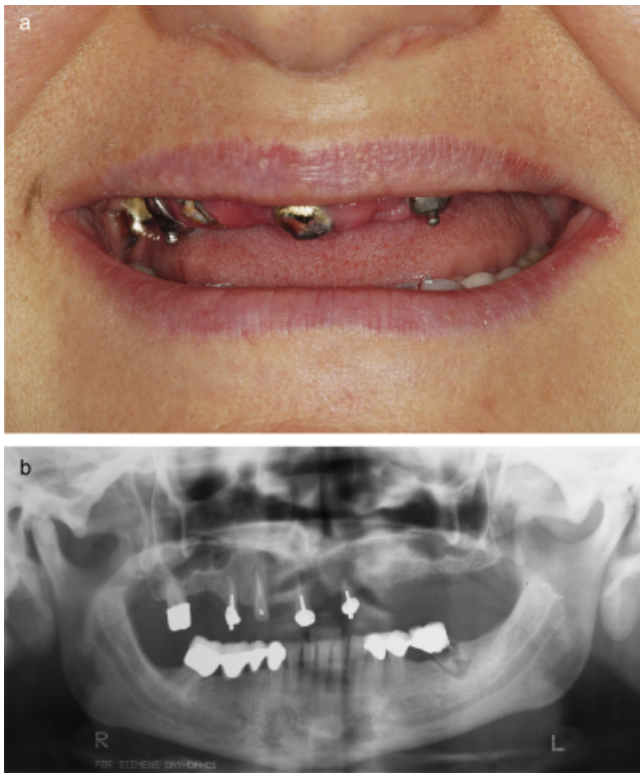


Fig. 1. (a) Pre-operative frontal view without the removable prosthesis. (b) Pre-operative orthopantomograph of the clinical case.

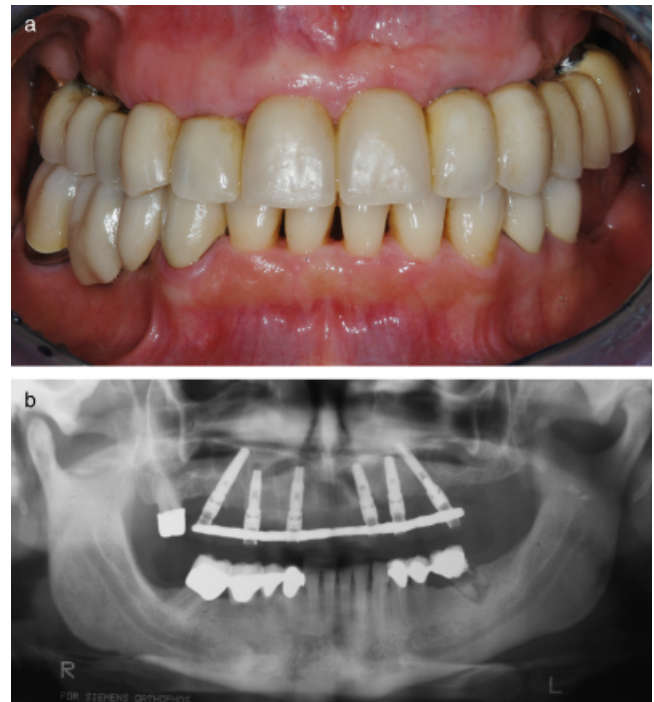

Fig. 2. (a) Immediately (48 h after surgery) loaded provisional prosthesis. (b) Orthopantomograph with metal-reinforced full-arch provisional prosthesis.

CE and FDA (Elite Implant Impression Material, Zhermack®, Badia Polesine, Rovigo, Italy).

Finally, a bite registration was taken and healing abutments were placed at 10 N cm using a torque controller.

**Restorative phase**

The provisional screw-retained prosthesis was delivered within 48 h from surgery using temporary provisional cylinders with fiber-reinforced acrylic teeth (Fig. 2a and b).

If the screw access hole was emerging on the vestibular site of the prosthesis, a composite resin was used to achieve an acceptable esthetic appearance. The final prosthesis was delivered 3 months later (Fig. 3a-c).

Seven final prosthesis were screw retained, fabricated with a titanium framework (CRESCO™ Astra Tech Implant System, Astra Tech AB, Mölndal, Sweden) with acrylic resin teeth; the remaining 23 prostheses were porcelain-cemented restorations with a cast mesiostructure connecting all the implants on each side.

The outcome measures evaluated for the present study were:

(1) *Prosthesis success*: when the prosthesis could be released as planned and its

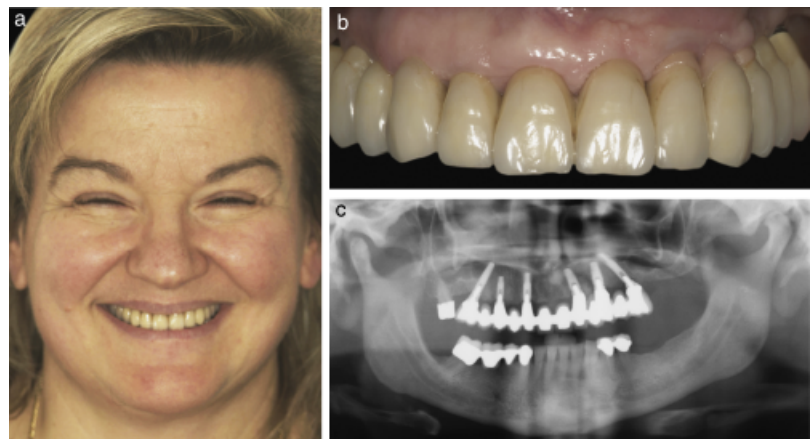


Fig. 3. (a) Extraoral frontal view of the final restoration. (b) Intraoral frontal view of the final full-arch ceramic restoration. (c) Final orthopantomograph with final restoration.

function was maintained without complications, even in case of the loss of one of more implants. Prosthesis was considered as failed whether it was not possible to place it as planned or whether its function was compromised due to implant failure.

(2) *Implant survival that was based on the following criteria* (Albrektsson et al. 1986): no evidence of peri-implant radiolucency; no recurrent or persistent peri-implant infection; no complaint of pain; and no complaint of neuropathies or paresthes-

ia. As an adjunct to the survival criteria, additional criteria for implant success were also imposed. Implants were considered to be successful if the following conditions were met at the time of evaluation, in conjunction with those specified for survival: no crestal bone loss exceeding 1.5 mm by the end of the first year of functional loading, and no bone loss exceeding 0.2 mm/year in the subsequent years.

(3) *Any biological or prosthetic complication: examples of possible biological*

*complications were:* numbness of the lower lip and chin, peri-implant mucositis (heavily inflamed soft tissue in the absence of bone loss), peri-implantitis (bone loss with suppuration or heavily inflamed tissues), fistulas, etc. Examples of possible prosthetic complications were: fracture of the implant, of the abutment screw, of the framework, of the occlusal material, etc.

(4) *Patient's satisfaction:* once the prosthesis was finalized, the patient completed a questionnaire for satisfaction evaluation regarding esthetics, phonetics, ease of maintenance and functional efficiency. The scoring for each subject was: excellent, very good, good, sufficient and poor. The same questionnaire was conducted at the 1-year evaluation.

(5) *Marginal bone-level change:* The radiographic evaluations were performed by means of image analysis software (Scion Image, Scion Corporation, Frederick, MD, USA), as described previously (Testori et al. 2003). All measurements were made by an independent evaluator not involved in the clinical procedures. The statistical comparisons between the test and the control group were also performed by the same independent evaluator.

#### Follow-up

No specific diet was recommended to the patients. The patients were scheduled for follow-up evaluation at 1, 3, 6 and 12 months post-surgery, and then annually up to 5 years. At each follow-up visit, periapical radiographs were taken using a paralleling technique, in order to evaluate peri-implant crestal bone-level changes over time. Data relative to marginal bone loss around tilted and axial implants were considered separately. In each patient, a single value of marginal bone loss was obtained for axial and for tilted implants, by averaging values from all single implants. Therefore, intra-patient variability was not accounted for and the patient was

the statistical unit for the analysis. Peri-implant bone change around axial and tilted implants was compared by means of paired Student's *t*-test. Differences in the proportion of failures at 1 year between the two groups were compared by means of Fisher's exact test. The significance level was considered as  $P = 0.05$ . Kaplan–Meier analysis was also performed to determine the cumulative implant survival rate at the current stage of the study.

#### Results

Between December 2002 and July 2006, a total of 41 patients (15 men, 26 women) were rehabilitated with a full-arch fixed prosthesis supported by both axial and tilted implants, according to an immediate loading protocol. The mean age at surgery was  $59.2 \pm 9.5$  (standard deviation) years (range 38–84 years). Out of 41 patients, 29 (70.7%) lost their teeth due to periodontal disease, two (4.9%) presented with decayed unrestorable teeth and 10 (4.9%) had combined etiology (both periodontal disease and caries). Twelve of the included patients were smokers (nine light smokers of <10 cigarettes/day, and three heavy smokers of about 20 cigarettes/day). Fifteen patients had mild systemic diseases controlled by pharmacological therapy. All patients could be rehabilitated according to the immediate protocol as planned.

One female patient died 4 months after treatment due to a car accident and was omitted from the study.

Table 1 reports some characteristics of the implant failures recorded to date. During the first 12 months, three implants failed in three patients. Two failures occurred in patients who had lost their teeth due to periodontal disease, and one in a patient who had decayed teeth. Two axially positioned implants (positions 13 and 23) failed after 2 and 8 months of function. One tilted implant (position 15) failed after

4 months of loading. All the failed implants were immediately replaced with implants of larger diameter and length without compromising the prosthesis function. The proportion of failures at 12 months of function was the same for tilted and axially positioned implants (1.2%).

The overall cumulative implant survival rate was 97.9% and 97.1% for axially positioned and for tilted implants, respectively, up to 3 years of observation (Table 2). No prosthetic failure occurred, resulting in an overall 100% prosthesis success rate.

Crestal bone loss averaged  $0.9 \pm 0.4$  and  $0.8 \pm 0.5$  mm for axial and tilted implants, respectively, at the 12-month evaluation. No significant difference was recorded in bone-level change between the two groups of implants.

Twenty-eight patients (70%) completed the questionnaire for satisfaction evaluation after 1-year follow-up. For simplicity of reporting, we pooled the 'excellent' and the 'very good' judgments. The main results were as follows: Esthetics (teeth and smile) was judged as excellent or very good by 75% of patients, good by 21.4% of them and sufficient by one patient (3.6%). Mastication function was considered excellent or very good by 69.2% of patients and good by 30.8%. Ease of maintenance was considered excellent or very good in 35.7% of cases, good in 42.9%, sufficient in 14.3% of cases, and poor by 7.1% of patients. Phonetics was judged excellent or very good in 85.7% of cases and sufficient in 14.3%. All patients affirmed that their quality of life had improved after the treatment.

The only prosthetic complication encountered was screw loosening, which occurred in seven provisional prostheses (17.5%), affecting prosthesis stability. The screw loosening occurred on three tilted and four axially placed implants. All screw loosening occurred during the first month of function.

No biological complication was reported.

**Table 1. Characteristics of failed implants**

Patient no./sex	Age at surgery (years)	Time of failure (month of function)	Implant position	Implant diameter (mm)	Implant length (mm)	Bone quality	Smoker ( <i>n</i> cigarettes/day)	Reason for failure
12/F	43.9	18	25 (tilted)	4	15	4	Y (20)	Mobility
21/M	60.5	2	13 (axial)	4	11.5	2	N	Mobility
25/F	56.7	15	13 (axial)	4	15	2	N	Mobility
30/F	49.4	8	23 (axial)	4	11.5	3	Y (<10)	Mobility
33/F	66.3	4	15 (tilted)	4	18	4	N	Mobility and pain

**Table 2.** Life table analysis of IL implants

Time interval (months)	Implants at beginning of interval	Withdrawn implants	Failed implants	Interval survival rate (%)	Cumulative survival rate (%)
<b>Axial implants</b>					
0–6	164	4	1	99.4	99.4
6–12	143	0	1	99.3	98.7
12–18	118	0	1	99.2	97.9
18–24	105	0	0	100	97.9
24–36	84	0	0	100	97.9
> 36	8	0	0	100	97.9
<b>Tilted implants</b>					
0–6	82	2	1	98.8	98.8
6–12	71	0	0	100	98.8
12–18	59	0	1	98.3	97.1
18–24	52	0	0	100	97.1
24–36	42	0	0	100	97.1
> 36	4	0	0	100	97.1

## Discussion

The clinical outcome of this prospective study indicates that the rehabilitation of the completely edentulous maxilla with an immediately loaded full-arch bridge, either screw retained or cement anchored to tilted and axial implants, may have a predictable outcome. Our data compare favorably with data published by Malo et al. (2005) concerning fixed complete-arch immediately loaded maxillary rehabilitations supported by two axial and two tilted implants. Also, immediate loading of tilted implants in the partially edentulous maxilla showed encouraging success rates (Calandriello & Tomatis 2005). However, these data are not comparable to ours because of the different clinical and biomechanics of the prosthesis.

Cumulative implant survival rates of tilted and axial implants to date are similar up to 3 years (Table 2). These data are consistent with other authors (Krekmanov et al. 2000; Aparicio et al. 2001). It could be speculated that tilted implants are placed and anchored with greater cortical bone contact than axial ones. In fact, the tilted implants are placed between the cortical bone of the crest, the mesial wall

of the maxillary sinus and the nasal floor, achieving tricortical anchorage.

Studies *in vitro* analyzing the load distribution of implants connected to angulated abutments discouraged their use; however, it must be pointed out that unfavorable results were reported for single implants (Clelland et al. 1993), and not for multiple implants in which the abutments are connected together (Krekmanov et al. 2000). Furthermore, it must be kept in mind that the external validity of *in vitro* studies can be extremely low due to highly different experimental conditions with respect to the clinical field.

No increase of load transfer to the bone with respect to axial implants was reported *in vivo* for tilted implants splinted to axially positioned implants (Krekmanov et al. 2000).

Furthermore, animal studies have shown that non-axial loading is not detrimental for the osseointegration process (Celletti et al. 1995; Miyata et al. 1998).

In this clinical study, the marginal bone loss was not affected by the tilting of the implants.

The marginal bone resorption for axial and tilted implants showed a normal pattern predicting normal bone response when tilted implants are splinted, similar

to what reported in previous studies (Calandriello & Tomatis 2005).

By tilting the posterior implants, sinus lift procedures can be avoided by reducing the morbidity of the surgical phase. Other clinical advantages include (1) the possibility of placement of longer implants that increases the bone-to-implant contact area and the implants' primary stability and (2) the distance between implants can be increased, reducing the cantilevers and thus optimizing load distribution. The use of fewer implants to support the prosthesis and the application of the immediate loading protocol can reduce the overall treatment costs.

The principle of using four or six implants instead of the maximum possible number of implants for the rehabilitation of fully edentulism is also supported by long-term studies (Brånemark et al. 1995).

## Conclusion

The present preliminary data suggest that immediate loading associated with tilted implants could be considered a viable treatment modality for the atrophic maxilla and that there does not seem to be a different clinical outcome between tilted and axial implants. The use of tilted implants may avoid more complex treatments, reducing the patient's morbidity, treatment time and costs. These results indicate that if the prerequisites for immediate loading such as high primary stability (30 N cm or more), splinting of the implants via a provisional prosthesis and the use of an osteoconductive surface are fulfilled, tilting the implants may not adversely affect the final outcome.

**Acknowledgements:** The authors are grateful to Dr Alan Meltzer and to Prof. Marco Esposito for reviewing the manuscript and to Dr Jorg M. Ritzmann for the prosthodontic phase.

## References

- Adell, R., Eriksson, B., Lekholm, U., Brånemark, P.I. & Jemt, T. (1990) Long-term follow-up study of osseointegrated implants in the treatment of totally edentulous jaws. *International Journal of Oral & Maxillofacial Implants* 5: 347–359.
- Albrektsson, T., Zarb, G., Worthington, P. & Eriksson, A.R. (1986) The long-term efficacy of currently used dental implants: a review and proposed criteria of success. *The International Journal of Oral & Maxillofacial Implants* 1: 11–25.
- Aparicio, C., Arevalo, X., Ouzzani, W. & Granados, C. (2002) A retrospective clinical and radiographic evaluation of tilted implants used in the treatment of the severely resorbed edentulous maxilla. *Applied Osseointegration Research* 3: 17–21.

- Aparicio, C., Perales, P. & Rangert, B. (2001) Tilted implants as an alternative to maxillary sinus grafting: a clinical, radiologic, and periotest study. *Clinical Implant Dentistry & Related Research* 3: 39–49.
- Bahat, O. (1992) Osseointegrated implants in the maxillary tuberosity: report on 45 consecutive patients. *The International Journal of Oral & Maxillofacial Implants* 7: 459–467.
- Balshi, T.J., Wolfinger, G.J. & Balshi, S.F. (1999) Analysis of 356 pterygo-maxillary implants in edentulous arches for fixed prosthesis anchorage. *The International Journal of Oral & Maxillofacial Implants* 14: 398–406.
- Brånemark, P.I., Gröndahl, K., Ohmell, L.O., Nilsson, P., Petruson, B., Svensson, B., Engstrand, P. & Nannmark, U. (2004) Zygoma fixture in the management of advanced atrophy of the maxilla: technique and long-term results. *Scandinavian Journal of Plastic and Reconstructive Surgery and Hand Surgery* 38: 70–85.
- Brånemark, P.I., Svensson, B. & van Steenberghe, D. (1995) Ten-year survival rates of fixed prostheses on four or six implants ad modum Brånemark in full edentulism. *Clinical Oral Implants Research* 6: 227–231.
- Calandriello, R. & Tomatis, M. (2005) Simplified treatment of the atrophic posterior maxilla via immediate/early function and tilted implants: a prospective 1-year clinical study. *Clinical Implant Dentistry & Related Research* 7: 1–12.
- Celletti, R., Pameijer, C.H., Bracchetti, G., Donath, D., Persichetti, G. & Visani, I. (1995) Histologic evaluation of osseointegrated implants restored in nonaxial functional occlusion with preangled abutments. *The International Journal of Periodontics and Restorative Dentistry* 15: 563–573.
- Clelland, N.L., Gilat, A., McGlumphy, E.A. & Brantley, W.A. (1993) A photoelastic and strain gauge analysis of angled abutments for an implant system. *The International Journal of Oral & Maxillofacial Implants* 8: 541–548.
- Del Fabbro, M., Testori, T., Francetti, L. & Weinstein, R. (2004) Systematic review of survival rates for implants placed in grafted maxillary sinus. *International Journal of Periodontics & Restorative Dentistry* 24: 565–577.
- Fortin, Y., Sullivan, R.M. & Rangert, B. (2002) The Marius implant bridge: surgical and prosthetic rehabilitation for the completely edentulous upper jaw with moderate to severe resorption: a 5-year retrospective clinical study. *Clinical Implant Dentistry & Related Research* 4: 69–77.
- Goene, R., Bianchesi, C., Huerzeler, M., Del Lupo, R., Testori, T., Davarpanah, M. & Jalbout, Z. (2005) Performance of short implants in partial restorations: 3-year follow-up of Osseotite implants. *Implant Dentistry* 14: 274–280.
- Khayat, P. & Nader, N. (1994) The use of osseointegrated implants in the maxillary tuberosity. *Practical Periodontics and Aesthetic Dentistry* 6: 53–61.
- Krekmanov, L. (2000) Placement of posterior mandibular and maxillary implants in patients with severe bone deficiency: a clinical report of procedure. *International Journal of Oral & Maxillofacial Implants* 15: 722–730.
- Krekmanov, L., Kahn, M., Rangert, B. & Lindström, H. (2000) Tilting of posterior mandibular and maxillary implants for improved prosthesis support. *The International Journal of Oral & Maxillofacial Implants* 15: 405–414.
- Malo, P., Rangert, B. & Nobre, M. (2005) All-on-4 immediate-function concept with Branemark system implants for completely edentulous maxillae: a 1-year retrospective clinical study. *Clinical Implant Dentistry & Related Research* 7 (Suppl. 1): S88–S94.
- Miyata, T., Kobayashi, Y., Araki, H., Motomura, Y. & Shin, K. (1998) The influence of controlled occlusal overload on peri-implant tissue: a histologic study in monkeys. *The International Journal of Oral & Maxillofacial Implants* 13: 677–693.
- Renouard, F. & Nisand, D. (2005) Short implants in the severely resorbed maxilla: a 2-year retrospective clinical study. *Clinical Implant Dentistry & Related Research* 7: 104–110.
- Shackleton, J.L., Carr, L., Slabbert, J.C. & Becker, P.J. (1994) Survival of fixed implant-supported prostheses related to cantilever lengths. *Journal of Prosthetic Dentistry* 71: 23–26.
- Testori, T., Del Fabbro, M., Szmukler-Moncler, S., Francetti, L. & Weinstein, R.L. (2003) Immediate occlusal loading of Osseotite® implants in the totally edentulous mandible. *The International Journal of Oral & Maxillofacial Implants* 18: 544–551.
- Venturelli, A. (1996) A modified surgical protocol for placing implants in the maxillary tuberosity: clinical results at 36 months after loading with fixed partial dentures. *The International Journal of Oral & Maxillofacial Implants* 11: 743–749.
- Wallace, S.S. & Froum, S.J. (2003) Effect of maxillary sinus augmentation on the survival of endosseous dental implants as compared to the survival of implants placed in the non-grafted posterior maxilla: an evidence-based literature review. *Annals of Periodontology* 8: 328–343.