

Acta chir belg, 2004, **104**, 519-526

Early Complications in Endovascular Treatment of Abdominal Aortic Aneurysm

L. Gabrielli, A. Baudo, A. Molinari, M. Domanin

Institute of Vascular Surgery. University of Milan, Via Commenda 12, 20122 Milan, Italy.

Key words. Abdominal aortic aneurysm ; operative complication ; endovascular repair ; stent graft.

Abstract. *Objective :* The incidence of perioperative complications during endovascular repair of abdominal aortic aneurysm (EVAR) is reported in limited series. The aim of this study is to evaluate a multi-center survey of unexpected intraprocedural critical events of EVAR.

Methods : A questionnaire relative to intraprocedural complications during EVAR was sent to major vascular surgery divisions in Italy. Eleven answered to the survey. The data obtained are relative to 1696 procedures.

Results : A wide range of incidence of critical events was observed, from a lower value of 2.7% to a higher value of 68.8% (mean 21.16%). The problems relative to the insertion phase of the delivery system were 7.7%. Endoleaks were reported in 5.5% of cases. Stent graft release was problematic in 0.4% of cases and in another 0.4% there was a problem in shaft retrieval. Unintentional coverage of renal or polar arteries occurred in 0.8% of the procedures ; hypogastric arteries were unwillingly excluded in 2.7% of cases.

Aortic or iliac artery rupture had an incidence of 0.7% ; arterial dissection occurred in 0.9%, atheroembolism in 0.5%, lower limb ischemia due to graft limb kinks in 0.7% and to occlusion in 0.9%.

Conclusions : Perioperative critical events represent a serious problem only in few cases of EVAR ; they are common but in many cases not predictable ; in most circumstances they can be easily corrected with adjunctive manoeuvres during the same procedure. There is a highly significant correlation between the total workload and the incidence of critical events ; these do not appear to be related to the learning curve.

Open surgical treatment of infrarenal abdominal aortic aneurysms (AAA) is effective and has a low morbidity and mortality rate in the middle-term and in the long-term period (1-4). On the contrary perioperative risk is high, with a range in mortality from 5 to 10%, and some high-risk patients are excluded from treatment (5-8).

From the first report in 1991 (9), endovascular treatment of AAA (EVAR) has gained a progressively wider acceptance and now is considered a consistent alternative to open surgery.

In spite of satisfactory medium-term results (9-15), recent studies have revealed some limits inherent to the procedure. The problems are related to the safety and integrity of the devices, the disconnection of its components, the graft migration and infection, the obstruction of iliac limbs and to aneurysm sac expansion in presence, in the majority of cases, of sac reperfusion (endoleaks) (16,-18). Sometimes such complications require the explantation of the endografts and the open treatment of AAA (conversion).

Effectiveness of EVAR in the long-term has to be proven and studies are underway ; some doubts remain if the procedure is indicated in young patients and in low-risk patients (18).

Little research was involved in defining the incidence of intraprocedural failures and complications, and of all

the adverse events that can occur during or immediately after the procedure (within 30 days) (19, 20, 21). These events can be considered critical for the success of the procedure ; if they are not adequately corrected there is a high risk of failure. Such a correction is frequently a routine complement of stent-graft implantation so that critical events are evaluated as a predictable part of EVAR whose diagnosis and treatment is easy and immediately performed. However, in many cases these events are not recorded unless they have serious or permanent clinical consequences.

In this paper we analyse intraprocedural critical events in EVAR in a large series of procedures. According to other authors (19) we consider critical events to be all the problems and technical difficulties that fit the following criteria : they occur during the procedure or within the first 30 days, they are neither predictable nor foreseen, they compromise the success of the procedure and they require an adjunctive treatment, normally not performed during the procedure, which may be endovascular or open.

Methods

A questionnaire to collect data relative to critical events in EVAR was sent to many divisions of vascular surgery

in Italy; eleven answered and data were recorded in a worksheet. In the Appendix there is the list of the divisions and of the Authors that contributed to the survey. The questionnaire regarded:

- the total number of EVAR
- the unexpected difficulties in graft insertion due to small arteries, arterial stenosis, calcification or tortuosity,
- the graft misplacement, with consequent endoleaks of type IA (from the proximal attachment site), type IB (from the distal attachment site) or type III (defect in connecting the segments of the modular stent-graft),
- the problems during the stent-graft delivery or the shaft withdrawal (e.g. notch trapping in stent or twist of slide guides),
- the unintentional coverage of renal, polar or hypogastric arteries,
- the limb graft kinks, stenosis or occlusions,
- the distal dissections,
- the aneurysmal or arterial rupture
- the incidence of atheroembolism.

We did not collect data relative to patient characteristics, aneurysm morphology and stent-graft type.

Analysis of the data was performed with a standard spreadsheet with statistical capabilities (Microsoft Excel – Microsoft Co. – Richmond, Va). Correlation of Pearson and its significance was evaluated between the total number of procedures in each division and the number of occurred critical events.

Results

The data collected are relative to 1696 EVAR performed from the beginning of the 1990's to October 2003 in eleven divisions of vascular surgery in Italy and are summarized in Table I.

The experience of single institutions varied from 28 to 520 EVAR and the incidence of critical events had a wide range, from a lower value of 2.7% to a higher value of 68.8% (mean 21.16%).

A correlation was observed between the workload of each center and its incidence of critical events (Fig. 1). Pearson correlation coefficient (r) was 0.796; for 9 degrees of freedom it has the highly significant t value of 3.94 ($p < 0.01$).

The mean value of critical events was 21.16% for the whole group, with two significant outliers that reported an incidence of critical events of 47% and 68.8% respectively.

Femoral insertion of the stent-graft revealed an unexpected incidence of difficulties due to small external iliac arteries (commonly less than 7 mm in diameter), stenosis, heavy calcifications and tortuosity for a cumulative value of 7.62% of cases.

Persistence of perfusion of the aneurysmal sac after deployment of the stent-graft was observed in 5.54% of cases; in the majority of cases it was an endoleak of type I, equally shared among types IA and IB. All cases were corrected with ballooning and adjunctive cuffs. Endoleaks type III, secondary to incomplete sealing of modular parts of the stent-graft or to their detachment, occurred in 1.0% of cases.

Critical events related to the device include problems during the stent-graft delivery and the delivery system retrieval. Delivery was impossible in 0.41% of cases for the presence of marked proximal aortic neck or distal iliac arteries angulation or for a fabric defect of the delivery system. The same figure is reported for difficult delivery system retrieval; the most frequent causes were the entrapment of the tip of the delivery system (notch) within the struts of the deployed stent-graft or, in a single type of stent-graft, the probable torsion of sliding guides.

We reported a coverage of visceral arteries in 3.5% of cases; renal arteries were covered unintentionally in 0.5% of cases, polar arteries in 0.3% and hypogastric arteries in 2.7%. Suprarenal deployment of the stent-graft was corrected when possible with a downward traction by means of a balloon inflated in the main body of the stent graft or by means of a guidewire crossing the graft bifurcation from one femoral artery to the other. In three cases the manoeuvre did not succeed; and one nephrectomy and two spleno-renal bypass grafts ensued.

Arterial rupture is the most feared critical event since it is life-threatening. Aortic rupture occurred in 0.17% of procedures and iliac ruptures in 0.53%; these cases were typical of the beginning of the learning curve. Most cases were treated with open conversion whereas some iliac ruptures were corrected with covered stents.

Lower limbs ischemic complications are rare in EVAR procedures and in most cases are due to graft limb kinks and twisting, extrinsic compression by calcified plaques in iliac arteries or an aortic bifurcation with a small lumen, less than 18 mm. We observed 1.59% of cases with such complications that could be treated with ballooning or stenting of the graft limb, thrombectomy or thrombolysis in case of occlusion. The same treatment was reserved to dissections with lower limb ischemia that occurred in 0.9% of cases. Atheroembolism to hypogastric region and to lower limbs was reported in 0.47% of cases and had a long painful course.

Discussion

The aim of this study is to define the incidence of the intraoperative critical events during EVAR and to discuss the adjunctive procedures for their resolution.

Table I
Distribution of intraprocedural critical events in AAA EVGR in 11 departments of vascular surgery in Italy

Center n.	n. evgr	S A	ST	C	T	EL1A	EL1B	EL3	SG D	DSR	Ra C	Pa C	Hya C	K&S	D AAA R	Art R	ATE	GLO	TCE	%	
1	520	16				17	21	5	2		4	2	24		4	1	2	2	8	108	20.77
2	109	1	4			1		1												7	6.42
3	121	2						1		4		1	1	1	4		1			16	13.22
4	74	1																		2	2.70
5	125	20	5	6	37	1	1	1		2	1	1	3	5	2					86	68.80
6	250		5	5	13	2	13	2	2		2			6	6					58	23.20
7	45		1			1			1				1				1			5	11.11
8	28								1	1										3	10.71
9	51	1	2		2	6	3						1			2			7	24	47.06
1	173			2		11		1	1			1	1							18	10.40
11	200		6					6			1		15				4			32	16.00
Total	1696	41	23	13	52	39	38	17	7	7	8	5	46	12	16	3	9	8	15	359	
Percent		2.4	1.35	0.77	3.1	2.3	2.24	1.0	0.41	0.41	0.47	0.30	2.71	0.71	0.94	0.17	0.53	0.47	0.88	21.16	

Legend : S A = Small Arteries, ST = Stenosis, C = Calcifications, T = Tortuosity, SG D = Stent-Graft Delivery, DS R = Delivery System Retrieval, Ra C = Renal arteries coverage, Pa C = Polar arteries coverage, Hya C = Hypogastric arteries coverage, K&S = Kinking and Stenosis, D = Dissection, AAA R = AAA Rupture, Art R = Artery rupture, ATE = Atheroembolism, GLO = Graft Limb Occlusion, TCE = Total of Critical Events.

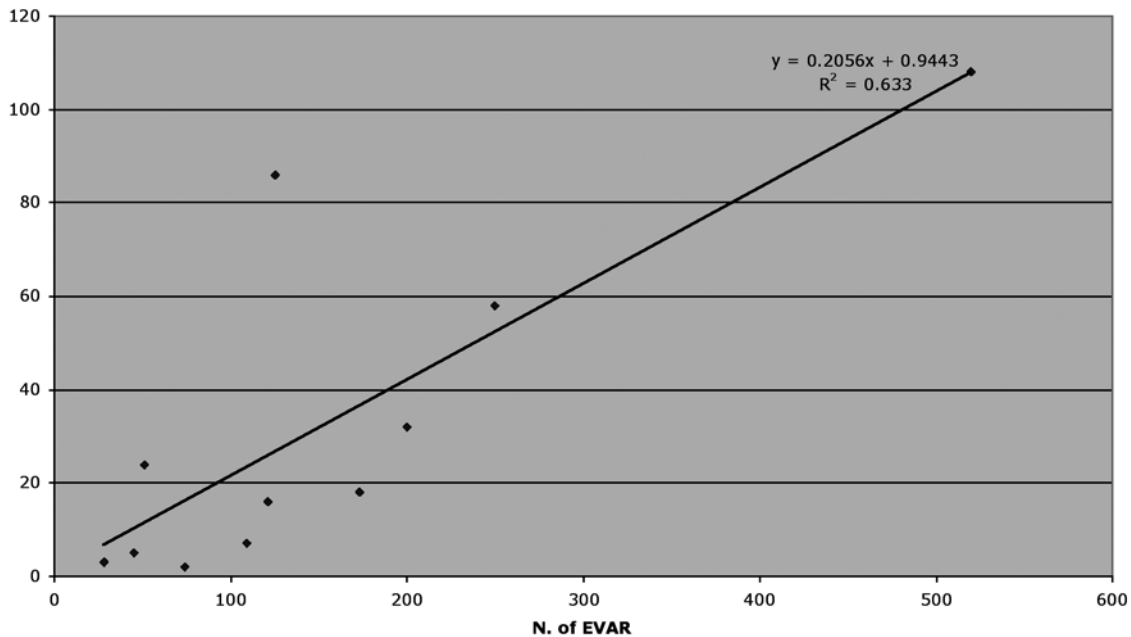


Fig. 1

Correlation between number of performed procedures (EVAR) and of critical events which occurred during individual experience in eleven divisions of vascular surgery. There is a correlation with total workload and not with the learning curve.

NASLUND (20) reported technical complications in 26% out of 34 endovascular repairs for AAA, BUTH *et al.* (21), who reported collaborative data from the EUROSTAR registry, have shown open conversion in 2.5% of the cases, device-related or procedure-related complications in 10%, and arterial complications in 3%.

FAIRMAN *et al.* (19) on the contrary reported an incidence of adverse events or the need of an adjunctive procedure in 89% of their cases.

We had a minimum of 2.7% of recorded critical events to a maximum of 68.8%, with a mean of 21.16%. This value is consistent with those of other Authors but in our multicenter survey we observed significant outlayered individual values in almost three centers: one extremely low to 2.7% and other two abnormally high (47% and 68.8%). If these outlayered values could have been excluded, we would have had a near perfect regression line with a Pearson "r" value of 0.98.

The wide range of reported critical events may be due to two important factors: the learning curve and the accuracy to keep track of the procedure. Many Authors in fact don't record the intraoperative critical events that can be treated easily during the same procedure.

According to some Authors the learning curve for EVAR has a great importance. LEE *et al.* (22) in their experience concluded that the learning curve is important for the reduction of the perioperative complications, but doesn't influence the technical success of the procedure. LOBATO *et al.* (23) have shown that 55 endovascu-

lar aneurysm repairs were necessary to achieve optimal results; and that the interval between the procedures was also important, with one case every 10 days being the minimal workload to achieve these success rates. FORBES *et al.* (24) in their analysis suggested that 60 elective endovascular repairs, or 20 with a specific device, are required to obtain optimal initial clinical success.

During the relatively brief history of endovascular aneurysm repair, it has become clear that endograft device design is a vital contributor to successful aneurysm exclusion (25). The initial use of aorto-aortic tube endograft determined early failure of EVAR for distal aortic attachment site complications and device migrations (24). Nevertheless MAY *et al.* (11) in their experience concluded that there are risks inherent in the endograft method rather than iatrogenic complications that occur as a learning curve phenomenon: new devices have modified the type of the adverse events but not their incidence. Our collective data confirm this opinion since we observed a straight correlation between the number of EVAR and the incidence of critical events. Apparently these events are not clustered in the initial phase of the learning curve as can be deduced by the two low-volume centers that had an incidence of 11%.

In any case a careful selection of patients based on morphologic standards for this endovascular procedure is the requirement for the prevention of adverse events (26).

The identification of risk factors for intraoperative complications is not yet clear. According to SHAMES (27) gender is important in the incidence of perioperative complications; he observed that women treated with AneuRx graft experienced more technical complications (17% versus 8.3%). At 30 days, systemic morbidity was significantly higher in women (26% versus 5.3%). CARPENTER *et al.* (28) have shown that women had higher incidence of secondary procedure and less eligibility to EVAR for anatomical reasons (small arteries, short, wide and angulated aortic neck) than their male counterparts.

Retroperitoneal approach is associated with an increased risk for perioperative complications. LEE *et al.* (29) reported that this approach enabled an additional 14% of patients with AAA to undergo endovascular techniques, but on the other hand it's related to a 1.8-fold higher rate of perioperative complications, compared with endovascular AAA repair with femoral exposure alone.

According to FAIRMAN (19), the overwhelming majority of the adverse events are access related. The incidence of these problems in our study is 7.7%. Insertion of the device via femoral route has an incidence of unexpected difficulties: small arteries, stenosis, kinking and calcification can hinder in the progression of the graft's delivery system. Access issues will remain a problem for this technology until the profile of the delivery systems is significantly reduced (19, 30). Access related problems can be worked out with a PTA of the stenotic vessel, a brachial-femoral guidewire path as suggested by CRIADO (30), a retroperitoneal approach to iliac arteries or a conversion to open surgery.

The incidence of perioperative endoleaks is uncertain because they are often solved in the operating room with relatively simple procedures and surgeons do not keep track of them (31). In any case the clinical importance of this adverse event remains unclear and poorly understood (32, 33, 34). Several studies have shown poor correlation between endoleak and outcome and many Authors believe that the most common variety of endoleak (type II: retrograde branch leak), rarely causes clinical consequences (35-37). We did not consider endoleaks type II as critical events since we believe that they do not deserve any treatment for at least 3 months, unless the aneurysm grows in that period. On the contrary, endoleaks type I and type III are well recognized as more hazardous for AAA enlargement and rupture risk, and for this reason they always need a treatment (18, 38). In literature almost all the endoleaks of type IV subsided spontaneously during the 30 days follow-up: their intraoperative observation requires excluding the association with an endoleak type I. In this case the filling of the sac is more rapid (31). These benign type IV endoleaks are not considered in our

study. ZARINS *et al.* (39) reported a 21% endoleak rate after discharge, which decreased to 9% at 1 month. WHITE *et al.* (40) presented an incidence of 24% of intraoperative endoleak type I. CRIADO *et al.* (30) had a rate of 14% for endoleak type I and II. ESPINOSA *et al.* (41) revealed an incidence of endoleak type I of 2.3%. BECQUEMIN *et al.* (42) demonstrated a 23.3% rate of early endoleaks.

For endoleaks type I we had a mean incidence of 5.5%, and for type III of 1%.

The diagnosis of endoleak type is made intraoperatively with selective angiographic runs, whereas IVUS was used in rare instances, but was not resolving and very expansive (42). In the postoperative period CT scan, with late runs, and colour echoDoppler, with second generation echocontrast and settings in the second harmonic with low mechanical index, are the best tools (43-49).

The treatment of endoleak type I is carried out with ballooning of the landing zone of the graft or coil embolization (10, 17). Extension cuffs are used in the great majority of the cases 31; on the contrary coil embolization is used in rare cases (50-52).

In rare cases aneurysms with type II endoleaks grow within the first month; treatment may be with coil embolization, thrombin or glue injection, laparoscopic retroperitoneal clipping and, in case of failure, conversion to open surgery (10, 53-55). Another treatment recently proposed for this type II endoleak is "saccotomy", which consists in the transperitoneal opening of the aneurysmal sac and direct lumbar ostia suture (56).

Type III endoleak may be due to unfitted overlapping of modular components of the endografts and can be treated with ballooning or with an intermediate cuff (31, 57). Conversion to open surgery is the last choice.

Device-related clinical events include problems with deployment of the graft or problems with withdrawal of the delivery system. The first may depend on a marked angulation of the aortic neck or of the iliac arteries or engineering failures of the device/delivery systems themselves. The graft cannot be released at all from the deployment system or difficulty in release brings about an inaccurate fixation of the graft. The solution is an adjunctive endograft if possible or conversion to open surgery. Withdrawal of the delivery system was difficult or impossible in 0.7% of cases in our collective experience. Proximal notch entrapment in the struts of the graft and sliding guides twisting were the most common occurrences. These events are often related to graft type and predictable (19). Every type of graft has his own tricks to resolve these situations but sometimes conversion is unavoidable.

Inadvertent suprarenal deployment can be successfully treated by balloon traction at the proximal attachment site of the endoprosthesis or by pulling down the endograft using a stiff guide wire over the graft

bifurcation (19, 58, 59). In case of failure conversion to open surgery is the only possible solution.

Accessory renal arteries can be covered with the graft if they are less than 3 mm in diameter, supply less than 25% of renal parenchyma, do not represent a possible cause of endoleak and the serum creatinine is normal (26). Intentional coverage of polar arteries is not a critical event; in this conditions an insignificant renal ischaemia (< 20% renal parenchyma) at worst can develop in absence of renal insufficiency (60).

Covering of renal or polar arteries is reported in 0.8% of cases in our collective experience. LIEWALD (61) reported an incidence of 3% in 130 EVAR.

Unintentional covering of hypogastric arteries can occur in case of distal migration of the graft during retraction of the delivery system or in case of overestimated length measurement from the renal artery orifice to the hypogastric orifice (62). In the first case it's possible to pull up the graft by using a pig tail catheter.

Sacrifice of the hypogastric artery is rarely associated with colon ischemia, hip and buttock claudication, impotence, paraplegia and pelvic necrosis (62). Hip and buttock claudication is the most common outcome related to hypogastric occlusion, with an incidence from 1.6% to 33% and with an excellent prognosis with medical therapy (54). These events are not experienced by patients with a unilateral occlusion. Hypogastric reimplantation or bypass graft is recommended if intestinal or gluteal ischemia is feared (63).

Life-threatening artery rupture is the most feared complication of EVAR and needs a conversion to open surgery. Aortic rupture occurred in 0.2% of cases in our study, in particular at the beginning of the experience: in one case it was due to the overzealous ballooning of a Parodi endoprosthesis aortic neck.

Iliac artery rupture occurred in 0.5% of cases: it can be successfully treated by covered distal extensions but open surgery sometimes is the only solution. Our results are similar to those in literature (19, 24).

Ischemic complications of lower limbs are also rare and may be due to kinks of graft limbs, particularly in non stented grafts, and stenosis from extrinsic compression by arterial plaque or small aortic bifurcation (less than 18 mm). FAIRMAN (19) reported 12% of this critical event (only in Ancure endografts); the treatment was a successful angioplasty and eventually a stenting of the kinked zone.

Acute limb ischemia is reported in 4-6.5% of cases (19, 58). In these cases some Authors prefer thrombolysis to thrombectomy (64).

Acute limb ischemia due to arterial dissection is more difficult to diagnose intraoperatively. It has been shown that IVUS is more useful than angiography for prompt diagnosis (43).

Atheroembolism is another adverse event of endovascular procedures, but has also been observed during open surgery. In lower limbs causes illness for many weeks. Treatment options include prostanoids, pentoxifyllin, local treatment with papaverin ointment and analgesics. It's a feared complication when it involves kidneys, small intestine and colon.

In conclusion, perioperative critical events during EVAR only in rare cases represent a serious problem. They are common but in many cases not predictable; in most circumstances they can be easily corrected with adjunctive manoeuvres during the same procedure. In medical reports they are generally underestimated for the low clinical impact but the analysis of adjunctive costs for their resolution probably leads to different consideration.

There is a highly significant correlation between the total workload and the incidence of critical events; these do not appear to be related to the learning curve. It is relevant that future evolution of preoperative evaluation of patients and of EVAR devices could lower the incidence of unexpected intraoperative complications.

Appendix

Divisions of Vascular Surgery participating to the survey:

Institute of Vascular Surgery – University of Milan (L. Gabrielli, A. Baudo, M. Domanin, A. Molinari)
Center “E. Malan” – S. Donato. - University of Milan (GD Tealdi, G. Nano)

Institute of Vascular Surgery. – University of Roma Tor Vergata (GR Pistolese, A Ippoliti)

Division of Vascular Surgery – IDI Hospital – Roma (F. Serino)

Division of Vascular Surgery – University of Insubria – Varese (P. Castelli)

Division of Vascular Surgery – Monteluca Hospital – Perugia (P. G. Cao, F. Verzini)

Division of Vascular Surgery – Cisanello Hospital – Pisa (M. Ferrari)

Division of Vascular Surgery – A. Manzoni Hospital – Lecco (G. Lorenzi, S. Ferrari)

Division of Vascular Surgery – CA Pizzardi Hospital – Bologna (L. Pedrini)

Division of Vascular Surgery – Ospedali Riuniti – Bergamo (M. Setti)

Division of Vascular Surgery – Ospedale di Circolo – Busto Arsizio (A. Tori, E. Costantini)

References

1. ERNST C. B. Abdominal aortic aneurysms. *N Engl J Med*, 1993, **328**: 1167-72.
2. JOHNSON K. W., CANADIAN SOCIETY FOR VASCULAR SURGERY ANEURYSM STUDY GROUP. Nonruptured abdominal aortic aneurysm: six-year follow-up results from the multicenter

- prospective Canadian aneurysm study. *J Vasc Surg*, 1994, **20**: 163-70.
3. CRAWFORD E. S., SALEH S. A., BABB J. K. III, GLAISER D. H., VACCARO P. S., SILVER A. Infrarenal AAA: factors influencing survival after operations performed over 25 year period. *Ann Surg*, 1981, **193**: 699.
 4. HALLETT J. W., MARSHALL D. M., PETTERSON T. M. *et al.* Graft related complications after abdominal aortic aneurysm repair: reassurance from a 36 year population based experience. *J Vasc Surg*, 1997, **25**: 277-86.
 5. KATZ D. J., STANLEY J. C., ZELANOCK G. B. Operative mortality rate for intact and ruptured abdominal aortic aneurysm in Michigan: an eleven-year statewide experience. *J Vasc Surg*, 1994, **19**: 804-17.
 6. KAZMERS A., JACOBS L., PERKINS A., LINDENAUER S. M., BATES E. Abdominal aortic aneurysm repair in Veterans Affairs medical centers. *J Vasc Surg*, 1996, **23**: 191-200.
 7. THE UK SMALL ANEURYSM TRIAL PARTICIPANTS. Mortality results for randomized controlled trial of early elective surgery or ultrasonographic surveillance for small abdominal aortic aneurysm. *Lancet*, 1998, **352**: 1649-55.
 8. LAWRENCE P. F., GOZAK C., BHIRANGI L. *et al.* The epidemiology of surgically repaired aneurysms in the United States. *J Vasc Surg*, 1999, **30**: 632-40.
 9. PARODI J. C., PALMAZ J. C., BARONE H. D. Transfemoral intraluminal graft implantation for abdominal aortic aneurysm. *Ann Vasc Surg*, 1991, **5**: 491-9.
 10. PFAMMATTER T., LACHAT M. L., KUNZLI A. *et al.* Short-term results of endovascular AAA repair with Excluder bifurcated stent-graft. *J Endovasc Ther*, 2002, **9**: 474-80.
 11. BLUM U., VOSHAGE G., LAMMER J. *et al.* Endoluminal stent-grafts for infrarenal abdominal aortic aneurysms. *N Engl J Med*, 1997, **336**: 13-20.
 12. GREENBERG R. K., LAWRENCE-BROWN M., BHANDARI G. *et al.* An update of the Zenith endovascular graft for abdominal aortic aneurysms: initial implantation and mid-term follow-up data. *J Vasc Surg*, 2001, **33** (suppl): S157-64.
 13. BREWSTER D. C., GELLER S. C., KAUFMAN J. A. *et al.* Initial experience with endovascular aneurysm repair: comparison of early results with outcome of conventional open repair. *J Vasc Surg*, 1998, **27**: 992-1005.
 14. BECQUEMIN J., BOURRIEZ A., D'AUDIFFRET A. *et al.* Mid-term results of endovascular versus open repair for abdominal aortic aneurysm in patients anatomically suitable for endovascular repair. *Eur J Vasc Endovasc Surg*, 2000, **19**: 656-61.
 15. HOLZENBEIN T. J., KRETSCHNER G., THURNHER S. *et al.* Mid-term durability of abdominal aortic aneurysm endograft repair: a word of caution. *J Vasc Surg*, 2001, **33**: S46-54.
 16. TERRAMANI T. T., NAJIBI S., BRINKMAN W. T., CHAIKOF E. L. Complications associated with endovascular repair of abdominal aortic aneurysms. *Adv Vasc Surg*, 2002, **10**: 109-16.
 17. TERRAMANI T. T., CHAIKOF E. L., RAYAN S. S. *et al.* Secondary conversion due to failed endovascular abdominal aortic aneurysm repair. *J Vasc Surg*, 2003, **38**: 473-8.
 18. DATILLO J. B., BREWSTER D. C., FAN C. M. *et al.* Clinical features of endovascular abdominal aortic aneurysm repair: incidence, causes, and management.
 19. FAIRMAN R. M., VELAZQUEZ O., BAUM R. *et al.* Endovascular repair of aortic aneurysms: critical events and adjunctive procedures. *J Vasc Surg*, 2001, **33** (6): 1226-32.
 20. NASLUND T. C., EDWARDS W. H. JR, NEUZIL D. F. *et al.* Technical complications of endovascular abdominal aortic aneurysm repair. *J Vasc Surg*, 1997, **26**: 502-10.
 21. BUTH J., LAHEIJ R. J. F., and EUROSTAR collaborators. Early complications and endoleaks after endovascular abdominal aortic aneurysm repair: report of a multicenter study. *J Vasc Surg*, 2000, **31**: 134-46.
 22. LEE W. A., WOLF Y. G., HILL B. B., CIPRIANO P., FOGARTY T. J., ZARINS C. K. The first 150 endovascular AAA repairs at a single institution: how steep is the learning curve? *J Endovasc Ther*, 2002, **9**: 269-276.
 23. LOBATO A. C., RODRIGUEZ-LOPEZ J., DIETRICH E. B. Learning curve for endovascular abdominal aortic aneurysm repair: evaluation of a 277-patient single-centre experience. *J Endovasc Ther*, 2002, **9**: 262-268.
 24. FORBES T. L., DEROSE G., KRIBBS S. W., HARRIS K. A. Cumulative sum failure analysis of the learning curve with endovascular abdominal aortic aneurysm repair. *J Vasc Surg*, 2004, **39**: 102-108.
 25. RESCH T., MALINA M., LINDBLAD B., IVANCEV K. The impact of stent-graft development on outcome of AAA repair-a 7-year experience. *Eur J Vasc Endovasc Surg*, 2001, **22**: 57-61.
 26. STANCANELLI V. Trattamento endovascolare degli aneurismi dell'aorta addominale sottorenale. In: BENEDETTI-VALENTINI F. (eds.). *Chirurgia Vascolare*. Torino: Edizioni Minerva Medica, 2001: 246-252.
 27. SHAMES M. L., SANCHEZ L. A., RUBIN B. G. *et al.* Delayed complications after endovascular AAA repair in women. *J Endovasc Ther*, 2003, **10** (1): 10-5.
 28. CARPENTER J. P., BAUM R. A., BARKER C. F. *et al.* Durability of benefits of endovascular versus conventional abdominal aortic aneurysm repair. *J Vasc Surg*, 2002, **35**: 222-8.
 29. LEE W. A., BERCELI S. A., HUBER T. S., OZAKI C. K., FLYNN T. C., SEEGER J. M. Morbidity with retroperitoneal procedures during endovascular abdominal aortic aneurysm repair. *J Vasc Surg*, 2003, **38**: 459-463.
 30. CRIADO F. J., FAIRMAN R. M., BECKER G. J. Investigators of Talent LPS Pivotal Clinical Trial. Talent LPS AAA stent graft: results of a pivotal clinical trial. *J Vasc Surg*, 2003, **37**: 709-15.
 31. CHAUFOUR X., MAY J., WHITE G. *et al.* Chirurgia endovascolare degli aneurismi. In: *Tecniche Chirurgiche. Chirurgia Vascolare. Enciclopedia Medico Chirurgica, 15° numero*, Ed. Scientifiche et Medicales Elsevier, 43155B: 1-26.
 32. MATSUMURA J. S., MOORE W. S., for Endovascular Technologies Investigators. Clinical consequence of periprosthetic leak after endovascular repair of abdominal aortic aneurysm. *J Vasc Surg*, 1998, **27**: 606-13.
 33. MAKAROUN M., ZAJCO A., SUGIMOTO H., ESKARDARE M., WEBSTER M. Fate of endoleaks after endoluminal repair of abdominal aortic aneurysm with the EVT device. *Eur J Vasc Endovasc Surg*, 1999, **18**: 185-90.
 34. CHUTER T.A.M., FARUQI R.M., SAWHNEY R. *et al.* Endoleak after endovascular repair of abdominal aortic aneurysm. *J Vasc Surg*, 2001, **34**: 98-105.
 35. ZARINS C. K., WHITE R. A., HODGSON K. J., SCHWARTEN D., FOGARTY T. J. Endoleak as a predictor of outcome after endovascular aneurysm repair: AneuRx multicenter clinical trial. *J Vasc Surg*, 2000, **32**: 90-107.
 36. RESCH T., IVANCEV K., LINDH M. *et al.* Persistent collateral perfusion of the abdominal aneurysm after endovascular repair does not lead to progressive change in aneurysm diameter. *J Vasc Surg*, 1998, **28**: 242-9.
 37. GILLING-SMITH G. L., MARTIN J., SUDHINDRAN S. *et al.* Freedom from endoleak after endovascular aneurysm repair does not equal treatment success. *Eur J Vasc Endovasc Surg*, 2000, **19**: 621-5.
 38. VALLABHANENI S. R., HARRIS P. L. Lessons learnt from the EUROSTAR registry on endovascular repair of abdominal aortic aneurysm repair. *Eur J Rad*, 2001, **39**: 34-41.
 39. ZARINS C. K., WHITE R. A., SCHWARTEN D. *et al.* AneuRx stent graft versus open surgical repair of abdominal aortic aneurysms: multicenter prospective clinical trial. *J Vasc Surg*, 1999, **29**: 292-305.
 40. WHITE G.H., MAY J., WAUGH R., UY W. Type 1 and type 2 endoleaks: a more useful classification for reporting results of endoluminal AAA repair (letter). *J Endovasc Surg*, 1998, **5**: 189-93.
 41. ESPINOSA G., MARCHIORI E., SILVA L. F., DE ARAUJO A. P., RIGUETTI C., BAQUERO R. A. Initial results of endovascular repair of abdominal aortic aneurysms with a self-expanding stent-graft. *J Vasc Interv Rad*, 2002, **13** (11): 1115-23.
 42. MOLINARI A., CRIPPA M., DOMANIN M., GABRIELLI L. L'ultrasonografia intravascolare nel monitoraggio intraoperatorio del posizionamento di endoprotesi per aneurisma dell'aorta addominale e dell'arteria iliaca. In: PEDRINI L. (eds.). *Il monitoraggio in chirurgia vascolare*. Bologna: Labanti & Nanni, 2000: 353-364.

43. McWILLIAMS R.G., MARTIN J., WHITE D. *et al.* Use of contrast-enhanced ultrasound in follow-up after endovascular aortic aneurysm repair. *J Vasc Interv Rad*, 1999, **10** : 1107-14.
44. HEILBERGER P., SCHUNN C., RITTER W., WEBER S., RAITHEL D. Postoperative color flow duplex scanning in aortic endografting. *J Endovasc Surg*, 1997, **4** (3) : 262-71.
45. GOLZARIAN J., MURGO S., DUSSAUSOIS L. *et al.* Evaluation of abdominal aortic aneurysm after endoluminal treatment : comparison of color Doppler sonography with biphasic helical CT. *AJR*, 2002, **178** (3) : 623-8.
46. MAY J., WHITE G., YU W., WAUGH R. C., STEPHEN M. S., HARRIS J. P. A prospective study of changes in morphology and dimension of AAA following endoluminal repair : a preliminary report. *J Endovasc Surg*, 1995, **2** (4) : 343-471.
47. GIANNONI M. F., SBARIGIA E., PANICO M. A., ROSSI A., CAPOCCIA L. Ultrasonografia vascolare con amplificatore di segnale di I e II generazione nel controllo a distanza delle endoprotesi vascolari : nostra esperienza. In : PRATESI C., PULLI R. (eds.). *Aneurismi dell'aorta addominale*. Torino : Edizioni Minerva Medica, 2003 : 517-523.
48. CALLIADA F., CAMPANI R., BOTTINELLI O., BOZZINI A., SOMMARUGA M. G. ultrasound contrast agents : basic principles. *Eur J Radiol*, 1998, **27** : S157-60.
49. WOJCIK G., MOULD J., AYTER S., CARCIONE L. A study of second harmonic generation by focused medical transducer pulses. *IEEE Ultrasonic Symposium Proceedings* 1998, 1-6.
50. KATO N., SEMBA C. P., DAKE M. D. Embolization of perigraft leaks after endovascular stent-graft treatment of aortic aneurysms. *J Vasc Interv Radiol*, 1996, **7** : 813-817.
51. MARTY B., SANCHEZ L. A., OHKI T. *et al.* Endoleak after endovascular graft repair of experimental aortic aneurysms : does coil embolization with angiographic "seal" lower intraneurysmal pressure ? *J Vasc Surg*, 1998, **27** : 454-462.
52. KIRBY L., GOODWIN J. Treatment of a primary type I A endoleak with a liquid embolic system under conditions of aortic occlusion. *J Vasc Surg*, 2003, **37** (2) : 456-460.
53. GOLZARIAN J., STRUYVEN J., ABADA H. T. *et al.* Endovascular aortic stent-grafts : transcatheter embolization of persistent perigraft leaks. *Radiology*, 1997, **202** : 731-734.
54. GORICH J., RILINGER N., SOLDNER J. *et al.* Endovascular repair of aortic aneurysms : treatment of complications. *J Endovasc Surg*, 1999, **6** : 136-146.
55. WISSELINK W., CUESTA M. A., BERENDS F. J., VAN DEN BERG F. G., RAUWERDA J. A. Retroperitoneal endoscopic ligation of lumbar and inferior mesenteric arteries as a treatment of persistent endoleak after endoluminal aortic aneurysm repair. *J Vasc Surg*, 2000, **31** : 1240-4.
56. HINCHLIFFE R. J., SINGH-RANGER R., WHITAKER S. C., HOPKINSON B. R. Type II endoleak : transperitoneal sacotomy and ligation of side branch endoleaks responsible for aneurysm sac expansion. *J Endovasc Ther*, 2002, **9** : 539-42.
57. STELTER W., UMSCHIED T., ZIEGLER P. Three-year experience with modular stent-graft devices for endovascular AAA treatment. *J Endovasc Surg*, 1997, **4** : 362-369.
58. HOVSEPIAN D. M., HEIN A. N., PILGRAM T. K. *et al.* Endovascular abdominal aortic aneurysm repair in 144 patients : correlation of aneurysm size, proximal aortic neck length, and procedure-related complications. *J Vasc Interv Radiol*, 2001, **12** : 1373-1382.
59. RUCKERT R., ROMANIUK P., ROGALLA P. *et al.* A method for adjusting a malpositioned bifurcated aortic endograft. *J Endovasc Surg*, 1997, **5** (3) : 261-265.
60. KAPLAN D., KWON C., MARIN M. *et al.* Endovascular repair of abdominal aortic aneurysms in patients with congenital renal vascular anomalies. *J Vasc Surg*, 1999, **30** (3) : 407-416.
61. LIEWALD F., SCHARRER-PAMLER R., GORICH J. *et al.* Intraoperative, perioperative and late complications with endovascular therapy of aortic aneurysm. *Eur J Vasc Endovasc Surg*, 2001, **22** : 251-256.
62. KARCH L. A., HODGSON K. J., MATTOS M. A., BOHANNON W. T., RAMSEY D. E., MCLAFFERTY R. B. Adverse consequences of internal iliac artery occlusion during endovascular repair of abdominal aortic aneurysm. *J Vasc Surg*, 2000, **32** : 676-83.
63. FARIES P. L., MORRISEY N., BURKS J. A. *et al.* Internal iliac artery revascularization as an adjunct to endovascular repair of aortoiliac aneurysms. *J Vasc Surg*, 2001, **34** : 892-9.
64. CHAIKOF E. L., BLANKENSTEIN J. D., HARRIS P. L. *et al.* Reporting standards for endovascular aortic aneurysm repair. *J Vasc Surg*, 2002, **35** : 1048-60.

Prof. Livio Gabrielli
Via Amedeo d'Aosta, 9
20129 Milan, Italy