

# Ocular Biomarkers of Alzheimer's Disease: The Role of Anterior Eye and Potential Future Directions

Cirous Dehghani,<sup>1</sup> Shaun Frost,<sup>2</sup> Rajiv Jayasena,<sup>1</sup> Colin L. Masters,<sup>3</sup> and Yogesan Kanagasingam<sup>2</sup>

<sup>1</sup>Australian e-Health Research Center, CSIRO, Parkville, Australia

<sup>2</sup>Australian e-Health Research Center, CSIRO, Perth, Australia

<sup>3</sup>The Florey Institute, The University of Melbourne, Parkville, Australia

Correspondence: Cirous Dehghani, CSIRO, 343 Royal Parade, Parkville VIC 3052, Australia; cirous.dehghani@csiro.au.

Submitted: May 01, 2018

Accepted: June 18, 2018

Citation: Dehghani C, Frost S, Jayasena R, Masters CL, Kanagasingam Y. Ocular biomarkers of Alzheimer's disease: the role of anterior eye and potential future directions. *Invest Ophthalmol Vis Sci.* 2018;59:3554-3563. <https://doi.org/10.1167/iovs.18-24694>

Globally, Alzheimer's disease (AD) is a growing health and economic challenge that has no effective cure. Recent clinical trials indicate that preclinical treatment may be required but a routine screening tool for AD has been elusive. Hence, a simple, yet sensitive biomarker for preclinical AD, when the disease is most likely to be amenable to treatment, is lacking. Due to several features, the eye has been explored for this purpose and, among the ocular tissues, the retina has received the most attention. Currently, major works investigating the potential AD diagnosis by detecting amyloid- $\beta$  (A $\beta$ ) signatures in the retinal tissue are underway, while the anterior eye is more accessible for in vivo imaging and examination. This report provides a concise review of current literature on the anterior eye components, including the crystalline lens, cornea, and aqueous humor, in AD. We also discuss the potential for assessment of the corneal nerve structure and regeneration as well as conjunctival tissue for AD-related alterations. The crystalline lens has received considerable attention, but further research is required to confirm whether A $\beta$  accumulates in the lens and whether it mirrors brain neuropathologic changes, particularly in preclinical AD. The rich corneal neural network and conjunctival vasculature also merit exploration in future studies to shed light on their potential association with AD pathologic changes.

Keywords: Alzheimer's disease, amyloid- $\beta$ , amyloid- $\beta$  protein precursor, biomarker, anterior eye, crystalline lens, cornea, dementia

Due to rising life expectancy, it is likely that the prevalence of age-related neurodegenerative diseases, such as dementia, will increase remarkably in the next few decades. With varying prevalence across the globe from 4.6% to 8.7%, over 46 million people worldwide were affected by dementia in 2015 and this figure is predicted to rise to approximately 132 million by 2050.<sup>1</sup> Alzheimer's disease (AD) is the most common cause of dementia in the elderly population. This progressive neurodegenerative disorder is characterized by brain atrophy associated with the presence of neuritic plaques and neurofibrillary tangles, made up largely of amyloid- $\beta$  (A $\beta$ ) deposits and accumulation of hyperphosphorylated tau proteins, respectively.<sup>2</sup> AD poses a major global public health and economic challenge and remains as one of the continuing unmet medical needs in neurology.<sup>1,3</sup>

A $\beta$  plaques, the major pathologic hallmark of AD, are extracellular aggregations and accumulations of misfolded A $\beta$  peptides (39–43 amino acid residues long; A $\beta$ 1–38 to A $\beta$ 1–43) in the brain and cerebral blood vessels of AD patients.<sup>4,5</sup> According to the amyloid cascade hypothesis, A $\beta$  is produced in the brain when amyloid- $\beta$  protein precursor (APP), a large transmembrane protein present in vesicle and cell surface membranes, is cleaved by multiple proteases including  $\beta$ - and  $\gamma$ -secretases and releases A $\beta$  fragments.<sup>3</sup> Several A $\beta$ -degrading enzymes are involved in cerebral A $\beta$  control, among which neprilysin is a crucial player and downregulation of its activity can contribute to AD development by promoting A $\beta$  accumulation.<sup>6,7</sup> Abnormally increased production and accumulation of A $\beta$  oligomers, primarily due to impaired clearance, leads to A $\beta$

plaque formation and consequently results in neuronal dysfunction and cell death in the cerebral cortex of AD patients.<sup>4,7</sup>

While AD is diagnosed definitively based only on autopsy brain findings,<sup>2</sup> at present the clinical diagnosis of AD mainly rests on conducting several tests, including medical history, cognitive tests, laboratory tests, and brain imaging techniques. With the advent of positron emission tomography (PET) imaging and cerebrospinal fluid (CSF) biomarkers (A $\beta$  and tau), there have been significant advances in the diagnosis of AD and these procedures can identify early neuropathologic changes before clinical decline.<sup>8–12</sup> However, the current brain A $\beta$  imaging tools and CSF procedures are expensive, invasive, and have limited availability in many countries. Researchers also have completed initial steps to improve diagnosis of AD by detecting blood-based A $\beta$  biomarkers.<sup>13</sup> However, this plasma A $\beta$  biomarker requires advanced laboratory expertise and equipment, and further validation is needed before the test can be used widely. Therefore, other alternatives or adjuncts to the blood test should continue to be explored. There is no doubt that an accurate, practical biomarker with the capability of early detection would have a large impact on AD research. Recent therapeutic research has focused on the preclinical phase of AD; hence, early detection will be key to tackling the occurrence of the underlying pathologic changes of AD using novel treatment modalities, well before symptoms appear.

The eye and its associated structures own a rich and complex sensory-motor innervation. From the 12 cranial nerves (CN) that emerge directly from the brain, three are specifically



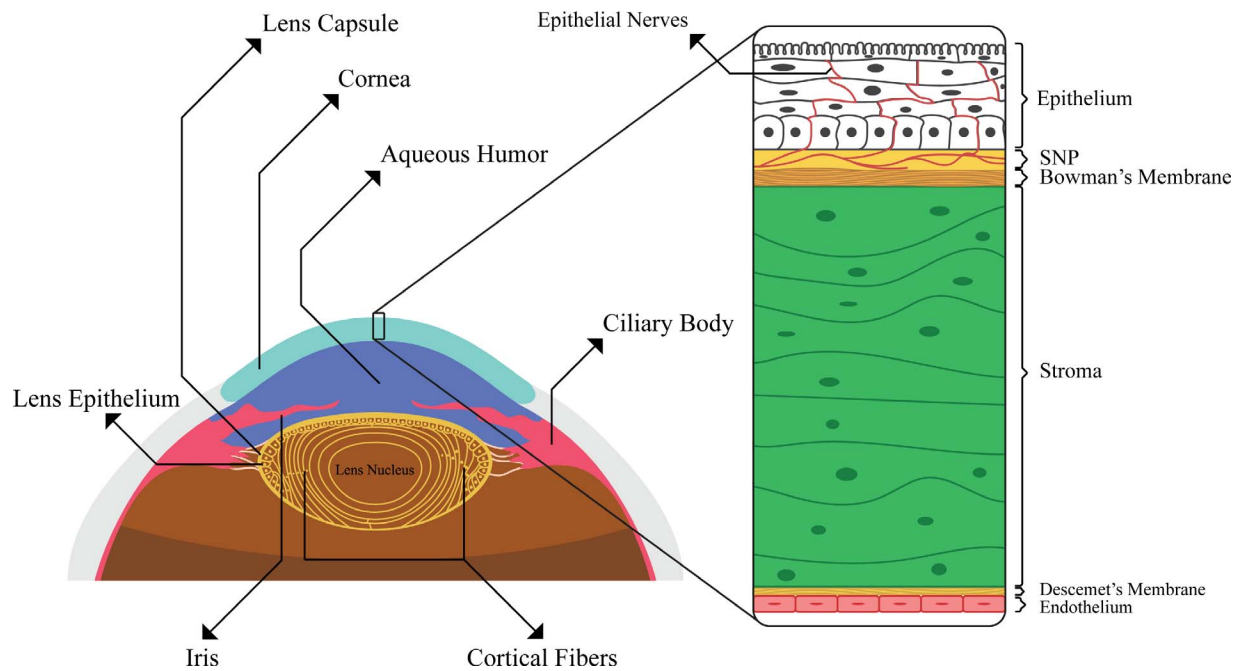


FIGURE 1. Graphical representation shows a cross-section through the anterior segment of the human eye.

devoted to oculomotor function (CN III, IV, and VI) and one (CN II, optic nerve) carries sensory information from the retina to the brain. The CN III also includes an efferent autonomic pathway that innervates the pupil and ciliary muscle. The ophthalmic division of CN V also innervates the ocular surface, lacrimal gland, eyelids, and eyebrows. Given this rich supply of neurons, it is not surprising that the eye has received a great deal of attention in several studies for AD-related alterations.

Using histochemical and imaging investigations, various studies have revealed AD-related changes in the neural and nonneural tissues of the eye. The retina, a developmental outgrowth of the brain, owns multiple interconnected neuronal layers and glial cells to support the nerve cells and has received the most attention. A growing body of evidence exists indicating retinal axonal and neural degeneration<sup>14,15</sup> and presence of A $\beta$  in the retinal tissue of the AD patients.<sup>15-17</sup> Investigators also have considered the potential usefulness of assessing the retinal blood flow and vasculature<sup>18,19</sup> and pupillary responses as markers of AD.<sup>20-22</sup>

The crystalline lens and corneal epithelium arise from the surface ectoderm, one of the three primitive embryonic layers responsible for formation of the eye and its structures.<sup>23</sup> The corneal endothelium and stromal keratocytes are formed from the neural crest, which also develops from the surface ectoderm in the region immediately adjoining the neural folds of neural ectoderm.<sup>23</sup> The lens also has shown promise as a potential site for the presence of A $\beta$  signature in AD.<sup>24,25</sup> However, the remaining anterior eye structures have received less attention compared to the posterior segment. Although exploring AD-specific alterations in the retina is worthwhile and the outcomes are encouraging, capturing quality images suitable for analysis is limited by several factors, including pupil size, formation of senile cataracts, and media opacities. Moreover, the retina is more prone to be affected by systemic diseases, such as diabetes and age-related degenerative conditions. However, the anterior eye is more accessible for imaging and less affected by the aforementioned factors.

In this review, we provide an overview of the literature and summarize the evidence that could support the possibility of exploration, which spans the investigation for AD-specific

changes or mechanisms paramount to AD etiology beyond the presence of A $\beta$  in the retina. Specifically, the pathologic evidence of A $\beta$  in the crystalline lens of animal and human eye advocating the hypothesis linking AD-related pathologic changes in the brain and lens will be reviewed followed by a small number of studies concerning the cornea and aqueous humor. The main outcomes of these studies are outlined in the Table and are discussed in more detail in the following sections. We will further describe the potential use of corneal nerve micromorphology examination using *in vivo* confocal microscopy in individuals with AD. Finally, the potential implication of the conjunctival tissue and vasculature will be discussed briefly.

## SEARCH STRATEGY

Electronic search was based on the PubMed, Scopus, and Google scholar databases up to February 2018 using combinations of the following keywords: Alzheimer's disease, eye, cornea, lens, aqueous humor, APP, A $\beta$ , and amyloid- $\beta$ . The included search filters were keyword, title, and abstract information. Articles with any combination of any of the anterior eye terms and Alzheimer's disease term were reviewed. Further works also were identified by searches of the reference lists of selected articles.

## THE CRYSTALLINE LENS

The crystalline lens is an avascular and transparent tissue located behind the iris, and its primary roles are to focus the incident light on the retina and supply the optical power of accommodation. Three main compartments of the human lens include the lens capsule, anterior single layer of lens epithelium, and lens fibers cells (Fig. 1). The lens owns a unique, concentric array of low water content fiber cells, densely packed with high concentrations of cytoplasmic crystalline proteins that have a critical role in maintaining its transparency.<sup>26</sup> Aging is accompanied by a progressive loss in the transparency of the human lens and, like AD, an increase of

**TABLE.** Animal and Human Studies Examined the Lens, Cornea, and Aqueous Humor for AD-Related Pathologic Changes

| Year | Authors                         | Subject(s) (Tissue Assessed) and Anterior Eye Findings   |
|------|---------------------------------|--|
| 1996 | Frederikse et al. <sup>29</sup> | <ul style="list-style-type: none"> <li>• Monkey, rabbit and rats (lens) <ul style="list-style-type: none"> <li>• Low level presence of APP and A<math>\beta</math> in normal lenses</li> <li>• APP and A<math>\beta</math> increased in monkey lenses and rabbit lens epithelium after oxidative stress exposure</li> <li>• Rat lenses exposed to oxidative stress showed increased APP in the anterior epithelium and cortex</li> <li>• A<math>\beta</math> produced vacuoles and was toxic to cultured rabbit lens epithelial cells</li> </ul> </li> <li>• Human (cataractous lens) <ul style="list-style-type: none"> <li>• A<math>\beta</math> in the cortical fiber cells below the epithelial cell surface layer</li> </ul> </li> </ul>  |
| 1998 | Frederikse et al. <sup>31</sup> | <ul style="list-style-type: none"> <li>• Mice (lenses) <ul style="list-style-type: none"> <li>• Presenilin expression in the epithelial layer of lens and cornea. Stronger expression in the region of the epithelium near the lens equator</li> </ul> </li> <li>• Monkey (lens and cornea) and mouse (lens) <ul style="list-style-type: none"> <li>• Presenilin expression was detected in the outer lens epithelial layer, and also is stronger in intensity near the equatorial margin</li> <li>• Using Western blot proteolysis, presenilin proteins were detected in total protein of monkey lens and cornea and mouse lens</li> </ul> </li> <li>• Human (noncataractous lens) <ul style="list-style-type: none"> <li>• Immunohistochemical detection of presenilin protein in a non-cataractous human lens</li> </ul> </li> </ul>  |
| 1999 | Frederikse et al. <sup>35</sup> | <ul style="list-style-type: none"> <li>• Mice (lenses) <ul style="list-style-type: none"> <li>• Thiamine (Vitamin B1) deficiency resulted in lens fiber cell degeneration observed primarily along the lens posterior beneath the intact capsule</li> <li>• A localized increased expression of APP, A<math>\beta</math> peptides, and presenilin was observed in the affected regions</li> </ul> </li> </ul>  |
| 2000 | Frederikse et al. <sup>38</sup> | <ul style="list-style-type: none"> <li>• Mice (lenses, <i>n</i> = 8) <ul style="list-style-type: none"> <li>• Amyloid-like protein structure in interior fiber cells</li> </ul> </li> <li>• Human (lenses, <i>n</i> = 8) <ul style="list-style-type: none"> <li>• Presence of amyloid protein supramolecular order of lens protein in interior fiber cells, demonstrated by amyloidophilic dye binding, thioflavine fluorescence, and birefringence</li> </ul> </li> </ul>   |
| 2002 | Frederikse et al. <sup>39</sup> | <ul style="list-style-type: none"> <li>• Human and mouse (lens and cornea) <ul style="list-style-type: none"> <li>• APP mRNA splicing pattern: presence of predominantly longer and potentially more deleterious APP transcript (encoding 751 and 770 amino acid proteins), in the human and mouse lenses compared to the shorter (695 amino acids) encoding transcript expressed in the brain and retina</li> </ul> </li> <li>• Human APP transgenic mice (lenses) <ul style="list-style-type: none"> <li>• APP expression is increased, consistent with the cycle of oxidative stress proposed in the mechanism of AD pathology</li> <li>• Fiber cell membrane defects similar to those observed in human cataracts, increased age-related lens degeneration (staining with hematoxylin and eosin)</li> <li>• Greatest sensitivity of the lens to AD than cornea and retina of transgenic animals</li> </ul> </li> </ul>   |
| 2003 | Li et al. <sup>41</sup>         | <ul style="list-style-type: none"> <li>• Mouse and rat (lenses) <ul style="list-style-type: none"> <li>• Lens expression of <math>\beta</math>-secretase, <math>\gamma</math>-secretase (presenilin and nicastrin proteins), notch and neprilysin</li> </ul> </li> </ul>   |
| 2003 | Goldstein et al. <sup>25</sup>  | <ul style="list-style-type: none"> <li>• Human (lenses; <i>n</i> = 9 with AD and <i>n</i> = 8 controls, aqueous humor without disorder; <i>n</i> = 3), postmortem study <ul style="list-style-type: none"> <li>• Identification of A<math>\beta</math>1-40 and A<math>\beta</math>1-42 in lenses from individuals with and without AD at concentrations comparable with the brain</li> <li>• Accumulation of A<math>\beta</math> in lenses of individuals with AD, located exclusively in the cytoplasm of supranuclear/deep cortical lens fiber cells (<i>n</i> = 4)</li> <li>• Presence of equatorial supranuclear cataracts in lenses from all individuals with AD (<i>n</i> = 9) while it was evident in none of the controls (<i>n</i> = 8).</li> <li>• Enhanced A<math>\beta</math> immunoreactivity and birefringent Congo Red staining observed in the supranuclear cataracts</li> <li>• A<math>\beta</math>1-40 in primary aqueous humour at concentrations comparable with cerebrospinal fluid.</li> </ul> </li> </ul> |
| 2009 | Dutescu et al. <sup>40</sup>    | <ul style="list-style-type: none"> <li>• Transgenic mice (lens and cornea) <ul style="list-style-type: none"> <li>• Strong cytoplasmic expression of APP and possibly A<math>\beta</math> in the lens and corneal epithelia</li> </ul> </li> </ul>   |
| 2010 | Prakasam et al. <sup>30</sup>   | <ul style="list-style-type: none"> <li>• Bovine and transgenic mice (lens, cornea and aqueous humor) <ul style="list-style-type: none"> <li>• APP was detected in the cornea and iris but not in the lens and aqueous humor of the normal adult bovine eyes (Western blots)</li> <li>• Detection of significant amounts of A<math>\beta</math>40 and A<math>\beta</math>42 in the aqueous humor of the Bovine and transgenic mice (ELISA)</li> </ul> </li> </ul>   |
| 2010 | Moncaster et al. <sup>42</sup>  | <ul style="list-style-type: none"> <li>• Human with Down syndrome (lenses; <i>n</i> = 12) and normal controls (lenses; <i>n</i> = 34), postmortem analysis <ul style="list-style-type: none"> <li>• Presence of supranuclear opacification associated with accelerated supranuclear A<math>\beta</math> accumulation</li> <li>• Colocalizing amyloid pathology, and fiber cell cytoplasmic A<math>\beta</math> aggregates (0.5-50 nm) identical to the lens pathology identified in AD</li> </ul> </li> </ul>  |
| 2013 | Michael et al. <sup>43</sup>    | <ul style="list-style-type: none"> <li>• Human with AD (<i>n</i> = 39 lenses from 21 donors), and age-matched controls (<i>n</i> = 15, lenses), postmortem examination <ul style="list-style-type: none"> <li>• Of 21 donors with AD, 15 cases had only minor or no cortical opacities and 6 had marked bilateral cortical lens opacities</li> <li>• Congo red, thioflavin, and mouse monoclonal A<math>\beta</math> antibody staining were negative for all lenses from AD and controls</li> </ul> </li> </ul>  |

TABLE. Continued

| Year | Authors                       | Subject(s) (Tissue Assessed) and Anterior Eye Findings  |
|------|-------------------------------|---|
| 2013 | Kerbage et al. <sup>47</sup>  | <ul style="list-style-type: none"> <li>• Human with AD (lenses from 10 participants), in vivo study using fluorescent ligand bound to A<math>\beta</math> and a laser scanning device</li> <li>• Fluorescent intensity was measured at three different locations starting from the lens cortex (SN1) into the deeper supranuclear region (SN3, ~ 900 <math>\mu</math> beneath lens capsule)</li> <li>• Both groups: SN3 showed a larger signal increase as compared to SN1 and SN2</li> <li>• AD group: <ul style="list-style-type: none"> <li>• Fluorescent intensity measurements in the SN1 and SN2 areas were higher compared to controls</li> <li>• A<math>\beta</math> specific frequency counts determined more than twofold higher than corresponding measures in controls</li> </ul> </li> </ul> |
| 2014 | Michael et al. <sup>44</sup>  | <ul style="list-style-type: none"> <li>• Human with AD (lenses from <math>n = 7</math> donors), postmortem study</li> <li>• 5 had only minor or no cortical opacities, 1 moderate and 1 had pronounced bilateral cortical lens opacities</li> <li>• Significantly different proteins profiles detected for forming lens opacifications and in hippocampal plaques and tangles in AD</li> <li>• The absence of A<math>\beta</math> immunostaining in cataractous and noncataractous cortical regions</li> </ul>  |
| 2014 | Ho et al. <sup>45</sup>       | <ul style="list-style-type: none"> <li>• Human (lenses from <math>n = 11</math> cases of AD, <math>n = 4</math> with Down syndrome and <math>n = 6</math> age-matched controls), postmortem</li> <li>• Immunostains (mouse monoclonal A<math>\beta</math> antibody: very weak staining of lenses in 3 of 6 controls and 5 of 11 cases with AD)</li> <li>• Congo red stains: completely negative for all cases</li> <li>• No birefringent congophilic material in the lens of cases with Down syndrome</li> </ul>  |
| 2015 | Kerbage et al. <sup>24</sup>  | <ul style="list-style-type: none"> <li>• Human (lenses from <math>n = 20</math> participants with AD and <math>n = 20</math> healthy controls), in vivo study using fluorescent ligand eye scanning technique</li> <li>• Twice higher fluorescence uptake value (FUV) for the AD group compared to control group (0.50 vs. 0.23, respectively)</li> <li>• Using FUV threshold of 0.367, a sensitivity of 85% and a specificity of 95% obtained in predicting clinical diagnosis of AD</li> <li>• Significant correlation between amyloid brain imaging using positron emission tomography and fluorescent ligand eye scanning (<math>r^2 = 0.33</math>, <math>P &lt; 0.001</math>)</li> </ul>   |
| 2017 | Williams et al. <sup>46</sup> | <ul style="list-style-type: none"> <li>• Human (lenses from <math>n = 17</math> with varying degrees of AD, and <math>n = 2</math> age-matched controls), postmortem study</li> <li>• None of the cases were identified with immunohistochemical staining for A<math>\beta</math> in any part of the eye including the lens</li> </ul>  |

misfolded, insoluble protein aggregation and accumulation.<sup>27,28</sup> These characteristics have provided an ideal site for exploring protein accumulation and potential AD signatures. A number of studies have demonstrated the presence of several mechanisms fundamental to AD etiology in the lens, and potential involvement of similar mechanisms for cataract formation and age-related amyloidogenic A $\beta$  degenerative conditions of the brain. However, some conflicting reports exist with respect to lens alterations mirroring AD changes in the brain as well.

In 1996, Frederikse et al.,<sup>29</sup> using in vivo and lens organ culture models, have shown the potential role that AD pathogenesis may have in oxidative stress-related lens degeneration and their study provided evidence that AD-associated pathologic mechanisms may contribute to the senile formation of cataract. Using immunohistochemistry (monoclonal APP and A $\beta$  antibody) and immunoblotting methods, they reported low level presence of APP and A $\beta$  in normal mammalian lenses and confirmed increased levels of these peptides in cortical fiber cells of cultured rat and monkey lenses after oxidative stress exposure. They also showed that A $\beta$  which was present in the cataractous human lens, is toxic to cultured mammalian lens epithelial cells. However, their finding of APP in the normal mammalian lenses differs from that of Prakasam et al.,<sup>30</sup> who did not detect APP in the lenses of the normal adult bovine eyes using biochemical analysis.

As noted earlier, A $\beta$  peptides constitute the principal molecular components found in the neuritic plaques of AD patients. As an intramembranous protease and a subunit of  $\gamma$ -secretase, presenilin proteins influence proteolytically the

cleavage process of APP to form A $\beta$  oligomers. In a subsequent work, Frederikse et al.<sup>31</sup> demonstrated that the AD-associated presenilins also are expressed and proteolytically processed in the mammalian lens. Presenilin expression was detected in the epithelial layer of mouse and monkey lens and was stronger near the equatorial region of the lens. Immunohistochemically, presenilin protein also was detected in the noncataractous human lens.

Thiamine (vitamin B1) has a significant role in energy metabolism. Thiamine deficiency, which is considered a classic model of oxidative impairment, has been linked to AD pathologic changes.<sup>32-34</sup> In another study by Frederikse et al.,<sup>35</sup> mice models with systemic oxidative stress induced by thiamine deficiency, produced Alzheimer-associated brain pathologic alterations. Using analysis of anti-APP, anti-A $\beta$ , and fluorescent conjugated secondary antibodies, they also demonstrated degeneration of the lens fiber cells with locally increased distributions of APP, A $\beta$ , and presenilin proteins.<sup>35</sup> The Raman and infrared spectroscopy studies of the lens proteins have shown that the predominant protein conformation found in the normal mammalian lenses is the  $\beta$ -pleated sheets.<sup>36,37</sup> Frederikse et al.,<sup>38</sup> using amyloidophilic stains of Congo red and thioflavine, revealed that the  $\beta$ -sheet arrays of mammalian crystalline lenses own an amyloid-like supramolecular order in interior fiber cells. In this study, as a positive control, histologic sections of the brain tissue from an individual previously diagnosed with AD also were stained.

To further extend their findings and provide additional support for their previous reports of AD pathologic mechanisms and lens degeneration, Frederikse et al.<sup>39</sup> used transgenic

mice harboring a complete copy of a genomic human APP (*hAPP*) in addition to the native APP gene. In *hAPP* transgenic mouse lenses, they determined an increased APP expression and morphologic changes, including lens fiber cell defects, increased age-related fiber cell degeneration, and cortical plaque formation. They claimed that their findings describing morphologic abnormalities in *hAPP* mice would advocate a significant role that *hAPP* gene dosage may have in protein aggregation effects that lead to cataract formation. This finding also may explain the higher frequency of early-onset cataracts detected in individuals with Down syndrome, who have a third copy of chromosome 21 (upon which APP is located), and show characteristics of AD at young ages, such as formation of A $\beta$  plaques, neuropathologic changes of the brain and cognitive decline. By examining APP mRNA splicing pattern, they also demonstrated the presence of predominantly longer and potentially more deleterious APP transcript (encoding 751 and 770 amino acid proteins) in human and mouse lenses compared to the shorter 695 amino acid encoding transcript expressed in the brain and retina. Furthermore, they found human A $\beta$  in the lenses of transgenic mice but not control (wild-type) mice. Likewise, in their immunocytochemistry study of eyes and brain samples in a mouse model of AD, Dutescu et al.<sup>40</sup> reported a strong cytoplasmic expression of APP and possibly A $\beta$  in the lens and corneal epithelia of transgenic mice while labeling in wild-type control tissues was insignificant.

As previously stated,  $\beta$ - and  $\gamma$ -secretases have a significant role in cleavage of APP and releasing A $\beta$  peptides. Neprilysin, an A $\beta$ -degrading enzyme, also is involved in the cerebral A $\beta$  control and downregulation of its activity can contribute to A $\beta$  accumulation.<sup>6,7</sup> Using immunoblots and immunohistochemistry, Li et al.<sup>41</sup> demonstrated expression of  $\beta$ - and  $\gamma$ -secretases together with neprilysin in mammalian lenses, denoting the role of these enzymes in the lens A $\beta$  turnover and providing additional evidence that mechanisms of Alzheimer's pathology can be present in the lens.

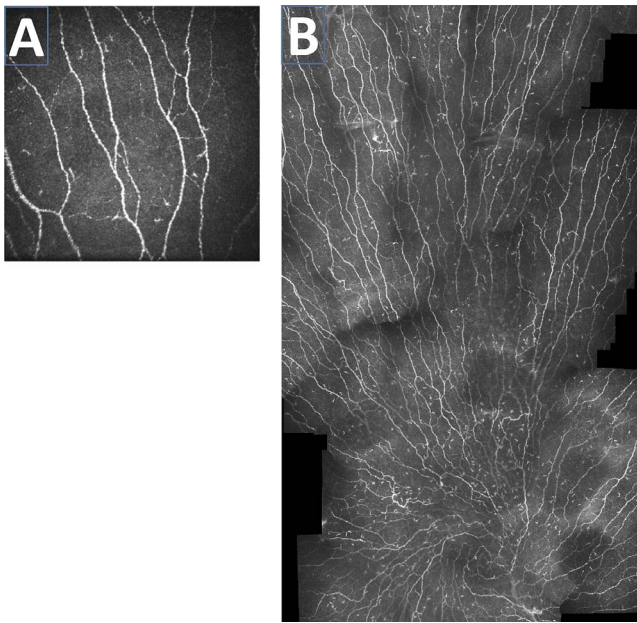
While it seems that A $\beta$  peptides accumulate during normal aging in the crystalline lens and there may be an accelerated A $\beta$  aggregation and accumulation associated with AD, some inconsistency exists in the literature as well. In a study of postmortem specimens of the eyes and brain from individuals with and controls without AD, using A $\beta$  immunoreactivity and birefringent Congo red staining, Goldstein et al.<sup>25</sup> reported identification of A $\beta$  peptides in the human lens at a concentration comparable with those in the aged human cerebral cortex. They noted AD-linked supranuclear opacification accompanied with A $\beta$  aggregates and colocalizing lenticular pathology in specimens from subjects with AD, but not in those with other anomalies nor in normal controls. Since AD and Down syndrome exhibit similarities in terms of neuropathology and neurocognitive consequences, interestingly a subsequent investigation<sup>42</sup> revealed the presence of pathologic alterations in the lenses of individuals with Down syndrome identical to what was described previously in people with AD.

While the findings of two reports by Goldstein et al.<sup>25</sup> and Moncaster et al.<sup>42</sup> referred to A $\beta$  accumulation in supranuclear (cortical) cataracts of subjects with AD and Down syndrome, their findings were faced with conflicting conclusions from other research groups.<sup>43-46</sup> In their first study, Michael et al.<sup>43</sup> examined 54 lenses ( $n = 39$ , from 21 postmortem donors with AD and  $n = 15$ , from age-matched controls) using Congo red, thioflavin, and A $\beta$  immunohistochemical (monoclonal A $\beta$  antibody, clone 6F/3D) staining. They found negative staining in all AD and control lenses. Interestingly, the majority of donors (12 of 17) showed no cortical cataracts or had minor extension of opacities, ruling out supranuclear cataracts as the

typical form of lens opacification observed in AD claimed by Goldstein et al.<sup>25</sup> In their second work, using confocal Raman microspectroscopy and imaging, they studied the protein profiles in the brain plaques and tangles as well as ocular lenses from seven neuropathologically confirmed AD donors. Consistent with their former study, the majority of the donors had minor or no cortical opacities. Additionally, while the staining procedures were positive for A $\beta$  and tau in the brain, they turned out to be fully negative for the crystalline lens regardless of the presence or absence of opacities.<sup>44</sup> They concluded that cortical cataracts do not constitute the main type of cataracts found in AD and are very unlikely to be linked with AD. Furthermore, they stated that the crystalline lens opacifications in AD do not hold substantial amounts of A $\beta$  as determined by Goldstein et al.<sup>25</sup>

A lack of A $\beta$  in the human lens also has been described subsequently by other researchers. In their postmortem examination using immunostains for A $\beta$  (mouse monoclonal antibody, clone 6F/3D), phospho-tau, and Congo red stains, although Ho et al.<sup>45</sup> found very weak nonspecific A $\beta$  staining in some cases, they did not detect any amyloid deposits or abnormal tau accumulations in the lenses from 11 cases of AD, six controls, and four cases of Down syndrome. They concluded that AD-related aggregates do not deposit in the eye similar to brain deposits, or are present at lower levels or in different forms. In a very recent examination of the eyes of 19 human postmortem cases (17 with AD and two age-matched controls), Williams et al.<sup>46</sup> performed hematoxylin and eosin staining as well as A $\beta$  immunohistochemistry (clone 6F/3D) and found no evidence of A $\beta$  deposits or accumulation in any part of the eye including the lens, concluding that there may be no concurrent or similar AD alterations in the brain and lens. The different methodologic approaches used in these studies including AD diagnostic criteria, using cross-sections rather than the whole mount tissue and the applied staining protocols, make comparison of outcomes of these studies difficult, but they may account, at least in part, for the reported discrepancies.

Despite these conflicting reports<sup>43-46</sup> that questioned the advocated notion of the crystalline lens to serve as an indicator or predictor of AD pathologic changes, the positive and promising outcomes of other studies encouraged investigators to develop noninvasive methods to explore in vivo AD signatures in the human crystalline lens. Kerbage et al.<sup>47</sup> first used an in vivo technique of laser scanning along with a fluorescent ligand to examine the presence of AD signatures in the human lens. They examined 10 participants (five with AD and five controls) and detected an exogenous fluorescent signature bound to A $\beta$  in the lens of the study sample, which was able to differentiate individuals with AD from the control group. They determined that A $\beta$  specific frequency counts in the AD group were more than 2-fold higher than those of the control group. In their subsequent, relatively larger study using the fluorescent ligand eye scanning (FLES) technique in the crystalline lens,<sup>24</sup> the same research team reported capability of the technique to discriminate a group of people with probable AD ( $n = 20$ ) from healthy controls ( $n = 20$ ). In their examiner-masked, age-matched case control cohort, a sensitivity and specificity of 85% and 95%, respectively, was obtained for diagnosis of AD. They also reported that A $\beta$  brain imaging using PET correlated significantly with the results obtained in the eye ( $r^2 = 0.33$ ,  $P < 0.001$ ). However, this should be interpreted with caution as they excluded the data pertaining to cases where qualitative PET or FLES made an incorrect prediction. Overall, they concluded that their FLES technique has the potential to be used for AD detection and classification of its severity.



**FIGURE 2.** (A) A  $400 \times 400 \mu\text{m}$  image of central corneal subbasal nerve plexus in a healthy individual. (B) An example of wide-field montage of the corneal subbasal nerve plexus which can be used to quantify the corneal nerve migration rate. Image courtesy of K. Al Rashah and K. Edwards, Anterior Eye Lab., Queensland University of Technology, Queensland, Australia.

Despite discrepancies among the published results concerning  $A\beta$  signatures and AD-related changes in the lens, this field of research requires more exploration, in particular, eliminating those factors that limit comparisons of the outcomes of different studies. An important inherent limitation of the crystalline lens as a site for exploring AD-specific changes is in individuals who have been/are affected by mature cataracts and had their cataract removed or are in the process of undergoing cataract surgery.

## THE CORNEA AND AQUEOUS HUMOR

While the majority of the research of the anterior eye and AD has focused on the crystalline lens, little is known about the potential presence of AD pathologic mechanisms in the cornea and aqueous humor. The cornea is a transparent and avascular connective tissue located anteriorly to the iris and, in combination with the precorneal tear film, has an important role via providing a proper anterior refractive surface and protects the eye against infection and structural damage to the deeper components of the eye.<sup>48,49</sup> Histologically, the human cornea consists of five basic layers, three cellular layers (epithelium, stroma, and endothelium) and two acellular interfaces (Bowman and Descemet membranes; Fig. 1). The human cornea is the most densely innervated surface tissue of the body with approximately  $606 \text{ terminals}/\text{mm}^2$  in the suprabasal layers of the central corneal epithelium.<sup>50</sup> The highly populated sensory endings are provided by the fine branches emanating from the corneal subbasal nerve plexus (SNP), a rich nerve network running parallel to the corneal surface, which is located between Bowman's layer and the basal epithelial cell layer<sup>51</sup> (Figs. 1, 2A).

Aqueous humor, a clear plasma-derived ultrafiltrate, is produced by the pigmented and nonpigmented epithelium of the ciliary body.<sup>26,52</sup> After passing through the pupil, the aqueous enters the anterior chamber and is mainly drained

away via the drainage structures located at the anterior chamber angle. In addition to the fundamental contribution of the aqueous humor in maintenance of the IOP and provision of the proper shape and optical properties of the eye, it has a pivotal role in nourishing the cornea and lens as well as eliminating of their waste products.<sup>52</sup>

Pathologic accumulation of amyloid proteins, such as keratoepithelin (AKer), may deposit in the corneal tissue causing the corneal lattice dystrophies, which exhibit the characteristics of staining with Congo red and green birefringence with a polarizing filter<sup>53-55</sup> similar to neuropathologic staining observed in AD. Studies investigating mechanisms of AD pathology, including the presence of  $A\beta$ , APP, as well as AD-related changes in the cornea and aqueous humor, are scarce in scope and mainly have been reported as a part of the other published results. Besides the previously discussed lens findings, Frederikse et al.<sup>31</sup> revealed that AD-associated presenilins also are expressed and proteolytically processed in the corneal epithelium of mammals, similar to presenilin processing in neurons. In their in situ hybridization analysis, Frederikse et al.<sup>31</sup> detected expression of presenilin mRNA in the epithelial layers of the mouse cornea. They also detected the presence of presenilin in monkey cornea by analyzing the corneal proteins on Western blots. Later, in their analysis of purified total RNA from ocular tissues, Frederikse et al.<sup>39</sup> described that human and transgenic mouse corneas predominantly express APP transcripts that are longer and potentially more deleterious compared to the major shorter APP amino acid encoding transcript expressed in the brain and retina. In comparison with the cornea, they found a greater sensitivity of the lens to AD pathology in *bAPP* transgenic mice. The presence of longer APP transcripts in the cornea of mammals also has been reported in the normal adult bovine eyes.<sup>30</sup>

Anterior ocular fluid and CSF share a number of features in common, such as the similarity between blood-aqueous and blood-CSF barriers.<sup>56</sup> To our knowledge, no study to date has analyzed the aqueous humor in AD individuals.  $A\beta_{42}$  and  $A\beta_{40}$  are two major isoforms of  $A\beta$  peptides, with the former having two extra residues at the C-terminus. While the amyloid aggregations in AD brains mainly consist of  $A\beta_{42}$ , the interaction between these two isoforms may have a critical role in AD.<sup>57</sup> Recent evidence also suggests that the CSF  $A\beta_{42}/A\beta_{40}$  ratio is superior to CSF  $A\beta_{42}$  to detect brain  $A\beta$  deposition in early stages of AD and to differentiate AD from non-AD dementias.<sup>58</sup> Using anti- $A\beta$  mass spectrometry analysis of aqueous humor samples of three AD-free individuals undergoing cataract extraction, Goldstein et al.<sup>25</sup> identified  $A\beta_{1-40}$  in human aqueous humor which was comparable with those in aged human CSF. In a biochemical analysis, while Prakasam et al.<sup>30</sup> did not detect APP in the aqueous humor of bovine eyes using Western blots, they described detection of significant amounts of  $A\beta_{40}$  and  $A\beta_{42}$  in the aqueous humor of the bovine and transgenic mice by ELISA analysis. They also suggested that secreted APP derivatives and  $A\beta$  may be produced in the retina, secreted into the vitreous humor and transported into the aqueous humor.

$A\beta$  peptide and AD-related protein levels have been reported to be present in aqueous humor of patients with pseudoexfoliation syndrome (PEX) and glaucoma; hence, lent themselves to being linked with AD etiologies.<sup>59,60</sup> Janciauskiene et al.<sup>61</sup> analyzed a large sample ( $n = 266$ ) of aqueous humor specimens obtained during cataract surgery in patients with cataracts only or in combination with ocular disorders, including glaucoma, pseudoexfoliation syndrome, macular degeneration, and diabetic retinopathy. Using the human (6E10) multiplex ELISA technology, they demonstrated measurable levels of the  $A\beta$  peptides ( $A\beta_{38}$ ,  $A\beta_{40}$ , and  $A\beta_{42}$ ) in at least 40% of all samples apart from the diabetic retinopathy

group for which A $\beta$ <sub>38</sub> was identified in only 31% of cases. However, in this study, when other groups were compared to a cataract-only population, no significant difference was found between groups in terms of the level of A $\beta$  peptides. By assessing concentrations of A $\beta$ <sub>40</sub> and A $\beta$ <sub>42</sub> in plasma and aqueous humor using ELISA as well as conducting Mini Mental State Examination (MMSE) and Clock Drawing Tests, Lesiewska et al.<sup>62</sup> also were unable to reveal any differences between PEX patients and controls undergoing cataract surgery for these measures, ruling out the potential link between PEX and AD amyloid peptides or cognitive functions.

Considering these studies indicating the presence of A $\beta$  peptides in aqueous humor, it would be informative to examine APP and A $\beta$  proteins in aqueous humor of individuals with AD, which may reveal higher levels of A $\beta$ <sub>42</sub>, the main type found in neocortical deposits. It must be noted that obtaining aqueous humor samples is an invasive procedure and even if the outcomes are promising, this would not become a viable procedure for AD screening. However, this would provide valuable insights regarding the interpretation of similar mechanisms of AD pathology in anterior avascular tissues; that is, the lens and cornea.

## POTENTIAL AREAS FOR FUTURE EXPLORATION

### Morphology of the Corneal SNP and Nerve Migration

The corneal SNP may serve as a site to investigate the potential direct and indirect neurotoxic effects of AD. The advent of corneal confocal microscopy (CCM) has remarkably improved our understanding of the corneal cellular and neural microstructure in the living state, in particular, the SNP. The technique of CCM offers researchers and clinicians the opportunity to directly and noninvasively examine the ocular surface at cellular level comparable to *in vitro* histochemical techniques. Besides its clinical application to investigate numerous eye diseases, over the past decade CCM has been used to assess the SNP micromorphology in a variety of systemic conditions and neurodegenerative diseases.

Diabetic and chemotherapy-induced neuropathies are two examples of peripheral neurodegenerative conditions in which CCM has been used. Morphologic examination of the small nerve fibers of the cornea using *in vivo* CCM has received considerable attention as an objective and reproducible imaging marker for diabetes-associated peripheral neuropathy.<sup>63</sup> CCM has demonstrated considerable utility in neuropathy detection,<sup>64,65</sup> early diagnosis,<sup>66</sup> stratification of severity,<sup>67</sup> and assessment of therapeutic efficacy.<sup>68</sup> Interestingly, by using this technique longitudinally, CCM had the capability for predicting future incident diabetic neuropathy<sup>69</sup> and tracking progressive corneal axonal degeneration in patients with neuropathy.<sup>70</sup> By demonstrating the corneal nerve alterations, CCM also has been able to reveal chemotherapy-induced peripheral neuropathy.<sup>71,72</sup>

Microstructural assessment of the SNP also has shown promise for some central nervous system (CNS) diseases. Parkinson's disease (PD) and multiple sclerosis (MS) are two main CNS neurodegenerative diseases in which CCM recently has been applied to investigate the corneal neural network. Using CCM, Anjos et al.<sup>73</sup> showed decreased corneal sensation and corneal nerve fiber changes in patients with PD. Later, Kass-Iliyya et al.<sup>74</sup> reported corneal nerve fiber pathology in patients with PD, which correlated with autonomic symptoms, parasympathetic deficits and motor scores. A more recent study also revealed even preclinical small nerve neuropathy in newly diagnosed PD patients.<sup>75</sup> Significant reduction in total

corneal nerve fiber density, which was associated with clinical severity<sup>76</sup> and reduced corneal nerve measures and increased dendritic cell density in patients with multiple sclerosis,<sup>77</sup> has been described in recent CCM studies.

The accessibility of the cornea and ease of imaging of its microstructure using CCM in addition to the evolving evidence suggesting a corneal nerve network might reflect the peripheral and central neurodegeneration, present an opportunity to investigate the contribution of potential SNP pathology to AD. AD is a multifaceted neurodegenerative condition and the rationale for this hypothesis is lent support primarily by the trophic role of nerve growth factor (NGF) in the sensory system and CNS,<sup>78</sup> as well as the potential role that acetylcholine (ACh) has in AD and the corneal epithelium. NGF is an essential neurotrophic factor for the development, survival and integrity of nerve cells in the CNS and cornea.<sup>78</sup> In AD, there is a NGF-dependent atrophy of basal forebrain cholinergic neurons.<sup>79</sup> As the most densely innervated and sensitive surface tissue of the body,<sup>50</sup> the NGF receptor also presents in the corneal tissue and has a pivotal contribution to corneal physiopathology,<sup>80,81</sup> including corneal nerve regeneration.<sup>82</sup> Moreover, in AD the key neurotransmitter deficit is ACh. The corneal epithelium also contains one of the highest concentrations of ACh in the body and has a significant contribution to the corneal epithelial maintenance and development.<sup>51</sup> Therefore, it is conceivable that corneal small nerve and epithelial alterations may occur parallel to AD neurologic changes (atrophy, cholinergic depletion), such that corneal structural parameters could be used for AD screening or monitoring.

SNP morphology can be investigated by capturing multiple images from this rich nerve network using CCM (Fig. 2A). Several morphometric parameters can be quantified using different segmentation tools. Another venue of exploration is examining the corneal nerve migration. In this newly developed approach,<sup>83</sup> wide-field montages (Fig. 2B) from the SNP are generated at baseline and after a certain period of time. Two corneal maps then are examined and a reference landmark as well as various nerve landmarks are identified and subsequently nerve movement is estimated. This technique could be of value in the assessment of the relationship between AD and the sensory nerve regeneration for instance in trials evaluating new therapies.

### AD-Specific Alterations in the Conjunctival Tissue

As a translucent and highly vascular membrane extending from the eyelid margin to the limbus, conjunctiva has an important role in the ocular surface protection and provides mucus for the tear film. *In vivo* investigation of conjunctival morphology at the cellular level, including blood vessels containing cellular elements, is now possible at high magnification using CCM.<sup>84</sup> Conjunctival microcirculation has the advantage of anatomical proximity to the brain circulation and, more importantly, both share a common root, which is the internal carotid artery. These features may indicate an inherent vulnerability of the conjunctiva to AD pathology. A $\beta$  plaques also have been identified in tissues other than the brain, including the kidneys and lungs of patients with AD.<sup>85</sup> Therefore, investigation of the conjunctival vascular and perivascular spaces may provide an opportunity for detection of AD-specific alterations or extracerebral AD-associated amyloid pathology. However, the currently available technologies of *in vivo* anterior segment imaging, such as CCM, require further modification to be able to detect A $\beta$  burden in the conjunctival tissue using staining or fluorescent techniques and they need better characterization of the blood vessels, their walls, and the cellular contents.

## CONCLUSION

AD, the most common cause of dementia in the elderly, is an emerging global public health and economic challenge and requires more attention. While the details of AD pathogenesis remain a topic of debate, it is widely believed that accumulation of misfolded A $\beta$  peptides is the primary event for AD neuronal deficits.

The current research on potential ocular markers of AD is concentrated mainly on the pathologic changes and A $\beta$  signatures in the retina, while the anterior eye is more accessible for imaging and examination than the retina. In efforts to advance our knowledge about eye markers of AD, focusing on the anterior part of the eye would be a valuable area of research.

Although incongruous conclusions have been reported in the literature regarding the presence of changes in the lens reflecting Alzheimer's brain pathologic changes, in particular through histochemical studies, and the role of the lens is limited in pseudophakic and aphakic patients, the crystalline lens still harbors the promise of identifying abnormal protein aggregations characteristic of AD, but it is still in early stages and further validation is needed. Future histopathology studies require more robust methodologic approaches to make the outcomes comparable. In vivo studies identifying A $\beta$  signatures in the crystalline lens must encompass a wider spectrum of individuals with cognitive decline (e.g., mild cognitive impairment) to address the potential early involvement as well. A longitudinal study also would offer an appreciation of a robust correlation with established methods of A $\beta$  brain imaging and CSF biomarkers.

The cornea and aqueous humor have not been fully dissected in relation to AD; hence, comprehensive studies are needed to conclusively examine these tissues in this disorder. Since AD is a neurodegenerative condition, it is also worth exploring the potential direct or indirect neurotoxic activity of this condition on the corneal nerve structure and its regeneration capacity, which would be feasible using the currently available powerful in vivo CCM technique. Detailed knowledge of the conjunctival vascular and perivascular tissues in AD also may lead to a better understanding of potential alterations associated with this disorder and would broaden the spectrum of the anterior eye opportunities to investigate potential changes associated with AD. However, this needs precise tissue characterization and additional technical improvement of the currently available in vivo techniques.

## Acknowledgments

The authors thank Farshid Dehghani for his assistance in the graphic design of Figure 1.

Disclosure: **C. Dehghani**, None; **S. Frost**, None; **R. Jayasena**, None; **C.L. Masters**, None; **Y. Kanagasigam**, None

## References

- Alzheimer's Disease International. World Alzheimer Report 2015: The Global Impact of Dementia. An Analysis of Prevalence, Incidence, Cost and Trends. Available at: <https://www.alz.co.uk/research/world-report-2015>.
- Ballard C, Gauthier S, Corbett A, Brayne C, Aarsland D, Jones E. Alzheimer's disease. *Lancet*. 2011;377:1019–1031.
- Scheltens P, Blennow K, Breteler MMB, de Strooper B, Frisoni GB, Salloway S, et al. Alzheimer's disease. *Lancet*. 2016;388:505–517.
- Hardy J, Selkoe DJ. The amyloid hypothesis of Alzheimer's disease: progress and problems on the road to therapeutics. *Science*. 2002;297:353–356.
- Friedman R. Aggregation of amyloids in a cellular context: modelling and experiment. *Biochem J*. 2011;438:415–426.
- Iwata N, Tsubuki S, Takaki Y, et al. Metabolic regulation of brain A $\beta$  by neprilysin. *Science*. 2001;292:1550–1552.
- Marr RA, Hafez DM. Amyloid-beta and Alzheimer's disease: the role of neprilysin-2 in amyloid-beta clearance. *Front Aging Neurosci*. 2014;6:187.
- Villemagne VL, Burnham S, Bourgeat P, et al. Amyloid beta deposition, neurodegeneration, and cognitive decline in sporadic Alzheimer's disease: a prospective cohort study. *Lancet Neurol*. 2013;12:357–367.
- Villemagne VL, Pike KE, Chetelat G, et al. Longitudinal assessment of Abeta and cognition in aging and Alzheimer disease. *Ann Neurol*. 2011;69:181–192.
- Vos SJ, Xiong C, Visser PJ, et al. Preclinical Alzheimer's disease and its outcome: a longitudinal cohort study. *Lancet Neurol*. 2013;12:957–965.
- Ayton S, Fazlollahi A, Bourgeat P, et al. Cerebral quantitative susceptibility mapping predicts amyloid-beta-related cognitive decline. *Brain*. 2017;140:2112–2119.
- Pietrzak RH, Lim YY, Ames D, et al. Trajectories of memory decline in preclinical Alzheimer's disease: results from the Australian Imaging, Biomarkers and Lifestyle Flagship Study of ageing. *Neurobiol Aging*. 2015;36:1231–1238.
- Nakamura A, Kaneko N, Villemagne VL, et al. High performance plasma amyloid-beta biomarkers for Alzheimer's disease. *Nature*. 2018;554:249–254.
- Cheung CY, Ikram MK, Chen C, Wong TY. Imaging retina to study dementia and stroke. *Prog Retin Eye Res*. 2017;57:89–107.
- Lim JKH, Li QX, He Z, et al. The eye as a biomarker for Alzheimer's disease. *Front Neurosci*. 2016;10:536.
- van Wijngaarden P, Hadoux X, Alwan M, Keel S, Dirani M. Emerging ocular biomarkers of Alzheimer disease. *Clin Exp Ophthalmol*. 2017;45:54–61.
- Koronyo Y, Biggs D, Barron E, et al. Retinal amyloid pathology and proof-of-concept imaging trial in Alzheimer's disease. *JCI Insight*. 2017;2:1–19.
- Frost S, Kanagasigam Y, Sohrabi H, et al. Retinal vascular biomarkers for early detection and monitoring of Alzheimer's disease. *Transl Psychiatry*. 2013;3:e233.
- Feke GT, Hyman BT, Stern RA, Pasquale LR. Retinal blood flow in mild cognitive impairment and Alzheimer's disease. *Alzheimers Dement (Amst)*. 2015;1:144–151.
- Fotiou F, Fountoulakis K, Tsolaki M, Goulas A, Palikaras A. Changes in pupil reaction to light in Alzheimer's disease patients: a preliminary report. *Int J Psychophysiol*. 2000;37:111–120.
- Frost SM, Kanagasigam Y, Sohrabi HR, et al. Pupil response biomarkers distinguish amyloid precursor protein mutation carriers from non-carriers. *Curr Alzheimer Res*. 2013;10:790–796.
- Prettyman R, Bitsios P, Szabadi E. Altered pupillary size and darkness and light reflexes in Alzheimer's disease. *J Neurol Neurosurg Psychiatry*. 1997;62:665–668.
- Riordan-Eva P. Anatomy and embryology of the eye. In: Augsburger JJ, Riordan-Eva P, eds. *Vaughan & Asbury's General Ophthalmology*. 18th ed. New York: The McGraw-Hill; 2011:1–26.
- Kerbage C, Sadowsky CH, Tariot PN, et al. Detection of amyloid beta signature in the lens and its correlation in the brain to aid in the diagnosis of Alzheimer's disease. *Am J Alzheimers Dis Other Dement*. 2015;30:738–745.
- Goldstein LE, Muffat JA, Cherny RA, et al. Cytosolic beta-amyloid deposition and supranuclear cataracts in lenses from people with Alzheimer's disease. *Lancet*. 2003;361:1258–1265.



26. Skalicky SE. The anterior eye. In: *Ocular and Visual Physiology: Clinical Application*. Singapore: Springer Singapore; 2016:47-83.
27. Michael R, Bron AJ. The ageing lens and cataract: a model of normal and pathological ageing. *PhilosTrans R Soc Lond B Biol Sci*. 2011;366:1278-1292.
28. Srivastava OP. Age-related increase in concentration and aggregation of degraded polypeptides in human lenses. *Exp Eye Res*. 1988;47:525-543.
29. Frederikse PH, Garland D, Zigler JS, Piatigorsky J. Oxidative stress increases production of  $\beta$ -amyloid precursor protein and  $\beta$ -amyloid ( $A\beta$ ) in mammalian lenses, and  $A\beta$  has toxic effects on lens epithelial cells. *J Biol Chem*. 1996;271:10169-10174.
30. Prakasam A, Muthuswamy A, Ablonczy Z, et al. Differential accumulation of secreted  $A\beta$ PP metabolites in ocular fluids. *J Alzheimers Dis*. 2010;20:1243-1253.
31. Frederikse PH, Zigler JS Jr. Presenilin expression in the ocular lens. *Curr Eye Res*. 1998;17:947-952.
32. Zhang Q, Yang G, Li W, et al. Thiamine deficiency increases beta-secretase activity and accumulation of beta-amyloid peptides. *Neurobiol Aging*. 2011;32:42-53.
33. Karuppagounder SS, Xu H, Shi Q, et al. Thiamine deficiency induces oxidative stress and exacerbates the plaque pathology in Alzheimer's mouse model. *Neurobiol Aging*. 2009;30:1587-1600.
34. Gold M, Chen MF, Johnson K. Plasma and red blood cell thiamine deficiency in patients with dementia of the Alzheimer's type. *Arch Neurol*. 1995;52:1081-1086.
35. Frederikse PH, Farnsworth P, Zigler JS. Thiamine deficiency in vivo produces fiber cell degeneration in mouse lenses. *Biochem Biophys Res Commun*. 1999;258:703-707.
36. Lamba OP, Borchman D, Sinha SK, Shah J, Renugopalakrishnan V, Yappert MC. Estimation of the secondary structure and conformation of bovine lens crystallins by infrared spectroscopy: quantitative analysis and resolution by Fourier self-deconvolution and curve fit. *Biochim Biophys Acta*. 1993;1163:113-123.
37. Thomas DM, Schepler KL. Raman spectra of normal and ultraviolet-induced cataractous rabbit lens. *Invest Ophthalmol Vis Sci*. 1980;19:904-912.
38. Frederikse PH. Amyloid-like protein structure in mammalian ocular lenses. *Curr Eye Res*. 2000;20:462-468.
39. Frederikse PH, Ren XO. Lens defects and age-related fiber cell degeneration in a mouse model of increased  $A\beta$ PP gene dosage in Down syndrome. *Am J Pathol*. 2002;161:1985-1990.
40. Dutescu RM, Li QX, Crowston J, Masters CL, Baird PN, Culvenor JG. Amyloid precursor protein processing and retinal pathology in mouse models of Alzheimer's disease. *Graefes Arch Clin Exp Ophthalmol*. 2009;247:1213-1221.
41. Li G, Percontino L, Sun Q, Qazi AS, Frederikse PH. Beta-amyloid secretases and beta-amyloid degrading enzyme expression in lens. *Mol Vis*. 2003;9:179-183.
42. Moncaster JA, Pineda R, Moir RD, et al. Alzheimer's disease amyloid-beta links lens and brain pathology in Down syndrome. *PLoS One*. 2010;5:e10659.
43. Michael R, Rosandic J, Montenegro GA, et al. Absence of beta-amyloid in cortical cataracts of donors with and without Alzheimer's disease. *Exp Eye Res*. 2013;106:5-13.
44. Michael R, Otto C, Lenferink A, et al. Absence of amyloid-beta in lenses of Alzheimer patients: a confocal Raman microspectroscopic study. *Exp Eye Res*. 2014;119(suppl C):44-53.
45. Ho CY, Troncoso JC, Knox D, Stark W, Eberhart CG. Beta-amyloid, phospho-tau and alpha-synuclein deposits similar to those in the brain are not identified in the eyes of Alzheimer's and Parkinson's disease patients. *Brain Pathol*. 2014;24:25-32.
46. Williams EA, McGuone D, Frosch MP, Hyman BT, Laver N, Stemmer-Rachamimov A. Absence of Alzheimer disease neuropathologic changes in eyes of subjects with Alzheimer disease. *J Neuropathol Exp Neurol*. 2017;76:376-383.
47. Kerbage C, Sadowsky CH, Jennings D, Cagle GD, Hartung PD. Alzheimer's disease diagnosis by detecting exogenous fluorescent signal of ligand bound to Beta amyloid in the lens of human eye: an exploratory study. *Front Neurol*. 2013;4:62.
48. DelMonte DW, Kim T. Anatomy and physiology of the cornea. *J Cataract Refract Surg*. 2011;37:588-598.
49. Farjo A, Brumm M, Soong H. Corneal anatomy, physiology and wound healing. In: Yanoff M, Duker JS, eds. *Ophthalmology*. Elsevier Inc.; 2014:163-167.
50. Marfurt CF, Cox J, Deek S, Dvorscak L. Anatomy of the human corneal innervation. *Exp Eye Res*. 2010;90:478-492.
51. Müller LJ, Marfurt CF, Kruse F, Tervo TMT. Corneal nerves: structure, contents and function. *Exp Eye Res*. 2003;76:521-542.
52. True Gabelt BA, Kaufman PL. Production and flow of aqueous humor. In: Levin L, Nilsson S, Ver Hoeve J, Wu S, Kaufman P, Alm A, eds. *Adler's Physiology of the Eye*. Saunders, Elsevier; 2011:274-308.
53. Bowling B. *Kanski's Clinical Ophthalmology: A Systematic Approach*. Elsevier; 2016:216-224.
54. Klintworth GK. Corneal dystrophies. *Orphanet J Rare Dis*. 2009;4:7.
55. Stix B, Leber M, Bingemer P, Gross C, et al. Hereditary lattice corneal dystrophy is associated with corneal amyloid deposits enclosing C-terminal fragments of keratoepithelin. *Invest Ophthalmol Vis Sci*. 2005;46:1133-1139.
56. Davson H. A comparative study of the aqueous humour and cerebrospinal fluid in the rabbit. *J Physiol*. 1955;129:111-133.
57. Lei G, Zhefeng G. Alzheimer's  $A\beta$ 42 and  $A\beta$ 40 peptides form interlaced amyloid fibrils. *J Neurochem*. 2013;126:305-311.
58. Shorena J, Henrik Z, Niklas M, et al. CSF  $A\beta$ 42/ $A\beta$ 40 and  $A\beta$ 42/ $A\beta$ 38 ratios: better diagnostic markers of Alzheimer disease. *Ann Clin Transl Neurol*. 2016;3:154-165.
59. Janciauskiene S, Krakau T. Alzheimer's peptide and serine proteinase inhibitors in glaucoma and exfoliation syndrome. *Doc Ophthalmol*. 2003;106:215-223.
60. Inoue T, Kawaji T, Tanihara H. Elevated levels of multiple biomarkers of Alzheimer's disease in the aqueous humor of eyes with open-angle glaucoma. *Invest Ophthalmol Vis Sci*. 2013;54:5353-5468.
61. Janciauskiene S, Westin K, Grip O, Krakau T. Detection of Alzheimer peptides and chemokines in the aqueous humor. *Eur J Ophthalmol*. 2011;21:104-111.
62. Lesiewska H, Malukiewicz G, Bagniewska-Iwanier M, Mańkowska-Cyl A, Sypniewska G. Amyloid  $\beta$  peptides and cognitive functions in patients with pseudoexfoliation syndrome. *Curr Eye Res*. 2016;41:662-666.
63. De Clerck EE, Schouten JS, Berendschot TT, et al. New ophthalmologic imaging techniques for detection and monitoring of neurodegenerative changes in diabetes: a systematic review. *Lancet Diabetes Endocrinol*. 2015;3:653-663.
64. Pritchard N, Edwards K, Dehghani C, et al. Longitudinal assessment of neuropathy in type 1 diabetes using novel ophthalmic markers (LANDMark: study design and baseline characteristics). *Diabetes Res Clin Pract*. 2014;104:248-256.
65. Petropoulos IN, Alam U, Fadavi H, et al. Rapid automated diagnosis of diabetic peripheral neuropathy with in vivo corneal confocal microscopy. *Invest Ophthalmol Vis Sci*. 2014;55:2071-2078.

66. Asghar O, Petropoulos IN, Alam U, et al. Corneal confocal microscopy detects neuropathy in subjects with impaired glucose tolerance. *Diabetes Care*. 2014;37:2643-2646.
67. Tavakoli M, Quattrini C, Abbott C, et al. Corneal confocal microscopy: a novel noninvasive test to diagnose and stratify the severity of human diabetic neuropathy. *Diabetes Care*. 2010;33:1792-1797.
68. Brines M, Dunne AN, van Velzen M, et al. ARA 290, a nonerythropoietic peptide engineered from erythropoietin, improves metabolic control and neuropathic symptoms in patients with type 2 diabetes. *Mol Med*. 2014;20:658-666.
69. Pritchard N, Edwards K, Russell AW, Perkins BA, Malik RA, Efron N. Corneal confocal microscopy predicts 4-year incident peripheral neuropathy in type 1 diabetes. *Diabetes Care*. 2015;38:671-675.
70. Dehghani C, Pritchard N, Edwards K, et al. Natural history of corneal nerve morphology in mild neuropathy associated with type 1 diabetes: development of a potential measure of diabetic peripheral neuropathy. *Invest Ophthalmol Vis Sci*. 2014;55:7982-7990.
71. Campagnolo M, Lazzarini D, Fregona I, et al. Corneal confocal microscopy in patients with chemotherapy-induced neuropathy (P3.311). *Neurology*. 2014;82(suppl 10):P3.311.
72. Ferrari G, Gemignani F, Macaluso C. Chemotherapy-associated peripheral sensory neuropathy assessed using in vivo corneal confocal microscopy. *Arch Neurol*. 2010;67:364-365.
73. Anjos R, Vieira L, Sousa A, Maduro V, Alves N, Candelaria P. Peripheral neuropathy in Parkinson disease: an in vivo confocal microscopy study. *Acta Ophthalmol (Copenh)*. 2014;92:51.
74. Kass-Iliyya L, Javed S, Gosal D, et al. Small fiber neuropathy in Parkinson's disease: a clinical, pathological and corneal confocal microscopy study. *Parkinsonism Relat Disord*. 2015;21:1454-1460.
75. Podgorny PJ, Suchowersky O, Romanchuk KG, Feasby TE. Evidence for small fiber neuropathy in early Parkinson's disease. *Parkinsonism Relat Disord*. 2016;28:94-99.
76. Mikolajczak J, Zimmermann H, Kheirkhah A, et al. Patients with multiple sclerosis demonstrate reduced subbasal corneal nerve fibre density. *Mult Scler*. 2017;23:1847-1853.
77. Bitirgen G, Akpınar Z, Malik RA, Ozkagnici A. Use of corneal confocal microscopy to detect corneal nerve loss and increased dendritic cells in patients with multiple sclerosis. *JAMA Ophthalmol*. 2017;135:777-782.
78. Aloe L, Rocco ML, Bianchi P, Manni L. Nerve growth factor: from the early discoveries to the potential clinical use. *J Transl Med*. 2012;10:239.
79. Bruno MA, Leon WC, Fragoso G, Mushynski WE, Almazan G, Cuello AC. Amyloid beta-induced nerve growth factor dysmetabolism in Alzheimer disease. *J Neuropathol Exp Neurol*. 2009;68:857-869.
80. Lambiase A, Manni L, Bonini S, Rama P, Micera A, Aloe L. Nerve growth factor promotes corneal healing: structural, biochemical, and molecular analyses of rat and human corneas. *Invest Ophthalmol Vis Sci*. 2000;41:1063-1069.
81. Lambiase A, Bonini S, Micera A, Rama P, Aloe L. Expression of nerve growth factor receptors on the ocular surface in healthy subjects and during manifestation of inflammatory diseases. *Invest Ophthalmol Vis Sci*. 1998;39:1272-1275.
82. Bonini S, Lambiase A, Rama P, Caprioglio G, Aloe L. Topical treatment with nerve growth factor for neurotrophic keratitis. *Ophthalmology*. 2000;107:1347-1351.
83. Edwards K, Pritchard N, Poole C, et al. Development of a novel technique to measure corneal nerve migration rate. *Cornea*. 2016;35:700-705.
84. Efron N, Al-Dossari M, Pritchard N. In vivo confocal microscopy of the bulbar conjunctiva. *Clin Experiment Ophthalmol*. 2009;37:335-344.
85. Skodras G, Peng J, Parker J, Kragel P. Immunohistochemical localization of amyloid beta-protein deposits in extracerebral tissues of patients with Alzheimer's disease. *Ann Clin Lab Sci*. 1993;23:275-280.



Minerva Access is the Institutional Repository of The University of Melbourne

**Author/s:**

Dehghani, C; Frost, S; Jayasena, R; Masters, CL; Kanagasingam, Y

**Title:**

Ocular Biomarkers of Alzheimer's Disease: The Role of Anterior Eye and Potential Future Directions

**Date:**

2018-07-01

**Citation:**

Dehghani, C; Frost, S; Jayasena, R; Masters, CL; Kanagasingam, Y, Ocular Biomarkers of Alzheimer's Disease: The Role of Anterior Eye and Potential Future Directions, INVESTIGATIVE OPHTHALMOLOGY & VISUAL SCIENCE, 2018, 59 (8), pp. 3554 - 3563

**Persistent Link:**

<http://hdl.handle.net/11343/220542>

**File Description:**

Published version