

Renal Structure in Normoalbuminuric and Albuminuric Patients With Type 2 Diabetes and Impaired Renal Function

ELIF I. EKINCI, PHD^{1,2,3}
 GEORGE JERUMS, MD^{1,2}
 ALISON SKENE, MBBS⁴
 PAUL CRAMMER, BAPPSC⁵
 DAVID POWER, PHD^{2,6}
 KAREY Y. CHEONG, BSC¹

SIANNA PANAGIOTOPOULOS, PHD¹
 KAREN McNEIL, MBBS¹
 SCOTT T. BAKER, MBBS^{1,2}
 PAOLA FIORETTO, MD⁷
 RICHARD J. MACISAAC, PHD⁸

OBJECTIVE—The structural basis of normoalbuminuric renal insufficiency in patients with type 2 diabetes remains to be elucidated. We compared renal biopsy findings in patients with type 2 diabetes and estimated glomerular filtration rate (eGFR) and measured GFR of <60 mL/min/1.73 m², associated with either normo-, micro-, or macroalbuminuria.

RESEARCH DESIGN AND METHODS—In patients with normo- ($n = 8$) or microalbuminuria ($n = 6$), renal biopsies were performed according to a research protocol. In patients with macroalbuminuria ($n = 17$), biopsies were performed according to clinical indication. Findings were categorized according to the Fioretto classification: category 1 (C1), normal/near normal; category 2 (C2), typical diabetic nephropathy (DN) with predominantly glomerular changes; and category 3 (C3), atypical with disproportionately severe interstitial/tubular/vascular damage and with no/mild diabetic glomerular changes.

RESULTS—In our study population (mean eGFR 35 mL/min/1.73 m²), typical glomerular changes (C2) of DN were observed in 22 of 23 subjects with micro- or macroalbuminuria compared with 3 of 8 subjects with normoalbuminuria ($P = 0.002$). By contrast, predominantly interstitial or vascular changes (C3) were seen in only 1 of 23 subjects with micro- or macroalbuminuria compared with 3 of 8 normoalbuminuric subjects ($P = 0.08$). Mesangial area increased progressively from normal controls to patients with type 2 diabetes and normo-, micro-, and macroalbuminuria. Varying degrees of arteriosclerosis, although not necessarily the predominant pattern, were seen in seven of eight subjects with normoalbuminuria.

CONCLUSIONS—Typical renal structural changes of DN were observed in patients with type 2 diabetes and elevated albuminuria. By contrast, in normoalbuminuric renal insufficiency, these changes were seen less frequently, likely reflecting greater contributions from aging, hypertension, and arteriosclerosis.

Diabetes Care 36:3620–3626, 2013

In diabetic kidney disease (DKD), incipient diabetic nephropathy (DN) is classically defined by increasing albuminuria, heralding a decline in glomerular filtration rate (GFR) (1), which usually does not occur until the transition to

macroalbuminuria (overt DN). However, a proportion of patients with either type 1 or type 2 diabetes does not follow this classical albuminuric pathway, instead showing declining renal function in the absence of an elevated albumin excretion rate (AER)

(2,3). Previously, we have reported that up to 25% of patients with type 1 or type 2 diabetes have reduced renal function in the setting of a normal AER (<20 μ g/min) (3). Others have also reported a reduction in GFR with normoalbuminuria in patients with type 1 diabetes (4). Subsequent studies have further demonstrated this dissociation between decreased GFR and increased albuminuria in patients with type 2 or type 1 diabetes (5–9).

In patients with type 1 diabetes and reduced GFR, classic glomerular changes of DKD have been described regardless of albuminuria status (2,10). By contrast, in patients with type 2 diabetes and DKD, regardless of the level of GFR or urinary AER, renal biopsy findings are generally accepted to be more heterogeneous than in type 1 diabetes. One study by Fioretto et al. (11) of subjects with type 2 diabetes, microalbuminuria (AER 20–200 μ g/min) and preserved GFR showed heterogeneous changes on renal biopsy. These changes were classifiable into three categories: category 1 (C1), defined by normal or near-normal renal structure, category 2 (C2), typical DN with predominantly glomerular changes, and category 3 (C3), defined by disproportionately severe interstitial, tubular, or vascular damage and few or no glomerular changes.

To date, few studies have compared renal biopsy findings in subjects with type 2 diabetes, reduced GFR, and different degrees of albuminuria, and as a result, the histological basis of normoalbuminuric DKD remains poorly understood. The aim of this study, therefore, was to investigate renal biopsy findings in subjects with type 2 diabetes and impaired renal function (measured or estimated GFR [eGFR] <60 mL/min/1.73 m²) associated with normo-, micro-, or macroalbuminuria.

RESEARCH DESIGN AND METHODS

Patients and procedures

Patients attending the Diabetes Clinics at Austin Health routinely undergo regular measurements of renal function and 24-h urine collections for assessment of AER.

From the ¹Endocrine Centre, Austin Health, Melbourne, Victoria, Australia; the ²Department of Medicine, Austin Health, University of Melbourne, Melbourne, Victoria, Australia; the ³Menzies School of Health Research, Darwin, Northern Territory, Australia; the ⁴Anatomical Pathology, Austin Health, Melbourne, Victoria, Australia; the ⁵Anatomical Pathology, Southern Health, Melbourne, Victoria, Australia; the ⁶Department of Nephrology, Austin Health, Melbourne, Victoria, Australia; the ⁷Department of Internal Medicine, University of Padova, Padova, Italy; and the ⁸Department of Endocrinology and Diabetes, St. Vincent's Health Fitzroy and University of Melbourne, Melbourne, Victoria, Australia.

Corresponding author: Elif I. Ekinci, elif.ekinci@unimelb.edu.au.

Received 11 December 2012 and accepted 30 April 2013.

DOI: 10.2337/dc12-2572

A slide set summarizing this article is available online.

© 2013 by the American Diabetes Association. Readers may use this article as long as the work is properly cited, the use is educational and not for profit, and the work is not altered. See <http://creativecommons.org/licenses/by-nc-nd/3.0/> for details.

Study Protocol

Biopsy type	Research	Research	Clinical
GFR (mL/min/1.73 m ²)	<60	<60	<60
AER category	Normo	Micro	Macro
Pre biopsy (n)	10	4	17
At biopsy (n)	8	2 + 4	17

Figure 1—Study protocol. Fourteen patients had research renal biopsies, and 17 patients with macroalbuminuria had renal biopsies for clinical reasons. As part of the study protocol, after ceasing RAS inhibitor therapy for 4–6 weeks prebiopsy, 2 out of 10 patients with normoalbuminuria developed microalbuminuria (“pseudonormoalbuminuria”), making the total number of patients with normoalbuminuria eight and with microalbuminuria six. Normo, normoalbuminuria; micro, microalbuminuria; macro; macroalbuminuria.

Patients with impaired renal function (eGFR <60 mL/min/1.73 m² using Modification of Diet in Renal Disease formula) and AER within the normoalbuminuric (<20 μg/min in two out of three consecutive 24-h urine collections) or microalbuminuric range (<200 μg/min in two out of three consecutive 24-h urine collections) were invited to participate in the study.

Between 2005 and 2010, research renal biopsies were performed in patients with normoalbuminuria and microalbuminuria. In the same period, clinically indicated biopsies were performed in macroalbuminuric patients with eGFR <60 mL/min/1.73 m². The study was approved by the Human Research Ethics Committee at Austin Health.

In patients with normo- or microalbuminuria, renal biopsies were performed according to a research protocol,

and eGFR was supplemented with isotopic ^{99m}Tc-diethylene triamine penta acetic acid (DTPA) measurement of GFR. Patients with normoalbuminuria or microalbuminuria receiving a renin-angiotensin system (RAS) inhibitor had this therapy withheld for 4–6 weeks prebiopsy. These medications were withheld prebiopsy in order to exclude the presence of normoalbuminuria due to RAS blockade, so called “pseudonormoalbuminuria.” During this period, patients were reviewed at two weekly intervals. If blood pressure increased to >140/80 mmHg, alternative, non-RAS antihypertensive agents were used to control blood pressure. Albuminuria status was then reassessed with a repeat 24-h urine collection prebiopsy.

Patients fasted from midnight the night before the renal biopsy and were

admitted to the Day Treatment Centre, Austin Health. An intravenous cannula was inserted. A 14-gauge TruCut biopsy needle was inserted into the kidney under real-time ultrasound guidance and one or two 1–2 cm cores of tissue were withdrawn.

Light and electron microscopy studies

Tissue for light microscopy (LM) was prepared using standard techniques (formalin fixation, processing to paraffin wax, sections cut at 1-μm thickness, stained with hematoxylin and eosin, periodic acid–Schiff, Masson’s trichrome, and silver impregnation). Sections for either immunofluorescence (using frozen tissue) or immunoperoxidase (using paraffin-embedded tissue) were stained with antibodies to immunoglobulins and complement. Tissue for electron microscopy (EM) was prepared by fixation in 2.5% glutaraldehyde and resin embedded, and ultrathin sections were examined on a Jeol transmission electron microscope. Basic renal morphology was assessed at LM, including semiquantitative assessment of global glomerulosclerosis (GS) (GS score 0 = <10%, 1 = 10–25%, 2 = 26–50%, and 3 = >50%), glomerular mesangial expansion (score 0 = none or mild and focal, 1 = mild and diffuse, 2 = obvious and diffuse, and 3 = nodular), tubular atrophy (TA), interstitial fibrosis (IF) (TA/IF score 0 = <5% biopsy area, 1 = 5–25%, 2 = 26–50%, and 3 = >50%), arteriosclerosis (score 0 = none, 1 = vascular narrowing

Table 1—Baseline characteristics of the study participants

Group	Normoalbuminuria (n = 8)	Microalbuminuria (n = 6)	Macroalbuminuria (n = 17)	P value
Sex	3 M, 5 F	5 M, 1 F	14 M, 3 F	0.053
Age (years)	67 ± 2.0	69 ± 2.8	63 ± 2.0	0.159
Duration (years)	12 ± 2.4	12 ± 3.5	18 ± 2.1	0.175
BMI (kg/m ²)	34 ± 1.6	33 ± 2.7	31 ± 1.7	0.508
Smoking	0/8	3/6	2/17	0.047
Retinopathy (proliferative or nonproliferative diabetic retinopathy)	4/8	3/6	13/17	0.236
AER (μg/min)	7.9 ± 1.2	113 ± 19	2,087 ± 336	
eGFR (mL/min/1.73 m ²)	41 ± 3.0	48 ± 4	31 ± 3	0.004
Brochner-Mortensen corrected DTPA GFR (mL/min/1.73 m ²)	47 ± 7 (performed in 5 of 8 patients)	49 ± 2 (performed in 5 of 6 patients)	Not performed	
HbA _{1c} (%) (mmol/mol)	6.8 ± 0.2	8.0 ± 0.5	7.3 ± 0.4	0.354
	51 ± 2.2	64 ± 5.5	56 ± 4.4	
Triglycerides (mmol/L)	2.6 ± 0.4	1.8 ± 0.3	2.5 ± 0.4	0.519
Cholesterol (mmol/L)	4.4 ± 0.2	4.1 ± 0.4	4.7 ± 0.3	0.529

Data shown as mean ± SD. P values obtained from ANOVA (continuous variables) or Fisher exact (categorical variables) tests. F, female; M, male.

Table 2—Renal structure patterns in patients with type 2 diabetes

Albuminuria category	Normoalbuminuria			Microalbuminuria			Macroalbuminuria		
Fioretto et al. (11)									
GFR >60 mL/min/1.73 m ² (mean GFR 101 ± 27 mL/min/1.73 m ²)				n = 34					
Number of subjects per category				C1	C2	C3			
				10	10	14			
Current study									
GFR <60 mL/min/1.73 m ²	n = 8			n = 6			n = 17		
Mean MDRD eGFR (mL/min/1.73 m ²)	41 ± 3.0			48 ± 4			31 ± 3		
Number of subjects per category	C1	C2	C3	C1	C2	C3	C1	C2	C3
	2	3	3	0	5	1	0	17	0

C1, defined by normal or near-normal histology; C2, defined by histology reflecting typical DN with predominantly glomerular changes; C3, defined by atypical histology, with disproportionately severe interstitial, tubular, or vascular damage and few or no glomerular changes; MDRD, Modification of Diet in Renal Disease.

of <25% luminal area in the most affected vessel, 2 = 26–50% narrowing, and 3 = >50% narrowing), and arteriolar hyalinosis (score 0 = none, 1 = mild to moderate in at least one arteriole, 2 = moderate to severe in >1 arteriole, and 3 = severe in many arterioles). Evidence of glomerulonephritis and other nondiabetic causes for renal impairment was sought. All biopsies contained sufficient glomeruli for diagnostic evaluation. EM assessment included quantitation of glomerular basement membrane (GBM) thickness and mesangial area (by computer-assisted measurement using Digimizer (version 4.2.2) image analysis software (MedCalc Software, Ostend, Belgium). Mesangial area was obtained using an on-screen drawing tool to define the boundaries of each mesangial area. Transverse sections through the middle of representative glomeruli were chosen. For each subject, all identifiable mesangial area per glomerulus was measured. The mean mesangial in a

glomerulus per subject was calculated. The normal range of mesangial area was calculated from examination of nondiabetic control patients from our institution in whom biopsies were performed for clinical reasons and showed qualitatively normal mesangium and in some cases thin basement membrane disease. LM was assessed by two experienced renal pathologists, and by consensus, each biopsy was classified according to the three patterns of renal injury described for microalbuminuric patients with type 2 diabetes, i.e., normal or near-normal renal structure (C1), “typical” DN (C2), and “atypical” patterns of renal injury (C3), with absent or mild diabetic glomerular changes associated with disproportionately severe tubulointerstitial lesions, arteriolar hyalinosis, and/or global GS (11).

Statistical analysis

One-way ANOVA was used to test for differences among micro-, normo-, and

macroalbuminuric groups for continuous variables, which are reported as mean ± SD. Categorical variables were analyzed using the χ^2 test or Fisher exact test. Statistical significance was assigned at the $P < 0.05$ level. Microsoft Excel and SPSS version 16.0 were used for the statistical analyses.

RESULTS—Fourteen patients had research renal biopsies, and 17 patients with macroalbuminuria had renal biopsies for clinical reasons (Fig. 1 and Table 1). As part of the study protocol, after ceasing RAS inhibitor therapy for 4–6 weeks pre-biopsy, 2 out of 10 patients with normoalbuminuria developed microalbuminuria (“pseudonormoalbuminuria”), making the total number of patients with normoalbuminuria eight and microalbuminuria six (Fig. 1).

The baseline characteristics of the study participants are shown in Table 1. There was a trend for a higher proportion of women in the normoalbuminuria group ($P = 0.05$). There were more smokers ($P < 0.05$) in the microalbuminuria group. The eGFR was lower in the macroalbuminuria group ($P < 0.005$). Otherwise there were no statistical differences between the groups. Eighty percent of the study population had hypertension.

Renal structural patterns in the 31 patients in the current study are shown in Table 2. We identified typical glomerular changes of DN (C2) in 22 of 23 patients: 5 of 6 patients with microalbuminuria (mean eGFR 48 mL/min/1.73 m²) and 17 of 17 patients with macroalbuminuria (mean eGFR 31 mL/min/1.73 m²), compared with 3 of 8 patients with normoalbuminuria (mean eGFR 31 mL/min/1.73 m², $P = 0.0002$, Fisher exact test). In the study group as a whole with a mean eGFR

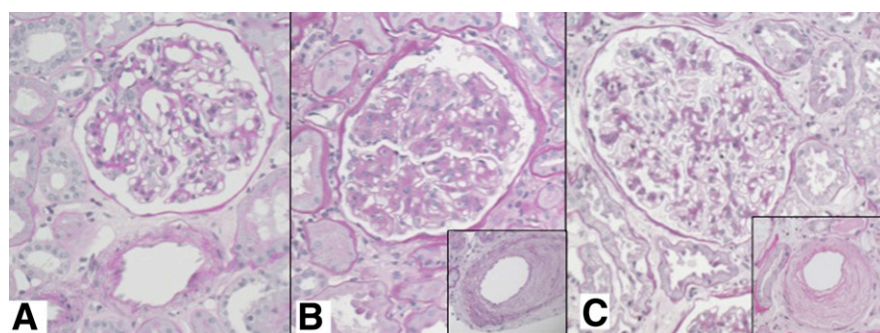


Figure 2—Histological appearances representative of normoalbuminuric cases. A: Patient 1, from Table 3, demonstrating normal glomerulus and arteries, Fioretto C1. B: Patient 3, from Table 3, demonstrating advanced diabetic GS and arteriosclerosis (inset), Fioretto C2. C: Patient 8, from Table 3, demonstrating minimal glomerular mesangial expansion and severe arteriosclerosis (inset), Fioretto C3 (all images periodic acid-Schiff stain, original magnification $\times 200$).

of 35 mL/min/1.73 m², a predominantly glomerular pattern (C2) was seen in 25 of 31 patients.

Considering subjects with normoalbuminuria, three out of eight had changes consistent with typical DN (C2). Early diabetic changes on LM or EM (mild diffuse mesangial expansion and/or GBM thickening) were seen in two out of eight and one had advanced nodular diabetic GS (C2). Predominantly interstitial or vascular changes (C3) were seen in 3 of 8 normoalbuminuric patients, and only 1 of 23 patients with micro- or macroalbuminuria ($P = 0.08$, Fisher exact test). The remaining two out of eight patients with normoalbuminuria had nonspecific changes (C1). The histological appearance representative of normoalbuminuric cases are shown in Fig. 2. None of the biopsies from normoalbuminuric patients were entirely normal. Varying degrees of arteriosclerosis, although not necessarily the predominant pattern, were seen in seven out of eight patients with normoalbuminuria (including patient number 8 with mild glomerular diabetic changes and disproportionate vascular and tubulointerstitial damage) (Table 3).

Of the 17 patients with macroalbuminuria, most ($n = 11$) had a rapid renal function decline or increase in albuminuria and had biopsies performed for clinical reasons. Some ($n = 5$) had clinical features suggestive of a glomerulonephritis (such as hematuria, positive anti-nuclear antibodies serology, or cryoglobulinemia). One had clinical features suggestive of amyloidosis. In four patients, there were also biopsy changes raising the possibility of acute interstitial nephritis. One had features of coexistent IgA nephropathy. Despite these clinical suspicions, we found typical advanced DN with prominent glomerular changes (diffuse or nodular GS), balanced with tubulointerstitial injury, arteriosclerosis, and arteriolar hyalinosis, in all 17 patients with macroalbuminuria.

Mesangial area was measured in a subgroup with EM images (normoalbuminuria [$n = 6$], microalbuminuria [$n = 3$], and macroalbuminuria [$n = 8$]) and compared with nondiabetic control patients ($n = 6$). The mean mesangial area in a glomerulus per subject was calculated (mean of 12 measurements of mesangial area per subject). Mesangial area was significantly different across the four groups (one-way ANOVA, $P = 0.02$). Mesangial area increased progressively from normal controls to patients with type 2 diabetes and

Table 3—Biopsy findings in participants with normoalbuminuria

Patient study number	Fioreto category	ICC	GS score (0–3)	Mesangial expansion (0–3)	TAMF (0–3)	Arteriolar hyalinosis (0–3)	Arteriosclerosis (0–3)	GBM thickness (on EM, nm)		Summary
								NR males 250–430 nm, females 230–395 nm	#	
1	C1	U	1	0	0	0	0		244 WNR	Not DN, mild IgA nephropathy, no cause for renal impairment found
2	C1	U	2	0	1	1	1		#	Mild nonspecific changes, not DN
3	C2	III	1	3	2	3	2		#	Typical advanced DN
4	C2	IIa	1	1	1	1	1		276 WNR	Typical early DN
5	C2	IIa	1	1	0	1	2		321 * ULN	Typical early DN
6	C3	U	1	0	1	2	1		260 WNR	Renovascular, not DN
7	C3	U	1	0	1	0	2		253 WNR	Renovascular, not DN
8	C3	I	3	1	3	1	3		395 >normal	Atypical DN, mild glomerular changes + severe vascular and tubulointerstitial disease

C1, defined by normal or near-normal histology; C2, defined by histology reflecting typical DN with predominantly glomerular changes; C3, defined by atypical histology, with disproportionately severe interstitial, tubular, or vascular damage and few or no glomerular changes; ICC, 2010 International Consensus Classification of DN; NR, normal range; U, unclassified; ULN, upper limit normal; WNR, within normal range. Normal range of GBM on EM reference (29), #EM not performed. * On EM, GBM had abnormal homogenized quality highly suggestive of DN.

normo-, micro-, and macroalbuminuria (Fig. 3).

CONCLUSIONS—We report that in patients with type 2 diabetes and renal insufficiency (eGFR <60 mL/min/1.73 m²), the typical glomerular changes of DN are less common in normoalbuminuric patients than in patients with micro- or macroalbuminuria. This suggests a multifactorial pathogenesis for the renal disease in these patients, with possible contributions from aging, hypertension, and vascular disease in addition to the specific contribution from diabetes.

In nearly all (22 of 23) patients with micro- or macroalbuminuria, typical glomerular changes (C2) of DN were observed. This was a significantly higher proportion than in a previous study in patients with type 2 diabetes, microalbuminuria, and a mean GFR of 101 ± 27 mL/min/1.73 m², of whom 10 of 34 patients showed a predominantly glomerular pattern of renal structural changes (Table 2, $P < 0.0001$, χ^2) (11). This is likely due to the selective recruitment of patients with eGFR <60 mL/min/1.73 m² in the current study. Since it has been demonstrated that in patients with type 2 diabetes and increased AER, the reduction

in GFR is correlated with the degree of mesangial expansion and GBM thickening (12), it is not surprising that the vast majority of patients in the current study with reduced GFR and micro- or macroalbuminuria had classic diabetic glomerulopathy. Furthermore, we found that the mesangial area increased progressively from normal control subjects to patients with type 2 diabetes and normo-, micro-, and macroalbuminuria (Fig. 3). This is consistent with the concept that mesangial expansion is related to decline in GFR in diabetes (10).

Although AER remains an important marker of DKD risk, the absence of an elevated AER does not identify patients with type 2 diabetes who are protected from a progressive decline in GFR (5). Compared with patients with similarly decreased GFR and macroalbuminuria, we have previously found that patients with normoalbuminuria were more likely to be older and female (5). In the current study, although the mean age was similar in the three groups, 5 of 8 subjects with normoalbuminuria were females, compared with 1 of 6 in the microalbuminuria and 3 of 17 in the macroalbuminuria groups. There was a predominance of typical DN (C2) in all micro- and macroalbuminuria patients. In subjects with normoalbuminuria, seven

of eight also had varying degrees of renal arteriosclerosis, implying that aging, blood pressure, and intrarenal vascular disease may be playing pathogenic roles.

Previously, we have demonstrated a role for intrarenal vascular disease in renal insufficiency in diabetes. In that study (13), patients with an eGFR <60 mL/min/1.73 m² had a higher resistance index of the renal interlobar arteries compared with patients with an eGFR ≥60 mL/min/1.73 m². Intrarenal vascular disease was associated with increased age and BMI and decreased eGFR and blood pressure. However, there was no relationship between AER status and intrarenal vascular resistance (13). It is likely that aging and hypertension are the chief contributors to the atypical nephropathy (C3) changes seen in patients with renal insufficiency and normoalbuminuria. Studies in animal models, such as the Cohen diabetic rat, may also provide further insights into normoalbuminuric DKD, because in this model, urinary protein excretion does not increase with the development of diabetes despite decreasing creatinine clearance and typical changes of DN on renal biopsy (14). However, this does not mimic the atypical pattern of renal damage with no or mild glomerular changes seen in the C3 patients.

Earlier studies of renal structure in type 2 diabetes and overt nephropathy have shown conflicting results, with some suggesting that the incidence of nondiabetic kidney disease is uncommon (15,16), similar to patients with type 1 diabetes, whereas others have reported a higher incidence of nondiabetic kidney disease in patients with type 2 diabetes (17–19). The characteristic histological lesions of DN, mesangial expansion and thickening of the GBM, correlate with rising proteinuria (20), and the decline in GFR is at least partly explained by the loss of filtration surface that accompanies mesangial expansion (20). By contrast, the structural basis of low GFR without an increase in albuminuria includes not only mesangial expansion but also tubulointerstitial and vascular changes.

Prominent interstitial pathology, including IF, TA, and mononuclear cell infiltration, correlates with renal microvascular alterations in long-standing DN, and it has been suggested that this is due to chronic ischemia (16,21,22). Furthermore, IF has been proposed as a codeterminant of decline in renal function in DN (23,24). An earlier biopsy study demonstrated atubular glomeruli and atrophic

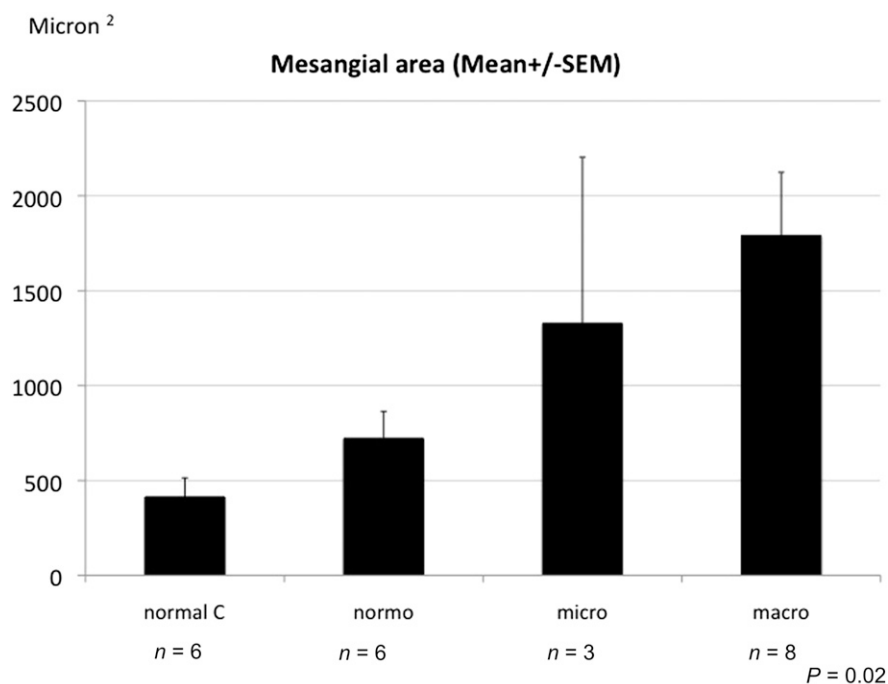


Figure 3—Mean mesangial area (micron²) across normal controls (normal C), patients with type 2 diabetes and normoalbuminuria (normo), patients with type 2 diabetes and microalbuminuria (micro), and patients with type 2 diabetes and macroalbuminuria (macro). $P = 0.02$, one-way ANOVA for mean mesangial area across the four groups.

tubules in patients with type 2 diabetes and low levels of proteinuria and suggested that both glomerular and interstitial damage may lead to the development of atubular glomeruli in patients with type 2 diabetes (20). However, in the current study, the existence of atubular glomeruli was not assessed.

The main limitation of this study is the small sample size. Although this is the first biopsy study exploring the association between normoalbuminuria and impaired renal function in patients with type 2 diabetes, this was a single-center study including only six patients with microalbuminuria. There was slow recruitment of participants in the current study due to the reluctance of both clinicians and patients to perform a renal biopsy as this is an invasive procedure with risk (25). Two of the patient renal biopsies were complicated by bleeding episodes requiring blood transfusions. In the current study, 17 of 17 patients with macroalbuminuria and type 2 diabetes undergoing a clinically indicated renal biopsy had typical changes of diabetes, suggesting that nondiabetic disease is relatively rare in these patients. This finding is in concordance with a previous study designed to evaluate the prevalence of nondiabetic renal disease in type 2 diabetes, in which 29 of 33 patients with type 2 diabetes and proteinuria had typical diabetic lesions (16). In our study, diagnostic categories were assigned based on LM appearance (according to Fioretto), supported in most cases by EM findings. Assignment to Fioretto C1 did not exclude the possibility of early mild DN, which requires quantitative EM assessment for diagnosis.

We used a classification system developed by Fioretto et al. (11), which differs from a recent classification system proposed by the Research Committee of the Renal Pathology Society (RPS), histopathological classification based purely on glomerular lesions (26). Under this classification, our normoalbuminuric cases would be assigned as unclassified (four cases), class I (one case), class IIa (two cases), and class III (one case) (see Table 3). The more severe lesions correspond to our Fioretto C2 cases, stratified by severity of diabetic glomerular changes. Two of the unclassified cases were assigned to Fioretto C3, which illustrates a shortcoming of the classification system proposed by the Research Committee of the RPS in that it underemphasizes the contribution of vascular and tubulointerstitial

injury in diabetes. Given the heterogeneity of the renal lesions underlying DN and the complex natural history of the disease, the RPS scheme is not yet ready for clinical application but should be considered an important first step toward the development of a clinically useful classification system (27). A study of 50 patients compared clinical features with the RPS classification of DN and found a decrease in mean eGFR and decreased 5-year renal survival as glomerular lesions increased from class I to IV (28).

In summary, in subjects with type 2 diabetes and reduced renal function, normoalbuminuria is associated with heterogeneous changes in renal structure. Furthermore, in patients with type 2 diabetes and reduced GFR, microalbuminuria and macroalbuminuria are associated with a predominantly glomerular pattern of renal damage, in contrast to the mixed pattern previously shown in microalbuminuric patients with type 2 diabetes and normal GFR (11). In type 2 diabetes, renal structural changes, both glomerular and nonglomerular, are more heterogeneous in normoalbuminuric than in albuminuric renal insufficiency. This suggests that aging, perturbations in blood pressure, and the development of intrarenal vascular disease may contribute to decreases in renal function independently of changes in albuminuria.

Acknowledgments—E.I.E. was supported by a National Health and Medical Research Council (NHMRC) post-graduate scholarship and an NHMRC Early Career Fellowship (1054312). This project was supported by an NHMRC project grant (266505).

No potential conflicts of interest relevant to this article were reported.

E.I.E. recruited participants, researched data, and wrote and reviewed the manuscript. G.J. researched data, applied for funding, and reviewed the manuscript. A.S., P.C., and D.P. researched data and edited the manuscript. K.Y.C. researched data and performed statistical analyses. S.P. researched data and applied for funding. K.M. recruited participants. S.T.B. recruited participants, performed statistical analyses, and reviewed the manuscript. P.F. reviewed the manuscript and contributed to the discussion. R.J.M. recruited participants, applied for funding, and reviewed the manuscript. E.I.E. and G.J. are the guarantors of this work and, as such, had full access to all the data in the study and take responsibility for the integrity of the data and the accuracy of the data analysis.

This study was presented in abstract form (guided audio poster tour) at the 72nd Scientific Sessions of the American Diabetes

Association, Philadelphia, Pennsylvania, 8–12 June 2012.

References

1. Mogensen CE. Microalbuminuria predicts clinical proteinuria and early mortality in maturity-onset diabetes. *N Engl J Med* 1984;310:356–360
2. Chavers BM, Bilous RW, Ellis EN, Steffes MW, Mauer SM. Glomerular lesions and urinary albumin excretion in type 1 diabetes without overt proteinuria. *N Engl J Med* 1989;320:966–970
3. Tsalamandris C, Allen TJ, Gilbert RE, et al. Progressive decline in renal function in diabetic patients with and without albuminuria. *Diabetes* 1994;43:649–655
4. Caramori ML, Fioretto P, Mauer M. The need for early predictors of diabetic nephropathy risk: is albumin excretion rate sufficient? *Diabetes* 2000;49:1399–1408
5. MacIsaac RJ, Tsalamandris C, Panagiotopoulos S, Smith TJ, McNeil KJ, Jerums G. Nonalbuminuric renal insufficiency in type 2 diabetes. *Diabetes Care* 2004;27:195–200
6. Retnakaran R, Cull CA, Thorne KI, Adler AI, Holman RR; UKPDS Study Group. Risk factors for renal dysfunction in type 2 diabetes: U.K. Prospective Diabetes Study 74. *Diabetes* 2006;55:1832–1839
7. Kramer HJ, Nguyen QD, Curhan G, Hsu CY. Renal insufficiency in the absence of albuminuria and retinopathy among adults with type 2 diabetes mellitus. *JAMA* 2003;289:3273–3277
8. Molitch ME, Steffes M, Sun W, et al.; Epidemiology of Diabetes Interventions and Complications Study Group. Development and progression of renal insufficiency with and without albuminuria in adults with type 1 diabetes in the diabetes control and complications trial and the epidemiology of diabetes interventions and complications study. *Diabetes Care* 2010;33:1536–1543
9. Caramori ML, Fioretto P, Mauer M. Low glomerular filtration rate in normoalbuminuric type 1 diabetic patients: an indicator of more advanced glomerular lesions. *Diabetes* 2003;52:1036–1040
10. Mauer SM, Steffes MW, Ellis EN, Sutherland DE, Brown DM, Goetz FC. Structural-functional relationships in diabetic nephropathy. *J Clin Invest* 1984;74:1143–1155
11. Fioretto P, Mauer M, Brocco E, et al. Patterns of renal injury in NIDDM patients with microalbuminuria. *Diabetologia* 1996;39:1569–1576
12. Nosadini R, Velussi M, Brocco E, et al. Course of renal function in type 2 diabetic patients with abnormalities of albumin excretion rate. *Diabetes* 2000;49:476–484
13. MacIsaac RJ, Panagiotopoulos S, McNeil KJ, et al. Is nonalbuminuric renal insufficiency

- in type 2 diabetes related to an increase in intrarenal vascular disease? *Diabetes Care* 2006;29:1560–1566
14. Yagil C, Barak A, Ben-Dor D, et al. Nonproteinuric diabetes-associated nephropathy in the Cohen rat model of type 2 diabetes. *Diabetes* 2005;54:1487–1496
 15. Waldherr R, Ilkenhans C, Ritz E. How frequent is glomerulonephritis in diabetes mellitus type II? *Clin Nephrol* 1992;37:271–273
 16. Olsen S, Mogensen CE. How often is NIDDM complicated with non-diabetic renal disease? An analysis of renal biopsies and the literature. *Diabetologia* 1996;39:1638–1645
 17. Parving HH, Gall MA, Skøtt P, et al. Prevalence and causes of albuminuria in non-insulin-dependent diabetic patients. *Kidney Int* 1992;41:758–762
 18. Gambará V, Mecca G, Remuzzi G, Bertani T. Heterogeneous nature of renal lesions in type II diabetes. *J Am Soc Nephrol* 1993;3:1458–1466
 19. Richards NT, Greaves I, Lee SJ, Howie AJ, Adu D, Michael J. Increased prevalence of renal biopsy findings other than diabetic glomerulopathy in type II diabetes mellitus. *Nephrol Dial Transplant* 1992;7:397–399
 20. White KE, Marshall SM, Bilous RW. Prevalence of atubular glomeruli in type 2 diabetic patients with nephropathy. *Nephrol Dial Transplant* 2008;23:3539–3545
 21. Bohle A, Wehrmann M, Bogenschütz O, Batz C, Müller CA, Müller GA. The pathogenesis of chronic renal failure in diabetic nephropathy. Investigation of 488 cases of diabetic glomerulosclerosis. *Pathol Res Pract* 1991;187:251–259
 22. Bader R, Bader H, Grund KE, Mackensen-Haen S, Christ H, Bohle A. Structure and function of the kidney in diabetic glomerulosclerosis. Correlations between morphological and functional parameters. *Pathol Res Pract* 1980;167:204–216
 23. Gilbert RE, Cooper ME. The tubulointerstitium in progressive diabetic kidney disease: more than an aftermath of glomerular injury? *Kidney Int* 1999;56:1627–1637
 24. Taft JL, Nolan CJ, Yeung SP, Hewitson TD, Martin FI. Clinical and histological correlations of decline in renal function in diabetic patients with proteinuria. *Diabetes* 1994;43:1046–1051
 25. Madaio MP. Renal biopsy. *Kidney Int* 1990;38:529–543
 26. Tervaert TW, Mooyaart AL, Amann K, et al.; Renal Pathology Society. Pathologic classification of diabetic nephropathy. *J Am Soc Nephrol* 2010;21:556–563
 27. Fioretto P, Mauer M. Diabetic nephropathy: diabetic nephropathy-challenges in pathologic classification. *Nat Rev Nephrol* 2010;6:508–510
 28. Oh SW, Kim S, Na KY, et al. Clinical implications of pathologic diagnosis and classification for diabetic nephropathy. *Diabetes Res Clin Pract* 2012;97:418–424
 29. Haas M. Alport syndrome and thin glomerular basement membrane nephropathy: a practical approach to diagnosis. *Arch Pathol Lab Med* 2009;133:224–232



Minerva Access is the Institutional Repository of The University of Melbourne

Author/s:

Ekinci, EI; Jerums, G; Skene, A; Crammer, P; Power, D; Cheong, KY; Panagiotopoulos, S; McNeil, K; Baker, ST; Fioretto, P; MacIsaac, RJ

Title:

Renal Structure in Normoalbuminuric and Albuminuric Patients With Type 2 Diabetes and Impaired Renal Function

Date:

2013-11-01

Citation:

Ekinci, EI; Jerums, G; Skene, A; Crammer, P; Power, D; Cheong, KY; Panagiotopoulos, S; McNeil, K; Baker, ST; Fioretto, P; MacIsaac, RJ, Renal Structure in Normoalbuminuric and Albuminuric Patients With Type 2 Diabetes and Impaired Renal Function, DIABETES CARE, 2013, 36 (11), pp. 3620 - 3626

Persistent Link:

<http://hdl.handle.net/11343/220517>

File Description:

Published version