



Short Communication

Physical Measurement of the Expansion Rate of Anisotropic Tissue Expander in the Skin of the Horse

S. H. Al-Majhali¹, N. H. Khairuddin^{1*}, M. Y. Loqman¹, Z. Radzi², H. C. Chen¹, S. F. Lau¹ and M. T. Rahman²

¹Faculty of Veterinary Medicine, Universiti Putra Malaysia, 43400 Serdang, Selangor, Malaysia

²Faculty of Dentistry, Universiti Malaya, 50603 Kuala Lumpur, Malaysia

ABSTRACT

Tissue expansion technique is one of the most important innovations in skin reconstructive surgery. In this study, anisotropic self-inflating hydrogel tissue expanders were implanted subcutaneously at different anatomical locations; frontal, right shoulder and right forelimb of horses. The resulting skin expansion were observed and recorded daily for the duration of 28 days by manual physical measurements. The rate of height growth and swelling that were recorded are 164.25% at the frontal region of the head, 189.13% at the shoulder region and 122.42% at the forelimb region. The growth of the tissue expander in the three sites could be summarized in three phases; biodegradable in week one, the peak of anisotropic expansion in week two and three, and final degree of swelling in week four.

Keywords: Anisotropic, horse, physical measurement, skin expansion, tissue expander

ARTICLE INFO

Article history:

Received: 19 April 2018

Accepted: 30 August 2018

Published: 14 November 2018

E-mail addresses:

saddamalmajhali@gmail.com (S. H. Al-Majhali)

nurulhayah@upm.edu.my/nurul.leman82@gmail.com (N. H. Khairuddin)

loqman@upm.edu.my (M. Y. Loqman)

zamrir@um.edu.my (Z. Radzi)

chen@upm.edu.my (H. C. Chen)

lausengfong@hotmail.com (S. F. Lau)

m.tariqr.rahman@gmail.com (M. T. Rahman)

* Corresponding author

INTRODUCTION

The clinical use of tissue expander for skin expansion in veterinary field is limited (Bristol, 2005). A study on the use of balloon type tissue expander has been described in three horses and a dog (Madison, Donawick, Johnston, & Orsini, 1989). Tissue expansion enables replacement of lost tissue with similar tissue of matching color, texture and other important local characteristics.

The most common method of tissue expansion is to place balloon expanders near the surgical site. Neumann purposely induced

soft tissue growth with a subcutaneously implanted balloon (expander) in an attempt to reconstruct an external ear deformity (Neumann, 1957). However, there are many complications associated with their use, especially with repeated filling through a port. The use of self-inflating tissue expander greatly minimized these complications (Zhu & Czernuszka, 2015).


The purpose of this study is to report the clinical observation and the rate of expansion of anisotropic self inflating hydrogel tissue expander in the skin of the horse upon implantation of the tissue expander subcutaneously at the frontal region of the head, side of shoulder and at the forelimb at the medial cannon. The expansion of the tissue expanders was measured using electronic digital caliper and clinical changes on the skin were observed and recorded daily for the duration of 28 days.

MATERIALS AND METHODS

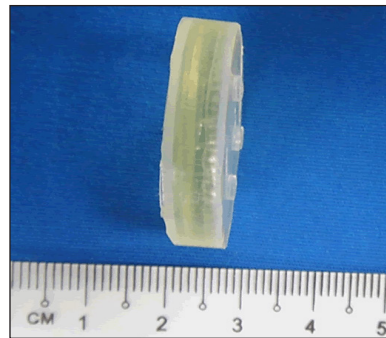
Tissue Expanders

All the tissue expanders used were Anisotropic, self-inflating (Oxtex)[®]UK, circular shape devices. Each tissue expander is approximately 6.5mm in height and 27mm in diameter in size (Figure 1(a) - (b)). These surgical devices containing hydrogels were specifically polymerized by Polymeric Sciences Ltd., UK. The gels were prepared by co-polymerization of pharmaceutical grade (ISO 13488) meth methacrylate (MMA) and vinyl-pyrrolidone (VP). This

hydrogel (90:10 VP: MMA Hydrogel) was coated with a medical grade impermeable silicone (MED-4211).



(a)



(b)

Figure 1. Oxtex[®] self-inflating anisotropic hydrogel tissue expanders before expansion. Each tissue expander is approximately (a) 6.5 mm in height and (b) 27 mm in diameter

Surgical Procedure

Implantation of tissue expanders was performed while the horse was standing and sedated with detomidine infusion (100 µg/ml, with constant rate infusion at 70 drops/min). Local block by using 2% lidocaine hydrochloride (5 to 20 ml) was performed on the site of implantations. A total of seven Anisotropic hydrogel tissue

expanders were placed subcutaneously on the rostral part of the frontal region of the horse head, lateral side of right shoulder and the dorsomedial part of the cannon region of the right forelimb (Figure 1-A,B). Three tissue expanders were implanted on the dorsal part of the frontal region of the horse head. Other three tissue expanders were implanted on the right shoulder and one on the dorsomedial part of the cannon region of the right forelimb. Each incision was for one implant material. From the initial incision site, the skin was then undermined with blunt dissection in order to create a subcutaneous tunnel or pocket to insert the tissue expander. Anisotropic tissue expander was gently inserted into the subcutaneous tunnel and was secured in position by placing a few tacking sutures along the subcutaneous tunnel to prevent migration of the tissue expander subcutaneously. The incision wound was then sutured with 2-0/3-0 Ethilon (Ethicon Ltd., Edinburgh, United Kingdom), cross mattress suture pattern. Broad-spectrum antibiotic with combination of procaine penicillin and dihydrostreptomycin sulphate, 22,000 IU/kg was given once daily by intramuscular injection, anti-inflammatory (Flunixin Meglumine 1.1 mg/kg) once daily intravenously for up to three days in order to reduce postoperative secondary bacterial infections and inflammation. The implantation sites were monitored daily by the same observer for any evidence of infection, suture site breakdown, discharge, implant rupture, hematoma and other signs.

Clinical Observation and Physical Measurements

The standard records and physical measurements were taken daily for 28 days period. Physical measurement of the implanted region was taken using electronic digital caliper to determine the height of expanded tissue for every implant and three readings were recorded for each site (Figure 2). The size and growth of the tissue expanders were also monitored weekly using radiography and cast impression techniques.

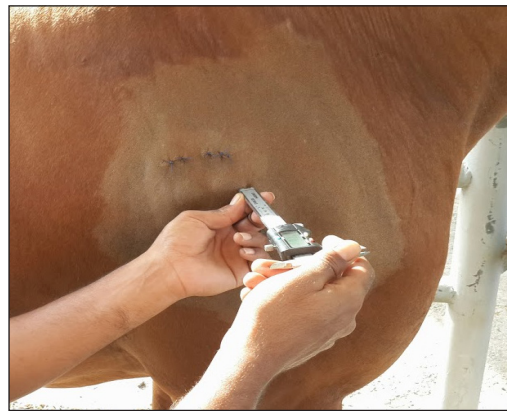

Figure 2. Physical measurement of the implanted tissue expander by using electronic digital caliper

RESULTS AND DISCUSSION

In this study, the physical measurements include measurement of the height of the expanded skin area. The physical measurements were recorded daily throughout the 28 days of post-operative period (Table 1).

Based on the physical measurement data in all horses (n=3), generally, swelling of the tissue expanders and expansion of skin start to increase by the second

day of post-operative implantation of tissue expanders for all sites that were implanted and continue to further expand until around post-operative day 9th -10th.

Tissue expansion was considered to increase but at a slower rate after day 10th until day 19th post-operatively as shown in Figure 3.

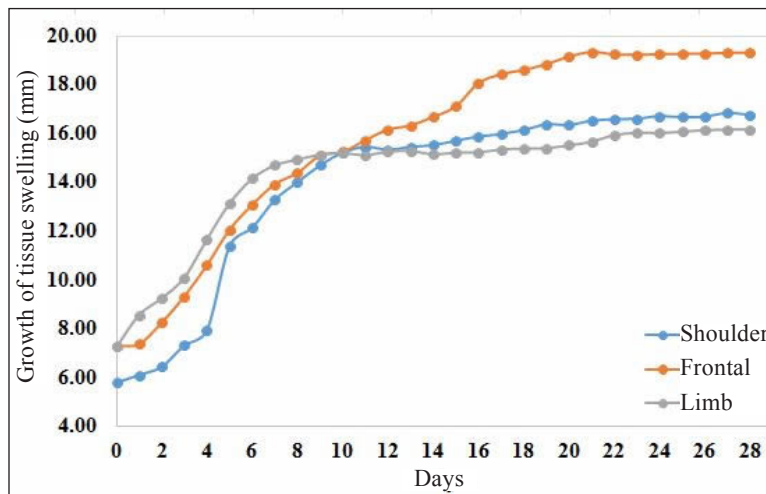


Figure 3. The mean data of physical measurement of tissue expansion of the frontal, forelimb, and shoulder region (n=3), for all horses over the 28 days study period

Data for physical measurement for all horses (n=3) were presented as mean ± s.d. The swelling of the frontal, shoulder and the forelimb at that period were increased.

On an average, highest height recorded was 19.31±1 mm (frontal), 16.76±0.53 mm (shoulder) and 16.17±1.85 mm (forelimb) at post-operative day 28th as shown in Table 1.

Table 1
The mean ±s.d of first and last day of the physical measurement of tissue expansion in the frontal, shoulder and forelimb region (n=3)

Skin sites	Measurement mm day1±S.D	Measurement mm day 28±S.D	Difference mm	%
Frontal (n=3)	7.3±0.46	19.31±1	12.01	164.25%
Shoulder (n=3)	5.8±2.0	16.76±0.53	10.97	189.13%
Forelimb (n=3)	7.27±1.18	16.17±1.85	8.90	122.42%

Through the physical measurement in all horses (n=3), the rate of height growth and swelling that were recorded; 164.25%

at the frontal region of the head, 189.13% at the shoulder region and 122.42% at the forelimb region (Table 1).

The anisotropic self-inflating tissue expander is efficient for expanding skin tissue in horses (Swan, 2007). This tissue expander has the capacity to absorb fluids, expanded in unidirectional in living tissues as it was expected to. This type of expander can be useful in cases that require anisotropic expansion specifically for delicate anatomical region (Swan, Bucknall, Czernuszka, Pigott, & Goodacre, 2012). The expansion rate of the expander grew at the initial stages at all implantation sites and it was observed in all horses in this study. By the beginning of week three, the size of the expander remained unchanged. Consequently, the growth of the skin is controlled in rate, in contrast to first generation of self-inflating tissue expander, which expands rapidly to its maximal volume only in few days after implantation resulting in complications. Van Damme, Heidbuchel, Kuijpers-Jagtman, Maltha and Freihofer (1992) suggested that surface-area increased by tissue expansion can be because of growth, stretching and recruitment of tissue, or it may be due to a combination of these processes (Van Damme et al., 1992).

In this study, the expansion rate of the tissue expander at different sites are showing different rate of expansion. The expanders at the forehead region were expanding much better than the expander placed at the distal limb region. The difference in growth can be attributed to the anatomical nature of these three sites. The superficial skin of the frontal area in horses is less elastic and

tightly attached to the frontal bone allowing space for expansion. (Table 1).

Surgical implantation of all devices was technically straightforward, with no immediate complication seen. All horses made a rapid postoperative recovery and were usually eating and drinking within 1 hours after cessation of anesthesia. In the current experiment, the growth of the tissue expander in the three sites passes in the same three phases; biodegradable in week one, the peak of anisotropic expansion in week two and three, and final degree of swelling in week four.

This result supports the use of self-inflating tissue expander and the effect of implantation time on expansion rate in the three sites. Therefore, to allow for maximum expansion of the self-inflating anisotropic tissue expander, at least a period of three weeks is needed.

CONCLUSION

To conclude, this study will help equine veterinarian to understand the expansion rate of the hydrogel tissue expander in the skin of the horse at the head, shoulder and forelimb regions, for application in advancement skin flap technique and reconstructive of massive skin defects in this species.

ACKNOWLEDGMENTS

This research is supported by High Impact Research MoE Grant UM.C/625/1/HIR/MoE/Dent21 from the Ministry of Education Malaysia.

CONFLICT OF INTEREST

None of the authors have any potential conflicts of interest to declare.

REFERENCES

- Bristol, D. G. (2005). Skin grafts and skin flaps in the horse. *Veterinary Clinics of North America: Equine Practice*, 21(1), 125-144.
- Madison, J. B., Donawick, W. J., Johnston, D. E., & Orsini, R. A. (1989). The use of skin expansion to repair cosmetic defects in animals. *Veterinary Surgery*, 18(1), 15-21.
- Neumann, C. G. (1957). The expansion of an area of skin by progressive distention of a subcutaneous balloon: Use of the method for securing skin for subtotal reconstruction of the ear. *Plastic and Reconstructive Surgery*, 19(2), 124-130.
- Swan, M. C. (2007). *Anisotropic self-inflating tissue expanders in reconstructive palstic surgery* (Unpublished doctoral dissertation), University of Oxford, United Kingdom.
- Swan, M. C., Bucknall, D. G., Czernuszka, J. T., Pigott, D. W., & Goodacre, T. E. (2012). Development of a novel anisotropic self-inflating tissue expander: in vivo submucoperiosteal performance in the porcine hard palate. *Plastic and Reconstructive Surgery*, 129(1), 79-88.
- Van Damme, P. A., Heidbuchel, K. L., Kuijpers-Jagtman, A.-M., Maltha, J. C., & Freihofer, H. P. M. (1992). Cranio-maxillo-facial tissue expansion, experimentally based or clinically empiric? A review of the literature. *Journal of Cranio-Maxillofacial Surgery*, 20(2), 61-69.
- Zhu, Y., & Czernuszka, J. T. (2015). Inter-penetrating polymer network hydrogel tissue expanders with controlled expansion and anisotropic properties. *Journal of Medical and Bioengineering*, 4(2), 86-92.