



# **Challenges in the surgical pathological diagnosis of breast cancer**

**Ph. D. Thesis**

**TAMÁS ZOMBORI, M.D.**

**Supervisor:**

**Gábor Cserni, M.D., D.Sc.**

**Department of Pathology**

**University of Szeged**

**Szeged, Hungary**

**2018**

## INTRODUCTION

Breast cancer remains the most frequent malignant tumor among women in Europe. Organized breast cancer screening programs, the mass media, the large number of dedicated conferences reveal the high level of epidemiological, sociological and psychological significance of this disease. A recent PubMed search identified 369900 different papers on breast cancer at the time of writing this thesis. This huge number of publications shows the degree of interest in the research on breast neoplasms. In our work, we focused on immunophenotyping of triple negative breast cancers (TNBCs), on effects of primary systemic therapy (PST) in the tumor bed and in the axillary lymph nodes, and on cases having diffuse ductal carcinoma in situ (DCIS) with comedo-like necrosis and amorphous calcification, which are potential cases of neoductogenesis.

### 1.1. TRIPLE NEGATIVE BREAST CANCER AS A DIAGNOSTIC CHALLENGE

Metastases of breast cancer develop through either the lymphatic or the blood vessels, and affect regional lymph nodes and distant organs. Sometimes, metastasis is the first clinical sign of an unknown primary breast cancer. In case of metastatic carcinoma, it is essential to prove its metastatic nature and origin. Despite their less than perfect specificity, estrogen receptor (ER), progesterone receptor (PR) and human epidermal growth receptor-2 (HER2) are among the most useful immunohistochemical (IHC) markers for suggesting breast origin. These antibodies can be helpful in cases of luminal A-like, luminal B-like and HER2+ subtypes, but not in cases of TNBC which represent approximately 15% of all breast cancers. Without the information of a previous primary breast carcinoma, and because of its phenotypic overlap with other potential primaries, a triple negative case can easily confuse the pathologist. Several immunomarkers as GATA-3, mammaglobin A (MG), gross cystic disease fluid protein-15 (GCDFP-15), NY-BR-1 and BRCA-225 have been studied recently to verify the breast origin in metastatic cancer.

### 1.2. TUMOR REGRESSION AFTER PRIMARY SYSTEMIC THERAPY (PST) IN BREAST CANCER

PST is currently applied in bulky (>2cm) tumors or locally advanced cancers. Despite (inter)national guidelines or reviews aiming at some uniformity in breast cancer reporting, there are several inconsistencies, namely in specimen work-up, definition of pathological complete regression (pCR), patterns and grades of regression. After PST, gross examination

must be correlated with the clinical and especially radiological localization to ensure that the correct area is sampled. Systematic sampling should include the grossly visible tumor bed or the location of clip markers and neighboring areas to incorporate the area involved by carcinoma before treatment.

A less analyzed feature of response to PST is homogeneity or heterogeneity of the regression. According to Provenzano and coworkers, the patterns of residual disease are the following: homogenous regression (cellularity decreased, size unchanged), inhomogeneous regression (cellularity decreased, size variable, small areas without residual disease), "scatter pattern" (cellularity decreased, size variable, part of tumor bed slides without residual disease) and "concentric shrinkage" (CS) (size decreased, cellularity similar). Especially the "scatter pattern" may lead to diagnostic pitfalls if not systematically sampled. After PST, bizarre and/or macronucleated neoplastic giant cells generally attributed to the effects of chemotherapy may sometimes be found in the tumor bed. The presence of these bizarre cells may increase the posttreatment grade, whereas a reduction in the proliferating cells may decrease it.

### 1.3. TUMOR REGRESSION AFTER PRIMARY SYSTEMIC THERAPY IN AXILLARY LYMPH NODES

The sentinel lymph nodes (SLN) are the first lymph nodes draining the tumor area, therefore the SLNs are the first involved during the lymphatic spread of cancer. The non-SLNs of the same anatomic region develop metastases only subsequently. Tumor-reactive lymphadenopathy (TRL) is a complex reaction of lymph nodes, which develops before the arrival of the metastatic tumor cells and comprises morphological and functional changes. As concerns the morphological alterations, previous publications found enlargement of the tumor draining lymph nodes, increased total number of functional blood vessels and lymphatic vessels/sinuses, dilation of functional blood vessels with structural remodeling and endothelial cell proliferation of high endothelial venules. Functional changes, such as increased blood perfusion and immunological differences, like the alterations in CD28 and CD3 $\zeta$  expression of CD4 $^{+}$  and CD8 $^{+}$  T-lymphocytes or the reduction in density and dendritic complexity of antigen presenting paracortical dendritic cells were also observed in tumor draining lymph nodes.

The above-mentioned factors may hypothetically alter the neoadjuvant therapy induced reactions in tumor-draining SLNs compared to lymph nodes without direct connection with

the primary carcinoma, i.e. non-SLNs. Enhanced blood flow and enriched vasculature may increase the load of chemotherapeutics or targeted cancer therapy agents (e.g. hormone receptor modulators or trastuzumab) in lymph nodes developing TRL. A preferential regression in SLNs might influence the false negative rate of SLN biopsy after PST, by resulting in complete regression in SLNs with remaining tumor burden in non-SLNs. Alternatively an immunosuppressed status of the SLNs as compared to non-SLNs could lead to less effect from cytotoxic therapeutics. A selective regression or non-regression may also alter the staging effect of the removal of radioactive seed localized nodes that proved to be positive before the initiation of primary systemic treatment.

#### 1.4. BREAST WITH DIFFUSE DCIS WITH COMEDO-LIKE NECROSIS AND AMORPHOUS CALCIFICATION –THEORY OF NEODUCTGENESIS

Breast parenchyma is organized into anatomic units corresponding to mammary lobes. An easy to imagine visual analogy of the lobar organization would be that of a tree, where the lactiferous duct would correspond to the trunk, the ducts to branches, and the lobules to compound leaves. Acini of the lobules and ducts are easy to distinguish from each other. Although both the ducts and lobules feature an outer myoepithelial cell layer and a basement membrane, there is usually also an elastic layer around the ducts, which is missing around the acini.

When DCIS develops in the ductal tree or its end, the terminal ductulobular unit, there is often a dilatation of the normal anatomic structures. When the anatomy of the breast is maintained, DCIS can easily be identified as involving the ducts and sometimes the lobules. The latter phenomenon has been called lobular cancerisation. Some forms of DCIS do not follow this regular growth and intraluminal spread. Instead, there are plenty of more or less dilated lumens dispersed with a relatively uniform and higher than normal density. Although some believe that this pattern is also due to abnormal extent of dilatation of pre-existing structures, there is apparently no obviously discernible lobular architecture maintained. The concept of neoductgenesis has been introduced to explain the morphology of these cancers. This concept suggests that new ducts are formed from the pre-existing ones and grow into the stroma. Newly formed ducts “invade” the stroma in a pushing and “coated” manner without losing their myoepithelial and basement membrane layers which are the diagnostic hallmark of in situ carcinomas and the clue used to exclude the presence of invasion in breast pathology. Neoductgenesis could explain the aggressive behavior of tumors with this

phenomenon having minor areas of classical invasive carcinoma of no special type. Local recurrence rates in cases diagnosed as representing pure DCIS are also higher in neoplasms with proposed neoductgenesis, and this is also related to their greater extension and diffuse growth pattern, but also reflects a worse overall prognosis.

Neoductgenesis has been associated with casting type calcifications on the mammogram, and tumors with this manifestation have been reported to have poor outcome in several series. Morphologic criteria have also been proposed by Zhou and coworkers on the basis of duct concentration, periductal fibrosis and lymphocytic infiltration and may help to identify cases with this phenomenon even on histological slides.

## 2. AIMS

The aims of the present thesis are listed as follows:

To look at the IHC staining of GATA-3, MG, GCDFP-15, NY-BR-1 and BCA-225 in a series of TNBCs showing CK5 expression and therefore being consistent with a basal-like phenotype on the basis of the IHC-based surrogate molecular classification.

To evaluate the response patterns in breast cancers after PST, focusing on correlations of radiological and pathological tumor sizes, regression heterogeneity in the tumor bed and in the axilla in different molecular subtypes of breast cancer, cellularity changes between biopsy and resection specimen, correlation between cellularity and size alterations and the incidence of macronucleated, bizarre neoplastic cells related to therapy.

To evaluate the differences in the degree of regression induced by neoadjuvant therapy in the SLNs (tumor draining lymph nodes) and in non-SLNs (non-tumor draining lymph nodes) in a series of patients who underwent SLN biopsy and axillary lymph node dissection (ALND) following PST for breast cancer.

To analyze lumen forming structures of the DCIS component of a few tumors (some of which were believed to represent DCIS with neoductgenesis) with orcein staining to see how ducts and acini maintain their staining when involved by DCIS, and to see how ducts believed to be newly formed behave with this stain.

### 3. MATERIALS AND METHODS

#### 3.1. IMMUNOHISTOLOGICAL EVALUATION OF BASAL-LIKE TNBCS

Invasive breast carcinomas operated on at the Bács-Kiskun County Teaching Hospital, Kecskemét between August 2005 and August 2015 and fulfilling the criteria of TNBC and CK5 positivity by IHC were selected for tissue microarray (TMA) construction. The TMAs were constructed from archived paraffin-embedded blocks; each carcinoma was represented in duplicate in 2 different TMAs.

IHC for GATA-3, MG, GCDFP-15, NY-BR-1 (and BCA-225) was performed on the TMAs and the stains were assessed by the two authors by evaluating the proportion of nuclear (GATA-3) and cytoplasmic (MG, GCDFP-15 and BCA-225) or both nuclear and cytoplasmic (NY-BR-1) labeling of tumor cells. A staining of 5% or more cells was considered a positive result.

#### 3.2. EVALUATION OF REGRESSION PATTERNS IN BREAST CANCER AFTER PST

Consecutive invasive breast carcinomas treated with PST and operated on at the Bács-Kiskun County Teaching Hospital, Kecskemét or at the Department of Surgery, University of Szeged from 2015 through February 2018 and from 2013 through May 2018, respectively were included. Both departments have used a similar work-up methodology matching the recommendations of the 3rd Hungarian Consensus Conference on Breast Cancer, including radiological localization, systematic sampling and clinical-pathological correlation.

All hematoxylin-eosin (HE) stained tumor (bed) containing slides of biopsy and excision specimens were analyzed. The cellularity was estimated by two pathologists both on biopsy and excision specimens. The presence of whole slides, any low power field (4x; 0.24 mm<sup>2</sup>) or any medium power field (10x; 0,005 mm<sup>2</sup>) showing complete response or the lack of any response was noted. Homogenous regression was defined as pCR, absence of regression on all slides and uniform degree of regression on all slides. Any other pattern was perceived as inhomogeneous response. The latter included the “scatter pattern”, and CS. The alteration of pre- and posttreatment cellularity and size; and the correlation between radiological (exclusively US data) and pathological size were analyzed by the Spearman rank model.

The cells having enlarged cytoplasm, multiple and/or enlarged bizarre hyperchromatic nuclei with different size and shape (“monster cells” for the purpose of this study) were

looked for in post-PST specimens. The slides of axillary lymph node excisions were reevaluated and the presence or absence of metastasis and regression was documented. If metastatic nodes were seen with and without regression, inhomogeneous axillary response was identified.

### 3.3 EVALUATION OF REGRESSION HETEROGENEITY IN AXILLARY LYMPH NODES AFTER PST

In this retrospective study, lymph node tissue sections of 142 female breast cancer patients staged with SLN biopsy and ALND after receiving PST were used from the archives of the authors' institutions. The presence and degree of regression were evaluated in all metastatic and non-metastatic lymph nodes, SLNs and non-SLNs separately. These results were used to categorize the cases, based on whether they supported the theory that regression in SLNs may be greater than in non-SLNs or not.

### 3.4. ANALYSIS OF LUMEN FORMING UNITS IN CASES OF DIFFUSE DCIS WITH COMEDO-LIKE NECROSIS AND CASTING TYPE CALCIFICATION

Selected histological slides of patients with areas of DCIS (mostly associated with areas of invasive cancer) demonstrating comedo necrosis and central calcification from the Pathology Departments of the University of Szeged and Bács-Kiskun County Teaching Hospital were retrospectively analyzed. HE staining was employed for the identification of anatomic structures involved by the in situ neoplastic cells as ducts or acini, whereas orcein staining (ORC) was used for the evaluation of elastic fibers around the units previously classified on the basis of the HE stain. One or two slides per case were selected and digitized with a 3DHistec Panoramic 250 scanner. The structures were numbered in parallel on both the HE and the ORC digital slides with the aid of the Panoramic Viewer software (3DHistec, Budapest, Hungary).

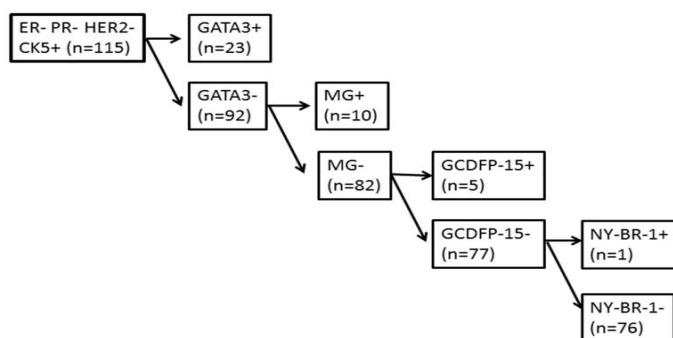
Each numbered structure was classified according to the resemblance to the normal microanatomical structures into one of the following categories: definitely representing a duct, likely to be a duct, unclassifiable, likely to be an acinus, definitely representing an acinus. The elastic fibers around the numbered and classified structures were graded as concentric presence, dominant presence (elastic fibers around more than half of the perimeter of the structure), dominant absence (elastic fibers around less than half of the perimeter of the structure) and absence of elastic fibers around the structure; these categories were scored from

3 (concentric elastic layer) to 0 (no elastic layer) in descending order. The neoductgenesis-score described by Zhou et al was applied for the identification of tumors demonstrating neoductgenesis. The original description of the score also includes a visual scale for each score component, and this was used to label the cases. However, we also applied the score to individual structures. For this, we used the first component of the combined score from the entire slide, but the two remaining score components were derived from the lymphocytic infiltration and fibrosis around the given structure. The statistics included the Mann-Whitney and the chi-square tests. We utilized the SPSS Statistics software (IBM, SSPS 22.0, Armonk, NY USA).

#### 4. RESULTS

##### 4.1. IMMUNIHISTOCHEMICAL EVALUATION OF BASAL-LIKE TNBCS

All markers could be evaluated in only 115 of the 118 tumors sampled, therefore the result are reported for these 115 cases. In 3 cases, the tissue cores were not evaluable due to necrosis or lack of tumor cells. GATA-3 labeling was characterized by nuclear staining in the tumor cells, whereas MG, GCDFP-15, NY-BR-1 and BCA-225 positivity was identified as obvious cytoplasmic staining. Taking any staining into account, GATA3 and BCA-225 labeling was seen in the majority of the cases, followed by MG and GCDFP-15, whereas NY-BR-1 immunoreactivity seen in only a few tumor samples. Using the 5% cut-off, there was a marked drop in the proportion of cases showing GATA3 positivity, but reductions were seen with all markers.



**Figure 1. Hierarchical labeling of the tumors**

Only one third of the cases showed notable (at least 5%) staining with any of the 4 markers considered to be more specific for a breast origin if a few caveats are kept in mind.



Using the frequency of labeling in this series, Figure 1 shows the hierarchical help that each of the markers can give in the assessment of a mammary origin of CK5 positive TNBCs. It is clear from the figure as from overall data, that NY-BR-1 is not of great help in this context.

#### 4.2. EVALUATION OF REGRESSION PATTERNS IN BREAST CANCER AFTER PST

In this series, 106 cases were included: 56 and 50 patients from the University of Szeged and the Bács-Kiskun County Teaching Hospital, respectively. Regarding the homogeneity of regression, the luminal A-like, HER-2 and TNBCs showed more homogeneity, whereas luminal B-like cases demonstrated more inhomogeneity. Unfortunately, statistical analysis could not be applied due to the low case numbers in the groups. Lack of any regression, uniform degree of regression and pCR were observed in 7.5%, 18.8% and 28.3% of all cases, respectively. The vast majority of inhomogeneous regression was minor inhomogeneity (36.7% of all cases). The scatter pattern was identified in only 7 cases (6.6%), while CS was the rarest (n=2; 1.8%). In the lymph node specimens, homogeneity was more frequent (homogeneity: 45.3% versus inhomogeneity: 23.5% of all cases). In cases having neither metastasis nor regression in the lymph nodes, homogeneity of regression or its lack could not be evaluated (31.2 %).

Cellularity changes reflected decrease in most cases (two thirds of all patients) but an increase was recorded in a significant minority (15.1%). The correlations between changes in cellularity and the alterations of post-treatment pathological and radiological tumor sizes compared to the pretreatment US size were significant ( $p=0.04$  and  $p=0.03$ , respectively). The grade of tumors was unchanged in 72.4%. Upgrading and downgrading were detected in 10 and 10 cases (13.8% and 13.8%), respectively. The latter was not seen among patients having TNBC. The Spearman rank correlation revealed that the concordance between post-treatment pathological size and radiological size (defined by US examination) was high ( $p=0.002$ ).

“Monster” cells were seen in 17.9% (n=19) of all cases. They were present in pre- and posttreatment grade 2 and 3 tumors exclusively. In 5 cases, upgrading (grade 2 to post-treatment y-grade 3) was detected in presence of “monster” cells and the monster cells were present only (all but one case) in patients who received PST including a taxane. No correlation was found between the molecular subtypes and treatment related alteration in (pathological) size, cellularity, grade, the homogeneity of regression in lymph node specimens and presence of "monster" cells.

#### 4.3. EVALUATION OF REGRESSION HETEROGENEITY IN AXILLARY LYMPH NODES AFTER PST

There were 110 ER positive tumors (including 25 HER2 positive cases), and of the 32 ER negative tumors, 12 were HER2 positive by immunohistochemistry or in situ hybridization. A pCR with or without residual in situ carcinoma was seen in 24 cases, and no signs of regression were reported in 16 primary cancers. No nodal regression at all was evidenced in 19 node-positive cases, whereas the number of cases having at least one metastatic lymph node without evidence of regression (NR4) was 55. A median of 2 SLNs (range: 1-8) and 14 non-SLNs (range: 2-42) were removed from the patients.

The practice of SLN biopsy in locally advanced breast cancer patients receiving PST is still somewhat controversial. Often the SLN biopsy was performed before primary systemic therapy or was not performed because of previously evidenced metastatic lymph nodes. Eighty seven from 142 cases including 40 node-positive cases without evidence of regression in the lymph nodes, were indifferent towards the tested hypothesis. Of the 89 cases with signs of nodal regression, the regression was of greater degree in non-SLNs in 22 cases (25%). Only 18/89 cases (20%) were in support of a selective and more pronounced regression in the SLNs.

#### 4.4. ANALYSIS OF LUMEN FORMING UNITS IN CASES OF DIFFUSE DCIS WITH COMEDO-LIKE NECROSIS AND CASTING TYPE CALCIFICATION

Twenty seven slides from 21 female patients were investigated in this retrospective study. Altogether 1220 structures were classified as ducts or acini with different levels of certitude, as described in the methods. The majority (nearly two thirds) were unclassifiable, and between 7.4 and 13.6 per cent belonged to one of the 4 remaining categories each. The concentric presence of elastic fibers is more frequent around structures identified as ducts or likely ducts, but was also seen around a minority of unclassifiable structures. At the opposite end of the spectrum, acini lack elastic fibers around, similarly to likely acini. Most unclassifiable structures are also completely or partially (dominant absence pattern) devoid of peristructural elastic fibers. The Mann-Whitney test revealed significant difference between ducts and acini: a concentric elastic fiber layer surrounds almost all normal ducts, but the acini do not have such an elastic coating ( $p < 0.001$ ).

Neoductgenesis was identified in six (25.5%) cases by using the neoductgenesis score. After the application of this scoring system to all numbered structures, we found that in neoductgenesis positive tumors, 27.3% of the numbered units were suggested as neoducts and there was hardly any potential neoducts (0.75%) in neoductgenesis negative tumors. We also examined the means of the scores of numbered individual structures per case. In neoductgenesis positive tumors (n=6), the average of the neoductgenesis related scores was higher (mean±S.D.: 3.87±0.35, range: 3.49-4.39) than in neoductgenesis negative cases (mean±S.D.: 1.97±1.11, range: 0-3.1). Two thirds of these neoducts identified by the per structure scoring system are irregular and uncertainly classifiable structures, and almost 80% of them are not or dominantly not surrounded by elastic fibers. The chi-square test revealed a significant difference between the normal structures and the individual score based neoducts: the latter generally do not have an elastic layer around (p<0.001).

In neoductgenesis positive and negative tumors, the presence of elastic fibers was evaluated by scoring of each structure on orcein stained slides as described in the methods. Lower scores were found in the neoductgenesis positive tumors (mean±S.D.: 0.57±0.32, range: 0.28-0.91) than in neoductgenesis negative neoplasms (mean±S.D.: 0.89±0.54, range: 0.1-2.1).

## 5. DISCUSSION

### 5.1. IMMUNOHISTOCHEMICAL EVALUATION OF BASAL-LIKE TNBCS

TNBCs are defined by their negativity for ER, PR and HER2. Metastases to the breast are rare, but metastases from TNBCs are relatively common. Proving the mammary origin of TNBCs may be problematic, as ER, one of the most commonly used, but not specific marker of breast origin is by definition absent in these tumors. In the present study, we investigated the expression of 5 markers developed or used to support the mammary origin of cancers according to the description in the data sheets. IHC was applied in a series of TNBCs deemed to be of the basal-like type on the basis of their CK5 expression.

Data on the staining frequency of GATA3, MG, GCDFP-15 and NY-BR-1 in TNBC are limited. On the basis of these data, the sensitivities of GATA-3, Mammaglobin-A, GCDFP-15 and NY-BR-1 to suggest a mammary origin are 43.5% (95%CI 0.396-0.476), 16.4% (95%CI: 0.136-0.196), 15.1% (95%CI: 0.127-0.179) and 5.4% (95%CI: 0.027-0.103), respectively.

To our knowledge, this is the largest series of TNBC analyzed for the expression of 5 markers of mammary origin, moreover the series includes exclusively TNBC of a distinct subtype, namely tumors expressing CK5 and therefore most likely to coincide with basal-like breast carcinomas. If we consider the documented lack of specificity of BCA-225, the remaining 4 breast markers fail to show any staining in about 15% of CK5 expressing TNBCs. A more detectable (at least 5%) expression of any of the 4 markers was seen in around one third of the cases, leaving the remaining two thirds unidentified as of mammary origin.

The expression of GATA3, MG, GCDFP-15 and NY-BR-1 is lower in TNBCs than in breast carcinomas in general. Although these markers may be positive in different other tumors, by using them, a subset of basal-like TNBC-s can be identified as of mammary origin. Though the positive staining supports a breast origin, negativity for all markers does not exclude this. Therefore we suggest using GATA-3, MG and GCDFP-15 as an IHC panel to establish breast origin in metastatic tumors when ER and PR are negative.

## 5.2. EVALUATION OF REGRESSION PATTERNS IN BREAST CANCER AFTER PST

In PST studies, the pathological diagnosis is the most important parameter for the generation of study endpoints. The histopathological changes after PST are complex, therefore careful systematic analysis of the specimen is required for accurate diagnosis and treatment. The standardization of specimen handling and histological interpretation is essential for approaching pCR as an indicator in PST studies, or for measuring residual disease.

Though the change in cellularity is one of the most representative features of PST, it is not recorded routinely in the histopathological reports. In the present series, biopsies taken before PST and resection specimens were evaluated for cellularity changes. In the vast majority of the cases, cellularity has declined and a significant correlation was detected between alterations of cellularity and (pathological) size.

Our findings suggest that homogeneity and inhomogeneity of regression are not associated with any molecular subtype, and both are present approximately in half of the cases. The majority of inhomogeneous regression represented minor inhomogeneity seen in differences between one and the other medium or low power field, while the scatter pattern and CS were exceptionally rare. Although the most remarkable pattern is the scatter pattern

regarding the problems of tumor bed sampling, as complete slides may be present without residual cancer, minor heterogeneity may also cause diagnostic controversy if only core biopsies are taken after PST. Several ongoing or completed studies on PST feature post-PST core biopsies as parts of their design. Tumor heterogeneity, especially the scatter pattern of regression may have an impact on these studies. Limited sampling of inhomogeneously responsive cases by taking interim or final biopsies may be the source of misinterpretations, if the biopsy is taken from the part of tumor bed showing complete response or another part lacking any response. To avoid these diagnostic pitfalls, generous sampling by multiple biopsies is recommended if the assessment of the complete tumor bed is not feasible.

Monster cells are giant tumor cells often associated with effects of PST. The presence of these cells was associated with taxane treatment. The principal effect of taxanes is the disruption of microtubule function, including the blockage of the mitotic spindle. Our findings suggest that the presence of these monster cells may increase nuclear atypia and therefore it may lead to upgrading following PST. Due to polyploidization, such cells are also expected to show an increased copy number of many genes, including HER2, leading to a post-treatment positive status of questionable therapeutic significance in these cells.

To our knowledge, this is the first study describing the distribution of regression heterogeneity according to molecular subtypes. Our findings suggest that regression may be inhomogeneous in half of the cases, and it does not seem to be related to any molecular subtype. The evaluation of the whole tumor bed is recommended for the best assessment of regression. “Monster” cells are related to PST including taxanes, and may cause upgrading in tumors with non-high grade nuclei at the start of PST.

### 5.3. REGRESSION HETEROGENEITY OF AXILLARY LYMPH NODES

Altogether the case numbers are relatively small, however, the distribution of the cases did not point in favor or against a selective regression (or non-regression) in SLNs. The fibrotic foci in the lymph nodes were interpreted as signs of regression, but these signs are not specific, and other processes may lead to the same morphological features. However, in the setting of neoadjuvant therapy, this latter is the most likely cause for these morphological changes, and therefore these were uniformly interpreted as signs of regression. The evidence gathered from the limited number of cases available suggests that despite the attractiveness of a preferential regression (or non-regression) in tumor draining lymph nodes (SLNs which seem to be immunosuppressed and at the same time are the sites of TRL), there is no obvious

difference in the degree of regressive histological changes shown by SLNs and NSLNs. Therefore, this phenomenon may not be a major contributor to the somewhat higher false negative rate of SLN biopsy after neoadjuvant treatment.

#### 5.4. DIFFUSE DCIS WITH COMEDO-LIKE NECROSIS AND AMORPHOUS CALCIFICATION

Our study of a large number of breast microanatomic structures suggests that most of the densely packed structures involved by morphological DCIS with comedo necrosis cannot be classified on the basis of the HE look as ducts or acini. The study also demonstrated that DCIS involved structures that could be classified as ducts or acini with some certainty displayed the elastic coating expected on the basis of the normal anatomic structures. On the other hand, most structures that could not be reliably classified as ducts or acini, in parallel with most structures classified as representing neoducts on the basis of the proposed scoring system adapted to the individual structures were devoid of an elastic coating. Although this could be used as a support to the acinar origin of these structures, it is more realistic to suggest that together with previously described stromal periductal tenascin-C accumulation, this could be another difference between preexisting and newly formed ducts.

Myoepithelial cells have been reported to have an altered phenotype in some DCIS cases, characterized by the loss of one or more myoepithelial markers labeling the myoepithelium around normal anatomic mammary structures. Although we did not study the expression of myoepithelial markers, we detected another abnormality of high grade DCIS cases with comedo necrosis, namely the lack of elastic fibers around the ducts.

Neoductgenesis is a concept to explain the morphology of certain breast cancers that show neoplastic cells in densely packed anatomic structures seemingly corresponding to either normal ducts or acini on the basis of the presence of a basement membrane and a myoepithelial layer at the outer surface, but not corresponding to any of these preexisting structures when looking at the lack of the tree-like distribution of normal anatomic structures. The theory suggests that some breast carcinomas are characterized by the outgrowth of new branches, i.e. new ducts, neoducts from the ductal tree, representing a pushing type infiltration. Three-dimensional analysis of such cases further reinforces the lack of normal distribution of ducts and acini in such tumors. This “disturbed arborization” could be the result of a disturbed alveolar switch, a hormonally driven physiologic mechanism responsible

for the development of acini from ductal epithelium. Our report indicates that the proposed neoducts are also devoid of elastic coating, resembling acini in this respect.

There were more structures that could not be reliably classified as ducts or acini than structures corresponding to neoducts on the basis of the neoduct scoring applied to the individual structures. These unclassifiable structures were generally devoid of elastic fibers. Our study therefore identifies possible neoducts as structures devoid of elastic periductal fibers and most of the structures that could not be classified as (likely) ducts or (likely) acini on the basis of distribution patterns as similarly devoid of elastic fibers and possibly also as neoducts. The use of elastic stains may probably be an aid in the study of neoductgenesis.

## 6. MAJOR NEW FINDINGS

To our knowledge, this is the largest series of TNBCs, more specifically CK5 expressing basal like TNBCs assessed with 5 potential IHC markers suggestive of breast origin.

The expression of GATA3, MG, GCDFP-15 and NY-BR-1 is lower in TNBCs than in breast carcinomas in general. With a 5% staining cut-off more than half of the CK5-positive TNBCs cannot be proven to be of mammary origin.

This is the first study to assess the degree of heterogeneity in regression after PST and look for possible associations with molecular subtypes. Our findings suggest that regression may be inhomogeneous in about half of the cases, and it does not seem to be related to any molecular subtype.

It is suggested that optimally the whole tumor bed should be investigated for the best assessment of regression, and limited sampling by core biopsy might not be suitable in all cases for the evaluation of the presence and degree of regression.

The neoplastic “monster” cells are related to PST including taxanes, and may cause upgrading in tumors with non-high grade nuclei at the start of PST.

Our study of the distribution of lymph node metastases and regression on a limited number of cases do not support a selective regression in SLNs, and therefore this phenomenon cannot explain the somewhat higher false negativity rate of post-PST SLN biopsies.

The structures involved by DCIS that cannot be classified as ducts or acini on the basis of the HE stain and the normal microanatomic distribution do not show an elastic coating characteristic of normal ducts and therefore resemble to acini or are atypical ducts. Structures corresponding to neoducts on the basis of the neoduct score also show a lack of elastic coating and cannot be classified as duct or acini on the basis of microscopic features and distribution. The use of elastic stains may probably be an aid in the study of neoductgenesis.

## 7. ACKNOWLEDGEMENTS

I greatly appreciate all the support and scientific guidance of my supervisor Professor Gábor Cserni from the Department of Pathology, University of Szeged and Head of the Department of Pathology, Bács-Kiskun County Teaching Hospital in Kecskemét.

I express special thanks to Professor Béla Iványi and László Tizslavicz, Heads of the Department of Pathology, University of Szeged at the time of writing the articles, who provided accomplished working conditions at the department.

I also thank to Dr. Tibor Hortobágyi for his support in the last phase of this thesis.

I am grateful to my tutors László Kaizer, Sándor Hamar and András Vörös who introduced me to challenges of breast histopathology.

I would like to express my gratitude for the staff members of the breast tumor board: Professor Zsuzsanna Kahán, Professor György Lázár, Attila Paszt, Zsolt Simonka, Katalin Ormándi, Csilla Hoffmann, Alíz Nikolényi, Orsolya Ruzs, Professor Gábor Cserni, Sándor Hamar, László Kaizer, András Vörös, and Mihály Dezső (photographic technician at the Department of Pathology, University of Szeged). Their high quality work helped this dissertation to come into existence.

I am thankful to my family, my fiancée and friends for support and subservience.

This study was partly funded by the National Research, Development and Innovation Office grant GINOP-2.3.2-15-2016-00020.



## LIST OF FULL PAPERS THAT SERVED AS THE BASIS OF THE PH.D. THESIS

I. Zombori T, Cserni G. Immunohistochemical analysis of the expression of breast markers in basal-like breast carcinomas defined as triple negative cancers expressing keratin 5. *Pathol Oncol Res.* 2018;24:259-267. doi: 10.1007/s12253-017-0246-y.

IF: 1.93

II. Cserni G, Zombori T, Andreu X, Bianchi S, Regitnig P, Amendoeira I, Balmativola D, Kovács A, Cordoba A, Reiner A, Kulka J, Kaya H, Liepniece-Karele I, Quinn C, Kővári B. Is Regression after neoadjuvant chemotherapy for locally advanced breast cancer different in sentinel and non-sentinel nodes? *Pathol Oncol Res.* 2018;24:167-170. doi: 10.1007/s12253-017-0229-z.

IF: 1.93

III. Zombori T, Cserni G. Elastic stains in the evaluation of DCIS with comedo necrosis in breast cancers. *Virchows Arch.* 2018;472:1007-1014. doi: 10.1007/s00428-017-2259-z.

IF: 2.93

IV. Zombori T, Cserni G. Patterns of regression in breast cancer after primary systemic treatment. *Pathol Oncol Res.* [under consideration]

## OTHER PUBLICATIONS

V. Janovszky Á, Szabó A, Varga R, Garab D, Boros M, Mester C, Beretka N, Zombori T, Wiesmann HP, Bernhardt R, Ocovszki I, Balázs P, Piffkó J. Periosteal microcirculatory reactions in a zoledronate-induced osteonecrosis model of the jaw in rats. *Clin Oral Investig.* 2015;19:1279-88. doi: 10.1007/s00784-014-1347-6.

IF: 2.38

VI. Zombori T, Furák J, Nyári T, Cserni G, Tiszlavicz L. Evaluation of grading systems in stage I lung adenocarcinomas: a retrospective cohort study. *J Clin Pathol.* 2018;71:135-140. doi: 10.1136/jclinpath-2016-204302.

IF: 2.89

VII. Zombori T, Lehóczky L, Cserni B, Nyári T, Cserni G. [Evaluation of anatomic and prognostic stages of breast cancer according to the 8th edition of the TNM staging system - Retrospective analysis based on data from deceased patients once diagnosed with breast cancer]. *Orv Hetil.* 2017;158:1373-1381. doi: 10.1556/650.2017.30849. [Hungarian]

IF: 0.32

VIII. Maráz R, Zombori T, Ambrózay É, Cserni G. The role of preoperative axillary ultrasound and fine-needle aspiration cytology in identifying patients with extensive axillary lymph node involvement. *Eur J Surg Oncol.* 2017;43:2021-2028. doi: 10.1016/j.ejso.2017.08.007.

IF: 3.68

IX. Vöröslakos M, Takeuchi Y, Brinyiczki K, Zombori T, Oliva A, Fernández-Ruiz A, Kozák G, Kincses ZT, Iványi B, Buzsáki G, Berényi A. Direct effects of transcranial electric stimulation on brain circuits in rats and humans. *Nat Commun.* 2018;9:483. doi: 10.1038/s41467-018-02928-3.

IF: 12.32

X. Zombori T, Nyári T, Tizslavicz L, Pálföldi R, Csada E, Géczi T, Otlakán A, Pécsy B, Cserni G, Furák J. The more the micropapillary pattern in stage I lung adenocarcinoma, the worse the prognosis-a retrospective study on digitalized slides. *Virchows Arch.* 2018;472:949-958. doi: 10.1007/s00428-018-2337-x.

IF: 2.93

XI. Diossy M, Reiniger L, Sztupinszki Z, Krzystanek M, Timms KM, Neff C, Solimeno C, Pruss D, Eklund AC, Tóth E, Kiss O, Ruzs O, Cserni G, Zombori T, Székely B, Tímár J, Csabai I, Szallasi Z. Breast cancer brain metastases show increased levels of genomic aberration-based homologous recombination deficiency scores relative to their corresponding primary tumors. *Ann Oncol.* 2018;29:1948-1954. doi: 10.1093/annonc/mdy216.

IF: 13.92

XII. Zombori T, Tóth N, Furák J, Berényi Z, Tizslavicz L. [Tumor of posterior mediastinum - rare case of extramedullary myelolipoma]. *Magy Seb.* 2017;70:74-77. doi: 10.1556/1046.70.2017.1.11. [Hungarian.]