

DOI: <https://doi.org/10.5114/pjr.2019.82992>Received: 06.01.2019
Accepted: 24.01.2019
Published: 01.02.2019<http://www.poldradiol.com>

Case report

Repeating enlargement, recanalisations, and subarachnoid haemorrhages after middle cerebral artery aneurysm embolisation using pCONus stent and coils – a case report

Marcin Miś^{1B,D,E,F}, Arkadiusz Kacała^{1B,D,E,F}, Małgorzata Milnerowicz^{1B,D,E,F}, Maciej Miś^{2B,D,E}, Jerzy Garcarek^{1D,E}¹Department of General Radiology, Interventional Radiology, and Neuroradiology, Wrocław Medical University, Wrocław, Poland²Department of Neurosurgery, Wrocław Medical University, Wrocław, Poland

Abstract

Purpose: Large and wide-necked bifurcation aneurysms remain technically challenging to treat by the endovascular approach. Several endovascular strategies have been established in recent years for treating wide-necked bifurcation aneurysms, such as balloon-assisted coiling, stent-assisted coiling, waffle cone technique (WCT), and intrasaccular flow disruptors.

Case report: A 64-year-old woman was diagnosed with three intracranial aneurysms of the right and left middle cerebral artery and right internal carotid artery. She was qualified for endovascular treatment of the left middle cerebral artery (LMCA) aneurysm because it posed the greatest risk of rupture. Due to complicated morphology, a pCONus stent and coils were chosen for treatment. Three months later the right middle cerebral artery aneurysm was embolised and the woman was scheduled for second-stage treatment of the LMCA aneurysm. One week before the planned admission the woman was diagnosed with subarachnoid haemorrhage (SAH) in the region of the previously treated LMCA aneurysm, and the second-stage treatment was conducted with a good result. The woman was discharged in improved condition. Three months later the woman was once again admitted with SAH – an enlarged LMCA aneurysm was observed and immediate third-stage embolisation was performed, but due to complications of SAH the woman eventually died.

Conclusions: On the basis of the presented case we would like to emphasise the importance of sufficient initial coil packing and frequent control of neck region of the aneurysm for the long-term stability and safety after pCONus-assisted coiling of intracranial aneurysms.

Key words: intracranial aneurysm, middle cerebral artery, subarachnoid haemorrhage, therapeutic embolisation.

Introduction

Large and wide-necked bifurcation aneurysms remain technically challenging to treat by the endovascular approach. The pCONus stent (Phenox) is a stent-like endovascular device aiding retention of coils within wide-necked bifurcation aneurysms. We report a fatal case of treatment of a large unruptured cerebral aneurysm of the middle cerebral artery using a pCONus stent and coils

followed by repeating enlargement, recanalisations, and subarachnoid haemorrhages.

Case report

A 64-year-old, non-smoking woman, treated for hypertension manifesting with headaches and vertigo, underwent CT angiography of the head, in which three aneurysms were detected. She was referred to planned

Correspondence address:

Arkadiusz Kacała, Department of General Radiology, Interventional Radiology, and Neuroradiology, Wrocław Medical University, Wrocław, Poland,
e-mail: arkadiusz.kacala@gmail.com

Authors' contribution:

A Study design · B Data collection · C Statistical analysis · D Data interpretation · E Manuscript preparation · F Literature search · G Funds collection

Table 1. Characteristics of the patient's aneurysms

Localisation	Height (mm)	Width (mm)	Depth (mm)	Neck (mm)	Dome-to-neck ratio	Additional information
Left middle cerebral artery (LMCA)	22.40	22.73	11.49	8.77	3.90	Both M2 branches arising from the dome of the aneurysm
Right middle cerebral artery (RMCA)	8.77	4.91	5.22	4.45	2.28	
Right internal carotid artery (RICA)	3.44	3.56	3.87	3.22	2.31	Located in cavernous segment of RICA

endovascular embolisation and prepared with dual anti-platelet therapy (DAPT) for seven days before the procedure. The 3D digital subtraction arteriography (DSA) confirmed three brain aneurysms, as described in Table 1.

The decision to perform left middle cerebral artery (LMCA) aneurysm embolisation was taken. Because of the large neck and M2 branches arising from the dome of an aneurysm posing a risk of coil protrusion, the pCONus

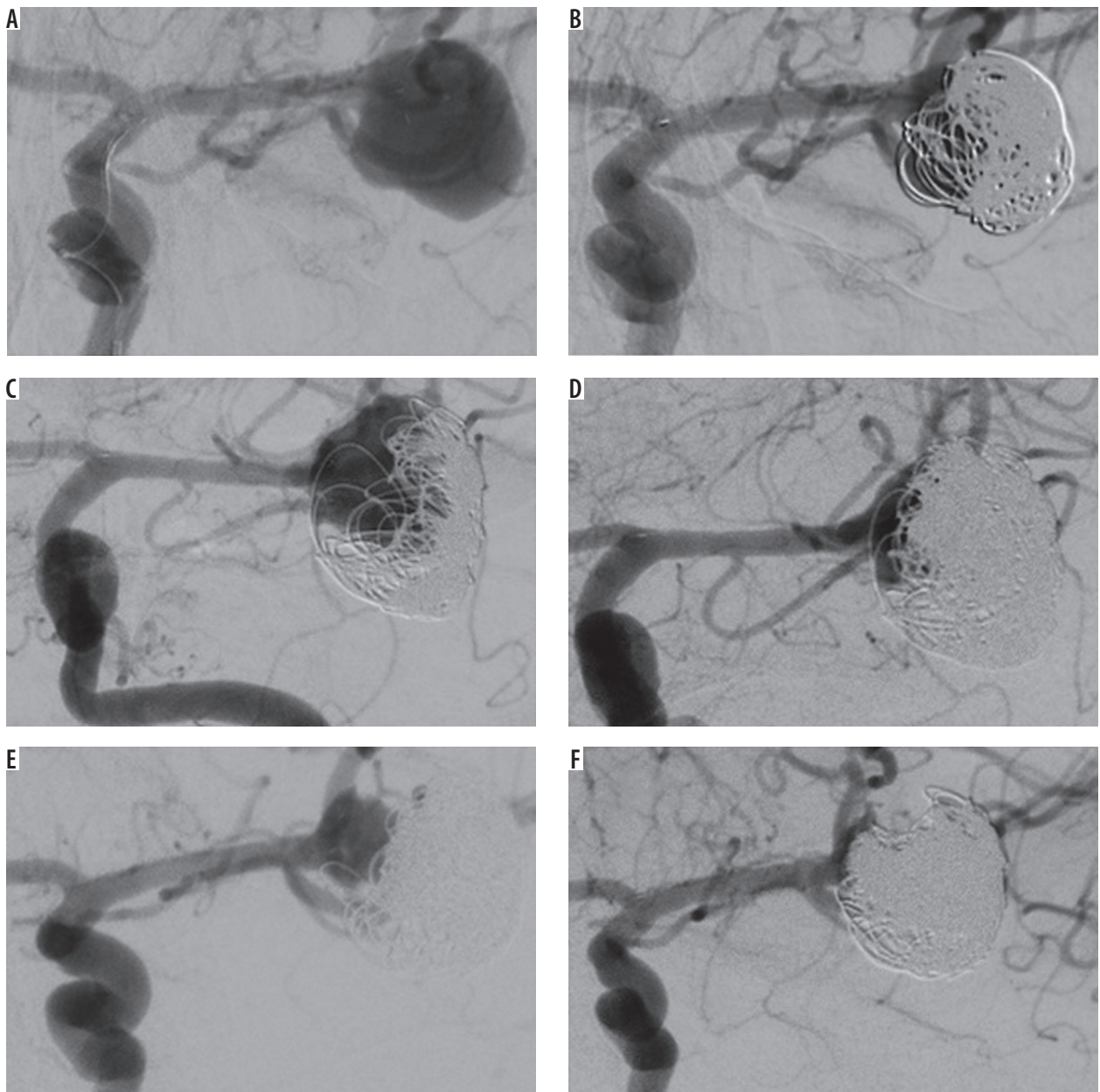


Figure 1. A) Wide-necked left middle cerebral artery aneurysm before embolisation; pCONus is positioned at the neck. B) Immediate angiographic control after first embolisation shows a remnant aneurysm with contrast agent inside the sac. C) Angiography after 13 months shows compression of coils and recanalisation of an aneurysm. D) Immediate angiographic control after second embolisation – the dome of an aneurysm filled with an additional 7 coils. E) Arteriography after 16 months (second SAH) shows once again the coil compression with recanalisation of an aneurysm. F) Immediate angiographic control after third embolisation with 7 additional coils – complete exclusion of the dome with the neck remnant

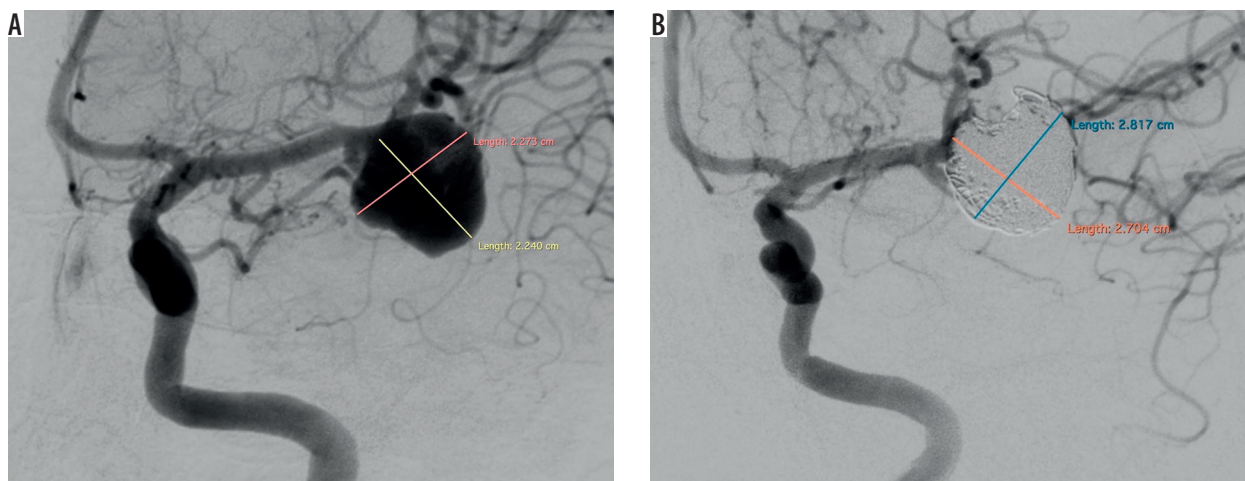


Figure 2. Comparison of size of left middle cerebral artery (LMCA) aneurysm before first and after last embolisation. **A)** Wide-necked LMCA aneurysm before embolisation (22.73 × 22.40 mm). **B)** LMCA aneurysm after last embolisation (28.17 × 27.04 mm). Significant difference in size of the aneurysm is visible

4-20-10-F stent (Phenox) was positioned and detachable coils were implanted into the aneurysmal dome (Figures 1A, B). Due to the complex morphology of the aneurysm and the repeating coil protrusion, the coiling implantation was stopped before complete obliteration was achieved. The pCONus device was then detached and control angiography confirmed the flow of all arising branches and contrast opacification within the coil interstices of a residual aneurysm (Modified Raymond-Roy classification – 3A). Postoperatively the patient did not show any symptoms of neurological dysfunction, DAPT was continued, and the patient was scheduled for the right middle cerebral artery (RMCA) embolisation in three months and discharged. DAPT was continued for three months and then only aspirin (150 mg) was administered.

Three months later the patient was readmitted. The RMCA aneurysm was embolised with detachable coils and was completely excluded from the circulation with preservation of the blood flow in the parent vessels, with no complications during or after the procedure. The LMCA aneurysm was controlled and showed subtle coil compression compared to the previous angiography. The patient was scheduled for second-stage treatment of the LMCA aneurysm but refused to be admitted to the hospital due to family reasons.

One year after LMCA aneurysm embolisation the patient was admitted for control DSA, which showed the complete obliteration of the RMCA aneurysm and enlargement of the LMCA aneurysm with recanalisation and compression of coils. The woman was once again scheduled for second-stage treatment of the LMCA aneurysm.

One week before the planned second-stage embolisation, she was readmitted due to subarachnoid haemorrhage (SAH). On examination, the patient was conscious, in logical verbal contact, and with positive meningeal symptoms and right hemiparesis – Hunt and Hess scale score of 3. CT of the head revealed SAH with hyperdense

blood localised mainly in the left hemisphere grooves. The urgent DSA revealed enlargement and recanalisation of the LMCA aneurysm with coil compression compared to the previous examination (Figure 1C). The dome of the remaining sac was completely filled with detachable coils, and the aneurysm was excluded from the circulation, retaining blood flow in the parent vessels. Adequate occlusion was achieved with dome embolisation and neck remnant. There were no technical or neurological procedure-related complications. The slight right hemiparesis retracted, and the patient was discharged with clinical improvement (Hunt and Hess scale score of 1).

Three months after last hospitalisation the patient was urgently readmitted diagnosed with SAH from a ruptured aneurysm of the LMCA, in severe condition, unconscious, intubated, on assisted breathing, neurologically manifesting anisocoria, and right-sided hemiparesis. CT of the head showed SAH and large intracerebral haemorrhage surrounding the embolised aneurysm in the left fronto-temporo-parietal region with mass effect, displacement of the middle structures to the right side, and the presence of blood in the ventricular system. Emergency neurosurgical decompression of the intracerebral haematoma was performed, followed by embolisation of the LMCA aneurysm. DSA showed again enlargement and coil compression with recanalisation of the aneurysm. The remnant part of the aneurysm sac was 9 × 12 mm (Figure 1E). Embolisation of the LMCA aneurysm was performed immediately with detachable coils, achieving a similar result to the previous procedure, with a complete exclusion of the dome with the neck remnant (Figures 1F and 2). After the procedure the patient remained in a serious condition – unconscious and intubated. During further hospitalisation the patient did not require any surgical re-intervention. In severe condition she was transferred to the intensive care unit in her local hospital where she eventually died. A summary of the procedures and time at which the patient received them is shown in Table 2.

Table 2. Time and characteristics of procedures the patient underwent

Time after initial procedure (months)	Procedure	LMCA aneurysm	RMCA aneurysm	RICA aneurysm (not treated)	Patient condition at discharge (modified Rankin Scale)
0	LMCA embolisation	MRRC 3a			1
3	RMCA embolisation	MRRC 3a	MRRC 1	Stable in size	1
12	Follow-up DSA	Enlargement and coil compaction	MRRC 1	Stable in size	1
13	SAH – urgent LMCA embolisation	Enlargement, coil compaction and rupture – postoperatively MRRC 2	MRRC 1	Stable in size	2
16	SAH – urgent LMCA embolisation	Enlargement, coil compaction and rupture – postoperatively MRRC 2	MRRC 1	Stable in size	5

LMCA – left middle cerebral artery, RMCA – right middle cerebral artery, DSA – 3D digital subtraction arteriography, SAH – subarachnoid haemorrhage, MRRC – Modified Raymond-Ray Classification

Discussion

Several endovascular strategies have been established in recent years for the treatment of wide-necked bifurcation aneurysms, such as balloon-assisted coiling, stent-assisted coiling, waffle cone technique (WCT), and intrasaccular flow disruptors. The pCONus stent is dedicated to WCT: it consists of stent-based support for the proximal part of the parent vessel with clover-shaped petals creating an effective scaffold for the aneurysm. Current endovascular treatment with the pCONus is reported to be an effective therapeutic option for managing patients with wide-necked bifurcation aneurysms [1-4].

The physicians that performed the embolisation have extensive experience in using the pCONus stent; they introduced the novel technique of combined use of a pCONus and a Solitaire stent for the treatment of complex intracranial aneurysms [5]. We believe that the treatment decisions were correct because the team ensured frequent control of the patient, and when it became clear that there was a need for second-stage embolisation the patient was immediately scheduled. Unfortunately, the woman could not be admitted due to personal reasons, and when the woman was scheduled for the second time, unfortunately, she developed SAH one week before admission to hospital. The second embolisation ended with neck remnant, although the dome was fully occluded, but it did not prevent the aneurysm from enlargement and rupture in the region between the distal end of pCONus stent and coil mass. Our team was surprised with the unfortunate outcome of treatment – it contributed to the authors' decision to search for similar cases in the literature and to publish this one.

There are suggestions that the use of a pCONus stent may change in some cases the haemodynamic situation by directing the bloodstream toward an aneurysm instead of diverting it [6,7]. This theory was not confirmed by Pérez *et al.* [8] in their *in vitro* study. On the other hand, there are similar reports of complete aneurysm occlusions assisted with a pCONus stent, which showed residual aneurysm perfusion and aneurysm enlargement in the follow-up DSA [9,10]. Aneurysm size (≥ 10 mm) and incomplete initial occlusion are two major predictive factors of aneurysm recanalisation, and after first intervention both were present in our patient when the first SAH occurred but not in the second case of SAH [11-13]. We cannot exclude that concurrence of all of these factors may have contributed to the recurrent expansions and ruptures of an LMCA aneurysm.

Conclusions

Large, wide-necked bifurcation MCA aneurysms are often treatable with a pCONus stent and coils. In cases when an aneurysm is initially not fully occluded, this technique may not prevent rupture and could promote coil compaction and aneurysm enlargement, leading to severe complications. On the basis of the presented case, we would like to emphasise the importance of sufficient initial coil packing and frequent control of the neck region of the aneurysm for the long-term stability and safety after pCONus-assisted coiling of intracranial aneurysms.

Conflict of interest

The authors declare no conflict of interest.

References

- Lubicz B, Morais R, Alghamdi F, et al. The pCONus device for the endovascular treatment of wide neck bifurcation aneurysms. *J Neurointerv Surg* 2016; 8: 940-944.
- Gory B, Aguilar-Pérez M, Pomeroy E, et al. pCONus device for the endovascular treatment of wide-neck middle cerebral artery aneurysms. *AJNR Am J Neuroradiol* 2015; 36: 1735-1740.

3. Fischer S, Weber A, Titschert A, et al. Single-center experience in the endovascular treatment of wide-necked intracranial aneurysms with a bridging intra-/extra-aneurysm implant (pCONus). *J Neurointerv Surg* 2016; 8: 1186-1191.
4. Aguilar Pérez M, Bhogal P, Martinez Moreno R, et al. Use of the pCONus as an adjunct to coil embolization of acutely ruptured aneurysms. *J Neurointerv Surg* 2017; 9: 39-44.
5. Bhogal P, Pérez MA, Moreno RM, et al. Combined use of a pCONus and a Solitaire stent: report of two cases. *Interv Neuroradiol* 2017; 23: 123-128.
6. Gao B, Baharoglu MI, Cohen AD, Malek AM. Stent-assisted coiling of intracranial bifurcation aneurysms leads to immediate and delayed intracranial vascular angle remodeling. *Am J Neuroradiol* 2012; 33: 649-654.
7. Aguilar-Pérez M, Kurre W, Fischer S, et al. Coil occlusion of wide-neck bifurcation aneurysms assisted by a novel intra- to extra-aneurysmatic neck-bridging device (pCONus): initial experience. *Am J Neuroradiol* 2014; 39: 965-971.
8. Pérez MA, Henkes H, Bouillot P, et al. Intra-aneurysmal hemodynamics: Evaluation of pCONus and pCANvas bifurcation aneurysm devices using DSA optical flow imaging. *J Neurointerv Surg* 2016; 8: 1197-1201.
9. Signorelli F, Sturiale CL, La Rocca G, et al. Giant basilar artery aneurysm involving the origin of bilateral posterior cerebral and superior cerebellar arteries: neck reconstruction with pCONus-assisted coiling. *Acta Neurochir Suppl* 2017; 124: 129-134.
10. Ulfert C, Pfaff J, Schönenberger S, et al. The pCONus device in treatment of wide-necked aneurysms: technical and midterm clinical and angiographic results. *Clin Neuroradiol* 2018; 28: 47-54.
11. Gory B, Aguilar-Pérez M, Pomero E, et al. One-year Angiographic Results After pCONus Stent-Assisted Coiling of 40 Wide-Neck Middle Cerebral Artery Aneurysms. *Neurosurgery* 2017; 80: 925-933.
12. Gory B, Rouchaud A, Saleme S, et al. Endovascular treatment of middle cerebral artery aneurysms for 120 nonselected patients: a prospective cohort study. *AJNR Am J Neuroradiol* 2014; 35: 715-720.
13. Raymond J, Guilbert F, Weill A, et al. Long-term angiographic recurrences after selective endovascular treatment of aneurysms with detachable coils. *Stroke* 2003; 34: 1398-1403.