

NOVEMBER
8-11, 2012
LISBON,
PORTUGAL

**17TH WORLD CONGRESS ON
CONTROVERSIES IN
OBSTETRICS, GYNECOLOGY
& INFERTILITY (COGI)**

Editor **Z. Ben-Rafael**

ISBN 978 88 6521 063 5

All rights reserved. No part of this publication may be reproduced, stored in a retrieval system, or internet communication system or transmitted in any form, or by any means, electronic, mechanical, photocopying, recording or otherwise, without the prior permission, in writing, from the publisher.

© Copyright 2013 MONDUZZI EDITORIALE S.r.l.

MONDUZZI EDITORIALE

Via B. Eustachi, 12 – 20129 Milano – Italy

Phone (+) 39-02-20404031 – Fax (+) 39-02-20404044

www.monduzzieditore.it

e-mail: monduzzi@monduzzieditore.it

Layout: ESN – Rastignano – Bologna – Italy

Printed in January 2013 by EB.O.D. – Milano – Italy

Single ultrasound evaluation for follicle and endometrium during ovulation induction compare with progesterone midluteal phase

J. Dewantiningrum

Medical Faculty Diponegoro University, Semarang, Central Java, Indonesia

SUMMARY

Ideally, there are many times ultrasound examination during ovulation induction. These examination are time and money consuming. Planning a single ultrasound examination at 12th days is necessary from the point view of developing country to reduce a cost. Mature follicle has significant correlation with progesterone level during single ultrasound evaluation at 12th days. But none of these parameters ultrasound (mature follicle, endometrial thickness and triple line pattern) could predict ovulation.

INTRODUCTION

Based on research past years ago, ultrasound has a valuable tool for investigation of folliculogenesis and predict endometrial receptivity during ovulation induction.¹ According to follicle size providing information mature follicle, so patient can be consented when to administer hCG. Progesterone midluteal phase is a reliable, simple and minimally invasive for predicting ovulation.² Ideally, there are many times ultrasound examination during ovulation induction, since day 10th.^{2,3} These examination are time and money consuming. Assuming of folliculogenesis during ovulation induction has a same schedule and menstrual cycle is 28 days, so follicle mature can be found at day 12th. Therefore, planning a single ultrasound examination at day 12th is necessary from the point view of developing country to reduce a cost. The objective of this study is to point out whether mature follicle, endometrial thickness or triple line pattern could predict ovulation and compare with mid progesterone luteal phase as an indicator of ovulation.

MATERIALS AND METHODS

This research was secondary data analysis of research about comparing two kinds of ovulation induction drug, clomiphene citrate and letrozole. A total of 40 women got ovulation induction drug (letrozole or clomiphene citrate) at day 3th until 7th and also evaluated for follicles and endometrial growth ultrasound at day 12th. At day 21th, subjects were checked progesterone serum as an indicator of ovulation. During ovulation induction, growth of follicle can be predicted, so progesterone examination can be done at day 21th.² Mature follicle was defined if diameter \geq 18 mm.⁴ Endometrial evaluation were endometrial thickness⁵ and triple line pattern⁶. The analysis was done to know whether correlation, sensitivity and specificity ultrasound parameter compare with mid luteal progesterone.

RESULTS AND CONCLUSION

The correlation between mature follicle and progesterone was significant ($r=0,5$, $p=0,03$). But no correlation between endometrial thickness and progesterone ($r=0,01$, $p= 0,94$) and between triple line pattern and progesterone $r=0,02$, $p=0,88$).

	Ovulation	Correlation(r)	<i>p</i>
Mature follicle		0,5	0,03
Yes	30		
No	8		
Endometrial Thickness		0,01	0,94
\geq 6 mm	20		
< 6 mm	18		
Triple line pattern		0,02	0,88
Yes	21		
No	17		
Phi Correlation			

Tab. 1 - Correlation among mature follicle, endometrial thickness and triple line pattern to mid luteal phase progesterone.

	Sensitivity (95% CI)	Specificity (95% CI)
Mature follicle	88,9 % (50,67% - 99,41%)	3,22 % (0,1% - 18,51%)
Endometrial Thickness	94,73 % (71,89% - 99,72%)	4,7 % (0,2% - 25,87%)
Triple line pattern	94,44% (70,62% - 99,7 %)	4,5 % (0,2% - 24,88%)

Tab. 2 - Sensitivity and specificity among mature follicle, endometrial thickness and triple line pattern to mid luteal phase progesterone.

Sensitivity mature follicle, endometrial thickness and triple line pattern are high, but all of those parameter have low specificity.

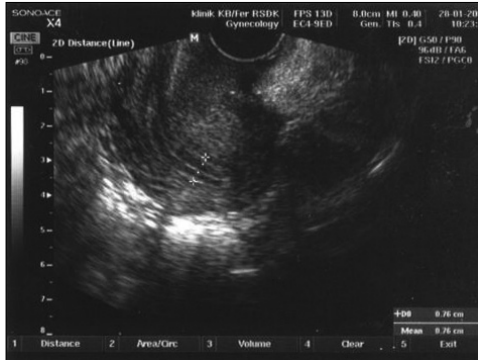

Fig. 1 - Endometrial evaluation.

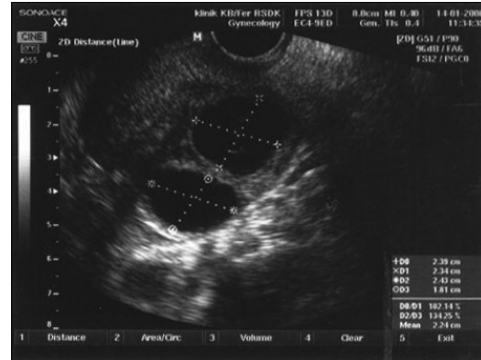


Fig. 2 - Follicle evaluation.

Mature follicle has significant correlation with progesterone level during single ultrasound evaluation at day 12th. But none of these parameters ultrasound (mature follicle, endometrial thickness and triple line pattern) could predict ovulation.

REFERENCES

1. Seibel MM, McArdle CR, Thompson IE, Berger MJ, Taymor ML. The role of ultrasound in ovulation induction: a critical appraisal. *Fertil Steril* 1981;36 (5):573-7.
2. Speroff L, Fritz MA. Female infertility. In *Clinical Gynecologic, Endocrinology and Infertility*. 7th ed. Philadelphia:Lippincott Williams and wilkins;2005.p.1013-213.
3. Homburg R. Clomiphene citrate-end of an era ? A mini review. *Hum. Reprod journal*. Available in: www.humrep.com
4. Kupesic S, Kurjak A, Bjelos D. Sonographic in infertility. In Kurjak A, Chervenak FA editors. *Textbook of ultrasound in obstetrics and gynecology*. United Kingdom: Parthenon publishing group; 2003. p.658-90.
5. Kupesic S. Sonographic imaging in infertility. Arenas JB, Kurjak A editors. In *textbook of transvaginal sonography*. India: Jaype brothers medical publisher; 2005. p.357-82.
6. Sanders RC. The role of ultrasound in the management of infertility. In Wallach EE, Zacur HA. *Reproductive Medicine and Surgery*. 1st ed. St. Louis Missouri: Mosby-year book, Inc; 1995. p. 1031-45.