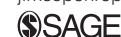



Successful treatment of feline leishmaniosis using a combination of allopurinol and N-methyl-glucamine antimoniate

Journal of Feline Medicine and Surgery
Open Reports
1–7

© The Author(s) 2016
Reprints and permissions:
sagepub.co.uk/journalsPermissions.nav
DOI: 10.1177/2055116916630002
jfmsoopenreports.com



Maria Alexandra Basso¹, Cátia Marques¹, Marcos Santos¹, Ana Duarte¹, Hugo Pissarra¹, L Miguel Carreira¹, Lídia Gomes¹, Ana Valério-Bolas², Luís Tavares¹, Gabriela Santos-Gomes² and Isabel Pereira da Fonseca¹

Abstract

Case summary This work describes the diagnosis and successful treatment of a 2-year-old domestic cat infected with *Leishmania* species and presenting fever, and ulcerative and nodular skin lesions after being treated for pyodermatitis for 1 year without clinical improvement. After anamnesis the cat was submitted to a complete clinical examination. Blood was collected for determination of haematological and biochemical parameters, detection of feline leukaemia virus (FeLV), feline immunodeficiency virus (FIV), feline coronavirus (FCoV) and *Leishmania* amastigotes. Fine-needle aspiration puncture from the skin nodules was also performed. After definitive diagnosis the animal was treated and followed up over a 2 year period. The animal tested negative for FIV-specific antibodies, FeLV antigen and feline coronavirus RNA. *Leishmania* amastigotes in the skin nodules were confirmed by cytology and molecular diagnosis. Treatment was initiated with allopurinol, resulting in a slight clinical improvement. Thus, N-methyl-glucamine antimoniate was added and administered for 30 days, with complete closure of the ulcerative lesions in the hindlimbs requiring a surgical approach. Close monitoring of the patient in the following 24 months indicated that combined therapy was safe and clinical cure was achieved without further relapses or side effects.

Relevance and novel information Considering the increasing number of feline leishmaniosis cases and the inconsistent results of most therapeutic protocols described in the literature, the use of new approaches, especially in refractory cases, is essential. Although the use of allopurinol and N-methyl-glucamine antimoniate is off-label in cats, in this case the combination treatment was followed by an extensive analytical monitoring, supporting their safety and effectiveness.

Accepted: 8 January

Introduction

The occurrence of feline leishmaniosis (FeL) has increased worldwide, revealing a possible role of cats in leishmaniosis epidemiology. Better accuracy of laboratory techniques has improved the diagnosis of this disease, and changes in ecosystems over the last few years associated with the use of repellents on dogs might play a role in sandflies' altered feeding patterns in urban areas, leading to infections in other mammalian hosts.^{1–3}

¹Centre for Interdisciplinary Research in Animal Health, Faculty of Veterinary Medicine, University of Lisbon, Lisbon, Portugal

²Global Health and Tropical Medicine, Institute of Hygiene and Tropical Medicine, New University of Lisbon, Lisbon, Portugal

Corresponding author:

Isabel Pereira Fonseca DVM, PhD, Centre for Interdisciplinary Research in Animal Health, Faculty of Veterinary Medicine, University of Lisbon, Avenida da Universidade Técnica, 1300-477 Lisbon, Portugal
Email: ifonseca@fmv.ulisboa.pt



Creative Commons Non Commercial CC-BY-NC: This article is distributed under the terms of the Creative Commons

Attribution-NonCommercial 3.0 License (<http://www.creativecommons.org/licenses/by-nc/3.0/>) which permits non-commercial use, reproduction and distribution of the work without further permission provided the original work is attributed as specified on the SAGE and Open Access pages (<https://us.sagepub.com/en-us/nam/open-access-at-sage>).

Worldwide epidemiological surveys of *Leishmania* species causing feline asymptomatic infection and FeL have been reported.^{4,5} In Europe, Spain had the first described FeL case in 1932.⁶ Some authors claim that low prevalence of FeL in endemic areas may be related to a natural resistance to the parasite in cats.⁷ Moreover, the number of clinical cases may be underestimated, leading to few reports and lack of information by clinicians and owners. Although Portugal is an endemic country for canine leishmaniosis caused by *Leishmania infantum*, there are few published clinical reports of FeL, with the first description of it in 1994 in Sesimbra, followed by others in Porto and Lisbon.^{8–10}

Despite occasional reports of ocular and visceral disease, dermatological, mucocutaneous/mucosal presentations and lymph node enlargement are the most frequent clinical features.^{11–14} Clinical suspicion is based on history, clinical signs and clinicopathological abnormalities. Diagnosis is confirmed with parasitological and serological methods.¹⁵

A long-term administration of allopurinol (10–20 mg/kg q12h or q24h) is the most recommended treatment protocol for FeL,^{10,11,15} however, similarly to dogs, recurrence can occur if the infection is not cleared. Some authors have reported a good clinical response using N-methyl-glucamine antimoniate monotherapy (5–100 mg/kg or 375 mg/cat q24h SC or IM under different protocols).^{8,15}

This study aims to describe the treatment of a recurring clinical case of FeL in a cat receiving combined therapy (allopurinol and N-methyl-glucamine antimoniate).

Case description

A 2-year-old domestic European neutered male cat was referred to the Veterinary Teaching Hospital of the Faculty of Veterinary Medicine, University of Lisbon,

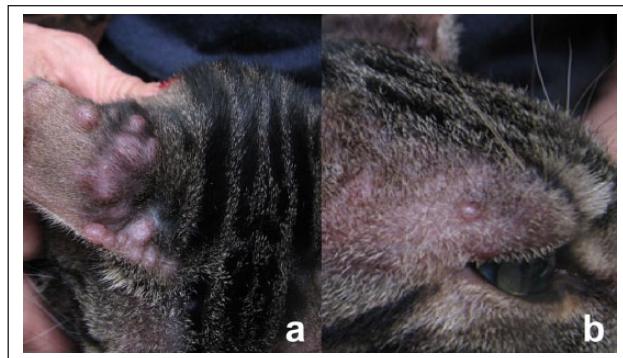


Figure 1 Skin nodules measuring 2–10 mm in diameter were distributed on the (a) outer pinnal surfaces and (b) orbital regions. Most of them were observed on the right pinna, where they gathered with coalescing patterns

with multiple nodular skin lesions (Figure 1), ulcerative dermatitis involving the four limbs (Figure 2) and fever. The cat was referred 1 year after the onset of skin lesions and was previously treated for a presumptive pyodermatitis with prednisolone (1 mg/kg PO q12h for 12 days) and amoxicillin/clavulanic acid (20 mg/kg PO q12h for 6 days), followed by doxycycline (5 mg/kg PO q12h for 8 days), and showed no clinical improvement.

The cat was not vaccinated, but had been regularly protected against ectoparasites with fipronil and imidacloprid. At first admission, mild fever (39.5°C) and dermatological lesions on the head and limbs were the only abnormalities on physical examination. About 20–25 skin nodules measuring 2–10 mm in diameter were distributed on the outer pinnal surfaces (Figure 1a) and orbital regions (Figure 1b). Most of them were observed on the pinnae, where they gathered with coalescing patterns. Differential diagnosis was pyodermatitis, allergic reaction, autoimmune disease, neoplastic disease or

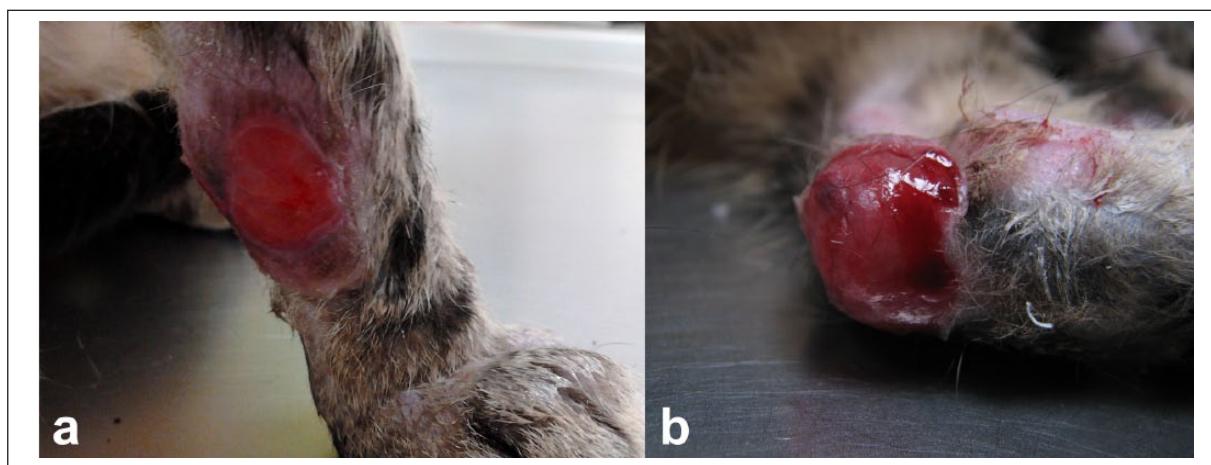


Figure 2 Single spots (between 20 and 50 mm in diameter) of ulcerative dermatitis that had raised margins affecting the (a) antebrachial and (b) hock regions after disinfection of lesions

leishmaniosis. Single spots (20–50 mm in diameter) of ulcerative dermatitis, which had raised margins, affected the antebrachial (Figure 2a) and hock (Figure 2b) regions.

A complete blood count and biochemical profile were used to evaluate the clinical status of the cat before treatment, after treatment and at all follow-up examinations. Urinalysis and urinary protein: creatinine ratio were evaluated 6 months after treatment. Haematological and biochemical values were within the reference intervals. Serum protein electrophoresis showed an albumin: globulin ratio, but a slight hypergammaglobulinaemia was evident (Table 1).

The patient was tested for FIV-specific antibodies, FeLV antigens by ELISA (ViraCHEK/FIV and

ViraCHEK/FeLV, respectively; Synbiotics) and immunofluorescence antibody test (IFAT) using an adaptation of *Leishmania* Spot IFI kit (bioMérieux) with a fluorescently labelled anticat IgG conjugate (anticat IgG MegaCor; MegaCor Diagnostik), which was used to quantify anti-*Leishmania* antibodies (cut-off 1:40). Previous studies, including more than 100 cats, validated this latter test in inter-laboratory assays using known positive and negative sera, with results as expected. Repeatability and reproducibility were also assessed (unpublished results). The cat tested negatively for FIV antibodies and FeLV antigens, but was positive for anti-*Leishmania* antibodies, with a titre \geq 1:1280 (Table 1).

Table 1 Haematological, biochemical and serological results obtained before, during and after treatment

	Day 0	Day 45	Month 6	Month 12	Month 18	Month 24	Reference intervals
Haemogram							
Leukocytes ($\times 10^3/\mu\text{l}$)	13.3	15.0	10.0	NA	NA	15.6	5.5–19.5
Erythrocytes ($\times 10^6/\mu\text{l}$)	6.6	9.2	10.2	NA	NA	9.5	5.0–10.0
Platelets ($\times 10^3/\mu\text{l}$)	185	327	129	NA	NA	223	300–700
Haemoglobin (g/dl)	9	12	14	NA	NA	13	8–15
PCV (%)	29	40	40	NA	NA	43	24–45
Non-segmented neutrophils ($/\mu\text{l}$)	0	0	0	NA	NA	0	0–300
Segmented neutrophils ($/\mu\text{l}$)	9.520	11,000	6.468	NA	NA	7.000	2.500–12.500
Lymphocytes ($/\mu\text{l}$)	2.856	3000	2.980	NA	NA	2.800	1.500–7.000
Monocytes ($/\mu\text{l}$)	0.5	0.3	0.1	NA	NA	4.7	0–850.0
Eosinophils ($/\mu\text{l}$)	0.680	0.600	0.390	NA	NA	0	0–1.500
Basophils ($/\mu\text{l}$)	0	0	0	NA	NA	0	Rare
Biochemical parameters							
Urea (mg/dl)	48.7	52.9	50.0	NA	52.3	59.9	0–82.0
Creatinine (mg/dl)	0.73	0.97	1.07	NA	1.23	1.25	0.70–2.20
ALT (U/l)	37	37	35	NA	45	37	10–130
AST (U/l)	NA	NA	NA	NA	28	28	8–35
Alkaline phosphatase (U/l)	NA	NA	43	NA	21	32	20–220
Calcium (mmol/l)	NA	NA	NA	NA	9.52	8.92	9.40–11.20
Total bilirubin (mg/dl)	NA	NA	NA	NA	0.06	0.05	0.08–0.30
Potassium (mmol/l)	NA	NA	NA	NA	4.4	4.8	3.5–5.2
Chloride (mmol/l)	NA	NA	NA	NA	123	137	108–128
Sodium (mmol/l)	NA	NA	NA	NA	156	156	143–153
Biliary acids ($\mu\text{mol/l}$)	NA	NA	NA	NA	3.68	3.53	1–20.00
Inorganic phosphorus (mmol/l)	NA	NA	NA	NA	4.4	4.8	2.4–6.0
Urinary protein: creatinine ratio (%)	NA	NA	0.04	NA	NA	NA	<0.50
Serum protein electrophoresis							
Total protein (g/dl)	6.9	7.1	6.8	NA	7.2	NA	5.7–7.9
Albumin (g/dl)	2.6	2.7	3.1	NA	3.2	NA	2.1–4.0
Alpha 1 (g/dl)	0.4	0.1	0.1	NA	0.1	NA	0.2–1.1
Alpha 2 (g/dl)	1.1	1.4	1.6	NA	1.7	NA	0.4–0.9
Beta (g/dl)	0.4	1.1	0.9	NA	1.1	NA	0.9–1.9
Gama (g/dl)	2.4	1.9	1.1	NA	1.1	NA	1.3–2.2
Albumin: globulin ratio (%)	0.60	0.60	0.90	NA	0.80	NA	0.45–1.30
Antibody titre (IFAT)							
Anti- <i>Leishmania</i> antibodies	\geq 1:1280	1:320	1:80	1:80	1:40	1:40	

PCV = packed cell volume; ALT = alanine aminotransferase; AST = aspartate aminotransferase; NA = not available

Fine-needle aspiration puncture from the ear skin nodules was performed. Smears were stained with Giemsa (Merck) and examined under an optical microscope (Olympus BX51). The aspirate was also used for further molecular and parasitological analysis. The smears revealed *Leishmania* amastigotes (Figure 3), and absence of bacteria/neutrophilic infiltration or characteristic cells of autoimmune diseases.

DNA extraction from EDTA blood samples, skin nodules and lymph node aspirates was carried out with a DNeasy Blood & Tissue kit (Qiagen). Detection of feline coronavirus from plasma was performed by reverse transcription quantitative PCR (RT-qPCR),¹⁶ targeting the 3' end of the virus genome. Additionally, qPCR using *L. infantum*-specific Taqman probes targeting the kinetoplast minicircle DNA (kDNA) was also performed to determine the initial and follow-up parasitic load.¹⁷

RT-qPCR was negative for coronavirus, while qPCR of skin nodules and blood samples were positive for *L. infantum* kDNA, showing a parasitic load of 1700 and 0.1 parasites per 50 ng DNA, respectively (Table 2).

Nodular and lymph node aspirates were inoculated in Schneider's Insect Medium (Sigma-Aldrich) supplemented with 0.6% (w/v) of CaCl₂, 5 mM HEPES, 10% fetal bovine serum, 100 U/ml penicillin and 100 µg/ml streptomycin.¹⁸ Cultures were maintained at 24°C in a refrigerated incubator (Lovibond) and observed by optical microscopy after 8 days of incubation. Viable promastigotes were observed.

The cat was treated orally with 10 mg/kg allopurinol q12h and a three-layered bandage was applied to the four limbs. Medical follow-up was performed every 2 days during the first fortnight. After 15 days of treatment with allopurinol only a slight clinical improvement was noted. Fever persisted and skin ulcers seemed equally profound. Therefore, a combined therapeutic protocol not yet approved for cats was suggested to the owner. N-methyl-glucamine antimoniate administration is off-label in cats, with only a few published cases of FeL treated with this drug. After owner consent was obtained, treatment was reinforced with 50 mg/kg N-methyl-glucamine antimoniate (Glucantime; Merial) q24h SC for 30 consecutive days. This study was conducted in the framework of FCT Project PTDC/CVT/118566/2010, with the agreement of the Ethics Committee and Animal Welfare of the Faculty of Veterinary Medicine, University of Lisbon.

During and after treatment there were no abnormalities reported by the owner. The cat maintained a normal physical condition¹⁹ and examination apart from the skin lesions.

Total remission of skin nodules on the head, as well as the foreleg ulcers, was achieved (Figure 4), with

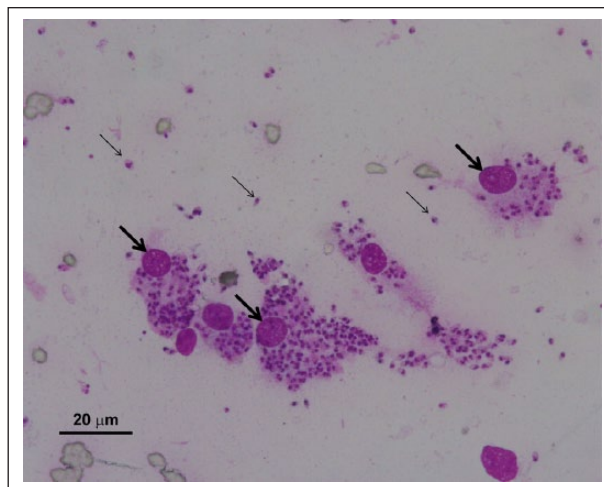


Figure 3 Fine-needle aspiration smear of a skin nodule showing many extracellular (small arrows) and intracellular *Leishmania* amastigotes in the cytoplasm of macrophages (large arrows). Giemsa stain, scale bar = 20 µm

body temperature being normalised on day 45. Complete closure of the hindlimb ulcerative lesions did not occur owing to an extreme tension in those regions, which required surgery (Figure 5). One hour prior to surgery, the cat received a therapeutic protocol of Ringer's lactate fluid therapy, amoxicillin with clavulanic acid (8.75 mg/kg IM), buprenorphine (0.02 mg/kg IM) and methylprednisolone succinate (1 mg/kg IM). Propofol (4 mg/kg IV) was used for the induction of anaesthesia followed by isoflurane for its maintenance. Debridement and excision of the wound edges were performed and a horizontal mattress suture was used for closure. The excised edges of the defect were immersed in a 10% formalin solution to allow for histopathological study.

The cat was medicated with antibiotic (amoxicillin/clavulanic acid, 12.5 mg/kg PO q12h for 10 days) and a non-steroidal anti-inflammatory (tolfenamic acid 4 mg/kg PO q 24h for 4 days), and was assessed 48 h after surgery in order to evaluate the regions operated on; stitches were removed on days 6 and 12. As an integral part of

Table 2 *Leishmania infantum* parasitic load detected by quantitative PCR before, during and after treatment

	Parasitic load (number of parasites/50 ng total DNA)			
	Day 0	Day 30	Day 45	Month 18
Skin nodules	1700	10	NA	NA
Blood	0.10	0.05	0.05	0
Lymph node	NA	100.0	0.1	0

NA = not available

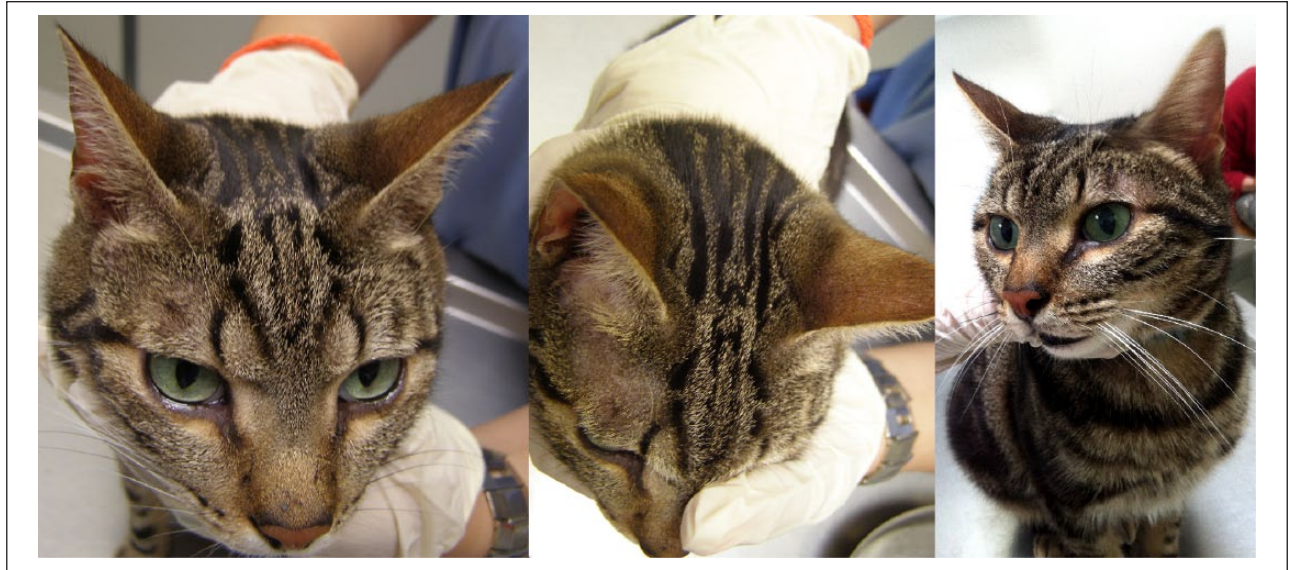


Figure 4 Cat 18 months after treatment with allopurinol and N-methyl-glucamine antimoniate (Glucantime; Merial), illustrating the absence of skin nodules on the ears and head

the healing process, the cat was maintained for 2 weeks with Robert-Jones bandages. The complete healing of hindlimb lesions was achieved 1 month after surgery (Figure 6).

Histological examination of the removed tissues showed a granulomatous-like inflammatory response with some foci of lymphocytes, activated plasmacytes and occasional intracellular amastigote forms of *Leishmania* species in macrophages.

The slight hypergammaglobulinaemia observed at admission returned to normal values. No further clinical or laboratory changes were detected 6, 18 and 24 months after the end of treatment (Table 1). Allopurinol was stopped when antibody titres decreased to 1:40 (18 months). At month 24, the antibody level remained unchanged.

Parasitic load decreased in both blood and skin nodules after 15 days of combined treatment. The lymph node parasitic load showed a pronounced decrease after day 30 (Table 2).

Discussion

FeL is rarely reported in various parts of the world.^{4,20,21} In Europe, a total of 46 clinical cases have been published between 1989 and 2014, namely in Italy, France, Spain and Switzerland, with regards to cats imported from Spain.^{4,20,22–24} In Portugal, although the first clinical case was reported in the 1990s,⁸ only in recent years have epidemiological studies been conducted to better understand the role of cats in the biological cycle of *Leishmania* species. In the metropolitan region of Lisbon, although the detection of anti-*Leishmania* antibody titres points to

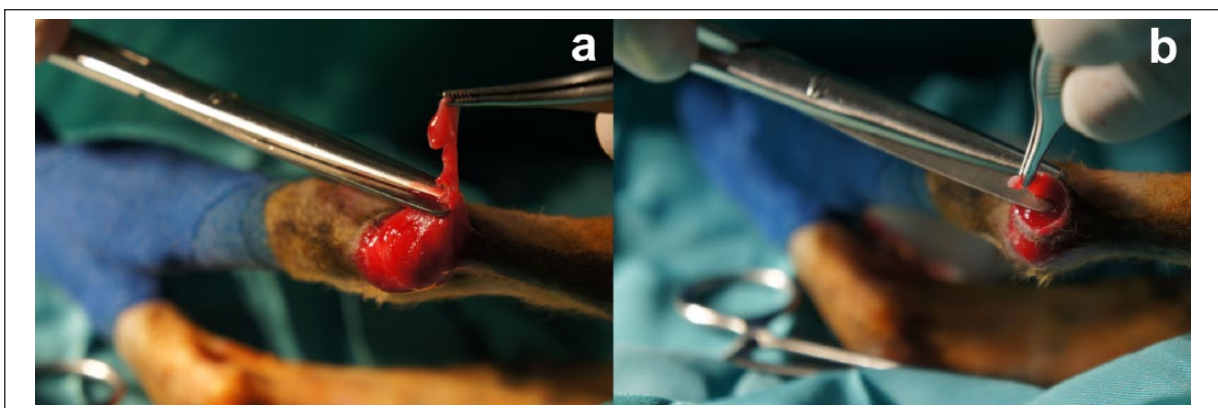


Figure 5 Intraoperative images showing the excision of the defect edges in the (a) right and (b) left hindlimb

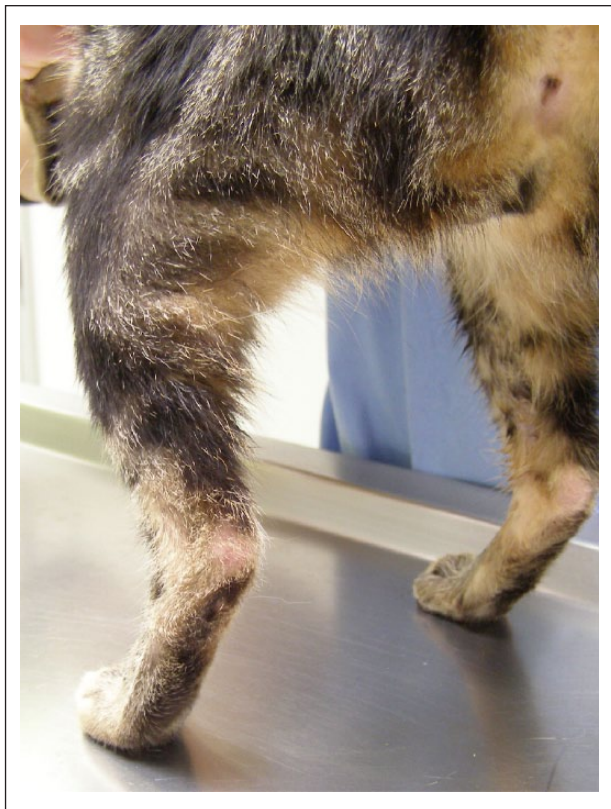

Figure 6 Hindlimbs 4 weeks after surgery

a low prevalence or, at least, low cat–parasite contact (1.3%), the detection of *Leishmania* DNA indicates high levels of infection in stray (30.4%) and domestic cats (20.3%). Even so, most of the animals are asymptomatic.³

This disease is seldom considered during the differential diagnosis in cats, as in the present clinical case, where the animal had been previously treated for other diseases for 1 year.

Dermatological findings in FeL usually include erythema, alopecia, papules, nodules, ulcers or crusts, with the head being the most affected region, but other body parts may also be affected.^{17,25,26} In the present clinical case, as the ulcers in the hindlimbs were severely contaminated at first examination, it was not possible to determine whether the fever was a systemic sign of FeL or a consequence of secondary bacterial infection. Concerning the available therapeutics for FeL, this cat was first treated with allopurinol, which was insufficient despite its use being common in the treatment of canine leishmaniosis. Even though the use of allopurinol is off-label in both dogs and cats, there is a more extensive clinical experience of efficacy and safety in dogs. Under the scope of ‘cascade’ a combined therapeutic not yet approved for cats was suggested to the owner.

Initially, this cat showed very high antibody titres by IFAT as seen in other reported cases of FeL.^{12,13,23} After 2

weeks of the combined protocol the decrease in antibody titre and parasitic load was evident. Similarly to canine leishmaniosis, there was a gradual decline in antibody titre and it took around 18 months to attain the lowest titre. Clinical remission was accomplished together with surgical recovery in less than 2 months. Furthermore, this therapeutic protocol seemed to be safe for the cat as no analytical change or side effect was observed.

By 24 months of follow-up, no relapses had occurred. Regarding the albumin levels, although within the reference interval, the increase noted, associated with the decrease in gamma(γ)-globulin values, kept the total protein concentration within the reference interval, which is in agreement with the remission of clinical signs.

Cats may live for years with a slowly progressing chronic disease, even without a specific anti-*Leishmania* treatment.^{4,5,15} However, in this case, the severity of cutaneous lesions was the clinician’s main concern leading her to search for another therapeutic protocol when monotherapy with allopurinol proved to be insufficient.

Although full clinical recovery was achieved, it is possible that a much reduced number of viable parasites may have persisted (mainly in the lymph nodes) after the end of the treatment. However, as it is not possible to guarantee total elimination or its dispersion to the skin, parasite transmission should be kept in mind. These facts highlight the need for new topical insecticides aiming to prevent sandfly bites in cats, as all insecticide products currently registered against sandflies contain permethrin, which is extremely toxic to cats.

Conclusions

The present work describes a successful case of FeL treatment in a young cat, negative for FIV antibodies and FeLV antigenaemia, after a 15 day refractory period using allopurinol monotherapy. To the best of our knowledge, this is the first report of a combined therapy, using allopurinol and N-methyl-glucamine antimoniate with no relapses or adverse effects, resulting in a possible new treatment for use in FeL refractory cases.

Acknowledgements We thank Merial (Portugal) for supplying the Glucantime used during the cat’s treatment.

Conflict of interest The authors declared no potential conflicts of interest with respect to the research, authorship, and/or publication of this article.

Funding Funding for this work was provided by the Portuguese Foundation for Science and Technology (FCT) with co-participation of European Union Fund (FEDER) through the research project PTDC/CVT/118566/2010 and UID/CVT/00276/2013, and grants SFRH/BD/77886/2011 and SFRH/BD/101467/2014.

References

- 1 WHO. **Control of the leishmaniases. Report of a meeting of the WHO Expert Committee on the Control of Leishmaniases.** WHO Technical Report Series, 2010, p 186.
- 2 Campino L and Maia C. **Epidemiologia das leishmanioses em Portugal.** *Acta Med Port* 2010; 23: 859–864.
- 3 Maia C, Gomes J, Cristóvão J, et al. **Feline *Leishmania* infection in a canine leishmaniasis endemic region, Portugal.** *Vet Parasitol* 2010; 174: 336–340.
- 4 Pennisi MG, Cardoso L, Baneth G, et al. **LeishVet update and recommendations on feline leishmaniosis.** *Parasit Vectors* 2015; 8: 302.
- 5 Soares CSA, Duarte SC and Sousa SR. **What do we know about feline leishmaniosis?** *J Feline Med Surg.* Epub ahead of print 26 June 2015. DOI: 1098612X15589358.
- 6 Ayllon T, Tesouro MA, Amusategui I, et al. **Serologic and molecular evaluation of *Leishmania infantum* in cats from Central Spain.** *Ann N Y Acad Sci* 2008; 1149: 361–364.
- 7 Solano-Gallego L, Rodríguez-Cortés A, Iniesta L, et al. **Cross-sectional serosurvey of feline leishmaniosis in ecoregions around the northwestern Mediterranean.** *Am J Trop Med Hyg* 2007; 76: 676–680.
- 8 Costa-Durão J, Rebelo E, Peleteiro M, et al. **First case of leishmaniosis in domestic cat (*Felis catus domesticus*) detected in Portugal (Sesimbra).** *Rev Port Cienc Vet* 1994; 511: 140–144.
- 9 Maia C, Sousa C, Ramos C, et al. **First case of leishmaniosis caused by *Leishmania infantum* genotype E in a cat with a concurrent nasal squamous cell carcinoma.** *J Feline Med Surg Open Rep* 2015; 1 (2). DOI: 10.1177/20551169155939690.
- 10 Marcos R, Santos M, Malhão F, et al. **Pancytopenia in a cat with visceral leishmaniosis.** *Vet Clin Path* 2009; 38: 201–205.
- 11 Leiva M, Lloret A, Peña T, et al. **Therapy of ocular and visceral leishmaniosis in a cat.** *Vet Ophthalmol* 2005; 8: 71–75.
- 12 Verneuil M. **Ocular leishmaniosis in a cat: case report.** *J Fr Ophthalmol* 2013; 36: e67–e72.
- 13 Pennisi M, Venza M, Reale S, et al. **Case report of leishmaniosis in four cats.** *Vet Res Commun* 2004; 28: 363–366.
- 14 Simões-Mattos L, Bevilacqua C, Mattos M, et al. **Feline leishmaniosis: uncommon or unknown?** *Rev Port Cienc Vet* 2004; 9: 79–97.
- 15 Pennisi MG, Hartmann K, Lloret A, et al. **Leishmaniosis in cats: ABCD guidelines on prevention and management.** *J Feline Med Surg* 2013; 15: 638.
- 16 Gil S, Leal RO, Duarte A, et al. **Relevance of feline interferon omega for clinical improvement and reduction of concurrent viral excretion in retrovirus infected cats from a rescue shelter.** *Res Vet Sci* 2013; 94: 753–763.
- 17 Helhazar M, Leitão J, Duarte A, et al. **Natural infection of synanthropic rodent species *Mus musculus* and *Ratus norvegicus* by *Leishmania infantum* in Sesimbra and Sintra – Portugal.** *Parasit Vectors* 2013; 6: 88.
- 18 Hockmeyer WT, Kager PA, Rees PH, et al. **The culture of *Leishmania donovani* in Schneider's insect medium: its value in the diagnosis and management of patients with visceral leishmaniosis.** *Trans R Soc Trop Med Hyg* 1981; 75: 861–863.
- 19 Bjornvad CR and Laflamme DP. **Cat body condition score.** <http://www.wsava.org/sites/default/files/Body%20condition%20score%20chart%20cats.pdf> (2013, accessed August 2, 2015).
- 20 Ozon C, Marty P, Pratlong F, et al. **Disseminated feline leishmaniosis due to *Leishmania infantum* in Southern France.** *Vet Parasitol* 1998; 75: 273–277.
- 21 Rougeron V, Catzeflis F, Hide M, et al. **First clinical case of cutaneous leishmaniosis due to *Leishmania (Viannia) braziliensis* in a domestic cat from French Guiana.** *Vet Parasitol* 2011; 181: 325–328.
- 22 Poli A, Abramo F, Barsotti P, et al. **Feline leishmaniosis due to *Leishmania infantum* in Italy.** *Vet Parasitol* 2002; 106: 181–191.
- 23 Rufenacht S, Sager H, Müller N, et al. **Two cases of feline leishmaniosis in Switzerland.** *Vet Rec* 2005; 156: 542–545.
- 24 Pennisi M. **Feline leishmaniosis from A to Z** [in Italian]. In: Veterinarie E (ed). *Leishmaniosi canina: recenti acquisizioni su pidemiologia, implicazioni cliniche, diagnosi, terapia e prevenzione.* Cremona: Edizioni Veterinarie, 2010, pp 59–64.
- 25 Hervás J, Chacón-Manrique de Lara F, Sanchez-Isarria M, et al. **Two cases of feline visceral and cutaneous leishmaniosis in Spain.** *J Feline Med Surg* 1999; 1: 101–105.
- 26 Pennisi MG, Lupo T, Malara D, et al. **Serological and molecular prevalence of *Leishmania infantum* infection in cats from southern Italy.** *J Feline Med Surg* 2012; 14: 656–657.