

Case Reports

An Unusual Cause of Camptocormia

Sahil Mehta^{1*}, Rajender Kumar² & Vivek Lal¹¹Department of Neurology, Post Graduate Institute of Medical Education and Research, Chandigarh, IN, ²Department of Nuclear Medicine and PET/CT, Post Graduate Institute of Medical Education and Research, Chandigarh, IN

Abstract

Background: Camptocormia is defined as forward flexion of the spine that manifests during walking and standing and disappears in recumbent position. The various etiologies include idiopathic Parkinson's disease, multiple system atrophy, myopathies, degenerative joint disease, and drugs.

Case Report: A 67-year-old diabetic female presented with bradykinesia and camptocormia that started 1 year prior to presentation. Evaluation revealed levosulpiride, a dopamine receptor blocker commonly used for dyspepsia, to be the culprit.

Discussion: It is well known that dopamine receptor blockers cause parkinsonism and tardive syndromes. We report a rare and unusual presentation of camptocormia attributed to this commonly used gastrointestinal drug in the Asian population.

Keywords: Levosulpiride, camptocormia, parkinsonism

Citation: Mehta S, Kumar R, Lal V. An unusual cause of camptocormia. Tremor Other Hyperkinet Mov. 2019; 9. doi: 10.7916/D8Q82X3K

*To whom correspondence should be addressed. E-mail: mehtasahilpgi@gmail.com

Editor: Elan D. Louis, Yale University, USA

Received: October 1, 2018 **Accepted:** November 13, 2018 **Published:** February 13, 2019

Copyright: © 2019 Mehta et al. This is an open-access article distributed under the terms of the Creative Commons Attribution–Noncommercial–No Derivatives License, which permits the user to copy, distribute, and transmit the work provided that the original authors and source are credited; that no commercial use is made of the work; and that the work is not altered or transformed.

Funding: None.

Financial Disclosures: None.

Conflicts of Interest: The authors report no conflicts of interest.

Ethics Statement: All patients that appear on video have provided written informed consent; authorization for the videotaping and for publication of the videotape was provided.

Introduction


Camptocormia is defined as forward flexion of the spine ($>45^\circ$) that manifests during walking and standing and disappears in recumbent position.¹ It has both neurological and musculoskeletal causes. Various neurological etiologies include idiopathic Parkinson's disease (PD), multiple system atrophy, genetic forms of PD, dystonias, myopathies, and drugs.² We report a patient who presented with camptocormia and evaluation disclosed an unusual cause.

Case report

A 67-year-old female presented with change in speech, slowness while walking, and forward bending of the spine that had started 1 year prior to presentation. Examination revealed slow hypophonic speech, bilateral bradykinesia, and rigidity. Gait was slow and short stepped, with gait initiation difficulty and the presence of camptocormia (Video 1). She was a known diabetic for 3 years and had a history of coronary artery disease with an ejection fraction of 45–50%. Her renal functions were deranged (creatinine 1.9 mg/dL) suggestive of diabetic nephropathy.

There were no red flags in the form of autonomic dysfunction, pyramidal or cerebellar signs, or cognitive problems to suggest atypical parkinsonism. She was evaluated to determine the cause of her symmetrical parkinsonism. Magnetic resonance imaging of the brain was normal. 18 F FLUORODOPA (FDOPA) positron emission tomography showed bilateral symmetrical uptake of dopamine in the striatum, thus ruling out a degenerative cause for parkinsonism (Figure 1A,B). Other relevant investigations such as the thyroid profile and liver function tests were normal. On review of her medical records, it was found that patient had been taking levosulpiride 75 mg/day for the last 18 months for her dyspeptic symptoms. There was a significant improvement in bradykinesia within 10 days of stopping levosulpiride and starting levodopa/carbidopa (125 mg three times daily). However, the improvement in camptocormia was modest and began 2 months after the introduction of levodopa.

At 6 months, there was significant improvement in her symptoms, and the patient is currently on regular doses of levodopa/carbidopa (Video 1). She is able to intermittently keep her posture erect with the reappearance of camptocormia.



Video 1. Segment 1. The presence of camptocormia and short step gait.

Segment 2. The near complete resolution of camptocormia with improvement in slowness.

Discussion

Camptocormia is defined as abnormal and severe flexion ($>45^\circ$) of the thoracolumbar spine that manifests during walking and standing and disappears in recumbent position.¹ It can occur in sporadic PD, post-encephalitic and parkin-related PD as well as in multiple system atrophy.² The pathogenesis of camptocormia in PD is not fully understood. It may represent a PD-related abnormal posture or be attributed either to truncal dystonia or to a severe form of rigidity.³ It usually responds poorly to levodopa but may be alleviated to some extent with botulinum toxin therapy and deep brain stimulation.^{4,5} It can also occur as a tardive syndrome after exposure to dopamine receptor blockers such as levosulpiride.⁶ Focal myopathy involving the paravertebral muscles is another postulate reported in the literature.⁷

Levosulpiride, a commonly used prokinetic in Asian countries, is a substituted benzamide that inhibits D2 receptors in the central nervous system and gastrointestinal tract. It is well known to cause parkinsonism, tremor, and tardive dyskinesia.^{6,8}

Neuronal damage in the striatum via oxidative stress and glutamatergic transmission on prolonged exposure to neuroleptics underlies the pathophysiology of tardive syndromes.⁹ Another school of thought is that hypersensitivity or upregulation of D2 receptors lead to maladaptive plasticity in the synapses and the cortico-striatal transmission, which leads to abnormal involuntary movements.¹⁰ There is also evidence of pharmacogenomics in the pathophysiology of tardive syndromes. Various polymorphisms in the genes encoding D2 and D3 receptors and 5-HT2A receptors, as well as in the *CYP2D6* gene, are known to influence the development of tardive syndromes.^{11,12}

It is well known that drug-induced parkinsonism almost always resolves when the causative agent is stopped.¹³ Tardive dystonias, on the other hand, are usually persistent, and spontaneous remissions are uncommon. Kiriakakis et al.¹⁴ in their study of 107 patients of tardive dystonia found that only 14% of patients showed remission after a mean duration of 8.5 years. The abnormal flexion of the spine in our patient took more than 2 months to resolve, and is therefore more likely to be

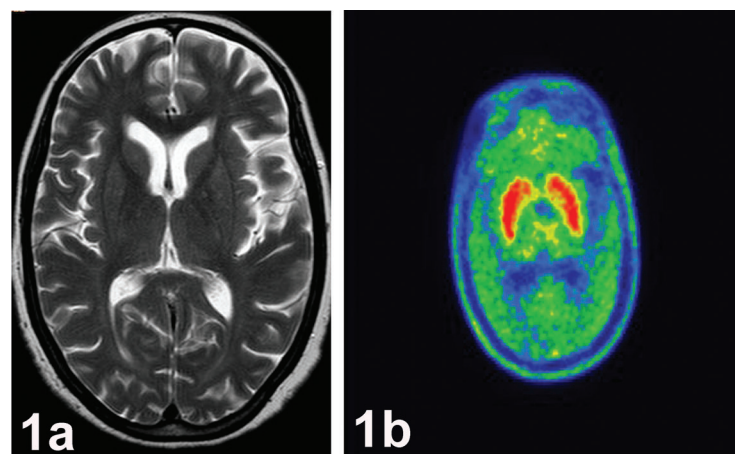


Figure 1. Structural and Functional Imaging of the Brain. (A) T2 weighted magnetic resonance imaging brain shows normal appearing bilateral basal ganglia. (B) 18 F FLUORODOPA (FDOPA) positron emission tomography revealed adequate tracer uptake in bilateral striatum.

due to tardive dystonia. Bradykinesia that resolves in less than 2 weeks suggests it to be the result of drug-induced parkinsonism.

Presentation with camptocormia was slightly unusual in our patient. In our patient, the strong temporal relationship of occurrence of camptocormia with levosulpiride intake in the presence of normal structural and functional imaging indicates a causative association. To the best of our knowledge, levosulpiride-induced camptocormia has not been previously reported in the literature.

References

1. Azher SN, Jankovic J. Camptocormia: pathogenesis, classification, and response to therapy. *Neurology* 2005;65:355–359. doi: 10.1212/01.wnl.0000171857.09079.9f
2. Ali F, Matsumoto JY, Hassan A. Camptocormia: etiology, diagnosis and treatment response. *Neurol Clin Pract* 2018;8:240–248. doi: 10.1212/CPJ.0000000000000453
3. Margraf NG, Wrede A, Deuschl G, Schulz-Schaeffer WJ. Pathophysiological concepts and treatment of camptocormia. *J Parkinsons Dis* 2016;6:485–501. doi: 10.3233/JPD-160836
4. Bertram KL, Stripe P, Colosimo C. Treatment of camptocormia with botulinum toxin. *Toxicon* 2015;107 (Pt A):148–153. doi: 10.1016/j.toxicon.2015.06.004
5. Lyons M, Boucher O, Patel N, Birch B, Evidente V. Long-term benefit of bilateral subthalamic deep brain stimulation on camptocormia in Parkinson's disease. *Turk Neurosurg* 2012;22:489–492. doi: 10.5137/1019-5149JTN.3857-10.0
6. Shin HW, Kim MJ, Kim MS, Lee MC, Chung SJ. Levosulpiride induced movement disorders. *Mov Disord* 2009;24:2249–53. doi: 10.1002/mds.22805
7. Margraf NG, Wrede A, Rohr A, Schulz-Schaeffer WJ, Raethjen J, Eymess A, et al. Camptocormia in idiopathic Parkinson's disease: a focal myopathy of the paravertebral muscles. *Mov Disord* 2010;25:542–551. doi: 10.1002/mds.22780
8. Mathew T, Nadimpally US, Prabhu AD, Nadig R. Drug-induced Parkinsonism on the rise: beware of levosulpiride and its combinations with proton pump inhibitors. *Neurol India* 2017;65:173–174. doi: 10.4103/0028-3886.198175
9. Aquino CC, Lang AE. Tardive dyskinesia syndromes: current concepts. *Parkinsonism Relat Disord* 2014;20:S113–117. doi: 10.1016/S1353-8020(13)70028-2
10. Hauser RA, Truong D. Tardive dyskinesia: out of the shadows. *J Neurol Sci* 2018;389:1–3. doi: 10.1016/j.jns.2018.02.009
11. Dolzan V, Plesnicar BK, Serretti, Mandelli L, Zalar B, Koprivsek J, Breskvar K. Polymorphisms in dopamine receptor DRD1 and DRD2 genes and psychopathological and extrapyramidal symptoms in patients on long-term antipsychotic treatment. *Am J Med Genet B Neuropsychiatr Genet* 2007;144B:809–815. doi: 10.1002/ajmg.b.30544
12. Wilffert B, Al Hadithy AF, Singh VJ, Matroos G, Hoek HW, van OS J, et al. The role of dopamine D3, 5-HT2A and 5-HT2C receptor variants as pharmacogenetic determinants in tardive dyskinesia in African-Caribbean patients under chronic antipsychotic treatment: Curacao extrapyramidal syndromes study 1X. *J Psychopharmacol* 2009;23:652–659. doi: 10.1177/0269881108091594
13. Lopez-Sendon J, Mena MA, de Yebenes JG. Drug-induced parkinsonism. *Expert Opin Drug Saf* 2013;12:487–496. doi: 10.1517/14740338.2013.787065
14. Kiriakakis V, Bhatia KP, Quinn NP, Marsden CD. The natural history of tardive dystonia. A long-term follow-up study of 107 cases. *Brain* 1998;121(Pt 11):2053–2066. doi: 10.1093/brain/121.11.2053