

Case Reports

A Rare Presentation of Orthostatic Tremor as Abdominal TremorChristina Mousele^{1*}, Paul Bentley² & Yen F. Tai²¹National Hospital for Neurology and Neurosurgery, University College London Hospitals NHS Foundation Trust, Queen Square, London WC1N 3BG UK,²Division of Brain Sciences, Charing Cross Hospital, Imperial College London, Fulham Palace Road, London, W6 8RF UK**Abstract****Background:** Orthostatic tremor (OT) is a weight-bearing hyperkinetic disorder characterized by unsteadiness while standing that is relieved when sitting or walking.**Case report:** A 66-year-old male presented with a 5 year-history of tremor in his abdomen, but only when he stood in a stationary position. The tremor disappeared when he stood or walked. On examination, he had palpable tremor in his rectus abdominis and gastrocnemius virtually instantaneously after standing. His electromyography findings confirmed the presence of a 12-Hz tremor in the tibialis anterior while standing, with subharmonics recorded in the external obliques and rectus abdominis.**Discussion:** Our case illustrates an unusual presentation of OT. The diagnosis is supported by its characteristic frequency and specific appearance only during upright stance.**Keywords:** Orthostatic, tremor, frequency, idiopathic, abdomen**Citation:** Mousele C, Bentley P, Tai YF. A rare presentation of orthostatic tremor as abdominal tremor. Tremor Other Hyperkinet Mov. 2018; 8. doi: 10.7916/D8W10PTG*To whom correspondence should be addressed. E-mail: christinamousele92@gmail.com**Editor:** Elan D. Louis, Yale University, USA**Received:** August 27, 2018 **Accepted:** October 22, 2018 **Published:** December 4, 2018**Copyright:** © 2018 Mousele et al. This is an open-access article distributed under the terms of the Creative Commons Attribution–Noncommercial–No Derivatives License, which permits the user to copy, distribute, and transmit the work provided that the original authors and source are credited; that no commercial use is made of the work; and that the work is not altered or transformed.**Funding:** None.**Financial Disclosures:** None.**Conflicts of Interest:** The authors report no conflict of interest.**Ethics Statement:** All patients that appear on video have provided written informed consent; authorization for the videotaping and for publication of the videotape was provided.**Introduction**

Orthostatic tremor (OT) is a rare weight-bearing hyperkinetic disorder affecting station and gait. OT is characterized by unsteadiness during standing that is relieved by sitting or walking. It is confirmed on neurophysiological recording by the presence of a high-frequency tremor of 12- to 18-Hz in the legs, trunk, and sometimes, the arms, which is coherent in all muscles studied.¹ It differs from other common tremor disorders by two features: its uniquely high-frequency spectrum and specific modulation in an upright stance.² OT can be primary (idiopathic) or secondary.

Case report**Medical History**

A 66-year-old male presented with a 5-year history of tremor in his abdomen that only occurred when he stood in a stationary position. The tremor resolved when he sat or walked. Alcohol helped reduce the tremor severity. His symptoms had slowly exacerbated over time. There was no family history of neurological problems. His medications

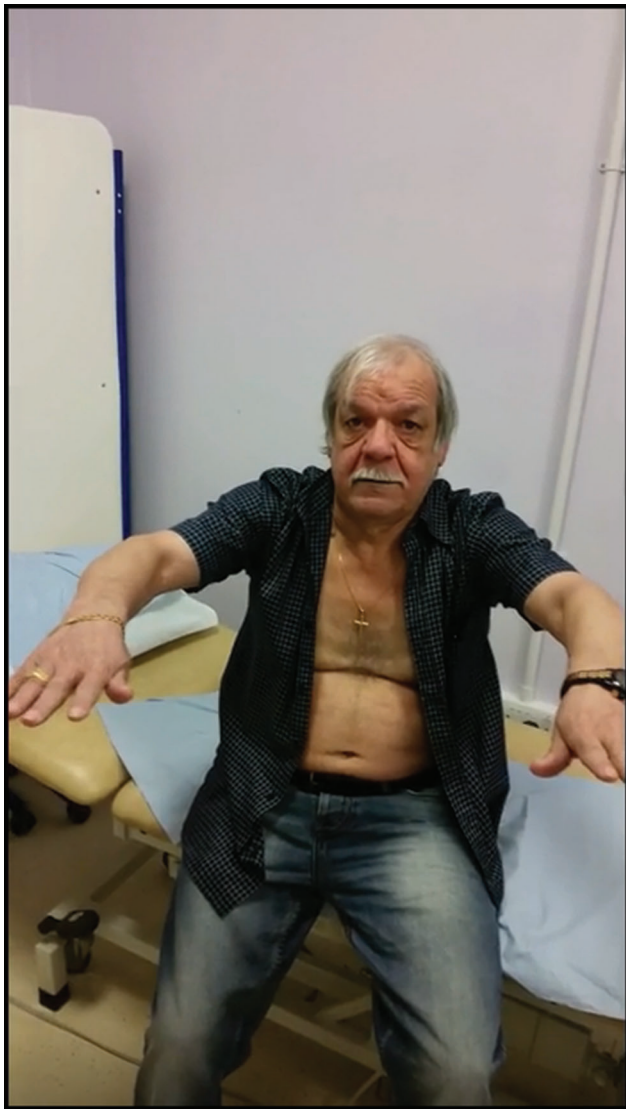
consisted of aspirin, dipyridamole, atorvastatin, bendroflumethiazide, and perindopril.

Examination

There was no hypomimia. He had slightly hypometric vertical saccades, but the rest of his eye movements were normal. There was minimal symmetrical postural tremor in his hands. He had visible and palpable tremor in his rectus abdominis and gastrocnemius almost immediately after standing (Video 1). The helicopter sign was positive in the abdomen but less so in the calves. He walked with a narrow gait without heel-to-shin ataxia. Deep tendon reflexes were normal, and his plantar responses were flexor. Brain magnetic resonance imaging (MRI) showed a mild degree of midline cerebellar volume loss, but his dopamine transporter scan was unremarkable.

Electromyogram (EMG)

His EMG examination showed no spontaneous activities or grouping (bursts) of motor units at rest when sitting on the bed. On standing, EMG bursts were noted at 11-12 Hz with the helicopter sign audible



Video 1. Tremor of the Rectus Abdominis and Gastrocnemius Muscles. Our patient's orthostatic tremor is shown. The tremor is evident in his rectus abdominis and gastrocnemius muscles bilaterally almost immediately after standing.

when the right tibialis anterior (TA) was examined. Bursts at about half the rate of TA frequency (5-6 Hz) were recorded when the external oblique and rectus abdominis were examined due to subharmonics of the high-frequency tremor spreading throughout the body.

Discussion

Our case illustrates an unusual presentation of OT. Its characteristic frequency and specific appearance only during upright stance support the diagnosis. According to the literature, a sizable number of OT patients have a low-frequency (5-10 Hz) postural arm tremor,³ which may represent a subharmonic of the higher frequency tremor typical of OT (12-18 Hz),⁴ spreading throughout the body. In our case, the low-frequency tremor in the abdomen was attributed to the same phenomenon.

Most cases of OT (75%) are idiopathic. Primary OT appears without evidence of any underlying structural brain disorder and must be differentiated from secondary OT.² The latter has been described in patients with essential tremor, hypokinetic-rigid syndrome, restless legs syndrome, Graves' disease, or cerebellar atrophy.⁴ In our case, there was mild midline cerebellar atrophy on brain MRI, but there were no other clinical signs to suggest a secondary pathology. While the frequency of OT in this patient was slightly lower than that mentioned in the consensus statement on OT by the Movement Disorder Society,⁵ there is increasing evidence to suggest that OT patients with a frequency of 10-13 Hz are clinically and electrophysiologically similar to OT patients with a higher frequency range (13-18 Hz).⁶

The pathophysiological mechanisms underlying primary OT are not fully understood. A functional imaging study associated this condition with abnormal bilateral cerebellar and contralateral lentiform and thalamic activation.⁷ Another study proposed that the unsteadiness is caused by tremulous disruption of proprioceptive afferent activity from the legs, causing co-contraction of the leg muscles to increase stability. This results in increased tremor-locked muscle activity, further blocking proprioceptive input.⁸

Pharmacological treatment of OT has often yielded insufficient benefit. Clonazepam is probably the first-line medication as it reduces tremor in about one-third of patients.⁴ Second-line therapies include gabapentin, primidone, and dopaminergic drugs.

Acknowledgments

I would like to thank Dr. Yen Fong Tai for his expert advice and encouragement throughout this project.

References

- Hassan A, van Gerpen JA. Orthostatic Tremor and Orthostatic Myoclonus: Weight-bearing Hyperkinetic Disorders: A Systematic Review, New Insights, and Unresolved Questions. *Tremor Other Hyperkinet Mov* 2016;6. doi: 10.7916/D84X584K
- Schöberl F, Feil K, Xiong G, Bartenstein P, la Fougère C, Jahn K, et al. Pathological ponto-cerebello-thalamo-cortical activations in primary orthostatic tremor during lying and stance. *Brain* 2017;140:83-97. doi: 10.1093/brain/aww268
- Yaltho TC, Ondo WG. Orthostatic tremor: a review of 45 cases. *Parkinsonism Relat Disord* 2014;20:723-5. doi: 10.1016/j.parkreldis.2014.03.013
- Benito-León J, Domingo-Santos A. Orthostatic Tremor: An Update on a Rare Entity. *Tremor Other Hyperkinet Mov* 2016;6. doi: 10.7916/D81N81BT
- Deuschl G, Bain P, Brin M. Consensus Statement of the Movement Disorder Society on Tremor. *Mov Disord* 1998;13:2-23. doi: 10.1002/mds.870131303
- Rigby HB, Rigby MH, Caviness JN. Orthostatic Tremor: A Spectrum of Fast and Slow Frequencies or Distinct Entities? *Tremor Other Hyperkinet Mov* 2015;5. doi: 10.7916/D8S75FHK
- Wills AJ, Thompson PD, Findley LJ, Brooks DJ. A positron emission tomography study of primary orthostatic tremor. *Neurology* 1996;46:747-52. doi: 10.1212/WNL.46.3.747
- Gerschlagner W, Brown P. Orthostatic tremor - a review. *Handb Clin Neurol* 2011;100:457-62. doi: 10.1016/B978-0-444-52014-2.00035-5