

Case Reports

Hemifacial Spasm in Mucopolysaccharidosis Type VI (Maroteaux–Lamy Syndrome)

Aneesh Karir¹, Michael Geraghty^{1,2}, Michael Vassilyadi^{1,3} & Asif Doja^{1,4*}

¹University of Ottawa Faculty of Medicine, Ottawa, ON, Canada, ²Division of Metabolics, Children's Hospital of Eastern Ontario, Ottawa, ON, Canada, ³Division of Paediatric Neurosurgery, Department of Surgery, Children's Hospital of Eastern Ontario, Ottawa, ON, Canada, ⁴Division of Neurology, Children's Hospital of Eastern Ontario, Ottawa, ON, Canada

Abstract

Background: Hemifacial spasms are involuntary contractions of the muscles of one side of the face.

Case Report: Here, we report a 5-year-old female patient with a significant past medical history, including mucopolysaccharidosis type VI, who also presented with hemifacial spasms. Further investigations showed narrowing of skull foramina and hydrocephalus, but no compression of the facial nerve. Carbamazepine was given to the patient, which caused cessation of the spasms.

Discussion: Currently, there is no literature discussing the relationship between hemifacial spasms and mucopolysaccharidosis type VI; we have proposed that mucopolysaccharide deposits or dural thickening may contribute to nerve irritation.

Keywords: Hemifacial spasm, mucopolysaccharidosis type VI

Citation: Karir A, Geraghty M, Vassilyadi M, Doja A. Hemifacial spasm in mucopolysaccharidosis type VI (Maroteaux-Lamy syndrome). Tremor Other Hyperkinet Mov. 2018; 8. doi: 10.7916/D8SX7WFQ

*To whom correspondence should be addressed. E-mail: adoja@cheo.on.ca

Editor: Elan D. Louis, Yale University, USA

Received: February 15, 2018 **Accepted:** May 7, 2018 **Published:** June 1, 2018

Copyright: © 2018 Karir et al. This is an open-access article distributed under the terms of the Creative Commons Attribution–Noncommercial–No Derivatives License, which permits the user to copy, distribute, and transmit the work provided that the original authors and source are credited; that no commercial use is made of the work; and that the work is not altered or transformed.

Funding: None.

Financial Disclosures: None.

Conflict of Interest: The authors report no conflict of interest.

Ethical Statement: This study was reviewed by the authors' institutional ethics committee and was considered exempted from further review.

Introduction

Hemifacial spasm (HFS) is a movement disorder characterized by involuntary, irregular, clonic, or tonic contractions of the muscles innervated by the facial nerve on one side of the face.¹ Patients with HFS usually present at between 40 and 50 years of age, and presentation during childhood is uncommon.² HFS can be either primary or secondary. Primary HFS results from the compression of the facial nerve at the root exit zone in the posterior cranial fossa by an aberrant or ectatic vessel, with the most common vessels involved being the superior cerebellar, anterior inferior cerebellar, or vertebral artery.³ Secondary HFS causes include cerebellopontine tumors, brainstem lesions, Bell's palsy, and structural abnormalities of the posterior cranial fossa.³

Maroteaux–Lamy syndrome, also known as mucopolysaccharidosis type VI, is caused by mutations in arylsulfatase B, resulting in accumulation of degraded glycosaminoglycans, dermatan sulfate, and chondroitin 4-sulfate.⁴ Common clinical findings include coarse facial

features, skeletal disease, joint abnormalities, respiratory disease, and cardiac abnormalities.⁵ Previously, mucopolysaccharidosis has not been associated with HFS; here, we report on a child with right-sided HFS and Maroteaux–Lamy syndrome.

Case report

A 5-year-old female patient was admitted to hospital with episodes of right eyelid droop and right facial grimace. These episodes occurred 10–13 times per day and were preceded by either vomiting or gagging, followed by a 3–4 minute episode of HFS. They were associated with feeding and chewing, but also occurred without food intake. There was no change in the level of consciousness during the HFS and no postictal phase. The HFSs were not associated with epileptiform activity when captured during prolonged video electroencephalography.

Physical examination revealed dysmorphic features such as macrocephaly, broad nasal bridge, short stature, frontal bossing, prominent eyes, and macrognathia. In addition to Maroteaux–Lamy syndrome,

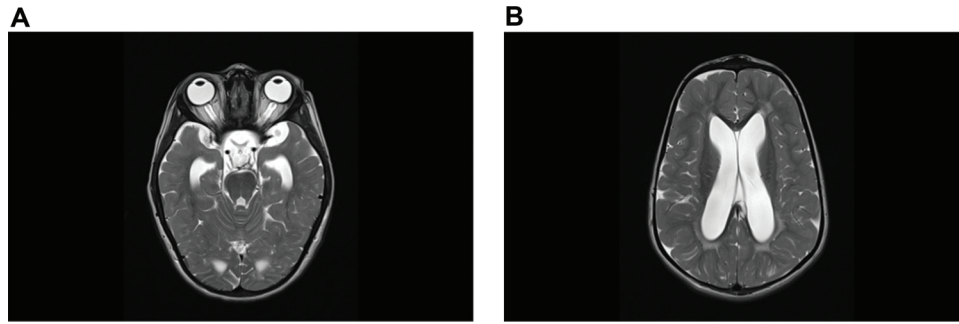


Figure 1. Magnetic Resonance Imaging of Patient with Hemifacial Spasm and Mucopolysaccharidosis Type VI. Axial T2 images demonstrating (A) increased cerebrospinal fluid space around the optic nerves and (B) ventricular enlargement.

her other past medical history includes esotropia, obstructive sleep apnea post tonsillectomy and -adenoidectomy, skeletal dysplasia, splenomegaly, cardiomegaly with thickening of all four valves, patent foramen ovale left–right shunting, otitis media, unspecified conductive hearing loss. Her 3-year-old brother also has mucopolysaccharidosis type VI.

A head magnetic resonance imaging (MRI) scan (Figure 1) revealed prominent perivascular cerebrospinal fluid (CSF) spaces around the corpus callosum, narrowing of the foramen magnum and bilateral jugular foramina, enlargement of the CSF spaces around the bilateral intraorbital optic nerves, and large ventricles. Despite this, the patient did not have any clinical signs of raised intracranial pressure (ICP), such as optic disc edema, even with longitudinal follow-up by ophthalmology over a 2-year period and no intervention was undertaken for increased ICP. The MRI did not show any evidence of impingement of cranial nerves III, IV, VI, and VII, and no evidence of compression at the stylomastoid foramen.

The patient was started on carbamazepine 75 mg twice a day (10 mg/kg/day), which caused immediate cessation of the spasms. A follow-up MRI again did not show any evidence of impingement of the previously mentioned cranial nerves.

Discussion

Previously, increased ICP has been associated with HFS, in a case report by Yamashita et al.⁶ However, this association is unlikely in our patient because of the lack of disc edema and signs of increased ICP. Thus, we report that this case illustrates the potential link between HFS and Maroteaux–Lamy syndrome. In the literature to date, there has been no mention of a relationship between HFS and Maroteaux–Lamy syndrome. In our case, because the patient clinically did not have raised ICP, it was hypothesized that the HFS may have been due to peripheral nerve irritation from dural thickening—despite this not being visualized on MRI—or from mucopolysaccharide deposits causing facial nerve irritation. Dilated Virchow–Robin spaces, which can often be seen in deposition disorders such as mucopolysaccharidosis, have been shown to cause HFS.⁷ However, our patient did not

have any dilated Virchow–Robin spaces in the brainstem, making this an unlikely etiology in our patient.

Our patient responded well to carbamazepine and various other anticonvulsants such as clonazepam and gabapentin, while other drugs such as anticholinergics, baclofen, and haloperidol have all been shown to have some efficacy in treating HFS.^{2,3} Currently, botulinum toxin injections are the most popular intervention for treatment.^{1–3} Microvascular decompression of the facial nerve at the cerebellopontine angle can also result in markedly improved HFS in the majority of patients, with success rates of over 90% in some series.⁸

The case report demonstrates the need to consider HFS as a possible diagnosis in children with abnormal facial movements, especially in those with an underlying disorder that may cause substrate accumulation and narrowing of the skull foramina.

References

1. Wang A, Jankovic J. Hemifacial spasm: clinical findings and treatment. *Muscle Nerve* 1998;21:1740–1747. doi: 10.1002/(SICI)1097-4598(199812)21:12<1740::AID-MUS17>3.0.CO;2-V
2. Tan NC, Chan LL, Tan EK. Hemifacial spasm and involuntary facial movements. *QJM* 2002;95:493–500. doi: 10.1093/qjmed/95.8.493
3. Chaudhry N, Srivastava A, Joshi L. Hemifacial spasm: the past, present and future. *J Neurolog Sci* 2015;356:27–31. doi: 10.1016/j.jns.2015.06.032
4. Litjens T, Hopwood JJ. Mucopolysaccharidosis type VI: structural and clinical implications of mutations in N-acetylgalactosamine-4-sulfatase. *Hum Mutat* 2001;18:282–95. doi: 10.1002/humu.1190
5. Valayannopoulos V, Nicely H, Harmatz P, Turbeville S. Mucopolysaccharidosis VI. *Orphanet J Rare Dis* 2010;5:5. doi: 10.1186/1750-1172-5-5
6. Yamashita S, Matsumoto Y, Tamiya T, Kawanishi M, Ogawa D, Nagao S. Disappearance of hemifacial spasm after ventriculoperitoneal shunting in a patient with achondroplasia. *Neurol Med Chir* 2005;45:104–7. doi: 10.2176/nmc.45.104
7. Solak Ö, Yaman M, Haktamr A, Aycicek A, Oruc S, Kirpiko O. Widening of Virchow–Robin spaces in the brain stem causing hemifacial spasm. *Eur J Radiol Extra* 2009;70:e1–3. doi: 10.1016/j.ejrex.2008.10.004
8. Jannetta PJ, Resnick D. Cranial rhizopathies. *Neurolog Surg* 1990;6:3771–84.