

Journal of Hip Preservation Surgery Vol. 5, No. 4, pp. 357–361
doi: 10.1093/jhps/hny046
Advance Access Publication 10 December 2018
Research article

OXFORD

ISHA—Richard Villar Best Clinical Paper Award: Acetabular labral tears in sexually active women: an evaluation of patient satisfaction following hip arthroscopy

Shruti Raut, Sachin Daivajna, Naoki Nakano and Vikas Khanduja *

Department of Trauma and Orthopaedics, Addenbrooke's Hospital, Cambridge University Hospitals NHS Foundation Trust,
Hills Road, Cambridge CB2 0QQ, UK.

*Correspondence to: V. Khanduja. E-mail: vk279@cam.ac.uk

Submitted 26 December 2017; Revised 27 September 2018; revised version accepted 20 October 2018

ABSTRACT

The aim of this study was to evaluate the effect of symptomatic labral tears on the sex lives of women and the effect of surgical intervention on hip symptoms during sexual intercourse. One hundred and twenty consecutive women who had undergone hip arthroscopy under a single surgeon at a tertiary referral centre were identified. A specific questionnaire was designed and sent to each of the patients. Data were collected on the nature of symptoms, if they experienced any hip pain during sexual intercourse and if this had impacted on their sex lives and the degree of resolution of hip symptoms after the procedure, on a scale of 1–10. One hundred and four responses were available. Ninety-two women reported that they were sexually active. Of these, 87 (94%) reported pain during intercourse affecting their sex life. Eight women reported hip pain for a few days following intercourse and four stated that they are often not able to continue on account of the pain. Mean patient satisfaction with a resolution of symptoms during intercourse was 7.8 out of the 10. Seventy-seven women reported a post-operative improvement in the hip symptoms experienced during sex. Labral tears do have a significant effect on the sex life of women. Hip arthroscopy to address the labral tear as well as any underlying pathology relieves the pain experienced by women during intercourse with, a resultant improvement in their sex lives.

INTRODUCTION

The acetabular labrum is a fibrocartilaginous structure within the hip joint. Its base attaches to the acetabulum on one side and blends in with the articular cartilage of the acetabulum on the other. The inner layers of the acetabulum are subjected to compressive and shear forces, and the capsular side, which comprises of dense connective tissue, is subjected to tension [1]. In health, its functions are to improve joint stability, provide a seal that helps to maintain synovial fluid pressure and improve joint lubrication [2, 3]. Acetabular labral tears are a major cause of hip pain, particularly in younger patients and can occur following acute trauma but can also be associated with childhood or congenital disorders of the hip such as Perthe's disease, developmental dysplasia of the hip and slipped upper femoral

epiphysis [4] as well as femoroacetabular impingement (FAI) [5–9]. Acetabular labral tears can be a significant cause of discomfort and disability with an undeniable impact on lifestyle [10]. The pain attributed to a labral tear is usually most noticeable when going from a seated to a standing position and many people also note pain during squatting or exercise or activities, which require rotation and flexion [3, 10, 11]. Anecdotally, it has been noted that some patients complain of pain in the hip or the groin during sexual intercourse. Given the sensitive nature of the subject matter, it is a topic rarely broached by the surgeon or the patient, and never in depth.

There are no studies to date that specifically address the effects of acetabular labral tears on the sexual lives of young women, or studies which look into the effect of surgical

intervention on the outcome of sexual lives of women. The aim of our study, therefore, was to evaluate the impact of labral tears and the underlying hip pathology on the sex lives of sexually active women and to establish whether there was any improvement in the hip symptoms experienced during sexual intercourse following arthroscopic intervention.

METHODS

We retrospectively evaluated 150 consecutive hip arthroscopies in female patients, performed by a single surgeon in a tertiary referral centre in the UK between January 2009 and September 2013. Of these, 120 patients were identified who underwent arthroscopic labral debridement or labral repair and were thus included in the study. If the patients had an underlying impingement lesion or other pathological finding, this was also addressed at the time of surgery. The indications for hip arthroscopy were persistent symptoms following conservative management and magnetic resonance imaging (MRI) proven labral pathology. All the patients reported hip pain with associated mechanical symptoms including locking, clicking or subjectively reported symptoms of instability and hip pain along with a positive impingement test on clinical examination. Patients with Tönnis Grade 3 or 4 osteoarthritis on plain radiographs of the hip and/or a reduction of joint space of <5 mm are not offered hip arthroscopy as an intervention at our institution and were therefore automatically excluded from the study. The age of the patients ranged from 16 to 61 years. All the patients had a standard pre-operative workup including, plain radiographs, pre-operative MRI scan or MR arthrogram and a diagnostic hip injection to confirm the intra-articular source of pain. Ninety-nine patients had MRI confirmed labral tears. As many of the patients had been tertiary referrals from other centres, we did not feel it was ethical to subject the patients to repeat scanning.

All procedures were performed by a single surgeon at our unit. Hip arthroscopy was performed in the lateral position via the previously well described three-portal technique [9]. Both central and peripheral compartments were accessed in all hips. Although labral tears remain the primary pathology for the purpose of this study, any labral, chondral and underlying bony pathology (impingement lesions) identified was addressed at arthroscopy. The acetabular labrum was assessed with the help of a probe. If it was found to be stable and well attached to the acetabular rim, then a debridement was carried out. If the labrum was found to be detached from the acetabular rim, an acetabular labral repair was performed using knotless anchors.

Post-operatively, patients were allowed to mobilise full weight bearing with crutches unless they had a microfracture in which case they were mobilized partially weight bearing with crutches for the first 2 weeks post-operatively, followed by fully weight bearing with crutches for a further 2 weeks. All the patients were provided with a locally developed, 16-week post-operative rehabilitation protocol. Patients were routinely followed up at 6 weeks, 3 and 6 months and at 1 year post-operatively prior to being discharged from the clinic.

Patient satisfaction was evaluated retrospectively with a minimum follow-up of 2 years. Follow-up ranged from 23 to 85 months post-operatively with mean of 43 months at the time of the questionnaire. Following consultation with the Obstetrics and Gynaecology Department at our institution, we found that there was currently no validated assessment tool to assess hip pain during sexual intercourse and the effects thereof in young women. We, therefore, designed a patient based questionnaire, which was then presented to and approved by the Institutional Review Board. The questionnaire was circulated and patients were asked specific binary questions focussing on whether or not they had experienced hip pain during sexual intercourse pre-operatively and whether there had been any improvement in the hip symptoms experienced during sex post-operatively. Finally, patients were asked to rate their overall satisfaction with the procedure on a scale of 1–10. Patients who did not respond to the survey were contacted via telephone.

RESULTS

Of the 120 patients included in the study, 60 initially responded to the survey. A further 44 women were contacted by telephone. Sixteen women either did not respond or preferred not to participate.

One hundred and three patients underwent labral debridement, with only one patient undergoing a labral repair. The surgical indication for repair was an unstable labrum that was detached from the acetabulum. **Table I** outlines the number of patients undergoing additional procedures at the time of arthroscopy, in addition to labral debridement or repair.

Ninety-two of the 104 patients who responded (88%) reported that they were sexually active at the time of surgery and of those, 87 (94%) reported that they had experienced pain in the affected hip during sexual intercourse pre-operatively. **Figure 1** demonstrates the proportion of sexually active women in our study who reported hip pain during sexual intercourse. Twenty women had specified that their symptoms were largely positional and that they experienced pain particularly when the hip was in a flexed

Table I. Secondary procedures performed at the time of hip arthroscopy, in addition to labral debridement or repair

Procedures	Number of patients
Excision of impingement lesion	100
Acetabular microfracture	8
Femoral or acetabular chondroplasty	13
Excision of medial synovial fold	3
Other (e.g. Iliopsoas release, excision of os acetabulare, division of adhesions, debridement of torn ligamentum teres, removal of loose bodies, excision of trochanteric bursa)	6

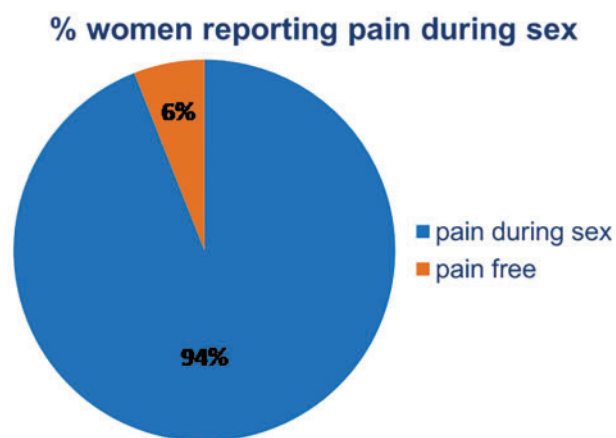


Fig. 1. The proportion of sexually active women who reported hip pain during sexual intercourse.

or abducted position. Eight women reported pain for a few days following sexual intercourse and four women stated that they were often not able to continue on account of hip discomfort.

Post-operatively, 77 out of the 87 women who had described hip pain during sexual intercourse, reported an improvement in their symptoms following hip arthroscopy. Figure 2 shows the proportion of women who reported an improvement in their hip pain following hip arthroscopy. Forty-four women out of the 77 who had reported an improvement in their symptoms, felt that while there had been an improvement, they still had a degree of persistent pain. A total of 10 women reported that there had not been any improvement in their symptoms. Finally, all patients were asked to rate their overall satisfaction with

% women reporting improvement after hip arthroscopy

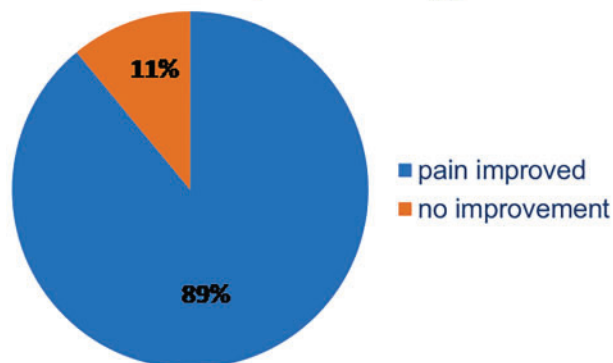


Fig. 2. The proportion of women who reported an improvement in their hip pain following hip arthroscopy.

the outcome of their procedure on a scale of 1–10. Scores ranged from 1 to 10 with a mean score of 7.88. Thirty-four percent (34%) of women reported 10/10 satisfaction with the procedure. At the time of follow-up, there were no documented major complications including heterotopic ossification, deep infection, nerve injury or progression of arthritis leading to a total hip replacement in any of the patients.

DISCUSSION

Similarities can be drawn between the acetabular labrum and the menisci in the knee. Just like the menisci, the acetabular labrum has a good blood supply peripherally while the free edge is comparatively avascular [12]. Tears frequently occur in this relatively avascular zone and are most commonly seen in the anterior region of the acetabulum [13]. Labral tears can be the result of structural diseases of the hip or secondary to trauma, either direct high-energy trauma or where the hip is subjected to torsional forces [14]. Previous studies have proposed various aetiological factors including road traffic collisions, falls both with and without hip dislocation [15] and a number of sporting activities including golf, running and hockey [16–18].

Labral tears associated with dysplasia and FAI include a range of morphological bony abnormalities. It has been postulated that dysplasia of the hip results in increased stresses on the labrum, thus increasing the risk of tears [19, 20]. Similarly in Cam-type FAI a large amount of shear stress is placed at the chondro-labral junction, leading to a split initially, followed by a full thickness tear of the acetabular labrum [6]. In fact, some authors have suggested that acetabular labral tears rarely occur in the absence of

structural abnormalities. The incidence of acetabular labral tears has been shown to be higher in women than in men and studies have shown that this may be a result of higher rates of hip dysplasia in women [21]. A number of studies have also reported the onset of symptoms either during pregnancy or during childbirth. It has been proposed that ligamentous laxity and altered collagen matrix in the articular cartilage are predisposing factors as well as positioning during childbirth [22, 23].

The indications for hip arthroscopy are rapidly expanding [24] and it continues to be a safe procedure with minimal complications, if carried out by an experienced surgeon. Management of acetabular labral tears remains one of few conditions in which the benefits have been well documented [7, 13, 21]. Most studies report promising short- to mid-term results with hip arthroscopy for labral tears, however, to the best of our knowledge, there has been no previous study evaluating the effect of labral tears on the sex lives of sexually active women. Whilst there is a growing body of work on the possible underlying causes for acetabular labral tears, there remains little work on the functional disability that results. As yet there has been no study specifically evaluating the impact of surgical intervention on the outcome of sex lives of sexually active women. Women with labral tears and femoroacetabular impingement syndromes very often experience hip pain with the hip in a deeply flexed position [25, 26], which can result in hip pain during sexual intercourse. However, due to the sensitive and rather personal nature of the subject matter, patients are unlikely to volunteer this information during a consultation, unless asked directly. It is likely that we are significantly underestimating the lifestyle impact and functional limitations that a labral tear may have on a young woman's life simply because we are not asking the right questions. The literature pertaining to this is limited as well. A study from 2011 evaluated surgeon and patient perspectives on sexual activity following a total hip arthroplasty (THA) [27]. The results of this study demonstrated that sexual activity is adversely affected in patients who are awaiting a THA and regaining sexual function is important to these patients. It showed that most surgeons do not discuss it with their patients and may not be aware of their patients' expectations in this regard [27]. A recent systematic review of sexual activity after total hip replacement yielded 10 studies between 1970 and 2015 [28]. Nine of these 10 studies evaluated the effects of THA on sexual activity in 1694 patients. The outcome of the review suggests that THA is associated with improved sexual activity and is an important topic for patients. We are not aware of any current study evaluating the effects of hip preservation surgery on sexual activity.

Our results demonstrate that a significant number of women (94%) have an impact on their sexual lives because of acetabular labral pathology. Secondly, in the short-term, there is a significant improvement in the symptoms specifically pertaining to sexual activity following arthroscopic intervention as reported by the majority of patients. In addition, a significant number report that they are completely symptom-free following the procedure.

There are a number of limitations to this study. As data were collected retrospectively by way of a questionnaire, the low-response rate could present the risk of sampling bias. We have attempted to overcome this by contacting those who did not respond to the postal questionnaire by telephone. We have also attempted to overcome subjectivity in the responses by asking binary questions. Secondly, we have only examined the short-term outcomes. A further study is warranted to evaluate the long-term benefits and to see whether the benefits of resolution of symptoms are maintained in the longer term. In addition, we have not evaluated whether there was a difference in patient satisfaction between those who already showed signs of early degeneration of the hip, compared with those who did not.

Anecdotally, we do have patients who have successfully conceived following hip arthroscopy for labral pathology, however, we have not objectively evaluated whether the desire to start a family prompts women to opt for surgical intervention. This would provide a direction for further study.

CONCLUSION

Labral tears do have a significant effect on the sex life of women. Hip arthroscopy to address the labral tear as well as any underlying impingement lesion relieves the pain experienced by women during intercourse with, with a resultant improvement in their sex lives.

CONFLICT OF INTEREST STATEMENT

None declared.

REFERENCES

1. Petersen W, Petersen F, Tillmann B. Structure and vascularization of the acetabular labrum with regard to the pathogenesis and healing of labral lesions. *Arch Orthop Trauma Surg* 2003; **123**: 283–8.
2. Ferguson SJ, Bryant JT, Ganz R *et al.* An in vitro investigation of the acetabular labral seal in hip joint mechanics. *J Biomech* 2003; **36**: 171–8.
3. Bsai S, Frei H, Beaulieu PE. The acetabular labrum: a review of its function. *Bone Joint J* 2016; **98-B**: 730–5.

4. McCarthy JC, Noble PC, Schuck MR *et al.* The role of labral lesions to development of early degenerative hip disease. *Clin Orthop Relat Res* 2001; **393**: 25–37.
5. Bedi A, Kelly BT, Khanduja V. Arthroscopic hip preservation surgery: current concepts and perspective. *Bone Joint J* 2013; **95-B**: 10–9.
6. Alshameeri Z, Khanduja V. The effect of femoro-acetabular impingement on the kinematics and kinetics of the hip joint. *International Orthopaedics* 2014; **38**:1615–20. Epub 2014/04/02.
7. Griffiths EJ, Khanduja V. Hip arthroscopy: evolution, current practice and future developments. *Int Orthop* 2012; **36**: 1115–21.
8. Imam S, Khanduja V. Current concepts in the diagnosis and management of femoroacetabular impingement. *Int Orthop* 2011; **35**: 1427–35.
9. Khanduja V, Villar RN. Arthroscopic surgery of the hip: current concepts and recent advances. *J Bone Joint Surg Br* 2006; **88-B**: 1557–66.
10. Haddad B, Konan S, Haddad FS. Debridement versus reattachment of acetabular labral tears: a review of the literature and quantitative analysis. *Bone Joint J* 2014; **96-B**: 24–30.
11. van Arkel RJ, Amis AA, Cobb JP *et al.* The capsular ligaments provide more hip rotational restraint than the acetabular labrum and the ligamentum teres: an experimental study. *Bone Joint J* 2015; **97-B**: 484–91.
12. Seldes RM, Tan V, Hunt J *et al.* Anatomy, histologic features, and vascularity of the adult acetabular labrum. *Clin Orthop Relat Res* 2001; **382**: 232–40.
13. McCarthy J, Noble P, Aluisio FV *et al.* Anatomy, pathologic features, and treatment of acetabular labral tears. *Clin Orthop Relat Res* 2003; **406**: 38–47.
14. Parmar R, Parvizi J. The multifaceted etiology of acetabular labral tears. *Surg Technol Int* 2010; **20**: 321–7.
15. Byrd JW. Labral lesions: an elusive source of hip pain case reports and literature review. *Arthroscopy* 1996; **12**: 603–12.
16. Binningsley D. Tear of the acetabular labrum in an elite athlete. *Br J Sports Med* 2003; **37**: 84–8.
17. Ikeda T, Awaya G, Suzuki S *et al.* Torn acetabular labrum in young patients. Arthroscopic diagnosis and management. *J Bone Joint Surg Br* 1988; **70-B**: 13–6.
18. Mason JB. Acetabular labral tears in the athlete. *Clin Sports Med* 2001; **20**: 779–90.
19. Dorrell JH, Catterall A. The torn acetabular labrum. *J Bone Joint Surg Br* 1986; **68**: 400–3.
20. Hickman JM, Peters CL. Hip pain in the young adult: diagnosis and treatment of disorders of the acetabular labrum and acetabular dysplasia. *Am J Orthop (Belle Mead, NJ)* 2001; **30**: 459–67.
21. Hunt D, Clohisey J, Prather H. Acetabular labral tears of the hip in women. *Phys Med Rehabil Clin N Am* 2007; **18**: 497–520, ix–x.
22. Baker JF, McGuire CM, Mulhall KJ. Acetabular labral tears following pregnancy. *Acta Orthop Belg* 2010; **76**: 325–8.
23. Brooks AG, Domb BG. Acetabular labral tear and postpartum hip pain. *Obstet Gynecol* 2012; **120**: 1093–8.
24. Nakano N, Yip G, Khanduja V. Current concepts in the diagnosis and management of extra-articular hip impingement syndromes. *Int Orthop* 2017; **41**: 1321–8.
25. Lee AJ, Armour P, Thind D *et al.* The prevalence of acetabular labral tears and associated pathology in a young asymptomatic population. *Bone Joint J* 2015; **97-B**: 623–7.
26. Tamura S, Nishii T, Takao M *et al.* Differences in the locations and modes of labral tearing between dysplastic hips and those with femoroacetabular impingement. *Bone Joint J* 2013; **95-B**: 1320–5.
27. Wall PD, Hossain M, Ganapathi M *et al.* Sexual activity and total hip arthroplasty: a survey of patients' and surgeons' perspectives. *Hip Int* 2011; **21**: 199–205.
28. Issa K, Pierce TP, Brothers A *et al.* Sexual activity after total hip arthroplasty: a systematic review of the outcomes. *J Arthroplasty* 2017; **32**: 336–40.