

Standard Article

J Vet Intern Med 2017

Relationship between Device Size and Body Weight in Dogs with Patent Ductus Arteriosus Undergoing Amplatz Canine Duct Occluder Deployment

S. Wesselowski , A.B. Saunders, and S.G. Gordon

Background: Deployment of the Amplatz Canine Duct Occluder (ACDO) is the preferred method for minimally invasive occlusion of patent ductus arteriosus (PDA) in dogs, with appropriate device sizing crucial to successful closure. Dogs of any body weight can be affected by PDA.

Objectives: To describe the range of ACDO sizes deployed in dogs of various body weights for improved procedural planning and inventory selection and to investigate for correlation between minimal ductal diameter (MDD) and body weight.

Animals: A total of 152 dogs undergoing ACDO deployment between 2008 and 2016.

Methods: Body weight, age, breed, sex, and MDD obtained by angiography (MDD-A), MDD obtained by transesophageal echocardiography (MDD-TEE), and ACDO size deployed were retrospectively evaluated.

Results: Correlation between body weight and ACDO size, MDD-A and MDD-TEE was poor, with R-squared values of 0.4, 0.36, and 0.3, respectively. Femoral artery diameter in the smallest population of dogs placed inherent limitations on the use of larger device sizes, with no limitations on the wide range of device sizes required as patient size increased. The most commonly used ACDO devices were size 3 through 6, representing 57% of the devices deployed within the entire study population.

Conclusions and Clinical Importance: Patent ductus arteriosus anatomy varies on an individual basis, with poor correlation between MDD and body weight. Weight-based assumptions about expected ACDO device size for a given patient are not recommended.

Key words: ACDO; Congenital; Echocardiography; Interventional; Minimally invasive; PDA.

Patent ductus arteriosus (PDA) is 1 of the most common congenital heart defects in dogs.^{1,2} It affects a variety of different breeds over a large range of body sizes. Minimally invasive transvascular occlusion with the Amplatz canine duct occluder (ACDO)^a has become the preferred treatment method for most veterinary cardiologists, with lower complication rates, more complete occlusion, and superior ease of use reported in comparison with other devices.^{3–6} When using the ACDO, careful assessment of ductal anatomy, in particular the minimal ductal diameter (MDD), is critical for appropriate device selection and successful PDA occlusion.^{4,5} Although rare or uncommonly reported, embolization of the device can occur and may be related to inappropriate device sizing.⁵

Anatomy of the PDA can vary substantially from dog to dog. Previous work presenting an angiographic

Abbreviations:

ACDO	Amplatz canine duct occluder
MDD-A	MDD obtained from angiography
MDD	minimal ductal diameter
MDD-TEE	MDD obtained from transesophageal echocardiography
PDA	patent ductus arteriosus
R ²	R-squared
TEE	transesophageal echocardiography
TTE	transthoracic echocardiography

classification scheme of PDA morphology in the dog described 4 anatomic variations, with a significantly larger MDD associated with type III morphology compared to types I, IIA, and IIB.⁷ Type III morphology is overrepresented in the German Shepherd breed, and, in many instances, precludes successful use of an ACDO.^{7–9} Specific breed predilections for the other PDA morphologies have not been reported. Additionally, correlation between body weight and MDD measured angiographically was not previously appreciated.⁷ Given the importance of appropriate device sizing, awareness of the range of potential device sizes needed for dogs of various body weights could prove clinically useful for procedural planning and inventory selection. This is particularly true in settings in which transthoracic echocardiography (TTE) is relied upon to assess MDD for preprocedural inventory ordering, because MDD as measured by TTE differs significantly from MDD measured by angiography.¹⁰

The objective of our study was to describe the range of ACDO sizes used for PDA occlusion in dogs of various body weight ranges presented over an 8-year period since the device became available for use. In addition, the relationship between MDD measured both

From the College of Veterinary Medicine, Texas A&M University, College Station, TX (Wesselowski, Saunders, Gordon).

This work was done at Texas A&M University.

There was no grant or other funding support for this study.

This study has not been presented at any meetings.

Corresponding author: S. Wesselowski, DVM, MS, DACVIM (Cardiology), Department of Small Animal Clinical Sciences, College of Veterinary Medicine and Biomedical Sciences, Texas A&M University, College Station, TX; email: swesselowski@cvm.tamu.edu.

Submitted March 14, 2017; Revised May 10, 2017; Accepted June 27, 2017.

Copyright © 2017 The Authors. Journal of Veterinary Internal Medicine published by Wiley Periodicals, Inc. on behalf of the American College of Veterinary Internal Medicine.

This is an open access article under the terms of the Creative Commons Attribution-NonCommercial License, which permits use, distribution and reproduction in any medium, provided the original work is properly cited and is not used for commercial purposes.

DOI: 10.1111/jvim.14797

angiographically and by transesophageal echocardiography (TEE) and body weight was further investigated for evidence of correlation.

Materials & Methods

A search of the Texas A&M University Veterinary Medical Teaching Hospital's veterinary medical information system and catheterization procedures log identified 152 dogs diagnosed with PDA that underwent placement of an ACDO between January 2008 and December 2016. The body weight, age, breed, sex, and MDD obtained from angiography (MDD-A), MDD obtained from transesophageal echocardiography (MDD-TEE), and ACDO size deployed were recorded for each dog when available. Any dogs with device embolization or with placement that varied from the original description^{4,5} were noted. All MDD measurements were obtained by a single operator (AS), either at the time of ACDO placement, or upon subsequent review. Devices were sized as previously described, with the waist of the ACDO device being oversized by approximately 200% compared to the MDD and the ratio between the PDA ampulla diameter and the proximal disk of the ACDO being oversized by approximately 130%.⁶

Statistics

Body weight data were plotted against ACDO size, MDD-A, and MDD-TEE in scatterplot form. Simple linear regression and calculation of the coefficient of determination or R^2 then were determined to assess the percentage of variation in these variables that was attributable to body weight.

Results

One hundred and fifty-two dogs had ACDO devices placed during the study period. Forty-four breeds were represented in addition to dogs of mixed breed origin. Mixed breed dogs were most common ($n = 23$), followed by German Shepherds ($n = 19$), Bichon Frise ($n = 10$), Poodles ($n = 7$), and Labrador Retrievers ($n = 7$). There were 104 females (44 neutered) and 48 males (18 neutered). The average age was 21.5 months (median, 9.2 months; range, 2–193 months), and the average body weight was 12.9 kg (median, 9.4 kg; range, 2.2–37.2 kg). The patient population was divided into 8 groups based on body weight in increments of 5 kg. The range of ACDO device sizes deployed within each weight group and the number of individual devices of each size utilized are presented in Table 1. The relationship between body weight and ACDO size within the entire study population is depicted in scatterplot form in Figure 1. The R^2 for this relationship was 0.40.

The MDD-A measurement was available in 150 dogs, whereas the MDD-TEE measurement was available in 122 dogs. The MDD-A ranged from 1 mm to 6.4 mm, whereas MDD-TEE ranged from 1.2 mm to 8.7 mm. The relationship between body weight and MDD-A resulted in an R^2 value of 0.36, whereas the relationship between body weight and MDD-TEE resulted in an R^2 value of 0.30.

During the study period, device embolization occurred in 4 dogs, 1 of which had a type IIA PDA

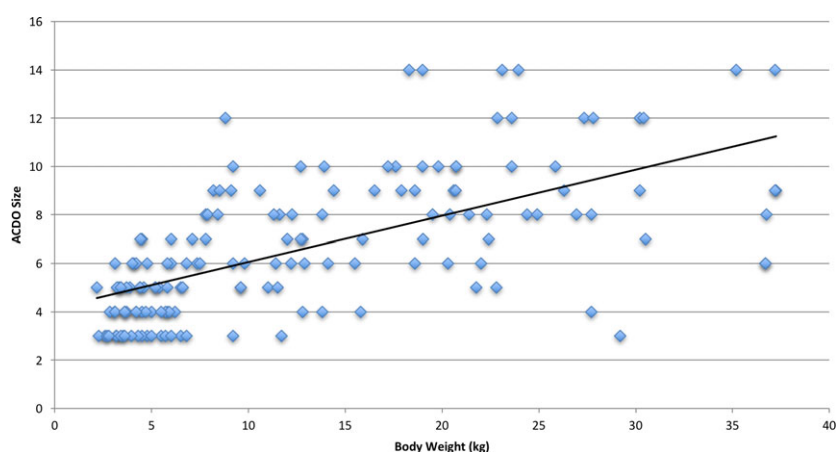
that subsequently was occluded successfully with an ACDO 1 size larger than the device that embolized. In this case, inappropriate device under-sizing could have played a role in the embolization. In the second and third dogs (Standard poodle and Chihuahua), appropriate device deployment and seating across the pulmonic ostium were achieved and confirmed by TEE and back-and-forth motion of the delivery cable before the device was released. Subsequently, prominent postdeployment dilatation of the PDA ampulla was documented by TEE. Dilatation of the ampulla occurred over a period of time that resulted in embolization 5–10 minutes after the device was released in 1 dog and after 28 minutes in the second dog in which the ampulla diameter 3 mm above the pulmonary ostium increased by 4.3 mm and 2.0 mm, respectively. The PDA anatomy in both of these dogs was type IIB. In the fourth dog, another type IIA PDA, embolization was delayed. Inappropriate postoperative patient confinement at home was determined to be the likely cause of embolization rather than sizing error in this dog.¹¹ Four embolizations after 152 ACDO device deployments represents an embolization rate of 2.6% over the 8-year study period. Of these, only 1 dog (the delayed embolization) experienced a fatal complication during this study period. Although not considered a true complication, in 1 dog the proximal disk did not take its normal shape in the ampulla.¹² The PDA in this dog was considered to have type I anatomy with a narrow ampulla and MDD of 1 mm. An embolization coil was not considered in this dog because of morphology, and a size 3 ACDO was deployed. The proximal disk was too large for the ampulla but was difficult to retract back into the catheter. Transesophageal echocardiography confirmed the disk was entirely within the ampulla and had completely occluded flow through the PDA. Finally, in 1 dog, an ACDO was purposefully deployed entirely within the ductal ampulla because of improper ACDO seating across the pulmonary ostium and the decision that a vascular plug would be insufficient for closure as assessed by TEE. No residual flow was detected in this dog during a 24-hour postoperative echocardiogram or at a subsequent reevaluation echocardiogram 27 months after ACDO placement.

Discussion

The data presented here support the conclusion that PDA anatomy varies considerably among individual dogs, with a large range of possible ACDO device sizes potentially required for a given body weight. Correlations between body weight and ACDO size, MDD-A, and MDD-TEE all were relatively poor based on R^2 values, indicating that a minimal amount of the variability in these variables was attributable to changes in body weight. These findings support the previous conclusion that there is no correlation between body size and angiographically measured MDD in dogs,⁷ and expand this conclusion to include MDD measured with TEE as well. Current results are also consistent with data from humans, where no relationships were found

Table 1. ACDO device sizes deployed across various body weight ranges. ACDO, Amplatz Canine Duct Occluder.

Weight range (kg)	Number of dogs (n = 152)	ACDO size range	ACDO size									
			ACDO 3 (n = 22)	ACDO 4 (n = 20)	ACDO 5 (n = 22)	ACDO 6 (n = 22)	ACDO 7 (n = 12)	ACDO 8 (n = 16)	ACDO 9 (n = 14)	ACDO 10 (n = 11)	ACDO 12 (n = 7)	ACDO 14 (n = 6)
0–5	42	3–7	14	11	10	5	2	0	0	0	0	0
5.1–10	37	3–12	6	5	8	7	3	3	3	1	1	0
10.1–15	20	3–10	1	2	2	4	3	4	2	2	0	0
15.1–20	15	4–14	0	1	0	2	2	1	3	4	0	2
20.1–25	19	5–14	0	0	2	2	1	5	2	3	2	2
25.1–30	9	3–12	1	1	0	0	0	2	1	1	3	0
30.1–35	3	7–12	0	0	0	0	1	0	1	0	1	0
35.1–40	7	6–14	0	0	0	2	0	1	2	0	0	2

**Fig 1.** Scatterplot data with regression line depicting ACDO device size deployed versus body weight (kg) in 152 dogs. ACDO, Amplatz Canine Duct Occluder.

among diameters, angiographic ductal classifications, patient ages, or patient body weights.¹³

Some degree of correlation between ACDO size and body weight is intrinsically unavoidable because of limitations in catheter accommodation, and thus ACDO device size, imposed by the femoral artery diameter in patients of smaller size. In fact, femoral artery size is often a rate-limiting variable that dictates that alternate methods of PDA correction such as surgical ligation be chosen for the smallest patient population. This limitation is overcome in patients of larger size, because any ACDO size potentially could be deployed in a larger patient with an appropriately sized femoral artery. This difference can be appreciated when reviewing Table 1, in which the narrowest ACDO size range is observed in the smallest weight range (0–5 kg), and substantial expansion in the ACDO size range is seen in higher weight brackets. In the 25.1–30 kg range, for example, ACDO devices at the smallest end of the spectrum were deployed, as were ACDO devices toward the largest end of the spectrum. From an inventory perspective, approximately two-thirds of the study population (n = 99) weighed ≤ 15 kg, with deployed ACDO sizes ranging from 3 up to 12. The most common ACDO sizes deployed in the dogs that weighed ≤ 15 kg were

sizes 3 through 6 (n = 75), representing 76% of the devices deployed in this population, or approximately 57% of the devices deployed in the entire study population (n = 86). Thus, it is likely prudent to maintain an inventory that at minimum encompasses these 4 ACDO sizes.

Complications related to device sizing in our study were rare, suggesting that in the majority of cases, appropriate device sizing was achieved based on MDD-A, MDD-TEE or, as is often the case at our institution, a combination of these measurement modalities. In our experience, 3-dimensional TEE has the potential to further improve ability to accurately measure the MDD in multiple dimensions and thus could lead to even fewer sizing complications in the future. We did not study this modality nor was any comparison made between MDD measured by TTE and MDD measured by angiography or TEE. Although not previously a reported cause of device embolization, dilatation of the PDA ampulla after ductal occlusion with an ACDO is reported in dogs, with significant increases in the length and width of the ampulla compared to pre-occlusion dimensions.⁵ In the 2 cases of embolization in our study in which ampulla dilatation occurred, prominent dilatation of the ampulla after occlusion was documented by TEE and

would not have been recognized as a contributing factor without on going TEE monitoring postdeployment. Whether type IIB ductal anatomy played a role in postocclusion dilatation is difficult to determine with such a small number of cases. Type IIB PDAs previously have been theorized to provide less device stability than type IIA PDAs, with a possible need for slightly larger device sizing proposed with this anatomical variant.¹⁴

Our study provides useful information for interventional cardiologists performing minimally invasive PDA occlusion with ACDO devices by offering insight into the range of device sizes that may be required for dogs of different body weights as well as the most commonly used device sizes in a large population for purposes of inventory planning. Additionally, it reinforces the notion that PDA anatomy varies on an individual basis, making weight-based assumptions about expected ACDO device size for any given patient unwise.

Footnote

^a Infiniti Medical, LLC Haverford, PA.

Conflict of Interest Declaration: Authors declare no conflict of interest.

Off-label Antimicrobial Declaration: Authors declare no off-label use of antimicrobials.

References

- Schrope DP. Prevalence of congenital heart disease in 76,301 mixed-breed dogs and 57,025 mixed-breed cats. *J Vet Cardiol* 2015;17:192–202.
- Oliveira P, Domenech O, Silva J, et al. Retrospective review of congenital heart disease in 976 dogs. *J Vet Intern Med* 2011;25:477–483.
- Singh MK, Kittleson MD, Kass PH, et al. Occlusion devices and approaches in canine patent ductus arteriosus: Comparison of outcomes. *J Vet Intern Med* 2012;26:85–92.
- Nguyenba TP, Tobias AH. The Amplatz canine duct occluder: A novel device for patent ductus arteriosus occlusion. *J Vet Cardiol* 2007;9:109–117.
- Nguyenba TP, Tobias AH. Minimally invasive per-catheter patent ductus arteriosus occlusion in dogs using a prototype duct occluder. *J Vet Intern Med* 2008;22:129–134.
- Gordon SG, Saunders AB, Achen SE, et al. Transarterial ductal occlusion using the Amplatz Canine Duct Occluder in 40 dogs. *J Vet Cardiol* 2010;12:85–92.
- Miller MW, Gordon SG, Saunders AB, et al. Angiographic classification of patent ductus arteriosus morphology in the dog. *J Vet Cardiol* 2006;8:109–114.
- Weisse C, Berent A. *Veterinary Image-Guided Interventions*. Ames, Iowa: John Wiley & Sons Inc.; 2015:564–574.
- Caivano D, Biretoni F, Fruganti A, et al. Transthoracic echocardiographically-guided interventional cardiac procedures in the dog. *J Vet Cardiol* 2012;14:431–444.
- Saunders AB, Miller MW, Gordon SG, et al. Echocardiographic and angiographic comparison of ductal dimensions in dogs with patent ductus arteriosus. *J Vet Intern Med* 2007;21:68–75.
- Carlson JA, Achen SA, Saunders AB, et al. Delayed embolization of an Amplatz((R)) canine duct occluder in a dog. *J Vet Cardiol* 2013;15:271–276.
- Saunders AB, Achen SE, Gordon SG, et al. Utility of transesophageal echocardiography for transcatheter occlusion of patent ductus arteriosus in dogs: Influence on the decision-making process. *J Vet Intern Med* 2010;24:1407–1413.
- Krichenko A, Benson LN, Burrows P, et al. Angiographic classification of the isolated, persistently patent ductus arteriosus and implications for percutaneous catheter occlusion. *Am J Cardiol* 1989;63:877–880.
- Silva J, Domenech O, Mavropoulou A, et al. Transesophageal echocardiography guided patent ductus arteriosus occlusion with a duct occluder. *J Vet Intern Med* 2013;27:1463–1470.