



LJMU Research Online

Olivo, G, Swenne, I, Zhukovsky, C, Tuunainen, A-K, Saaid, A, Salonen-Ros, H, Larsson, E-M, Brooks, SJ and Schiöth, HB

Preserved white matter microstructure in adolescent patients with atypical anorexia nervosa

<http://researchonline.ljmu.ac.uk/10073/>

Article

Citation (please note it is advisable to refer to the publisher's version if you intend to cite from this work)

Olivo, G, Swenne, I, Zhukovsky, C, Tuunainen, A-K, Saaid, A, Salonen-Ros, H, Larsson, E-M, Brooks, SJ and Schiöth, HB (2019) Preserved white matter microstructure in adolescent patients with atypical anorexia nervosa. International Journal of Eating Disorders. ISSN 0276-3478

LJMU has developed **LJMU Research Online** for users to access the research output of the University more effectively. Copyright © and Moral Rights for the papers on this site are retained by the individual authors and/or other copyright owners. Users may download and/or print one copy of any article(s) in LJMU Research Online to facilitate their private study or for non-commercial research. You may not engage in further distribution of the material or use it for any profit-making activities or any commercial gain.


The version presented here may differ from the published version or from the version of the record. Please see the repository URL above for details on accessing the published version and note that access may require a subscription.

For more information please contact researchonline@ljmu.ac.uk

<http://researchonline.ljmu.ac.uk/>

ORIGINAL ARTICLE

Preserved white matter microstructure in adolescent patients with atypical anorexia nervosa

Gaia Olivo MD¹  | Ingemar Swenne MD²  | Christina Zhukovsky MSc¹ |
Anna-Kaisa Tuunainen MSc¹ | Avista Saaid BSc¹ | Helena Salonen-Ros MD³ |
Elna-Marie Larsson MD, PhD⁴ | Samantha J. Brooks PhD^{5,6} | Helgi B. Schiöth PhD¹

¹Department of Neuroscience, Functional Pharmacology, Uppsala University, Uppsala, Sweden

²Department of Women's and Children's Health, Uppsala University, Uppsala, Sweden

³Department of Neuroscience, Child and Adolescent Psychiatry, Uppsala University, Uppsala, Sweden

⁴Department of Surgical Sciences, Radiology, Uppsala University, Uppsala, Sweden

⁵Department of Human Biology, University of Cape Town, Cape Town, South Africa

⁶School of Natural Sciences and Psychology, Research Centre for Brain & Behaviour, Liverpool, United Kingdom

Correspondence

Gaia Olivo, Department of Neuroscience, Uppsala University, Box 593, Husargatan 3, 751 24 Uppsala, Sweden.
Email: gaia.olivo@neuro.uu.se

Funding information

Gillbergska Foundation; Brain Research foundation; Swedish Research Council

Abstract

Objective: Patients with atypical anorexia nervosa (AN) are often in the normal-weight range at presentation; however, signs of starvation and medical instability are not rare. White matter (WM) microstructural correlates of atypical AN have not yet been investigated, leaving an important gap in our knowledge regarding the neural pathogenesis of this disorder.

Method: We investigated WM microstructural integrity in 25 drug-naïve adolescent patients with atypical AN and 25 healthy controls, using diffusion tensor imaging (DTI) with a tract-based spatial statistics (TBSS) approach. Psychological variables related to the eating disorder and depressive symptoms were also evaluated by administering the eating disorder examination questionnaire (EDE-Q) and the Montgomery-Åsberg depression rating scale (MADRS-S) respectively, to all participants.

Results: Patients and controls were in the normal-weight range and did not differ from the body mass index standard deviations for their age. No between groups difference in WM microstructure could be detected.

Discussion: Our findings support the hypothesis that brain structural alterations may not be associated to early-stage atypical AN. These findings also suggest that previous observations of alterations in WM microstructure in full syndrome AN may constitute state-related consequences of severe weight loss. Whether the preservation of WM structure is a pathogenetically discriminant feature of atypical AN or only an effect of a less severe nutritional disturbance, will have to be verified by future studies on larger samples, possibly directly comparing AN and atypical AN.

KEYWORDS

adolescent, anorexia nervosa, brain, cognitive neuroscience, diffusion tensor imaging, feeding and eating disorders, neuroimaging

1 | INTRODUCTION

Atypical anorexia nervosa (AN) is defined by the presence of all the criteria for AN except significant weight loss, as reported in the fifth edition of the Diagnostic and Statistical Manual of Mental Disorders (DSM-5) (American Psychiatric Association, 2013). Patients with atypical AN are often in the normal-weight range at presentation (Moskowitz & Weiselberg, 2017; Sawyer, Whitelaw, Le Grange, Yeo, & Hughes, 2016), however, signs of

starvation and medical instability are not rare (Moskowitz & Weiselberg, 2017), and medical consequences can be as severe as in full-threshold AN (Sawyer et al., 2016). Neuroimaging can help us investigate the pathophysiology and neurobiology related to EDs development (Beato-Fernandez, Rodriguez-Cano, & Garcia-Vilches, 2011; Frank, 2015). Though its usefulness as a diagnostic tool is still limited (Jauregui-Lobera, 2011), its prognostic value has been highlighted (Jauregui-Lobera, 2011). Nonetheless, most of the current neuroimaging research has focused on

full-syndrome AN rather than atypical AN, leaving an important gap in our knowledge regarding the neural correlates underlying this disorder. This is of particular interest, given the current debate whether full-syndrome and atypical AN should be considered as different manifestations of the same disease along a spectrum of severity, rather than different diagnostic categories (Fairweather-Schmidt & Wade, 2014).

Only few neuroimaging studies have been conducted on adolescents with EDs, and the few studies available have been conducted in full-syndrome AN patients. White matter (WM) integrity and structural connectivity (Frank, Shott, Hagman, & Yang, 2013; Gaudio et al., 2017; Kaufmann et al., 2017; Olivo et al., 2017; Pfuhl et al., 2016; Travis et al., 2015; Vogel et al., 2016; von Schwanenflug et al., 2018) have been explored with somewhat conflicting results (Figure 1). In particular, diffusor tensor imaging (DTI) studies reported either increased (Frank et al., 2013; Travis et al., 2015; Vogel et al., 2016) or decreased (Frank et al., 2013; Gaudio et al., 2017; Olivo et al., 2017; von Schwanenflug et al., 2018) fractional anisotropy (FA) in AN patients compared to controls, and one study did not find any differences in diffusivity parameters between patients and controls (Pfuhl et al., 2016). Moreover, some findings, such as the occurrence of microstructural changes in the fornix of AN patients, might have been biased by partial volume effects (Kaufmann et al., 2017). Given the heterogeneity of the samples between studies in terms of AN subtype (restrictive vs. binge) and disease duration, and the scarce number of studies available, any straightforward interpretation of the discrepancies has to be considered speculative at best.

In adults, on the other hand, FA has been consistently found to be decreased in AN patients compared to controls (Cha et al., 2016; Frieling et al., 2012; Kazlouski et al., 2011; Nagahara et al., 2014). The FA measures the diffusivity of water molecules along the principal direction of the axon. FA is sensitive to several tissue characteristics, such as myelination, axon diameter, fiber density, and organization

(Beaulieu, 2002). FA decreases often occur in several psychiatric disorders, and are generally due to either decreased diffusivity along the longitudinal axis of the axon (e.g., due to axonal loss) or to increased radial diffusivity (e.g., due to disruption of the myelin sheaths) (Beaulieu, 2002). On the other hand, FA increases are less frequent, and might reflect restricted perpendicular diffusivity, facilitated parallel diffusivity or some combination of the two, reflective of a change in fibers architecture (e.g., due to increased fiber coherence following a reduction in the number or density of crossing fibers) (Jones & Cercignani, 2010; Travis et al., 2015). In adults, a reduction in FA due to the impact of malnutrition, dehydration, and weight loss (King, Frank, Thompson, & Ehrlich, 2017) might thus be more likely to occur compared with an increase in FA. In fact, an increase in FA would require an architectural reorganization which, though possible in adults (Wang & Young, 2014), is often partially counterbalanced by age-related myelin loss and turnover (Wang & Young, 2014). The adolescent brain, on the other hand, is at a stage of rapid development (Lebel, Treit, & Beaulieu, 2017). The shape and strength of newly-built connections are dramatically influenced by heredity, sex hormones, and environmental and social stimuli (Arain et al., 2013) (Figure 1). As a result, white matter undergoes complex structural and architectural changes during adolescence (Lebel et al., 2017), and increases and decreases in FA can be observed at different stages and in different structures.

To date, no neuroimaging studies, in either adults or adolescents have been conducted to investigate WM integrity in atypical AN. We used DTI to investigate WM microstructural integrity in 25 drug-naïve adolescent patients with atypical AN, and 25 healthy controls. We aimed at exploring the WM microstructural correlates of adolescent atypical AN, and its relation with neuropsychological clinical symptoms. To this aim, ED-related symptoms were evaluated by administering the eating disorder examination questionnaire (EDE-Q) to all participants. To better characterize our sample, depressive symptoms,

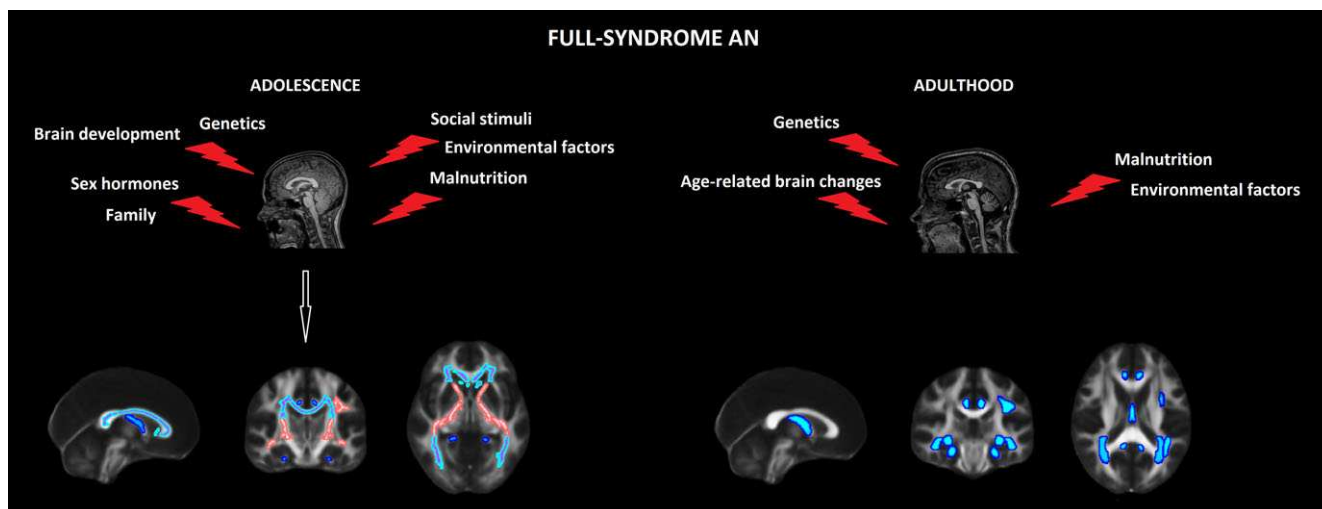


FIGURE 1 Fractional anisotropy increases and decreases in patients with anorexia nervosa. The figure summarizes previous findings relative to fractional anisotropy alterations detected in patients with full-syndrome anorexia nervosa, compared with age-matched controls. Several factors, listed in the figure, can disrupt white matter microstructure in adult and adolescent patients. In adolescent patients (left), increases (pink) as well as decreases (blue) in FA values have been variably reported in several white matter structures, and sometimes both increases and decreases have been detected in the same tracts (purple and light blue), such as the corpus callosum, even in the same paper (Travis et al.). Conversely, in adults, FA has been consistently found to be decreased in several structures (blue). The figures have been generated with FSL for illustrative purposes only [Color figure can be viewed at wileyonlinelibrary.com]

which have been reported to have high comorbidity with restrictive ED and can contribute to the high rate of suicides and suicide attempts in these patients, were measured with the Montgomery-Åsberg depression rating scale self-report (MADRS-S) (Brockmeyer et al., 2012; Franko & Keel, 2006; Harrington, Jimerson, Haxton, & Jimerson, 2015; Jaite, Hoffmann, Glaeske, & Bachmann, 2013; Koutek, Kocourkova, & Dudova, 2016; Lule et al., 2014).

2 | METHODS

2.1 | Subjects

All participants and their guardians gave written consent to participate in the study. The protocol was in accordance to the Declaration of Helsinki and was approved by the local ethics committee of the Faculty of Medicine of Uppsala University, Uppsala, Sweden. Demographic and clinical information are reported in Table 1 and Figure 2.

Twenty-five adolescent female outpatients (mean age 14.8 years, range 13–18 years) were recruited by the eating disorder unit (EDU) of the Department of Child and Adolescent Psychiatry at the Uppsala University Hospital, Uppsala, Sweden. The diagnosis of atypical AN was based on the criteria listed in the fifth edition of the Diagnostic and Statistical Manual of Mental Disorders (DSM-5) (American Psychiatric Association, 2013), as patients presented with features of AN but were above -2 BMI standard deviation scores (SDS) for age (Table 1). The initial assessment of patients and the diagnostic procedure were performed by a pediatrician with experience of ED, and followed a structured protocol including: the history of the ED, medical history (including medical and psychiatric comorbidity), menstrual status, demographics, and physical examination (including weight and height measurements). Nine patients had secondary amenorrhea, three patients were in premenarche, one patient was taking hormonal contraceptives, and the remaining twelve patients had menstruations. Diagnoses of atypical AN were then confirmed by a psychiatrist or

psychologist at the EDU, and the history of weight and height changes was obtained from the growth charts provided by the school health services, and weight loss was calculated as the difference between maximum documented weight and the weight at diagnosis. Patients started treatment the day after the visit, however, the diagnosis of atypical AN was still confirmed at the time of scanning. Twenty-five healthy controls (mean age 14.5 years, range 13–18 years) were recruited from local schools through advertisement. Ten patients and 18 controls of our current sample were also included in our previous DTI study on restrictive EDs (Olivo et al., 2017). Sixteen patients and 22 controls of our current sample were also included on our previous voxel-based morphometry (VBM) study on atypical AN (Olivo et al., 2018).

ED-related cognition was assessed via a 38-items self-reported questionnaire, the EDE-Q (Fairburn & Beglin, 1994), youth version (Carter, Stewart, & Fairburn, 2001). The EDE-Q comprises four subscales measuring specific features of the ED behavior: restraint, eating concern, shape concern, and weight concern. Given the high comorbidity with depression, depression symptoms were assessed with the MADRS-S (Svanborg & Asberg, 1994), Swedish version.

Inclusion criteria were female gender, and age between 13 and 18 years. Exclusion criteria for all participants were male gender, comorbid neurological diseases, left-handedness, metallic implants, claustrophobia, and use of psychotropic medications, past or current comorbidity (patients) or history (controls) of psychiatric disorders. For controls, additional exclusion criteria were a BMI below the 5th or above the 95th percentile per age, and an EDE-Q total score > 2.0 , which has been suggested as the optimal cut-off to distinguish between the clinical and the general population (Ekeröth & Birgegård, 2014). We focused on females given the higher prevalence of ED in women (Lahteenmaki et al., 2014; Mangweth-Matzek & Hoek, 2017; Smink, van Hoeken, & Hoek, 2012; Sweeting et al., 2015), estimated to be 1.6% compared to 0.1% in males, as reported in a Swedish sample (Goodman, Heshmati, Malki, & Koupil, 2014).

2.2 | MRI acquisition

The scanning procedure was carried out within 40 days of the initial visit at the clinic. This delay was due to technical reasons. At their first visit to the clinic, parents and their children were given information about the study and they had 1 week time to communicate whether they wanted to participate or not. Then, a time for the MRI was set in accordance to the hospital necessities. The queue for scanning, coupled to the rapid diagnosis-to-treatment time, led to a delay of 10–40 days. Under this period, the average weight gain of the participants was 2.4 kg. The diagnosis of ED was still confirmed. The participants were instructed to eat before coming to the hospital. Prior to the scanning, they were asked to rate their satiety on a visual scale ranging from 1 to 10. If they indicated a score below three, they were provided with something to eat, like cookies or snacks.

A Philips 3-Tesla scanner (Achieva, Philips Healthcare, Best Netherlands) using a standard 32-channel head coil was used to acquire the MRI sequences. Structural images were acquired with a T1-weighted turbo-field-echo (TFE) sequence (TR = 8,100 ms; TE = 3.7 ms; flip angle: 8°; slice thickness = 1 mm; slice spacing = 1 mm).

TABLE 1 Clinical and demographics data of the participants

	Patients mean (SD)	Controls mean (SD)	<i>p</i>
Age (years)	14.8 (1.5)	14.5 (1.4)	.447
BMI at diagnosis (Kg/m ²)	18.6 (2.4)	20.0 (1.9)	.014*
Weight gain before scanning	2.4 (2.2)	–	–
BMI at scanning (Kg/m ²)	19.5 (2.5)	20.0 (1.9)	.365
BMI-SDS	−0.28 (1.1)	0.04 (0.6)	.109
EDE-Q	3.2 (1.7)	0.3 (0.3)	.001**
Restraint	3.0 (1.9)	0.2 (0.3)	.001**
Eating concern	2.7 (1.7)	0.1 (0.2)	.001**
Weight concern	3.5 (1.9)	0.3 (0.4)	.001**
Shape concern	3.8 (2.1)	0.6 (0.6)	.001**
MADRS-S	27.5 (11.2)	5.4 (5.7)	.001**
Disease duration (years)	0.7 (0.4)	–	–
Age at max documented weight (years)	13.9 (1.4)	–	–
Weight loss (Kg)	6.3 (4.5)	–	–

p* < .05; *p* < .01.

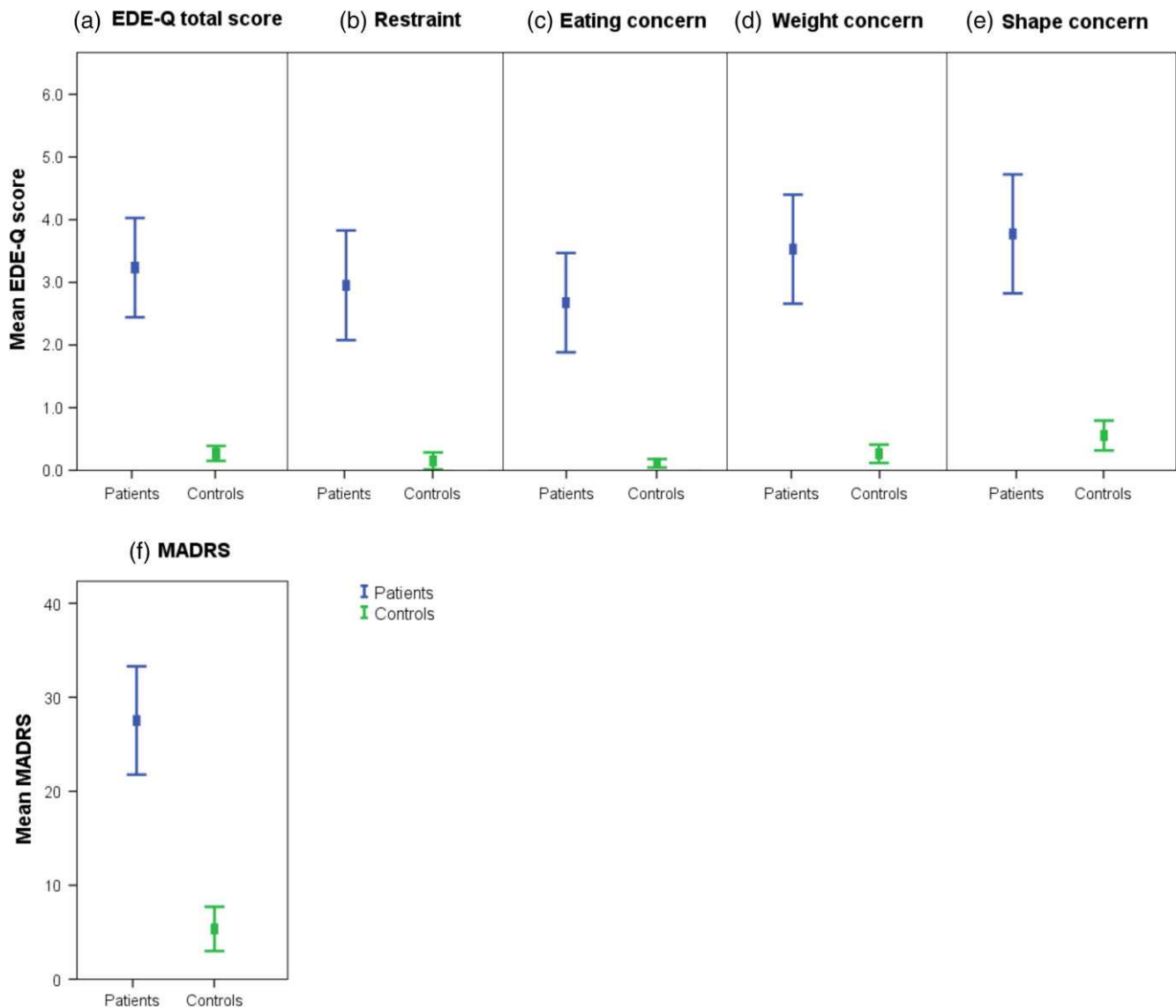


FIGURE 2 Psychometric questionnaire scores in patients compared with controls. The figure shows the mean scores on the EDE-Q (upper panel) and MADRS-S (lower panel) questionnaire in patients (blue) and controls (green). The patients scored significantly higher on the (a) EDE-Q total score and EDE-Q subscales, namely (b) Restraint, (c) Eating concern, (d) Weight concern, and (e) Shape concern. They did also score significantly higher on the (f) MADRS-S, compared with controls [Color figure can be viewed at wileyonlinelibrary.com]

The DTI data were acquired using an echoplanar imaging sequence (EPI) (TR: 6700 ms, TE: 77 ms, voxel size: $1.75 \times 1.75 \times 1.75 \text{ mm}^3$, 48 directions, 60 axial slices covering the whole brain).

2.3 | Preprocessing of DTI data

Preprocessing of the DTI data was carried out in FMRIB Software Library (FSL), provided in the public domain by the Oxford Centre for Functional Magnetic Resonance Imaging of the Brain (Smith et al., 2004). DTI images were corrected for eddy currents and head motion using the FMRIB's Diffusion Toolbox (FDT) implemented in FSL. Brain images were extracted from the b0 volume using the brain extraction tool (BET) (Smith, 2002). The diffusion tensor model was then fitted at each voxel, obtaining FA, mean diffusivity (MD), and axial diffusivity (AD) maps. The second and third eigenvalues were then averaged to obtain the radial diffusivity (RD) maps.

A whole-brain, voxel-wise tract-based spatial statistics (TBSS) (Smith et al., 2006) analysis was performed using the FSL. For each analysis, the FA images were aligned to a common target (FMRIB58_FA; http://fsl.fmrib.ox.ac.uk/fsl/fsl4.0/tbss/FMRIB58_FA.html) in the MNI 152 standard space using nonlinear registration, and resampled to a $1 \times 1 \times 1 \text{ mm}^3$ voxel size. The normalization parameters were then applied to the other diffusivity parameters maps (AD, RD, MD). FA images were averaged to create a mean FA image, then a skeleton was created, representing the center of all fibers bundle, using a threshold of FA > 0.2 to exclude voxels not belonging to WM. FA maps of each participant were then projected onto the skeleton. The same procedure was applied to the MD, RD, and AD maps.

2.4 | Statistical analyses

Statistical analyses of clinical measures were performed with Statistical Package for Social Sciences, v 24.0, by IBM (SPSS; <https://www.>

ibm.com/analytics/data-science/predictive-analytics/spss-statistical-software). A series of Mann–Whitney tests were carried out to test for differences between patients and controls in age, BMI, BMI-SDS for age, and total scores on the psychological questionnaires. The threshold for significance was set at $p < .01$, corrected for multiple comparisons according to Bonferroni (0.05/5 tests). As the EDE-Q total score was found to significantly differ between groups, EDE-Q subscales were also investigated, setting the threshold for significance at $p < .0125$, corrected for multiple testing according to Bonferroni.

Statistical analyses of DTI data were carried out using a nonparametric permutation-based statistics (Smith et al., 2006), as implemented in FSL. Patients and controls were tested for differences in FA, AD, MD, and RD (Alexander, Lee, Lazar, & Field, 2007) with two different models. In the first model, age was entered as sole covariate of no interest. As nutritional status can impact on brain development during adolescence (Arain et al., 2013), a second model was run, by including also BMI at scanning as covariate in order to explore the influence of BMI on WM integrity, as also suggested in the guidelines proposed by (Frank, Favaro, Marsh, Ehrlich, & Lawson, 2018). Disease duration was also tested for correlations with FA, AD, MD, and RD in patients, correcting for age (Frank et al., 2018). The number of permutations was set at 10,000, and the threshold for significance was set at $p < .05$, corrected for multiple comparisons at cluster level with a threshold-free cluster enhancement (TFCE) approach (Smith & Nichols, 2009).

Additionally, a region of interest (ROI) based analysis was carried out. Forty-eight WM tracts, as defined in the Juelich Histological atlas (JHU) provided by FSL, were investigated for FA differences between groups. Mean FA values were extracted from each structure and imported in SPSS. A series of ANOVA analyses were carried out to test for an effect of group on each tract, including age (first model), or age and BMI (second model) as covariates. The threshold for significance was set at $p < .001$, to account for multiple testing according to Bonferroni's approach (0.05/48 tracts).

3 | RESULTS

3.1 | Clinical assessment

Age did not differ between groups. At diagnosis, BMI was significantly lower in patients ($p < .014$) though it did not survive the threshold for multiple testing; however the BMI-SDS did not differ between groups. At the time of scanning, BMI did not differ between patients and controls. The EDE-Q and MADRS-S scores were significantly higher in patients compared with controls ($p < .001$). All of the EDE-Q subscales were also significantly different between groups ($p < .001$) (Table 1 and Figure 2).

3.2 | White matter microstructural assessment

In the DTI analysis, no differences in FA, MD, or RD were detected when comparing patients and controls, either when correcting for age, or for age and BMI. A cluster of reduced AD in patients compared to controls was found (28 voxels), encompassing the right superior

corona radiata and superior longitudinal fasciculus (SLF) ($p < .05$, tfce-corrected) when correcting for age, however it was no longer significant when further correcting for BMI. Disease duration did not correlate with diffusivity parameters in patients.

3.3 | ROI-based analysis of FA values

At the ROI-based analysis, the left anterior corona radiate, the left fornix, and the tapetum showed trends of significant difference between groups, not surviving the threshold for multiple testing. None of the other tracts from the JHU atlas showed FA differences between groups. Mean FA values and standard deviations for each tract are reported in Table 2.

4 | DISCUSSION

We investigated WM microstructural integrity and ED-related symptomatology in a sample of 25 drug-naïve adolescents diagnosed with atypical AN, compared with 25 healthy controls of comparable age. We report higher ED-related and depressive symptomatology in patients compared with controls, as measured by the EDE-Q and MADRS-S questionnaires respectively. However, no difference in most of WM diffusivity parameters could be detected. Only a reduced AD, reflective of axonal damage (Alexander et al., 2007), was found in patients in the right superior corona radiata extending to the right SLF. However BMI is likely to be responsible for this alteration. In fact, the difference between groups was no longer detectable when the analysis was corrected for BMI, which might reflect the occurrence of a statistical phenomenon known as the Simpson paradox (Kievit, Frankenhuis, Waldorp, & Borsboom, 2013; Wang, Wu, Kwan, Tu, & Feng, 2018). The Simpson paradox arises when the relationship between two variables is modified by other factors (the so-called "hidden variables") which might be mediating such association. While patients and controls did not differ in terms of BMI at scanning, in fact, the variance was nonetheless greater for patients than controls (6.3 vs. 3.5), with a BMI range of 10.8 kg/m² in patients and 7.8 kg/m² in controls (15.1 kg/m² to 25.9 kg/m² in patients and 16.4 kg/m² to 24.2 kg/m² in controls). In line with this hypothesis, BMI has been reported to be positively correlated to the AD of the right corona radiata and right SLF (Xu, Li, Lin, Sinha, & Potenza, 2013), so that lower BMI is associated with reduced AD.

In our previous study, conducted on a mixed sample including adolescents with both full syndrome or atypical AN, we found reduced FA and increased RD in patients compared with controls in the corpus callosum, corona radiata and posterior thalamic radiation. However our current imaging findings, coupled with our previous VBM study reporting preserved grey matter volumes in atypical AN (Olivo et al., 2018), suggest that the brain structural correlates of atypical AN may differ from full syndrome AN. In fact, in adolescents with full syndrome AN, WM microstructural alterations can be seen in the brain even at early stages (Gaudio et al., 2017; Travis et al., 2015), so whether our previous findings might have been driven by the inclusion of patients with full syndrome AN is an open question. In fact, all patients in our current sample were in the normal-weight range and

TABLE 2 FA values in patients and controls

	Patients mean (SD)	Controls mean (SD)	<i>p</i> (age)	<i>p</i> (age + BMI)
Middle cerebellar peduncle	0.29 (0.02)	0.29 (0.01)	.961	.952
Pontine crossing tract	0.39 (0.03)	0.40 (0.03)	.735	.622
Genu of corpus callosum	0.40 (0.02)	0.40 (0.01)	.214	.270
Body of corpus callosum	0.57 (0.02)	0.58 (0.02)	.446	.496
Splenium of corpus callosum	0.69 (0.02)	0.69 (0.02)	.823	.815
Fornix	0.40 (0.04)	0.40 (0.03)	.413	.621
Corticospinal tract, R	0.32 (0.03)	0.31 (0.03)	.405	.485
Corticospinal tract, L	0.28 (0.02)	0.28 (0.01)	.378	.497
Medial lemniscus, R	0.44 (0.03)	0.43 (0.02)	.148	.190
Medial lemniscus, L	0.44 (0.03)	0.43 (0.03)	.166	.205
Inferior cerebellar peduncle, R	0.26 (0.02)	0.26 (0.02)	.918	.983
Inferior cerebellar peduncle, L	0.25 (0.01)	0.24 (0.02)	.460	.505
Superior cerebellar peduncle, R	0.52 (0.03)	0.51 (0.02)	.409	.444
Superior cerebellar peduncle, L	0.49 (0.02)	0.48 (0.02)	.316	.346
Cerebral peduncle, R	0.61 (0.03)	0.61 (0.02)	.194	.292
Cerebral peduncle, L	0.61 (0.02)	0.60 (0.02)	.313	.405
Anterior limb of internal capsule, R	0.50 (0.02)	0.50 (0.02)	.439	.631
Anterior limb of internal capsule, L	0.49 (0.02)	0.49 (0.02)	.747	.573
Posterior limb of internal capsule, R	0.60 (0.02)	0.59 (0.02)	.511	.695
Posterior limb of internal capsule, L	0.60 (0.03)	0.60 (0.02)	.670	.860
Retrolenticular part of internal capsule, R	0.55 (0.03)	0.54 (0.02)	.507	.678
Retrolenticular part of internal capsule, L	0.55 (0.02)	0.55 (0.02)	.766	.514
Anterior corona radiata, R	0.34 (0.03)	0.45 (0.02)	.224	.207
Anterior corona radiata, L	0.34 (0.02)	0.35 (0.02)	.030*	.037*
Superior corona radiata, R	0.44 (0.02)	0.44 (0.02)	.221	.211
Superior corona radiata, L	0.44 (0.02)	0.44 (0.02)	.088	.065
Posterior corona radiata, R	0.45 (0.02)	0.45 (0.02)	.563	.599
Posterior corona radiata, L	0.43 (0.03)	0.43 (0.02)	.388	.378
Posterior thalamic radiation, R	0.56 (0.03)	0.55 (0.03)	.219	.243
Posterior thalamic radiation, L	0.55 (0.03)	0.53 (0.02)	.054	.062
Sagittal stratum, R	0.51 (0.04)	0.49 (0.03)	.101	.144
Sagittal stratum, L	0.47 (0.03)	0.46 (0.01)	.194	.234
External capsule, R	0.37 (0.03)	0.36 (0.02)	.517	.643
External capsule, L	0.38 (0.02)	0.37 (0.02)	.908	.936
Cingulum (cingulate gyrus), R	0.41 (0.03)	0.41 (0.03)	.538	.641
Cingulum (cingulate gyrus), L	0.45 (0.03)	0.46 (0.03)	.109	.107
Cingulum (hippocampus), R	0.36 (0.03)	0.35 (0.03)	.832	.858
Cingulum (hippocampus), L	0.35 (0.02)	0.34 (0.02)	.863	.988
Fornix (cres)/stria terminalis, R	0.45 (0.03)	0.46 (0.02)	.513	.495
Fornix (cres)/stria terminalis, L	0.47 (0.02)	0.48 (0.02)	.019*	.017*
Superior longitudinal fasciculus, R	0.44 (0.02)	0.43 (0.02)	.702	.810
Superior longitudinal fasciculus, L	0.43 (0.02)	0.43 (0.02)	.855	.544
Superior fronto-occipital fasciculus, R	0.44 (0.03)	0.43 (0.02)	.700	.783
Superior fronto-occipital fasciculus, L	0.42 (0.02)	0.42 (0.03)	.456	.338
Uncinate fasciculus, R	0.42 (0.03)	0.42 (0.03)	.860	.843
Uncinate fasciculus, L	0.41 (0.03)	0.40 (0.03)	.563	.467
Tapetum, R	0.36 (0.03)	0.38 (0.02)	.030*	.050*
Tapetum, L	0.27 (0.02)	0.29 (0.03)	.019*	.035*

**p* < .05.

their BMI-SDS for age was comparable to the controls', contrarily to the typical under-weight status of AN patients. As nutritional status is known to impact brain maturation and development during adolescence (Arain et al., 2013), this might partially explain the discrepancy between the findings in AN and atypical AN. In fact, brain development, in terms of reduced gyrification of GM and cortical folding, has been found to be influenced by the weight status in adolescents with AN (Bernardoni et al., 2018), and GM volumetric alterations have been largely reported in both adolescents and adults with AN (Frank, 2015; Seitz et al., 2014; Seitz, Herpertz-Dahlmann, & Konrad, 2016). Nonetheless, our patients had experienced a significant weight loss. Unfortunately, we were not able to directly compare atypical AN with full-syndrome AN due to the low number of AN patients recruited. In our clinical setting, in fact, only around 12% of the patients with a restrictive ED had full-syndrome AN. Though this is a lower proportion compared to other studies, epidemiological studies have indeed reported atypical AN to be more common than full-syndrome AN. Moreover, the chain for referral to a specialist was very rapid, preventing further weight loss so that most of the patients were still above the weight limit for full-syndrome AN. Thus, whether the preservation of grey and white matter structure is a discriminant feature of atypical AN, or whether it is due to the maintenance of a normal-range weight, will have to be assessed by future studies directly comparing AN and atypical AN.

We did not perform any free water correction. Ventricular volume has been reported to be greater in AN compared with controls, and it has been reported to affect WM diffusivity parameters, at least in the fornix (Kaufmann et al., 2017). In our sample, we could not detect any difference between groups in terms of either total or voxel-wise CSF volumes. It must also be noted that though the TBSS approach is more robust to free water artifacts compared to other procedures (Kaufmann et al., 2017), it can still be affected, though to a lesser extent (Kaufmann et al., 2017). However, free-water artifacts tend to generate false positive rather than false negative results (Stippich, 2015).

Ours is the first study investigating WM microstructural alterations in adolescents with atypical AN, however some limitations exist. First of all, we could not perform a direct comparison of AN patients with atypical AN, thus any interpretation of the differences between these two disorders has to be considered speculative. Moreover, though our sample size was adequate at least for functional MRI studies (Thirion et al., 2007), data are lacking regarding the appropriate sample size for DTI studies. Thus, future studies with larger sample sizes are required to verify and further elucidate our findings. Another important limitation is the delay between the diagnosis and the scanning, leading to starting the treatment before the MRI assessment. As described in the methods, this delay was due to the informed consent protocol and hospital procedures. Nonetheless, whether early-onset effects of the treatment might have affected our results needs to be clarified. Finally, we reported all the relevant information for study reproducibility as suggested by (Frank et al., 2018) and (King, Frank, Thompson, & Ehrlich, 2018); however, some information were missing. For example, we did not have information regarding physical activity of the participants and we were lacking information regarding

the menstrual status of the controls, thus we could not control its relation with WM diffusivity.

5 | CONCLUSIONS

We investigated WM microstructural integrity and neuropsychological scores in a sample of 25 drug-naïve adolescents diagnosed with atypical AN, compared with 25 healthy controls of comparable age. Patients scored significantly higher on the EDE-Q and MADRS-S questionnaires, measuring ED-related and depressive symptomatology, respectively. However, no differences could be detected in WM microstructure between patients and controls, indicating that brain structural alterations do not play a core role in the pathogenesis of atypical AN. These findings also suggest that previous observations of alterations in WM microstructure in full syndrome AN may constitute state-related consequences of severe weight loss. Nonetheless, whether the preservation of WM structure is a discriminant feature of atypical AN will have to be verified by future studies on larger samples, possibly directly comparing AN with atypical AN.

ACKNOWLEDGMENTS

The study was supported by Formas, the Swedish Research Council, the Swedish Brain Research foundation, Gunvoroch Josef Anérs Foundation, A Karlssons Foundation, LR Åkerhams Foundation, Kempe-Carlgrenska Foundation, Tore Nilsons foundation and the Gillbergska Foundation.

CONFLICT OF INTEREST

The authors declare no conflict of interest.

ORCID

Gaia Olivo  <https://orcid.org/0000-0002-7514-4493>

Ingemar Swenne  <https://orcid.org/0000-0003-3352-0742>

REFERENCES

- Alexander, A. L., Lee, J. E., Lazar, M., & Field, A. S. (2007). Diffusion tensor imaging of the brain. *Neurotherapeutics*, 4(3), 316–329. <https://doi.org/10.1016/j.nurt.2007.05.011>
- American Psychiatric Association. (2013). *Diagnostic and statistical manual of mental disorders* (5th ed.). Washington, DC: Author.
- Arain, M., Haque, M., Johal, L., Mathur, P., Nel, W., Rais, A., ... Sharma, S. (2013). Maturation of the adolescent brain. *Neuropsychiatric Disease and Treatment*, 9, 449–461. <https://doi.org/10.2147/NDT.S39776>
- Beato-Fernandez, L., Rodriguez-Cano, T., & Garcia-Vilches, I. (2011). Psychopathological alterations and neuroimaging findings with discriminant value in eating behavior disorders. *Actas Españolas de Psiquiatría*, 39(4), 203–210.
- Beaulieu, C. (2002). The basis of anisotropic water diffusion in the nervous system - a technical review. *NMR in Biomedicine*, 15(7–8), 435–455. <https://doi.org/10.1002/nbm.782>
- Bernardoni, F., King, J. A., Geisler, D., Birkenstock, J., Tam, F. I., Weidner, K., ... Ehrlich, S. (2018). Nutritional status affects cortical folding: Lessons learned from anorexia nervosa. *Biol Psychiatry*, 84(9), 692–701. <https://doi.org/10.1016/j.biopsych.2018.05.008>
- Brockmeyer, T., Bents, H., Holtforth, M. G., Pfeiffer, N., Herzog, W., & Friederich, H. C. (2012). Specific emotion regulation impairments in

- major depression and anorexia nervosa. *Psychiatry Research*, 200(2–3), 550–553. <https://doi.org/10.1016/j.psychres.2012.07.009>
- Carter, J. C., Stewart, D. A., & Fairburn, C. G. (2001). Eating disorder examination questionnaire: Norms for young adolescent girls. *Behaviour Research and Therapy*, 39(5), 625–632.
- Cha, J., Ide, J. S., Bowman, F. D., Simpson, H. B., Posner, J., & Steinglass, J. E. (2016). Abnormal reward circuitry in anorexia nervosa: A longitudinal, multimodal MRI study. *Human Brain Mapping*, 37(11), 3835–3846. <https://doi.org/10.1002/hbm.23279>
- Ekeroth, K., & Birgegard, A. (2014). Evaluating reliable and clinically significant change in eating disorders: Comparisons to changes in DSM-IV diagnoses. *Psychiatry Research*, 216(2), 248–254. <https://doi.org/10.1016/j.psychres.2014.02.008>
- Fairburn, C. G., & Beglin, S. J. (1994). Assessment of eating disorders: Interview or self-report questionnaire? *The International Journal of Eating Disorders*, 16(4), 363–370.
- Fairweather-Schmidt, A. K., & Wade, T. D. (2014). DSM-5 eating disorders and other specified eating and feeding disorders: Is there a meaningful differentiation? *The International Journal of Eating Disorders*, 47(5), 524–533. <https://doi.org/10.1002/eat.22257>
- Frank, G. K. (2015). Advances from neuroimaging studies in eating disorders. *CNS Spectrums*, 20(4), 391–400. <https://doi.org/10.1017/S1092852915000012>
- Frank, G. K., Shott, M. E., Hagman, J. O., & Yang, T. T. (2013). Localized brain volume and white matter integrity alterations in adolescent anorexia nervosa. *Journal of the American Academy of Child and Adolescent Psychiatry*, 52(10), 1066–1075. <https://doi.org/10.1016/j.jaac.2013.07.007>
- Frank, G. K. W., Favaro, A., Marsh, R., Ehrlich, S., & Lawson, E. A. (2018). Toward valid and reliable brain imaging results in eating disorders. *The International Journal of Eating Disorders*, 51(3), 250–261. <https://doi.org/10.1002/eat.22829>
- Franko, D. L., & Keel, P. K. (2006). Suicidality in eating disorders: Occurrence, correlates, and clinical implications. *Clinical Psychology Review*, 26(6), 769–782. <https://doi.org/10.1016/j.cpr.2006.04.001>
- Frieling, H., Fischer, J., Wilhelm, J., Engelhorn, T., Bleich, S., Hillemecher, T., ... Peschel, T. (2012). Microstructural abnormalities of the posterior thalamic radiation and the mediodorsal thalamic nuclei in females with anorexia nervosa—A voxel based diffusion tensor imaging (DTI) study. *Journal of Psychiatric Research*, 46(9), 1237–1242. <https://doi.org/10.1016/j.jpsychires.2012.06.005>
- Gaudio, S., Quattrocchi, C. C., Piervincenzi, C., Zobel, B. B., Montecchi, F. R., Dakanalis, A., ... Carducci, F. (2017). White matter abnormalities in treatment-naïve adolescents at the earliest stages of anorexia nervosa: A diffusion tensor imaging study. *Psychiatry Research*, 266, 138–145. <https://doi.org/10.1016/j.psychres.2017.06.011>
- Goodman, A., Heshmati, A., Malki, N., & Koupil, I. (2014). Associations between birth characteristics and eating disorders across the life course: Findings from 2 million males and females born in Sweden, 1975–1998. *American Journal of Epidemiology*, 179(7), 852–863. <https://doi.org/10.1093/aje/kwt445>
- Harrington, B. C., Jimerson, M., Haxton, C., & Jimerson, D. C. (2015). Initial evaluation, diagnosis, and treatment of anorexia nervosa and bulimia nervosa. *American Family Physician*, 91(1), 46–52.
- Jaite, C., Hoffmann, F., Glaeske, G., & Bachmann, C. J. (2013). Prevalence, comorbidities and outpatient treatment of anorexia and bulimia nervosa in German children and adolescents. *Eating and Weight Disorders*, 18(2), 157–165. <https://doi.org/10.1007/s40519-013-0020-4>
- Jauregui-Lobera, I. (2011). Neuroimaging in eating disorders. *Neuropsychiatric Disease and Treatment*, 7, 577–584. <https://doi.org/10.2147/NDT.S25186>
- Jones, D. K., & Cercignani, M. (2010). Twenty-five pitfalls in the analysis of diffusion MRI data. *NMR in Biomedicine*, 23(7), 803–820. <https://doi.org/10.1002/nbm.1543>
- Kaufmann, L. K., Baur, V., Hanggi, J., Jancke, L., Piccirelli, M., Kollias, S., ... Milos, G. (2017). Fornix under water? Ventricular enlargement biases Forniceal diffusion magnetic resonance imaging indices in anorexia nervosa. *Biological Psychiatry Cognitive Neuroscience and Neuroimaging*, 2(5), 430–437. <https://doi.org/10.1016/j.bpsc.2017.03.014>
- Kazlouski, D., Rollin, M. D., Tregellas, J., Shott, M. E., Jappe, L. M., Hagman, J. O., ... Frank, G. K. (2011). Altered fimbria-fornix white matter integrity in anorexia nervosa predicts harm avoidance. *Psychiatry Research*, 192(2), 109–116. <https://doi.org/10.1016/j.psychres.2010.12.006>
- Kievit, R. A., Frankenhuus, W. E., Waldorp, L. J., & Borsboom, D. (2013). Simpson's paradox in psychological science: A practical guide. *Frontiers in Psychology*, 4, 513. <https://doi.org/10.3389/fpsyg.2013.00513>
- King, J. A., Frank, G. K. W., Thompson, P. M., & Ehrlich, S. (2017). Structural neuroimaging of anorexia nervosa: Future directions in the quest for mechanisms underlying dynamic alterations. *Biological Psychiatry*, 83(3), 224–234. <https://doi.org/10.1016/j.biopsych.2017.08.011>
- King, J. A., Frank, G. K. W., Thompson, P. M., & Ehrlich, S. (2018). Structural neuroimaging of anorexia nervosa: Future directions in the quest for mechanisms underlying dynamic alterations. *Biological Psychiatry*, 83(3), 224–234. <https://doi.org/10.1016/j.biopsych.2017.08.011>
- Koutek, J., Kocourkova, J., & Dudova, I. (2016). Suicidal behavior and self-harm in girls with eating disorders. *Neuropsychiatric Disease and Treatment*, 12, 787–793. <https://doi.org/10.2147/NDT.S103015>
- Lahteenmaki, S., Saarni, S., Suokas, J., Saarni, S., Perala, J., Lonnqvist, J., & Suvisaari, J. (2014). Prevalence and correlates of eating disorders among young adults in Finland. *Nordic Journal of Psychiatry*, 68(3), 196–203. <https://doi.org/10.3109/08039488.2013.797021>
- Lebel, C., Treit, S., & Beaulieu, C. (2017). A review of diffusion MRI of typical white matter development from early childhood to young adulthood. *NMR in Biomedicine*. <https://doi.org/10.1002/nbm.3778>. [Epub]
- Lule, D., Schulze, U. M., Bauer, K., Scholl, F., Muller, S., Fladung, A. K., & Uttner, I. (2014). Anorexia nervosa and its relation to depression, anxiety, alexithymia and emotional processing deficits. *Eating and Weight Disorders*, 19(2), 209–216. <https://doi.org/10.1007/s40519-014-0101-z>
- Mangweth-Matzek, B., & Hoek, H. W. (2017). Epidemiology and treatment of eating disorders in men and women of middle and older age. *Current Opinion in Psychiatry*, 30(6), 446–451. <https://doi.org/10.1097/YCO.0000000000000356>
- Moskowitz, L., & Weiselberg, E. (2017). Anorexia Nervosa/Atypical Anorexia Nervosa. *Current Problems in Pediatric and Adolescent Health Care*, 47(4), 70–84. <https://doi.org/10.1016/j.cped.2017.02.003>
- Nagahara, Y., Nakamae, T., Nishizawa, S., Mizuhara, Y., Moritoki, Y., Wada, Y., ... Fukui, K. (2014). A tract-based spatial statistics study in anorexia nervosa: Abnormality in the fornix and the cerebellum. *Progress in Neuro-Psychopharmacology & Biological Psychiatry*, 51, 72–77. <https://doi.org/10.1016/j.pnpbp.2014.01.009>
- Olivo, G., Solstrand Dahlberg, L., Wiemerslage, L., Swenne, I., Zhukovsky, C., Salonen-Ros, H., ... Schiöth, H. B. (2018). Atypical anorexia nervosa is not related to brain structural changes in newly diagnosed adolescent patients. *The International Journal of Eating Disorders*, 51(1), 39–45. <https://doi.org/10.1002/eat.22805>
- Olivo, G., Wiemerslage, L., Swenne, I., Zhukovsky, C., Salonen-Ros, H., Larsson, E. M., ... Schiöth, H. B. (2017). Limbic-thalamo-cortical projections and reward-related circuitry integrity affects eating behavior: A longitudinal DTI study in adolescents with restrictive eating disorders. *PLoS One*, 12(3), e0172129. <https://doi.org/10.1371/journal.pone.0172129>
- Pfuhl, G., King, J. A., Geisler, D., Roschinski, B., Ritschel, F., Seidel, M., ... Ehrlich, S. (2016). Preserved white matter microstructure in young patients with anorexia nervosa? *Human Brain Mapping*, 37(11), 4069–4083. <https://doi.org/10.1002/hbm.23296>
- Sawyer, S. M., Whitelaw, M., Le Grange, D., Yeo, M., & Hughes, E. K. (2016). Physical and psychological morbidity in adolescents with atypical anorexia nervosa. *Pediatrics*, 137(4), e20154080. <https://doi.org/10.1542/peds.2015-4080>
- Seitz, J., Buhren, K., von Polier, G. G., Heussen, N., Herpertz-Dahlmann, B., & Konrad, K. (2014). Morphological changes in the brain of acutely ill and weight-recovered patients with anorexia nervosa. A meta-analysis and qualitative review. *Z Kinder Jugendpsychiatr Psychother*, 42(1), 7–17; quiz 17–18. <https://doi.org/10.1024/1422-4917/a000265>
- Seitz, J., Herpertz-Dahlmann, B., & Konrad, K. (2016). Brain morphological changes in adolescent and adult patients with anorexia nervosa. *Journal of Neural Transmission*, 123(8), 949–959. <https://doi.org/10.1007/s00702-016-1567-9>

- Smink, F. R., van Hoeken, D., & Hoek, H. W. (2012). Epidemiology of eating disorders: Incidence, prevalence and mortality rates. *Current Psychiatry Reports*, 14(4), 406–414. <https://doi.org/10.1007/s11920-012-0282-y>
- Smith, S. M. (2002). Fast robust automated brain extraction. *Human Brain Mapping*, 17(3), 143–155. <https://doi.org/10.1002/hbm.10062>
- Smith, S. M., Jenkinson, M., Johansen-Berg, H., Rueckert, D., Nichols, T. E., MacKay, C. E., ... Behrens, T. E. (2006). Tract-based spatial statistics: Voxelwise analysis of multi-subject diffusion data. *NeuroImage*, 31(4), 1487–1505. <https://doi.org/10.1016/j.neuroimage.2006.02.024>
- Smith, S. M., Jenkinson, M., Woolrich, M. W., Beckmann, C. F., Behrens, T. E., Johansen-Berg, H., ... Matthews, P. M. (2004). Advances in functional and structural MR image analysis and implementation as FSL. *NeuroImage*, 23(Suppl 1), S208–S219. <https://doi.org/10.1016/j.neuroimage.2004.07.051>
- Smith, S. M., & Nichols, T. E. (2009). Threshold-free cluster enhancement: Addressing problems of smoothing, threshold dependence and localisation in cluster inference. *NeuroImage*, 44(1), 83–98. <https://doi.org/10.1016/j.neuroimage.2008.03.061>
- Stippich, C. (2015). *Clinical functional MRI: Presurgical functional neuroimaging* (2nd ed.). Berlin Heidelberg: Springer-Verlag.
- Svanborg, P., & Asberg, M. (1994). A new self-rating scale for depression and anxiety states based on the comprehensive psychopathological rating scale. *Acta Psychiatrica Scandinavica*, 89(1), 21–28.
- Sweeting, H., Walker, L., MacLean, A., Patterson, C., Raisanen, U., & Hunt, K. (2015). Prevalence of eating disorders in males: A review of rates reported in academic research and UK mass media. *International Journal of Men's Health*, 14(2). <https://doi.org/10.3149/jmh.1402.86>
- Thirion, B., Pinel, P., Mériaux, S., Roche, A., Dehaene, S., & Poline, J. B. (2007). Analysis of a large fMRI cohort: Statistical and methodological issues for group analyses. *NeuroImage*, 35(1), 105–120. <https://doi.org/10.1016/j.neuroimage.2006.11.054>
- Travis, K. E., Golden, N. H., Feldman, H. M., Solomon, M., Nguyen, J., Mezer, A., ... Dougherty, R. F. (2015). Abnormal white matter properties in adolescent girls with anorexia nervosa. *NeuroImage: Clinical*, 9, 648–659. <https://doi.org/10.1016/j.nicl.2015.10.008>
- Vogel, K., Timmers, I., Kumar, V., Nickl-Jockschat, T., Bastiani, M., Roebroek, A., ... Seitz, J. (2016). White matter microstructural changes in adolescent anorexia nervosa including an exploratory longitudinal study. *NeuroImage: Clinical*, 11, 614–621. <https://doi.org/10.1016/j.nicl.2016.04.002>
- von Schwabenflug, N., Müller, D. K., King, J. A., Ritschel, F., Bernardoni, F., Mohammadi, S., ... Ehrlich, S. (2018). Dynamic changes in white matter microstructure in anorexia nervosa: Findings from a longitudinal study. *Psychological Medicine*, 1–10. <https://doi.org/10.1017/S003329171800212X>. [Epub].
- Wang, B., Wu, P., Kwan, B., Tu, X. M., & Feng, C. (2018). Simpson's Paradox: Examples. *Shanghai Archives of Psychiatry*, 30(2), 139–143. <https://doi.org/10.11919/j.issn.1002-0829.218026>
- Wang, S., & Young, K. M. (2014). White matter plasticity in adulthood. *Neuroscience*, 276, 148–160. <https://doi.org/10.1016/j.neuroscience.2013.10.018>
- Xu, J., Li, Y., Lin, H., Sinha, R., & Potenza, M. N. (2013). Body mass index correlates negatively with white matter integrity in the fornix and corpus callosum: A diffusion tensor imaging study. *Human Brain Mapping*, 34(5), 1044–1052. <https://doi.org/10.1002/hbm.21491>

How to cite this article: Olivo G, Swenne I, Zhukovsky C, et al. Preserved white matter microstructure in adolescent patients with atypical anorexia nervosa. *Int J Eat Disord*. 2019; 1–9. <https://doi.org/10.1002/eat.23012>