

Original Article

A New Navigation System for Minimally Invasive Total Knee Arthroplasty

Yusuke Yokoyama^a, Nobuhiro Abe^{b,c,*}, Kazuo Fujiwara^c, Masahiko Suzuki^d,
Yoshikazu Nakajima^e, Naohiko Sugita^e, Mamoru Mitsuishi^e,
Yoshio Nakashima^f, and Toshifumi Ozaki^a

Departments of ^aOrthopaedic Surgery, ^cIntelligent Orthopaedic System, Okayama University Graduate School of Medicine, Dentistry and Pharmaceutical Sciences, Okayama 700-8558, Japan, ^bDepartment of Orthopaedic Surgery and Sport Medicine, Kawasaki Hospital, Kawasaki Medical School, Okayama 700-8505, Japan, ^dResearch Center for Frontier Medical Engineering, Chiba University, Inage-ku, Chiba 263-8522, Japan, ^eSchool of Engineering, The University of Tokyo, Tokyo 113-8656, Japan, ^fNakashima Medical Co., Ltd., Okayama 709-0625, Japan

A computer-assisted navigation system to be used for total knee arthroplasties (TKAs) was reported to improve the accuracy of bone resection and result in precise implant placement, but the concomitant surgical invasion and time consumption are clinical problems. We developed a computed tomography (CT)-based navigation system (NNS) to be used for minimally invasive TKA. It requires only the reference points from a small limited area of the medial femoral condyle and proximal tibia through a skin incision to obtain optical images. Here we evaluated the usefulness and accuracy of the NNS in comparison with the commercially available BrainLAB image-free navigation system (BLS). In a clinical experiment, the registration times obtained with the NNS tended to be shorter than those obtained with the BLS, but not significantly so. The NNS group tended to be in the extended position in the sagittal plane of the distal femur within 3 degrees, and the BLS group showed rather flexed deviation in the sagittal plane of the anterior femur.

Key words: total knee arthroplasty, navigation system, minimally invasive surgery

Total knee arthroplasty (TKA) has become one of the most successful procedures in orthopedics, with survival rates greater than 90% after 15 years [1, 2]. The success of a TKA is dependent on many factors including preoperative patient characteristics, the implant selection, the implantation technique, and most importantly, the component and limb alignment [3]. Any misalignment of the components could lead to various types of implant failure, such as aseptic

loosening and instability, polyethylene wear, and patellar dislocation [4-6]. In particular, an error in the coronal positioning of more than 3° significantly increases the rate of failure of the component [4, 6].

The use of a navigation system was reported to improve the accuracy of bone resection and positioning of implants for TKAs [7, 8]. The majority of studies examining computer-assisted TKA surgery have shown more consistent restoration of neutral mechanical alignment, with improved precision of component placement in one or more of the measured anatomic planes, compared to conventional TKA [3, 8-10]. Several studies have demonstrated superior

alignment of the components in the coronal plane in navigated TKA compared to conventional TKA, with fewer outliers outside a range of 3° varus or valgus [3, 10–12]. Proponents of computer-assisted surgery (CAS) have argued that the improved consistency of alignment seen in association with computer navigation will improve implant longevity and decrease the revision rate.

However, CAS presents some clinical problems concerning surgical invasion [8, 11, 13, 14]. Navigated TKA requires extensive joint exposure and a large skin incision for precise registration, and the surgical time necessary for navigated TKA was reported to be longer than that of conventional TKA [8, 13]. A recent study reported that navigated TKA took 27 min longer than TKA with an intramedullary guide [14]. In orthopedic surgery, there is considerable interest in minimally invasive (MI) surgical techniques [15]. Encouraging intermediate-term results have been reported for unicompartmental knee arthroplasty performed with a smaller incision, limited arthrotomy, and without patellar eversion [16]. It is also possible to perform a navigated TKA with a smaller incision and without patellar eversion. Many surgeons usually prefer the MI TKA, and it is sometimes a challenge to obtain the appropriate surgical exposure and identify the reference landmarks.

We have developed a new navigation system for minimally invasive TKA, and it has been used in a rather limited area for registration. The purpose of the present study was to evaluate the new developed navigation system (NNS) regarding the precision of the osteotomized plane and the system's handling compared with a commercially available navigation system (Ci Knee, BrainLAB, Feldkirchen, Germany), especially in light of the need for minimally invasive surgery.

Materials and Methods

Newly developed navigation system. The NNS is a computed tomography (CT)-based navigation system followed the preoperative planning after intraoperative registration. With this system, preoperative CT scans of the hip, knee and ankle region are collected. In the pre-operative planning process, the system first generates a three-dimensional reconstruction model through the femoral head to the distal end of the tibia. This planning allows the precise orienta-

tion of the prosthetic components and presents an optimal alignment to the mechanical limb axis with a computer-simulation technique.

The NNS has an optical tracking unit which detects reflecting spheric markers by an infrared camera. These reflected tracker markers are respectively placed into the distal femur and proximal tibia for detecting the position and orientation of the leg. The surgical preoperative plan is matched to the intraoperative knee by the reference points that were obtained from anatomical landmarks by pointing with a paired point-matching technique, the articular surface registered by sliding a pointer with a surface morphing method, and the center of the femoral head is calculated using a pivoting algorithm by slowly rotating and crossing the femoral head with the leg.

In MI surgeries, only a small limited area of the medial femoral condyle and proximal tibia are visible through the skin incision for surgical exposure, and thus the anatomical landmarks of the distal femur were registered with the medial and lateral epicondyle on the skin. The surface of the medial distal femoral condyle and the lateral intercondylar notch are used only for surface matching (Fig. 1A, B). The configuration of the lateral component was not necessary for the registration.

The anatomical landmarks of the tibia are also registered with the medial edge of the tibial tuberosity, medial malleolus and lateral malleolus on the skin. The surface of the anterior cortex of the proximal tibia, the medial edge, the medial tibial plateau and the medial tibial tuberosity were used for surface matching (Fig. 1C) through the surgical area. The information about the lateral side of the tibia is not needed. The medial and lateral malleoli are registered with the surface matching technique by morphing on the skin (Fig. 1D, E).

BrainLAB navigation system. The commercially available BrainLAB navigation system (BLS), which is an image-free navigation system, was used at the same time for comparison with the NNS. The BLS has an infrared optical tracking unit as does the NNS, but without a matching intra-operative knee for the preoperative planning. The reference points are collected to define the joint line and mechanical axis in three-dimensional planes as follows.

The location of the center of the femur head is determined by rotational calculations, similar to the

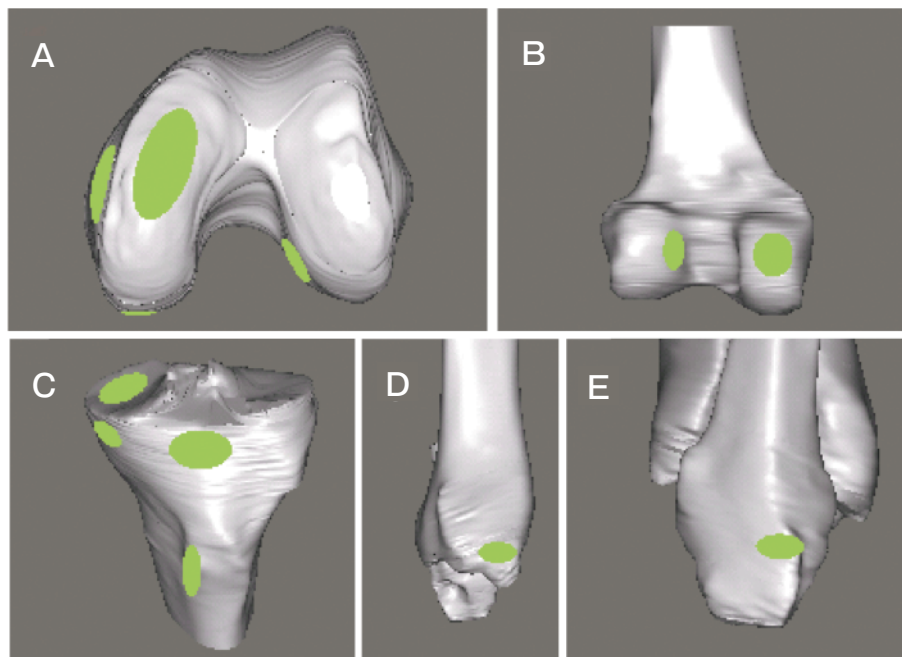


Fig. 1 The small limited area for the surface registration point in the NNS. The area of femur for registration was the surface of the distal plane, medial edge (**A**) and the posterior plane (**B**) of the medial condyle. The surface of the lateral intercondylar notch (**B**) was added. The area of tibia for registration was the surface of the anterior cortex of the proximal tibia, the medial edge, the medial plateau, and the medial tibial tuberosity (**C**). In addition, the surfaces of the medial (**D**) and lateral malleoli (**E**) were registered on the skin.

NNS technique. The specific anatomic landmarks on the femur are registered at the medial epicondyle, the lateral epicondyle, the center of the distal femoral condyle, the trochlear groove (Whiteside line), the surface of the anterior distal femoral cortex, the surface of the medial distal femoral condyle, and the distal lateral femoral condyle.

The neutral rotational plane of the femur is derived from an average of the epicondylar position and the trochlear groove. The coronal alignment on the femur is determined by variation from a plane that runs through the center of the distal femoral condyle and the derived center of the femoral head. For the tibia, the surgeon uses the pointer to identify the center of the tibial plateau, the surfaces of the medial and lateral tibial condyles, and the neutral anterior-posterior (AP) axis of the knee. This AP axis is judged as a line from the center of the posterior cruciate ligament to the intercondylar spine of the proximal tibia. At the ankle, the tips of the medial and lateral malleoli are palpated and marked on the skin. The center of the ankle is identified by the medial and lateral malleoli. The long axis of the tibia is then the line

between the center of the tibial plateaus and the center of the ankle.

In both the NNS and the BLS, the femoral and tibial cutting blocks are oriented to the bone in real-time visualization on the navigation system. After resection, all planes are evaluated by the navigation system's verification tool.

Bone model experiment. CT scans for the entire lower leg (from the femur head to the ankle joint) were performed with 5 bone models (Sawbones[®], Pacific Research Laboratories Inc., Vashon, WA, USA). Registration was performed by 2 navigation systems and the above-described method. Bone cutting was achieved by using the 2 navigation systems at the same time (Fig. 2A, B).

The alignment and position of the cutting surface were evaluated by each navigation system. The evaluation of the alignment and position of distal femur was performed for flexion/extension, varus/valgus and bone resection volume (Fig. 3A). The evaluation of the anterior femoral surface was performed for the position of flexion/extension, rotation and AP shift (Fig. 3B). In the osteotomized surface of the proxi-

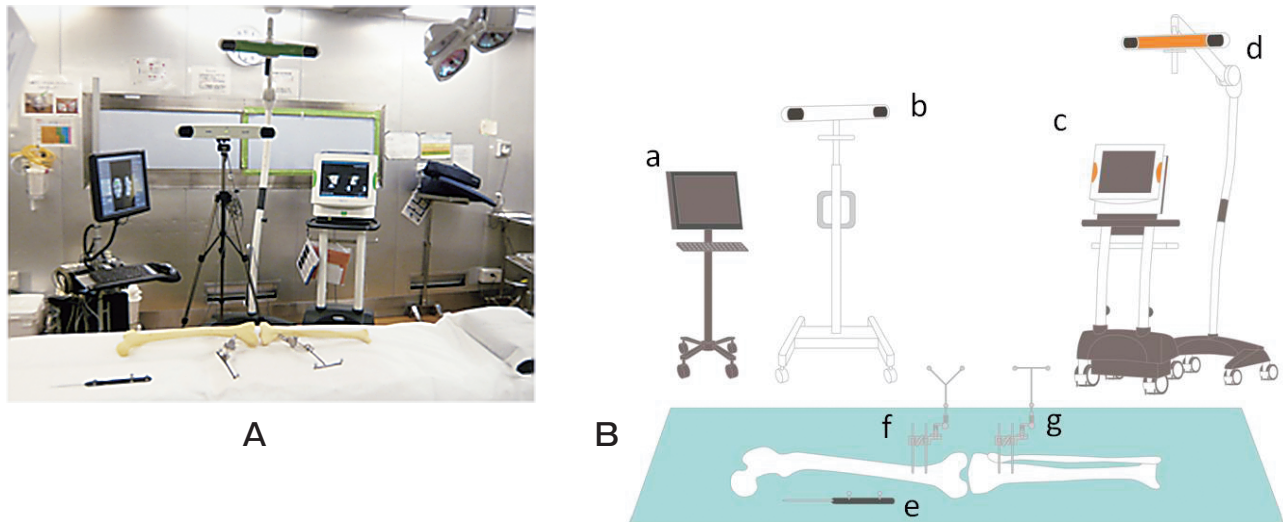


Fig. 2 **A**, Two navigation systems were simultaneously analyzed in a bone model experiment. Registration was respectively performed using both navigation systems; **B**, Double navigation schema. The NNS' navigation system (a), the NNS optical tracking unit (b), the BLS' navigation system (c), the BLS optical tracking unit (d), the reference pointer (e), the femoral reflected marker (f), and the tibial reflected marker (g).

mal tibia, the position of the proximal tibia was evaluated for the posterior slope, varus/valgus angle and bone resection volume (Fig. 3C). The cutting surface was also measured using a 3D surface scanner (Renishaw-Cyclone, Mitutoyo, Kanagawa, Japan) as the absolute values. The accuracy was evaluated by the difference between these absolute values and the data measured by each navigation system.

Clinical experiment. The research protocol was approved by the Institutional Review Board of the Okayama University Graduate School, and all patients gave written consent to participate in the study. From January 2010 to May 2011, we performed 30 TKAs in 29 patients (3 men, 26 women) using both navigation systems at our institution (Fig. 4). The patients' mean age was 72 ± 7.4 (range 54–86) years. Twenty-four knees had been diagnosed with osteoarthritis, and 6 with rheumatoid arthritis.

The surgical technique consisted of a medial mini-parapatellar approach through a 9- to 10-cm skin incision, no patellar eversion and thus minimum invasion to the quadriceps muscle for the knee extensor mechanism. The other stab skin incisions for tracker pins were added above both the femoral and tibial bones. Registration was performed by the NNS and BLS navigation systems as described above. The times for registration were recorded and compared.

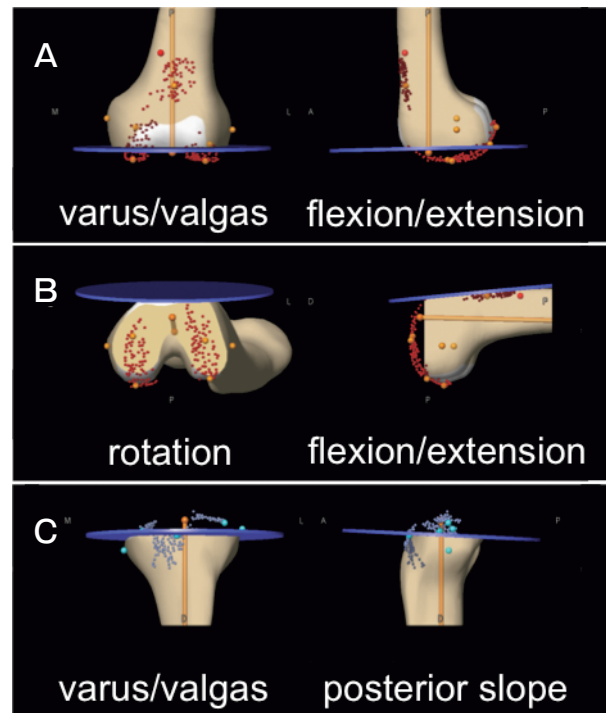


Fig. 3 The evaluation of the alignment and position of the cutting surface. **(A)** The evaluation of the distal femur was performed for varus/valgus, flexion/extension and bone resection volume. **(B)** The evaluation of anterior femur was performed for rotation, flexion/extension and AP shift. **(C)** The position of proximal tibia was evaluated for varus/valgus, posterior slope and bone resection volume.

Bone resection was performed under the direction of the BLS. The alignment and position of the cutting surface were evaluated by both navigation systems respectively. Postoperative CT-scans using 1-mm contiguous slices were performed for the entire lower leg, and a three-dimensional leg model was reconstructed from these data according to the Perth CT protocol [17]. The alignment and position of the components were measured by 3D software (Mimics, Materialise, Leuven, Belgium), and the data obtained were evaluated and compared with the 2 navigation systems.

Statistical analysis. Results are expressed as mean values with standard deviations. Mann-Whitney *U*-test was used for continuous variables. Significance

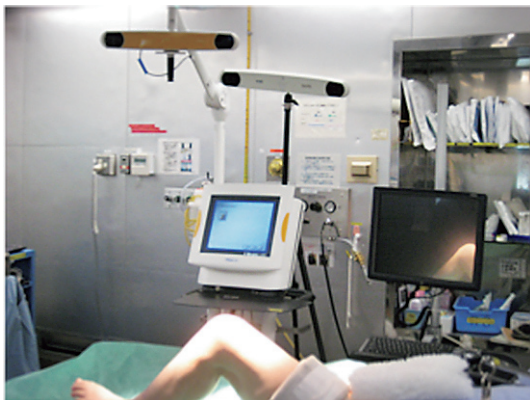

Fig. 4 In the clinical experiment, the 2 navigation systems were placed the same as in the bone model experiment. Registration was respectively performed using both navigation systems.

was established at $p < 0.05$.

Results

Bone model experiment. The deviation of each navigation system's data in comparison with the 3D scanner measurement of the bone models is presented in Table 1. The deviation between the group NNS/group BLS data was $0.6 \pm 0.8/0.6 \pm 1.0$ degrees on the coronal plane, $0.8 \pm 1.2/3.0 \pm 1.9$ degrees on the sagittal plane, and $1.1 \pm 0.9/1.0 \pm 0.8$ mm on bone resection at the cutting surface of the distal femur.

The deviation at the cutting surface of the anterior femur was $0.1 \pm 3.0/2.1 \pm 1.3$ degrees on rotation, $1.7 \pm 0.1/0.2 \pm 0.6$ degrees on the sagittal plane, and $0.4 \pm 3.3/0.8 \pm 1.5$ mm on bone resection.

The deviation at the cutting surface of the proximal tibia was $0.2 \pm 1.3/0.2 \pm 0.4$ degrees on the coronal plane, $0.1 \pm 0.4/0.2 \pm 2.0$ degrees on the sagittal plane, and $0.6 \pm 1.7/1.1 \pm 0.2$ mm on bone resection. There was no significant difference between the 2 groups' data, and both groups had sufficient accuracy to perform the appropriate placement of components [4, 6].

Clinical experiment. The registration time for the femur in group NNS/group BLS was $115.5 \pm 28.1/117.6 \pm 42.6$ sec, and the tibial registration time was $111.9 \pm 22.5/119.4 \pm 37.2$ sec. The total registration time was $227.4 \pm 46.6/237.1 \pm 63.9$ sec (Table 2). There was no significant difference between the 2 groups.

The deviation in the group NNS/group BLS data

Table 1 The deviation of the NNS and BLS navigation systems compared with 3D scanner measurements in the bone model experiment

Variable	Positive direction	NDS	BLS	<i>p</i> value
Distal femur				
flexion/extension (°)	extension	-0.8 ± 1.2	-3.0 ± 1.9	0.175
varus/valgus (°)	valgus	0.6 ± 0.8	0.6 ± 1.0	1.000
bone resection (mm)	proximal	1.1 ± 0.9	1.0 ± 0.8	0.897
Anterior femur				
flexion/extension (°)	extension	1.7 ± 0.1	0.2 ± 0.6	0.080
rotation (°)	external	0.1 ± 3.0	2.1 ± 1.3	0.341
AP shift (mm)	anterior	0.4 ± 3.3	0.8 ± 1.5	0.890
Proximal tibia				
posterior slope (°)	posterior	0.1 ± 0.4	-0.2 ± 2.0	0.981
varus/valgus (°)	valgus	-0.2 ± 1.3	-0.2 ± 0.4	1.000
bone resection (mm)	proximal	-0.6 ± 1.7	1.1 ± 0.2	0.155

NNS, newly developed navigation system; BLS, BrainLAB navigation system.

compared to the measured CT data was $1.1 \pm 1.2/0.9 \pm 1.1$ degrees on the coronal plane, $2.5 \pm 2.2/0.4 \pm 2.7$ degrees on the sagittal plane, and $1.1 \pm 2.9/0.1 \pm 1.6$ mm on bone resection at the cutting surface of the distal femur.

The deviation at the cutting surface of the anterior femur was $1.1 \pm 2.8/0.2 \pm 6.8$ degrees on rotation, $0.9 \pm 1.5/4.4 \pm 1.6$ degrees on the sagittal plane, and $0.9 \pm 1.6/1.6 \pm 0.6$ mm on bone resection.

The deviation at the cutting surface of the proximal tibia was $0.5 \pm 1.2/0.4 \pm 1.3$ degrees on the coronal plane, $0.8 \pm 2.0/1.5 \pm 0.9$ degrees on the sagittal plane, and $0.9 \pm 2.9/0.7 \pm 2.5$ mm on bone resection (Table 3). The accuracy of the sagittal planes in the anterior femur and proximal tibia was significantly precise in the NNS group. The AP shift in the anterior femur differed significantly between the groups ($p < 0.001$).

Discussion

Minimally invasive (MI) surgical techniques may result in decreased pain, faster recovery, greater

quadriceps muscle strength, improved cosmetic appearance, and higher patient satisfaction [15, 18]. However, MI techniques have also been associated with longer operative times, less than optimal joint alignments, and higher frequencies of malposition or loosening of components in TKA [18]. Navigation systems have been associated with greater accuracy of component alignment, a higher frequency of normal femorotibial axes, and fewer radiographic outliers. Commercialized navigation techniques may require extensive joint exposure and large skin incisions for precise registration.

In our earlier study, we evaluated the precision of a CT-based navigation system (BrainLAB ver. 1.6) for MI TKA. The deviation of MI cases was larger than that of standard surgical exposed cases [19]. These 2 techniques may conflict, but an MI technique would be preferred in clinical situations if the navigation system would be correctly worked even in small limited surgical exposure.

The surgical time needed for navigated TKA was also reported to be longer than that of conventional TKA [8, 13]. Moreover, MI TKA also requires a longer time. Bonutti *et al.* [18] reported that MI navigated TKA had longer surgical times (by a mean of 58 min) than MI TKA. In the present study, we found no significant difference in registration time between the NNS and BLS groups. However, the registration times for the NNS group showed only a small standard deviation, and thus NNS has the advantage of being an easy-to-use, surgeon-friendly system. Moreover, this reproductive method using

Table 2 Registration times obtained with the NNS and BLS in the clinical experiment

	NDS	BLS	p value
Femoral registration (s)	115.5 ± 28.1	117.6 ± 42.6	0.857
Tibial registration (s)	111.9 ± 22.5	119.4 ± 37.2	0.457
Total registration (s)	227.4 ± 46.6	237.1 ± 63.9	0.600

NDS, newly developed navigation system; BLS, BrainLAB navigation system.

Table 3 The deviations obtained with the 2 navigation systems in comparison with the measured CT data

Variable	Positive direction	NDS	BLS	p value
Distal femur				
flexion/extension ($^{\circ}$)	extension	2.5 ± 2.1	0.5 ± 2.4	*0.029
varus/valgus ($^{\circ}$)	valgus	1.2 ± 1.2	0.9 ± 1.1	0.614
bone resection (mm)	proximal	1.1 ± 2.9	-0.1 ± 1.6	0.437
Anterior femur				
flexion/extension ($^{\circ}$)	extension	1.0 ± 1.6	-4.6 ± 1.8	* < 0.001
rotation ($^{\circ}$)	external	1.1 ± 2.7	0.1 ± 5.8	0.556
AP shift (mm)	anterior	-0.8 ± 1.5	1.4 ± 0.8	* < 0.001
Proximal tibia				
posterior slope ($^{\circ}$)	posterior	0.6 ± 1.8	-1.8 ± 1.0	* < 0.001
varus/valgus ($^{\circ}$)	valgus	0.3 ± 1.2	0.2 ± 1.4	0.963
bone resection (mm)	proximal	0.9 ± 2.9	-0.7 ± 2.5	0.275

NDS, newly developed navigation system; BLS, BrainLAB navigation system.

* $p < 0.05$.

NNS would provide accurate registration for precise implantation even in different variants and severe deformities of the knees.

Image-free navigation systems are more widely used than the CT-based navigation systems, probably because of the need for pre-operative CT scans and the planning time. Martin *et al.* [20] reported that their comparison of the accuracy of a CT-based navigation system with that of an image-free navigation system showed no differences in the postoperative alignment using the radiographs. However, some studies have demonstrated that using CT scan data, which was reconstructed as three-dimensional images, was necessary for precise preoperative TKA planning to avoid alignment failure [21–23].

Several studies suggested that deviations in the mechanical axis following image-free navigated TKA might be the result of inaccurate landmarking [24, 25]. For image-free TKA, the data for constructing the numerical model are acquired during operation. This is usually done by visual selection of the anatomic landmarks and/or the kinematics method, which requires the surgeon's ability. Yau *et al.* [24] reported that the maximum potential error in the identification of the medial femoral epicondyle could be up to 7.6mm because of the thick soft tissue covering. Moreover, Brin *et al.* [25] reported that inaccuracies of landmarking as much as 5mm caused a significant axis deviation. This source of inaccuracy is especially evident when arthritis changes the knee's normal anatomy, and some of the landmarks are more difficult to recognize. Finally, Takasaki *et al.* [26] cautioned that great care must be taken when using image-free navigation for severely deformed knees.

In the present bone model experiment, there was no significant difference between the NNS and BLS groups, and the accuracy in both the NNS and BLS groups was sufficient to perform the appropriate placement of components referred from previous reviews [4, 6]. However, various deviations were shown with both groups in more complicated clinical situations.

The NNS is a CT-based navigation system which requires not only the anatomic landmarks but also the surface information for registration. This navigation system has been set up to increase the percentage of surface matching for correct registration. The accuracy of the present NNS group showed that the align-

ment error was less than 2° and the position error was less than 2mm in other than the sagittal plane of the distal femur, which was indicated as the sagittal alignment error ($2.5 \pm 2.1^\circ$ less than 3°).

Notching of the anterior femoral cortex contributes to complications such as postoperative femoral fracture. In the sagittal plane of the femur, there are 2 important requirements for navigation systems: (1) the perpendicular cut of the distal femoral plane to the femoral mechanical axis, and (2) the prevention of notching of the anterior femoral cortex. However, these 2 requirements may conflict [27].

The sagittal alignment of the distal femur in our present NNS group had a tendency toward extension ($2.5 \pm 2.1^\circ$). When using the NNS, surgeons need to recognize that the cutting surface of the distal femur tends to be in an extended position and would use caution to be more flexed to avoid the anterior notching. On the other hand, the sagittal alignment of the anterior femur in the BLS group tended to be flexion ($4.6 \pm 1.8^\circ$). This avoidance of the notch was accomplished with a computer program with the recognition of the anterior femoral cortex. However, the large deviation of the sagittal plane affects the ligament balances and the patellofemoral joint, which leads to implant failure.

The specific registration areas of the NNS for minimally invasive TKA consist of the surface of the lateral intercondylar notch, the medial tibial tuberosity, and the medial malleolous and lateral malleolous. These areas contribute to the accuracy of the alignment and the position of the cutting surface.

The use of the NNS in the present study showed much error in the deviation angle of the osteotomized distal femur, but less deviation of the anterior femur plane. These paradoxical results are related to the femoral component rotation around the femoral mechanical axis. Thus the NNS could indicate the precise rotation of a femoral implant according to anatomical landmarks.

Bonner *et al.* reported that the relationship between the survival rate of a TKA and mechanical axis alignment was weaker than that described in a number of previous reports [28]. However, the angle of the osteotomized plane remains a satisfactory target to obtain the appropriate ligament balance in TKA. Therefore, the navigation system would have an effective means of the precise implantation.

The present study has some limitations. First, the number of patients is relatively small. Second, the rotational alignment of the tibial component was not evaluated. Lewis *et al.* [29] reported that malrotation caused rotational incongruity between femoral and tibial components, resulting in increased contact stresses along the tibia during flexion.

In conclusion, this experimental study demonstrated that our newly developed navigation system had enough accuracy for the bone resection of the knee even in small and limited registration areas.

Acknowledgments. We thank Mr. Takayuki Inoue, Mr. Ryotaro Koizumi and Mr. Kunihiko Fujiwara for their support. This work was supported by a grant from the Ministry of Economy, Trade and Industry (Standardization Promotion Program in Asia 2010).

References

- Vessely MB, Whaley AL, Harmsen WS, Schleck CD and Berry DJ: The Chitranjan Ranawat Award: Long-term survivorship and failure modes of 1000 cemented condylar total knee arthroplasties. *Clin Orthop Relat Res* (2006) 452: 28–34.
- Rodricks DJ, Patil S, Pulido P and Colwell CW Jr: Press-fit condylar design total knee arthroplasty. Fourteen to seventeen-year follow-up. *J Bone Joint Surg Am* (2007) 89: 89–95.
- Kim SJ, MacDonald M, Hernandez J and Wixson RL: Computer assisted navigation in total knee arthroplasty: improved coronal alignment. *J Arthroplasty* (2005) 20: 123–131.
- Jeffery RS, Morris RW and Denham RA: Coronal alignment after total knee replacement. *J Bone Joint Surg Br* (1991) 73: 709–714.
- Wasiliewski RC, Galante JO, Leighty RM, Natarajan RN and Rosenberg AG: Wear patterns on retrieved polyethylene tibial inserts and their relationship to technical considerations during total knee arthroplasty. *Clin Orthop Relat Res* (1994) 299: 31–43.
- Ritter MA, Faris PM, Keating EM and Meding JB: Postoperative alignment of total knee replacement. Its effect on survival. *Clin Orthop Relat Res* (1994) 299: 153–156.
- Pitto RP, Graydon AJ, Bradley L, Malak SF, Walker CG and Anderson IA: Accuracy of a computer-assisted navigation system for total knee replacement. *J Bone Joint Surg Br* (2006) 88: 601–605.
- Chauhan SK, Scott RG, Bredahl W and Beaver RJ: Computer-assisted knee arthroplasty versus a conventional jig-based technique. A randomized, prospective trial. *J Bone Joint Surg Br* (2004) 86: 372–377.
- Bäthis H, Perlick L, Tingart M, Lüring C, Perlick C and Grifka J: Radiological results of image-based and non-image-based computer-assisted total knee arthroplasty. *Int Orthop* (2004) 28: 87–90.
- Anderson KC, Buehler KC and Markel DC: Computer assisted navigation in total knee arthroplasty: comparison with conventional methods. *J Arthroplasty* (2005) 20: 132–138.
- Carter RE 3rd, Rush PF, Smid JA and Smith WL: Experience with computer-assisted navigation for total knee arthroplasty in a community setting. *J Arthroplasty* (2008) 23: 707–713.
- Nabeyama R, Matsuda S, Miura H, Mawatari T, Kawano T and Iwamoto Y: The accuracy of image-guided knee replacement based on computed tomography. *J Bone Joint Surg Br* (2004) 86: 366–371.
- Stulberg SD, Yaffe MA and Koo SS: Computer-assisted surgery versus manual total knee arthroplasty: a case-controlled study. *J Bone Joint Surg Am* (2006) 88: 47–54.
- Blakeney WG, Khan RJK and Wall SJ: Computer-assisted techniques versus conventional guides for component alignment in total knee arthroplasty: a randomized controlled trial. *J Bone Joint Surg Am* (2011) 93: 1377–1384.
- Seon JK and Song EK: Navigation-assisted less invasive total knee arthroplasty compared with conventional total knee arthroplasty: a randomized prospective trial. *J Arthroplasty* (2006) 21: 777–782.
- Romanowski MR and Repicci JA: Minimally invasive unicondylar arthroplasty: eight-year follow-up. *J Knee Surg* (2002) 15: 17–22.
- Chauhan SK, Clark GW, Lloyd S, Scott RG, Bredahl W and Sikorski JM: Computer-assisted total knee replacement. A controlled cadaver study using a multi-parameter quantitative CT assessment of alignment (the Perth CT protocol). *J Bone Joint Surg Br* (2004) 86: 818–823.
- Bonutti PM, Dethmers DA, McGrath MS, Ulrich SD and Mont MA: Navigation did not improve the precision of minimally invasive knee arthroplasty. *Clin Orthop Relat Res* (2008) 466: 2730–2735.
- Abe N, Fujiwara K, Yoshitaka T, Nasu Y, Date H, Sakoma Y and Ozaki T: The accuracy of registration with CT-based navigation system (1.6) and its application for minimally invasive total knee arthroplasty. *The knee* (2007) 31: 267–270 (in Japanese).
- Martin A and von Stempel A: Two-year outcomes of computed tomography-based and computed tomography free navigation for total knee arthroplasties. *Clin Orthop Relat Res* (2006) 449: 275–282.
- Akagi M, Yamashita E, Nakagawa T, Asano T and Nakamura T: Relationship between frontal knee alignment and reference axes in the distal femur. *Clin Orthop Relat Res* (2001) 388: 147–156.
- Aglietti P, Sensi L, Cuomo P and Ciardullo A: Rotational position of femoral and tibial components in TKA using the femoral transepicondylar axis. *Clin Orthop Relat Res* (2008) 466: 2751–2755.
- Victor J: Rotational alignment of the distal femur: a literature review. *Orthop Traumatol Surg Res* (2009) 95: 365–372.
- Yau WP, Leung A, Chiu KY, Tang WM and Ng TP: Intraobserver errors in obtaining visually selected anatomic landmarks during registration process in nonimage-based navigation-assisted total knee arthroplasty: a cadaveric experiment. *J Arthroplasty* (2005) 20: 591–601.
- Brin YS, Livshetz I, Antoniou J, Greenberg-Dotan S and Zukor DJ: Precise landmarking in computer assisted total knee arthroplasty is critical to final alignment. *J Orthop Res* (2010) 28: 1355–1359.
- Takasaki M, Matsuda S, Fukagawa S, Mitsuyasu H, Miura H and Iwamoto Y: Accuracy of image-free navigation for severely deformed knees. *Knee Surg Sports Traumatol Arthrosc* (2010) 18: 763–768.
- Minoda Y, Kobayashi A, Iwaki H, Mitsuhiko I, Kadoya Y, Ohashi H, Takaoka K and Nakamura H: The risk of notching the anterior femoral cortex with the use of navigation systems in total knee arthroplasty. *Knee Surg Sports Traumatol Arthrosc* (2010) 18: 718–722.
- Bonner TJ, Eardley WGP, Patterson P and Gregg PJ: The effect of post-operative mechanical axis alignment on the survival of primary total knee replacements after a follow-up of 15 years. *J Bone Joint Surg Br* (2011) 93: 1217–1222.
- Lewis P, Rorabeck CH, Bourne RB and Devane P: Posteromedial tibial polyethylene failure in total knee replacements. *Clin Orthop Relat Res* (1994) 299: 11–17.