

Cosmetic dentistry in ancient times: V-shaped dental mutilation in skeletal remains from Corycus, Turkey

• Huseyin Afsin (1), Ahmet Sadi Cagdir (1), Yalçın Büyük (1), Beytullah Karaday (2) •

1- State Institute of Forensic Medicine, Istanbul, Turkey

2- University of Istanbul, Cerrahpaşa School of Medicine, Department of Forensic Medicine, Istanbul, Turkey

Address for correspondence:

Dr. Beytullah Karadayi,
Department of Forensic Medicine,
Istanbul University,
Cerrahpasa Faculty of Medicine,
34303, Istanbul, Turkey.
Tel: +90 212 414 30 00
E-mail: bkaradayi1970@yahoo.com

Bull Int Assoc Paleodont. 2013;7(2):148-156.

Abstract

Dental mutilation can provide clues about the migration of human populations in the world and provide valuable information about the socio-economic and socio-cultural structure of those populations. The aim of this study is to gain knowledge and contribute to literature about the habits, physical appearance and migratory routes of ancient people from the data findings on their skeletal remains found in an ancient castle (Maiden's Castle) located in the south of Turkey. Dental findings from skeletal remains found during the archeological excavation of Corycus in Turkey were investigated. V-shaped dental mutilations were identified in two upper incisor from a single individual and the results were evaluated according to Romero's classification. The dental mutilation discoveries identified in this study will contribute to the literature regarding the migratory routes and cultural interactions of the people who lived there in the past.

Keywords: Dental Mutilation; Prehistoric Dentistry; Cosmetic Dentistry; Incisor Anterior Teeth

Introduction

Teeth can provide insight into both the health and the behavioral practices of a culture (1). It has been noted that teeth have been utilized for purposes other than that of the usual mastication of food. For instance, teeth have been used as tools to hold pins, pipe sinew, etc. With this information, dental anthropologists can interpret general and specific cultural behaviors, which aid in the reconstruction of past lifestyles (2, 3). It is also possible for anthropologists to determine the approximate age of death of an individual, due to the extent of wear in teeth (4).

Dental mutilation is one of the most popular topics amongst anthropologists and such cases can be found in a variety of cultures and geographic locations (2, 5). Over the course of history, people have mutilated their heads, noses, ears, necks, tooth, lips or feet for a variety of reasons. These type of ethnical behaviors can be described as barbarian, primitive behaviors, but they can be seen both in developed societies and in primitive societies (6). Such ancient applications became fashion and spread into wide geographic locations (7).

Existence of some form of cosmetic dentistry in ancient times has been proven by paleodontological research. Dental procedures such as dental decoration, dental mutilation and modifications on anterior teeth have been encountered in many cultures. These kinds of modifications found in archaeological specimens contributed much to our understanding of ancient nations and also human behavior in the past (6, 8).

Different types of dental mutilation and intentional dental modifications have been found in some of the earliest civilizations in China, India, Southeast Asia, Africa and America (8 -14). These kinds of dental modifications are best documented in the people species of pre-Columbian America (8, 15). In Europe, has only been found in Viking communities (16).

The aim of this study is to gain knowledge and contribute to literature about the habits, physical appearances and migratory routes of the ancient people from the findings on their skeletal remains found in an ancient castle (Maiden's Castle) located in the south of Turkey.

Materials and Methods

Turkey has been the center for many civilizations dating back to the Neolithic era when agriculture and animal husbandry started for the first time in the world. Kız Kalesi (Maiden's Castle) is located on a tiny island 200 meters offshore and about 60 km from the Mediterranean city of Mersin (Figure 1). It was built in the 12th century A.D. to watch over the ancient Byzantine post of Corycus. The castle walls stretched about 900 meters. The legend of the region states that a king in Mersin wished very much to have a daughter. His wish came true and he had a daughter known for her

beauty and kindness. One day a fortune teller predicted that the princess would be bitten by a poisonous snake. King, loving her daughter very much, ordered the building of a castle. Yet a snake still crawled in a basket of fruit to enter the castle and bit the princess to death.

The materials used in this study were retrieved by a group of archaeologists led by F. Güler Gürkan who is affiliated with the Tourism and Culture Ministry of Turkey. These skeletal remains were found by this group at the excavation site in 2001 (17). Due to the possibility that some of the remains were recent, excavations were halted, and the findings were reported to our unit (Forensic Identification Department of the National Institute of Forensic Medicine). While the excavations were suspended, our group of forensic experts and forensic dentists conducted an investigation. The remains were brought to the State Institute of Forensic Medicine in Istanbul on October the 23rd, 2001. In the following process, 7 skeletons retrieved from the excavations were sent to the Paleoanthropology Laboratory in Ankara University Faculty of Languages, History and Geography's Department of Anthropology for the paleoanthropological investigation in 2004.

It was noted that all individual skeletons had been mixed together during excavation and shipping to the Institute. A minimum number of individuals (MNI) was calculated using the upper and lower jaws. Dental and cranial findings of the skeletal remains found in the archeological excavation in Mersin Kız Kalesi (Maiden's Castle)-Corycus were investigated, and the results evaluated in the Forensic Odontology Department of the National Institute of Forensic Medicine.

Dental mutilation was classified according to Romero's classification system. To visualize the possible appearance of the faces of individuals, three dimensional facial reconstructions were made on two of the skulls by Dr. Çağdır (Figure 2 a,b).

Results

After the analyses were conducted on the skeletal remains, it was found out that the remains belonged to a total of 17 people from different age groups of Caucasian origin. Anthropological examination indicated that remains were buried with hands crossed over the chest and not in any particular alignment direction. They were highly fragmented. There was no evidence of fresh wounds (peri-mortem injuries). There was no severe infectious disease. Healed ante-mortem trauma was present in 3 skulls including several deep cuts and a puncture wound probably caused by a fight or battle (Figure 3).

Dental health was good with few teeth lost ante-mortem but with heavy attrition. Forensic examination of archaeological remains provides a different perspective about health, disease and body morphology. In addition, cause and manner of death can better be understood when these remains are examined with a forensic science approach. The residents of the fortress seemed to

be the defenders of their community. Many of them suffered from cranial trauma but were in good health without any bone infection.

V-shaped dental mutilations were identified in two upper incisor anterior teeth (Figure 4 a,b,c). These lesions were not due to disease or unsuitable environmental conditions, they were deliberately caused due to cultural customs (V-shaped dental mutilation matching Romero Dental classification A1). When all of the teeth were examined, it was noted that there were no dental caries, but the degree of dental attrition was higher than others in the same age group.

Discussion

Archaeological information is very important for determining which era the skeletal remains belonged to. It was later claimed that the skeletal remains might belong to the Roman-Byzantium era upon the findings of graveyard artifacts, ceramic pieces, beads, and the identified ways of burial by anthropologist Erol and her colleagues on the excavation site, and upon the studies on the 7 skeletons found in the process (18). In addition, the discovery of a Saint Teresa necklace indicated that the remains could date back to around 12th century A.D of the Byzantium era.

Dental mutilation, also known as intentional dental modification, is an interesting cultural practice that enjoyed a long and diverse history in many populations. There are many explanations for groups to artificially alter the morphology of their teeth. For instance, some researchers believe that dental modifications are indicative of beautification (15,19), ethnic markers or tribal identification (20), and social status (21).

Mexican anthropologist Romero examined a collection of 1212 modified teeth located in a national museum in Mexico. A classification system was developed for artificially modified teeth. Romero grouped them into seven basic types (A through G), and came up with a total of 59 types or variants based upon whether there were inlays or filings, and what kind of modifications were noted on the edges, and/or the angles of the teeth (15) (Figure 5). Romero believed that tooth filing among the Mayans came into practice in the pre-classical period (1400-600 B.C.) (15). According to Olivares, Romero noted that in the pre-classical period, Mayan dental mutilation was mainly limited to upper incisors representing Type A on his classification system (22). As time went on, especially during the classical period, a high level of skill became apparent with the diversity of type G forms, which appear on the central upper incisors. In our study, V-shaped mutilation was found on the central upper incisors.

Dental mutilations give some clues about the migration of the human populations in the world, and provide valuable information about the socio-economic and socio-cultural structure of a certain population. While some studies claim that dental mutilations are a marker of elite status (15, 23,

24), some of the studies present little or no evidence for a relationship between socio-economic status and dental modification. (21, 25, 26). In our study, the individual with the V-shaped dental modifications had good health and we think that these people had a high social position.

20,000 years ago, in a time known as the Ice Age, the human populations had to migrate from Middle-Asia to North America (Alaska) through Bering strait. So, the same cultural attributes can be seen between Middle-Asian and American Indian cultures (19, 27). Since there are no reports of such dental mutilations in historical skeletal remains from the excavations carried out in Turkey, it is hard to say that the dental mutilation discoveries which were found at Corycus are a sign of cultural interaction between different communities. First of all, by extending the archaeological research of the area, it could become apparent whether these dental mutilations are common among the people who lived in that castle or not. On the other hand, the fact that those people had interactions with other coastal cities, cultures and marauding pirates should not be ignored.

Havill et al. stated that dental mutilation is usually limited to the anterior maxillary dentition (22). Since dental modification is noted in the most visible part of the teeth, it is believed that the purpose of dental modification in Mesoamerica was for ornamentation purposes, although others have speculated that dental mutilations may have been part of some kind of rite of initiation or rite of passage. Some authors (21, 22, 28) reported that artificial dental modification can take several forms including sharpening, cutting, inlaying, ablation, filing or a combination of these. As with other body ornamentation, it is very possible that dental modification has significance beyond aesthetics. However, it is generally agreed that these techniques were not restorative, but instead purely decorative or perhaps ritually significant (20, 21). Some researchers reported that in the pre-historic times, some kind of anesthetic plants were used in the process of mutilation, and in order to avoid infections afterwards, some healing plants were also used. (29-31). The fact that there were no resorption found on the apex areas, and on maxilla from the studies conducted on V-shaped dental mutilated teeth, gave rise to thought that the craftsmen who applied those mutilations were very informed, skilled and experienced.

Dental mutilation is a very widespread practice which is associated with certain cultures, beliefs and aesthetic ideals. Even though there have been numerous excavations carried out in Turkey before, no symptoms of dental mutilations suitable to Romero's classification have been reported. Dental mutilations identified in this study, will provide a valuable contribution to the other studies researching the migratory routes and cultural interactions on these areas.

References

1. Mata AC. Dental treatments in pre-hispanic Mesoamerica. San Francisco: The Pre-Columbian Art Research Institute, 1994; Vol. 9.
2. Alt K, Pichler S. Artificial modifications of human teeth in dental anthropology fundamentals, limits and prospects. Alt K, Rosing F, Teschler-Nicola M, editors. New York: SpringerWien, 1998.
3. Anton SC. Intentional cranial vault deformation and induced changes of the cranial base and face. *American Journal of Physical Anthropology* 1988; 79:253-267.
4. Benedix D. A biocultural analysis of intentional dental-modifications [thesis]. Knoxville, (TN): University of Tennessee, 1998.
5. Milner GR, Larsen. (1991). Teeth as artifacts of human behavior: Intentional mutilation and accidental modification. In MA Kelley, CS Larsen, eds: *Advances in Dental Anthropology*. New York:Wiley-Liss 1991.
6. Yasar ZF, Erol AS. Dental Mutilations. *Mehmet Akif Ersoy Üniversitesi Sosyal Bilimler Enstitüsü Dergisi* 2011; 3(4): 33-37.
7. Özbek M. *Dünden Bugüne İnsan*. Ankara: Pelin Ofset 2000.
8. Vukovic A, Bajzman A, Zukic S, Secic S. Cosmetic dentistry in ancient times – a short review. *Bull Int Assoc Paleodont* 2009; 3 (2):9-13.
9. Lukacs JR, Pastor RF. Activity-induced patterns of dental abrasion in prehistoric Pakistan:evidence from Mehrgarh and Harappa. *American Journal of Physical Anthropology* 1988;76: 377–98.
10. Larsen CS. Dental modifications and tool use in the Western Great Basin. *American Journal of Physical Anthropology* 1985;67:393–402.
11. White TD, De Gusta D, Richards GD, Baker SG. Prehistoric dentistry in the American southwest: A drilled canine from Sky Aerie, Colorado. *American Journal of Physical Anthropology* 1997; 103(3):409-414.
12. Reichart PA, Creutz U, Scheifele C. Dental mutilations and associated alveolar bone pathology in African skulls of the anthropological skull collection, Charité, Berlin. *Journal of Oral Pathology & Medicine* 2008;37(1) 50-55.
13. Finucane BC, Manning K, Touré M. Prehistoric dental modification in West Africa - early evidence from Karkarichinkat Nord, Mali. *International Journal of Osteoarcheology* 2008; 18 (6): 632-640.
14. Haour A, Pearson JA. An instance of dental modification on a human skeleton from Niger, West Africa. *Oxford J. Archaeol.* 2005; 24: 427-433.
15. Romero J. Dental mutilation, trephination, and cranial deformation. In: Wauchope R, Stewart TD, editors. *Handbook of Middle American Indians*. Austin: University of Texas Press, 1970; 50-67.
16. Arcini C. The Vikings bare their filed teeth. *American Journal of Physical Anthropology* 2005;128(4): 727-733.
17. Sevim A, Günay I, Satar Z. Mersin Kız Kalesi iskeletlerinin paleoantropolojik açıdan incelenmesi. 20.Arkeometri sonuçları toplantısı. T.C. Kültür ve Turizm Bakanlığı Yayınları 2004. Yayın no: 3032 20. pp.67-76.
18. Gürkan FG, Ünlü Y. "2001 yılı kız kalesi temizlik kazısı", 13. muze çalışmaları ve kurtarma kazıları sempozyumu. 2002. pp.69-85, Denizli.
19. Fastlicht S. *Tooth mutilations and dentistry in Pre-Columbian Mexico*. Chicago: Quintessence Books 1976.
20. Gill GW. Cultural implications of artificially modified human remains from Northwestern Mexico. In: Foster MS, Weigand PC, editors. *The archaeology of West and Northwest Mesoamerica*. Boulder: Westview Pres, 1985.
21. Havill LM, Warren DM, Jacobi KP, Gettleman KD, Cook DC, Pyburn KA. Late postclassic tooth filing at Chau Hiix and Tipu, Belize. In *Bones of the Maya: Studies-of-ancient skeletons*. Whittington SL, Reeds DM, editors. Washington: Smithsonian Institution Press 1997.
22. Olivares NM. Dental alterations from Peten, Guatemala, in *Bones-of the Maya: Studies of ancient skeletons*. Whittington, SL, Reed DM, editors. Washington: Smithsonian Institution Pres, 1997.
23. Becker, Marshall J. Archaeological Evidence for Occupational Specialization among the Classic Period Maya at Tikal, Guatemala. *American Antiquity* 1973;38:396– 406.
24. Smith, A. Ledyard. Dental Decoration. In *Excavations at Altar de Sacrificios: Architecture, Settlement, Burials and Caches*, edited by A. Ledyard Smith, pp. 222–229. *Papers of the Peabody Museum of Archaeology and Ethnology* Vol. 62 No. 2. Harvard University, Cambridge, MA 1972.
25. Saul JM., and Saul PM. The Preclassic Skeletons from Cuello. In *Bones of the Maya: Studies of Ancient Skeletons*, edited by Stephen L. Whittington and David M. Reed, pp. 28–50. Smithsonian Institution Press, Washington, DC 1997.
26. Massey VK. and Steele DG. A Maya Skull Pit from the Terminal Classic Period, Colha, Belize. In *Bones of the Maya*, edited by Stephen L. Whittington and David M. Reed, Smithsonian Press, Washington, DC 1997.
27. Ozdogan M. Neolitik çag: devrimlerin atasi. *Arkeo-Atlas* 2002;1:64-88.
28. Hillson S. *Dental anthropology*. New York: Cambridge University Press, 1996.
29. Bussmann RW, Sharon D. Traditional medicinal plant use in Northern Peru: tracking two thousand years of healing

culture. *Journal of Ethnobiology and Ethnomedicine* 2006; 2:43-47.

30. Halberstein RA. Applications of medicinal plants in dentistry. *Eur J Gen Dent* 2012;1:123-4.

31. Halberstein RA. Medicinal plants: historical and cross-cultural usage patterns. *Annals of Epidemiology* 2005;15:686–99.

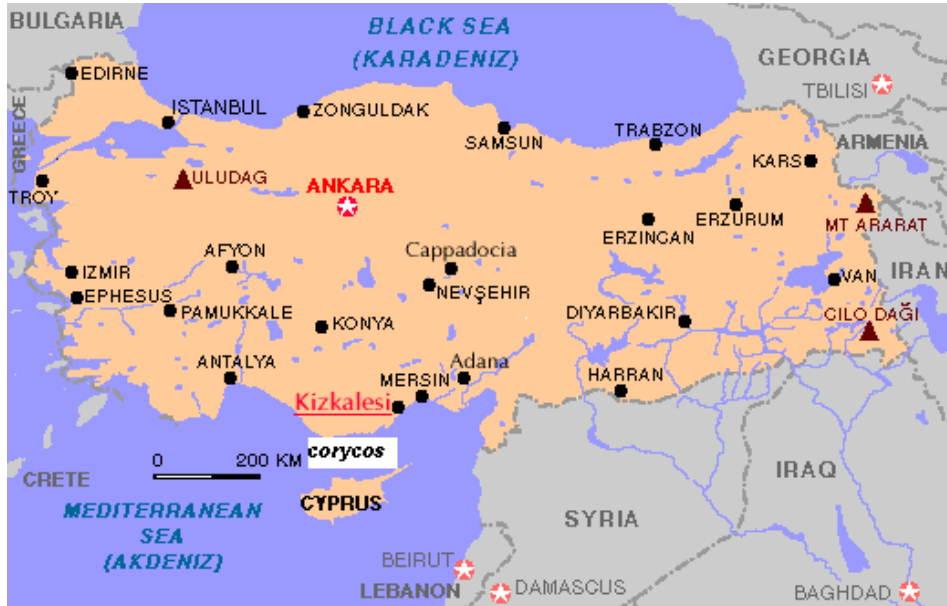

Figure 1. The location of Corycus (Kiz Kalesi-Maiden's Castle).




Figure 2 (a,b). Facial reconstruction studies on the skulls found at Corycus.

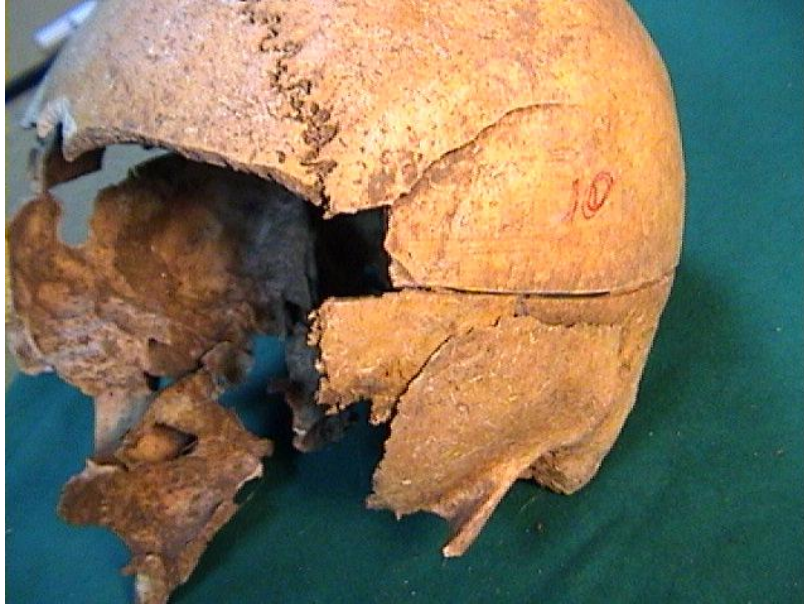

Figure 3. Deep cuts and puncture on a skull found at Corycus.

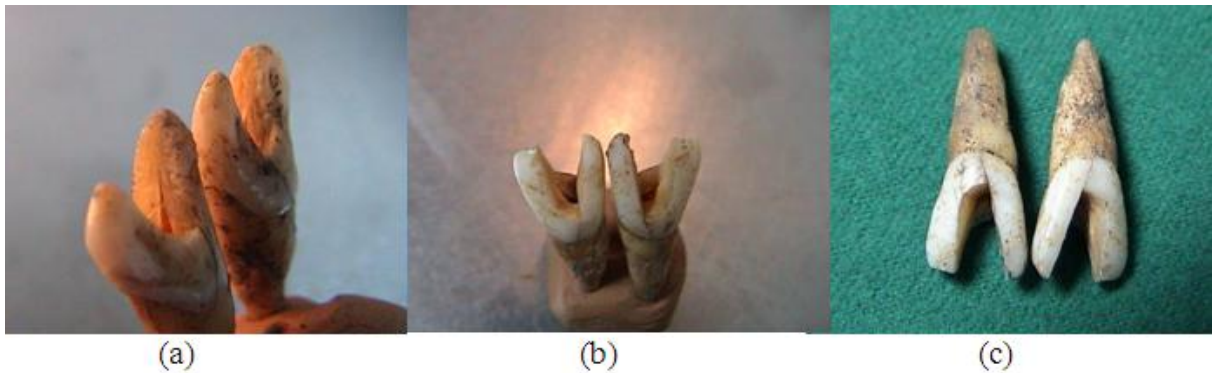

Figure 4 (a,b,c). V-shaped dental mutilations in the upper two incisor anterior teeth.




Figure 5. Romero's system of classification for teeth with dental modification (15).