

Case Report

Unusual Formation and Sub-Omohyoid Course of External Jugular Vein

Sirasanagandla SR¹, Narendra P² (✉), Satheesha NB¹, Somayaji SN¹, Kumar MR Bhat³, Surekha DS¹, Jyothisna P¹

¹Department of Anatomy, Melaka Manipal Medical College (Manipal Campus), Manipal University, Manipal, Karnataka, India.

²Faculty in Anatomy, School of Medicine and Health Sciences, Monash University, Sunway Campus, 46150 Kuala Lumpur, Malaysia

³Department of Anatomy, Kasturba Medical College, Manipal University, Manipal, Karnataka, India.

Abstract

Variations in the origin and termination of external jugular vein are common and are reported in the past. However, variations in the course of external jugular vein are uncommon. During routine dissection classes for medical undergraduates, we came across the unusual formation and course of right external jugular vein and absence of common facial vein, in an approximately 60-year-old male cadaver of Indian origin. External jugular vein was formed by the continuation of undivided trunk of retromandibular vein. Following its formation, it passed vertically superficial to sternocleidomastoid muscle to the lower part of occipital triangle. In the occipital triangle it pierced the investing layer of deep cervical fascia and passed deep to the inferior belly of omohyoid muscle and coursed through the subclavian triangle. Then, it terminated at the junction of subclavian vein with internal jugular vein. Facial vein joined with submental vein and finally drained into internal jugular vein. Further, the posterior auricular vein and anterior jugular veins were absent. Knowledge about the variations of the retromandibular vein, common facial vein and external jugular vein observed in this study, may be important for the surgeons, to prevent inadvertent injury and excessive bleeding during diagnostic and therapeutic procedures.

Keywords: Cadaver, sternocleidomastoid muscle, bleeding, termination, injury.

Correspondence:

Dr. Narendra Pamidi, Faculty in Anatomy, Jeffrey Cheah School of Medicine & Health Sciences, Monash University, Sunway Campus, 46150 Kuala Lumpur, Malaysia. Tel: +603 355144412 Fax: +603 355146001 Email: narendra.pamidi@gmail.com

Date of submission: 04 Apr, 2013

Date of acceptance: 23 May, 2013

Introduction

Retromandibular vein (RMV) and external jugular vein (EJV) drain the major portion of the venous blood from the face and scalp. RMV is formed within the substance of the parotid gland, by the union of superficial temporal vein and the maxillary vein. At the apex of parotid gland, RMV divides into anterior and posterior divisions. The common facial vein (CFV) is formed by the union of anterior division of RMV and the facial vein. The CFV finally drains into internal jugular vein. EJV is formed by the joining of the posterior division of the RMV with posterior auricular vein. It descends vertically in the superficial

fascia from the angle of the mandible, superficial to sternocleidomastoid muscle, to the root of the neck (1). Here, just above the midpoint of clavicle, it pierces the deep fascia in the subclavian triangle and opens into subclavian vein. Tributaries of EJV include posterior external jugular, anterior jugular, occipital and transverse cervical veins.

The superficial veins of the head and neck are frequently used for intravenous cannulation and for the injection of intravenous fluids and medicines. They are also used to obtain blood samples. The segments of the superficial veins of the head and neck are used in surgical procedure such as carotid endarterectomy

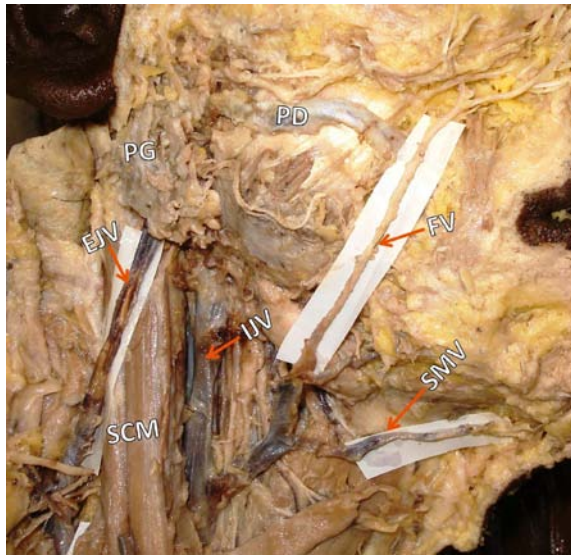

Figure 1: Superficial dissection of the right side head and neck. Superficial dissection of the right side neck showing the external jugular vein (EJV), which is a continuation of the undivided retromandibular vein (not seen in the figure). Facial vein (FV) in the submandibular region joined with submental vein (SMV) and finally terminated in internal jugular vein (IJV). (SCM: sternocleidomastoid muscle; PG: parotid gland; PD: parotid duct).

(CEA) to prevent stroke. Having the detailed knowledge of anatomical variations of the veins of head and neck may be useful in performing these surgical procedures (2).

Case Report

During routine dissection classes for the undergraduate medical students, in an approximately 60-year-old male cadaver of Indian origin, we observed following venous variations on the right side of the head and neck region. RMV was formed by the joining of superficial temporal vein with the maxillary vein within the substance of parotid gland and it did not divide into two divisions. Its undivided trunk continued as EJV (Fig. 1). EJV ran vertically superficial to sternocleidomastoid muscle till the lower part of the roof of the occipital triangle where, it pierced the investing layer of deep cervical fascia. Here, it passed deep to the inferior belly of omohyoid and coursed through the subclavian triangle and finally terminated at the junction of the right subclavian vein with internal jugular vein (Fig. 2). The facial vein presented a normal course in the face lying posterior to the facial artery and in the submandibular region it joined with the submental vein and finally drained into internal jugular vein. Posterior auricular vein and anterior jugular veins were absent. Further, transverse cervical vein and suprascapular vein formed a

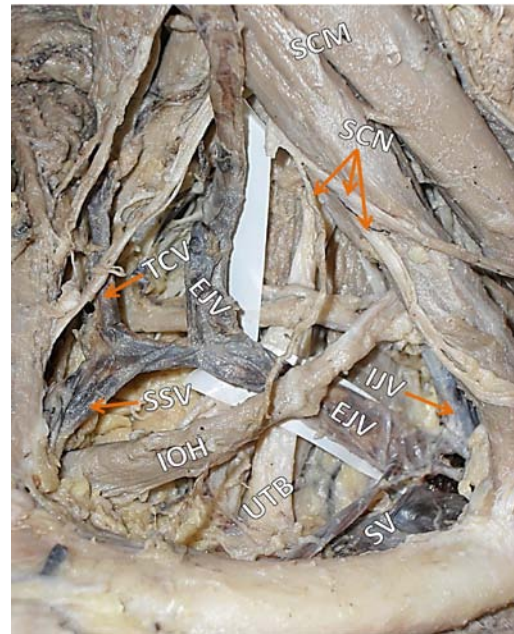


Figure 2: Superficial dissection of the right side neck. Superficial dissection of the right side neck showing the closer view of unusual course of external jugular vein (EJV) passing deep to the inferior belly of omohyoid muscle (IOH) and draining into the junction of subclavian vein (SV) with internal jugular vein (IJV). Note transverse cervical vein (TCV) and suprascapular vein (SSV) forming the common trunk draining into the EJV. (SCM: sternocleidomastoid muscle; UTB: upper trunk of brachial plexus; SCN: supraclavicular nerves).

common trunk before draining into the external jugular vein. The observed venous variations were unilateral.

Discussion

Variations in the venous drainage pattern of the face and neck are relatively common and have been reported by various researchers. The abnormal development of the vascular system may result in formation of clinically important anomalies (3). Earlier, studies have reported the cases of undivided RMV, absence of posterior auricular vein and CFV (4,5,6). In a report by Devi and Sharmila, the formation of CFV and the termination of RMV into anterior and posterior divisions was completely absent as observed in our case (7). In a report by Yadav et al., the EJV crossed sternocleidomastoid muscle superficially and terminated in the IJV above the level of superior belly of omohyoid muscle (8). Though EJV frequently shows variations in its formation, the subomohyoid course of EJV reported in the present case is seldom reported in the literature. The unusual course of EJV, deep to the inferior belly of omohyoid is clinically important as there may be a chance of

compression of EJV by omohyoid muscle against the upper trunk of brachial plexus.

The superficial veins of the head and neck are commonly used for central venous pressure monitoring the cannulation, for intravenous infusion and for the venegraft harvesting in carotid endarterectomies (2). Because of its accessibility at the carotid exposure site, the segments of the CFV have been used as a patch material in procedures such as carotid angioplasty (9). CFV also has been used in ventriculojugular shunts in the treatment of hydrocephalus and for passing the central venous catheter for monitoring the hyperalimentation and venous pressure (10). The RMV vein is ligated during some of the head and neck surgeries to avoid unnecessary bleeding. During surgical procedures such as superficial parotidectomy and correction of mandibular condylar fractures, RMV has also been used as a key structure to identify the branches of the facial nerve (3). Unintentional injury of RMV or CFV can lead to profuse bleeding leading to heavy blood loss in surgeries of temporomandibular joint, posterior ramus of mandible, parotid gland and upper part of neck. Because of its superficial location, the EJV has been commonly used for trans-jugular liver biopsy and for the reconstruction of femoral artery to avoid a deep neck exposure and to reduce the risk in patients with impaired coagulation (11). In the current case, the EJV passed deep to the inferior belly of omohyoid before its termination. The vein might get compressed against the upper trunk of brachial plexus, if the omohyoid muscle gets hypertrophied. This may result in engorgement of the vein in the neck. This abnormal course might make the invasive radiological procedures difficult. The temporary engorgement of EJV is seen in some individuals while talking and singing. We cannot rule out the possibility of EJV passing deep to the inferior belly of omohyoid in them. Knowledge about variations in the venous pattern of head and neck may be important for the surgeons, to prevent inadvertent injury and excessive bleeding during diagnostic and therapeutic procedures.

Conclusion

Knowledge of variations of the RMV, CFV and EJV observed in this study may be very useful radiologists and vascular surgeons in performing angiographic and sonographic studies with greater rate of success. A thorough knowledge of the normal anatomy and variances of facial and neck veins could be useful from the surgical point of view, hence these variations have been considered to be of immense significance.

References

1. Standing S, Harold E, Jeremiah CH et al. In Neck. Gray's anatomy. 39th Ed. London: Elsevier, Churchill Livingstone, 2005, pp-512, 551.
2. Bertha A, Suganthy R. Anatomical variations in termination of common facial vein. J Clin Diagn Res 2011; 5(1): 24-27.
3. Choudhary S, Sharma AK, Singh H. Undivided retromandibular vein continuing as external jugular vein with facial vein draining into it: an anatomical variation. JK Science 2010; 12(4): 203-204.
4. Nayak SB, Soumya KV. Abnormal formation and communication of external jugular vein. IJAV 2008; 1:15-18.
5. Peuker ET, Fischer G, Filler TJ. Facial vein terminating in the superficial temporal vein: a case report. J Anat 2001; 198(4):509-510.
6. Gonzalez-Garcia R, Roman-Romero L, de la Plata MM. The rare phenomenon of internal jugular vein duplication. Otolaryngol Head Neck Surg 2007; 137(5): 847-848.
7. Devi SK, Sharmila BP. Variant anatomy of fenestrated internal jugular vein with unusual retromandibular and facial veins. IJAV 2011; 4: 144-146.
8. Yadav S, Ghosh SK, Anand C. Variations of superficial veins of head and neck. J Anat Soc India 2000; 49(1): 61-62.
9. Abeysekera AM, Siriwardana HP, Prabaharan B, Tiwari A, Madipolagedara N, Jacob S. Common facial vein: an alternative patch material in carotid angioplasty. ANZ J Surg 2008; 78(3): 185-188.
10. Zumbro GL Jr, Mullin MJ, Nelson TG. Central venous catheter placement utilizing common facial vein. A technic useful in hyperalimentation and venous pressure monitoring. Am J Surg 1973; 125(5): 654-656.
11. Siegel EL, Caresio J, Eckard DA. Use of the external jugular vein approach for transvenous liver biopsy. J Vasc Interv Radiol 1992; 3(2): 371-374.