

*Case Report***Stable improvement of renal function after initiation of highly active anti-retroviral therapy in patients with HIV-1-associated nephropathy**Michiel G. H. Betjes¹ and Dominique W. M. Verhagen²

¹Academic Hospital Rotterdam, Dijkzigt, Department of Internal Medicine, Division of Nephrology, Rotterdam, The Netherlands and ²Department of Infectious Diseases, Tropical Medicine and AIDS, F4-222, Academic Medical Centre, Amsterdam, The Netherlands

Keywords: ACE-inhibition; anti-retroviral therapy; glomerulosclerosis; HIV-1; nephropathy; proteinuria

Introduction

Infection with human immunodeficiency virus type 1 (HIV-1) is associated with a variety of well-known renal diseases like IgA nephropathy, membranous nephropathy, and haemolytic uraemic syndrome [1]. HIV-associated nephropathy (HIVAN) is now being recognized as a distinct clinico-pathological entity that presents with proteinuria in the nephrotic range and impairment of renal function [1]. Untreated, HIVAN carries a poor prognosis and invariably leads to end-stage renal failure within months. The most striking finding on renal biopsy is collapsing focal glomerulosclerosis, but all renal compartments are essentially affected [1]. HIVAN is predominantly seen in black patients and has become a major cause for end-stage renal disease (ESRD) in this patient group. Treatment of HIVAN has included the use of steroids, ACE-inhibition and anti-retroviral drugs but the optimal treatment is not known [1]. Corticosteroids and ACE-inhibition probably slow down the progression to ESRD especially in cases with mild to moderate renal impairment. An animal model of mice transgenic for an HIV-1 gene construct suggested a direct pathogenic effect of HIV on renal cells [2]. Aggressive reduction of the viral load by a combination of anti-retroviral drugs, also known as highly active anti-retroviral therapy (HAART), is now considered standard therapy for HIV-1 infection. Anecdotal data suggest that marked improvement of renal function may occur after starting HAART [3]. Preliminary reports showed

a better renal survival for patients with HIVAN treated with HAART [4,5]. Prospective randomized clinical trials comparing different treatment regimes for HIVAN have not been performed. Based on present data, HAART combined with ACE-inhibition may be the optimal treatment for HIVAN. In this report we describe three patients with HIVAN, who presented with rapidly progressive renal insufficiency and were not treated previously for their HIV-1 infection. Marked and prolonged improvement of renal function was established after starting HAART and ACE-inhibition.

Case 1

A 30-year-old black female patient was admitted with a 1-week history of general malaise, increase in weight, and peripheral oedema. Her weight was 72.7 kg and her blood pressure was 120/60 mmHg. There were signs of oedema periorbitally and at the lower legs. Multiple ulcers were present on the buttocks.

Laboratory tests showed a plasma creatinine of 9.17 mg/dl, urea 84.0 mg/dl, and albumin 17 g/l. Two months before the plasma creatinine concentration was 0.84 mg/dl. The urinary sediment revealed four to 10 erythrocytes and four to 10 leukocytes per high power field and urinary protein was 16 g/day. Ultrasound examination showed normal sized kidneys measuring 11 cm with increased echogenicity of the cortex.

HIV-1 antibodies were present and the viral load was 210 000 copies/ml. The CD4-positive lymphocyte count was 30/mm³. Tests for collagen diseases, vasculitis, or hepatitis were all negative. Smear cultures from the skin ulcers were positive for herpes simplex virus. A renal biopsy was performed. Microscopic examination revealed 20 glomeruli, all showing a varying degree of collapse of the capillaries with areas of proliferation of visceral podocytes. In the mesangium there was a slight proliferation of mesangial cells and minimal fibrosis. The tubuli were

Correspondence and offprint requests to: Michiel G. H. Betjes, MD, PhD, Academic Hospital Rotterdam, Dijkzigt, Department of Internal Medicine, Division of Nephrology, Dr Molewater plein 40, NL-3015 GD Rotterdam, The Netherlands.
Email: betjes@inw1.azr.nl

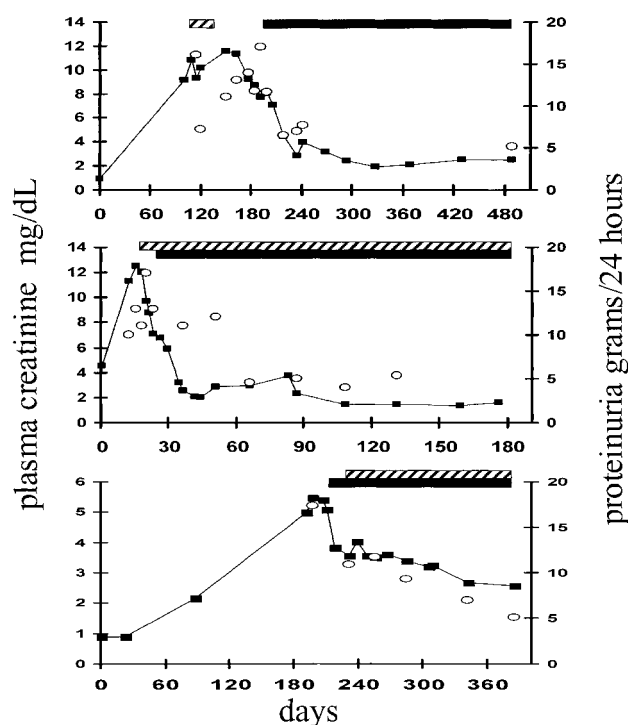


Fig. 1. Plasma creatinine concentrations (■) and proteinuria (○) in time (days) of patients described in Case 1 (top), Case 2 (middle), and Case 3 (bottom). The black bars indicate the period of treatment with HAART and the dashed bars the period of treatment with ACE-inhibition.

atrophic with cystic dilatation. In the interstitium some oedema and fibrosis was present with minimal infiltration of mononuclear cells. A diagnosis of HIVAN was made but the patient did not accept the diagnosis of HIV infection and, therefore, refused to take anti-retroviral medication the first 3 months of her admission. In these months she was treated with diuretics and a brief period of ACE-inhibition. Two months after starting HAART, containing lamivudine, stavudine, and nevirapin, the viral load had declined to 1200 copies/ml and the CD4 cell count increased to 280/mm³. This was accompanied by a rapid and stable improvement of renal function (Figure 1, top).

Shortly after admission her clinical course was further complicated by a *Pneumocystis carinii* pneumonia infection, a pneumonia and bacteraemia caused by *Streptococcus pneumoniae* and a *Candida albicans* esophagitis, for which she was treated successfully. Eighteen months after presentation she had gained 20 kg in weight with stable plasma creatinine concentrations.

Case 2

A 32-year-old male black patient presented with complaints of general malaise and a short history of progressive oedema of the lower legs. His blood pressure was 140/70 mmHg, weight 69 kg, and height 172 cm. There were signs of bilateral pleural effusion and on the lower legs peripheral oedema extending

to the knees was found. Laboratory investigations showed a plasma creatinine of 11.3 mg/dl, urea 94.4 mg/dl, and albumin 16 g/l. Two weeks before his plasma creatinine was 6.8 mg/dl. Additional laboratory tests revealed a normal urinary sediment on microscopy with a urinary protein excretion of 13 g/24 h. Tests for collagen diseases, vasculitis, or hepatitis were negative. Antibodies to HIV-1 were present. His CD4 lymphocyte count was below the lower level of detection and the viral load 40 000 viral copies/ml. Ultrasonography showed large and swollen kidneys. A percutaneous kidney biopsy could not be performed because of a prolonged bleeding time that could not be corrected. He was treated with furosemide, enalapril, and HAART consisting of zidovudine, zalcitabine, lamivudine, and zalcitabine (Figure 1). His renal function improved markedly and the viral load dropped below 50 copies/ml.

Four weeks after starting HAART the bleeding time was normal and a kidney biopsy was performed. It showed changes typical for HIVAN. All the 11 glomeruli showed significant segmental or global tuft collapse with wrinkling of the basal membrane and epithelial crescents in some of the glomeruli. The mesangial extracellular matrix was increased with variable mesangial cell proliferation. The tubuli were atrophic with cystic dilatation and were embedded in an interstitium with fibrosis and variable infiltration of mononuclear cells. On electron-microscopic examination glomerular endothelial cells showed tubuloreticular inclusions. No significant deposits of immunoglobulins or complement could be detected.

Case 3

A 40-year-old female black patient was seen at the outpatient clinic of the gastroenterology department because of weight loss. She used no medication or drugs. Pneumonia of the middle lobe was diagnosed which was treated with antibiotics orally. Additional investigations revealed a positive HIV-1 serology with a lowered CD4-positive lymphocyte count of 160/mm³ and a viral load of 124 000 copies/ml. She was referred to the outpatient clinic of the department of infectious diseases. Her blood pressure was 130/85 mmHg and no signs of oedema were present; plasma creatinine was 0.89 mg/dl. Shortly thereafter, she developed a severe herpes zoster infection ophthalmicus, which was treated appropriately. Anti-retroviral therapy could not be started because of problems with the health insurance. During follow-up, renal function deteriorated. The urinary sediment revealed four to 10 erythrocytes and four to 10 leukocytes per high power field and urinary protein was 17.2 g/day. Serology tests were negative for hepatitis C and positive for hepatitis B surface and core antibody. Ultrasonography showed kidneys measuring 11 cm with a hyperechogenic cortex.

A renal biopsy was performed that contained 34 glomeruli, 13 showing global sclerosis. The other

glomeruli showed signs of focal glomerulosclerosis with varying collapse and proliferation of visceral podocytes. The tubuli were atrophic and dilated. The interstitium showed infiltration of predominantly lymphocytes and extensive interstitial fibrosis. Some granular distribution of IgM and complement was seen on immunofluorescence examination. Electron microscopy revealed many tubuloreticular structures in the endothelial cells of the glomerulus. A diagnosis of HIVAN was made and patient was treated with HAART (stavudine, lamivudine, and efavirenz) in conjunction with ACE-inhibition. The viral load dropped to 70 copies/ml and the CD4 cell count increased to 290/mm³. The renal function improved with a decrease in proteinuria (Figure 1).

Discussion

The pathogenesis of HIVAN most probably involves a direct cytotoxic effect of HIV on renal cells. Heterozygote HIV-1 transgenic mice develop a nephrotic syndrome that closely resembles the human situation [2]. Crossover renal transplantation experiments suggested that intrarenal expression of HIV genes is essential in the pathogenesis [2]. The cytopathic effect on podocytes leads to dedifferentiation, proliferation, and loss of contact inhibition thereby causing collapsing glomerulosclerosis and heavy proteinuria [6]. The mesangial extracellular matrix may be thickened with increased numbers of mesangial cells. The tubuli are always affected and show dedifferentiation, atrophy, and increased apoptosis leading to cystic dilatation. In the interstitium, extensive fibrosis may be observed with varying infiltration by mononuclear cells [1]. Electron microscopic examination of the glomerular endothelial cells frequently reveals tubuloreticular structures, a feature that is shared with systemic lupus erythematosus (SLE) nephritis. Their presence could be caused by the action of interferon-alpha [1].

HIV-1 infects renal cells and the kidney may be an important long-term reservoir for the virus [5]. The porte d'entree for HIV-1 is not known as cellular receptors on renal cells like CD4 or the chemokine receptors have not been identified beyond doubt [7].

HIVAN usually occurs in patients with an AIDS-defining diagnosis with high viral loads, suggesting the importance of a high viral burden in the pathogenesis of HIVAN [1,8]. Also, the introduction of HAART has decreased the prevalence of HIVAN. The marked susceptibility of black HIV-1-infected patients and a familial disposition for ESRD indicates a strong genetic predisposition for HIVAN [1].

Based on pathogenic considerations as mentioned above, the optimal treatment for HIVAN would be the lowering of viral load. Since the introduction of HAART, this has now become feasible in most HIV-1-infected patients in western countries. The effect of HAART on renal function in patients with HIVAN is poorly studied, but is probably beneficial [3–5]. In these reports most patients were already

treated with anti-retroviral drugs or were given steroids thereby limiting the interpretation of the data. Monotherapy with a reverse transcriptase inhibitor like AZT was associated with a better renal prognosis especially early in the course of the disease [1].

Besides anti-retroviral drugs, corticosteroids and ACE-inhibition have been employed in the treatment of HIVAN. Corticosteroids may improve renal function although data from prospectively randomized trials are not available [1]. A recently published retrospective cohort study showed that corticosteroids are effective in slowing down the progression of renal dysfunction although most patients became dialysis dependent after 1 year [1]. The effect of corticosteroids may be mediated by diminishing the tubulo-interstitial mononuclear cell infiltrate [9]. Although corticosteroids can be safely used for a short-term period in most HIV patients, they should not be given to patients with severe opportunistic infections like Cases 1 and 2.

ACE-inhibition seems particularly beneficial in the treatment of HIVAN. When given to patients with modest renal insufficiency and proteinuria, ACE-inhibition may markedly slow down further progression of HIVAN [1]. Data from randomized clinical trials are unfortunately not available but the beneficial effects of ACE-inhibition were substantiated in HIV-1 transgenic mice. Captopril given after birth in these mice largely prevented the clinical and histopathological sequences of HIVAN [10]. The effects of ACE-inhibition have been attributed to inhibition of renal fibrosis caused by over expression of transforming growth factor (TGF)- β and β fibroblast growth factor (FGF). However, renal TGF- β expression did not differ between the captopril-treated and control mice [10].

The three patients in this report showed the typical clinical and pathological characteristics of HIVAN. They were black, had high viral loads, and impaired immunity as evidenced by low CD4 lymphocyte counts and serious infections in Cases 1 and 2. None of them were using medication or drugs. All three patients showed a rapid decline in renal function with massive proteinuria. Renal biopsy revealed the typical collapsing glomerulosclerosis with involvement of all renal cell compartments and the presence of reticulotubular structures. Cases 2 and 3 showed rapid improvement of renal function together with diminishing peripheral oedema during treatment with furosemide. This beneficial effect on renal function is probably mediated partly by diminishing the renal oedema as well, as in the renal biopsies no other rapidly reversible factor could be identified. Further improvement occurred with effective lowering of the viral load by giving HAART. The additional role of ACE-inhibition is unclear, although in Case 1 the proteinuria decreased markedly on furosemide and ACE-inhibition without HAART. This patient stopped the use of ACE-inhibition early in the course of treatment but nevertheless showed an excellent and stable improvement of renal function after starting HAART. Corticosteroids were not given because of the co-existence of severe

infections and the good response on HAART and ACE-inhibition. In all the patients HAART was continued but the effect on long-range renal function remains to be established.

The rapid progression of renal dysfunction in HIVAN combines usually with an impressive amount of irreversible renal damage. The ultimate recovery of renal function is dependent on the amount of glomerulosclerosis and interstitial fibrosis. The collapsed glomerulus with little or no sclerosis may recover completely [3]. In our cases no follow-up biopsies were performed.

Based on our preliminary data it appears that HAART with ACE-inhibition should be the treatment of choice in HIVAN and that stable and impressive improvement in renal function can be achieved. It should be noted that the clearance of several antiretroviral drugs is dependent on renal function and, therefore, dosage reductions or interval extensions should be made according to the existing guidelines. The use of corticosteroids can be reserved for patients that do not respond favourably to this therapy and have a dense tubulo-interstitial cell infiltrate. Early recognition and treatment is of paramount importance to minimize irreversible renal damage and optimally preserve renal function. The importance is further stressed by the fact that HIVAN is now the third leading cause of ESRD in blacks in the USA [1].

References

1. Kimmel P. The nephropathies of HIV infection: pathogenesis and treatment. *Curr Opin Nephrol Hypertens* 2000; 9: 117–122
2. Bruggeman LA, Dikman S, Meng C, Quaggin SE, Coffman TM, Klotman PE. Nephropathy in human immunodeficiency virus-1 transgenic mice is due to renal transgene expression. *J Clin Invest* 1997; 100: 84–92
3. Wali RK, Drachenberg CI, Papadimitriou JC, Keay S, Ramos E. HIV-1 associated nephropathy and response to highly-active antiretroviral therapy. *Lancet* 1998; 352: 783–784
4. Szezech LA, van der Horst C, Bartlett JA, Heald AE, Svetkey LP. Protease inhibitors are associated with a slowed progression of HIV-associated nephropathy. *J Am Soc Nephrol* 1999; 10: A0595
5. Winston JA, Bruggeman LA, Ross MD *et al.* Nephropathy and establishment of a renal reservoir of HIV type 1 during primary infection. *N Eng J Med* 2001; 344: 1979–1984
6. Schwartz EJ, Cara A, Snoeck H *et al.* Human immunodeficiency virus-1 induces loss of contact inhibition in podocytes. *J Am Soc Nephrol* 2001; 12: 1677–1684
7. Eitner F, Cui F, Hudkins KL, Stokes MB, Segerer S, Mack M. Chemokine receptor CCR5 and CXCR4 expression and HIV-1 detection in HIV-associated kidney disease. *J Am Soc Nephrol* 2000; 11: 856–867
8. Winston JA, Klotman ME, Klotman PE. HIV-associated nephropathy is a late, not early manifestation of HIV-1 infection. *Kidney Int* 1999; 55: 1036–1040
9. Briggs WA, Tanawattanacharoen S, Choi MJ, Scheel PJ, Nadasdy T, Racusen L. Clinicopathologic correlates of prednisone treatment of human immunodeficiency virus-associated nephropathy. *Am J Kidney Dis* 1996; 28: 618–621
10. Bird JF, Durham SK, Giancarli MR *et al.* Captopril prevents nephropathy in HIV-transgenic mice. *J Am Soc Nephrol* 1998; 9: 1441–1447

Received for publication: 14.3.02

Accepted in revised form: 3.6.02