

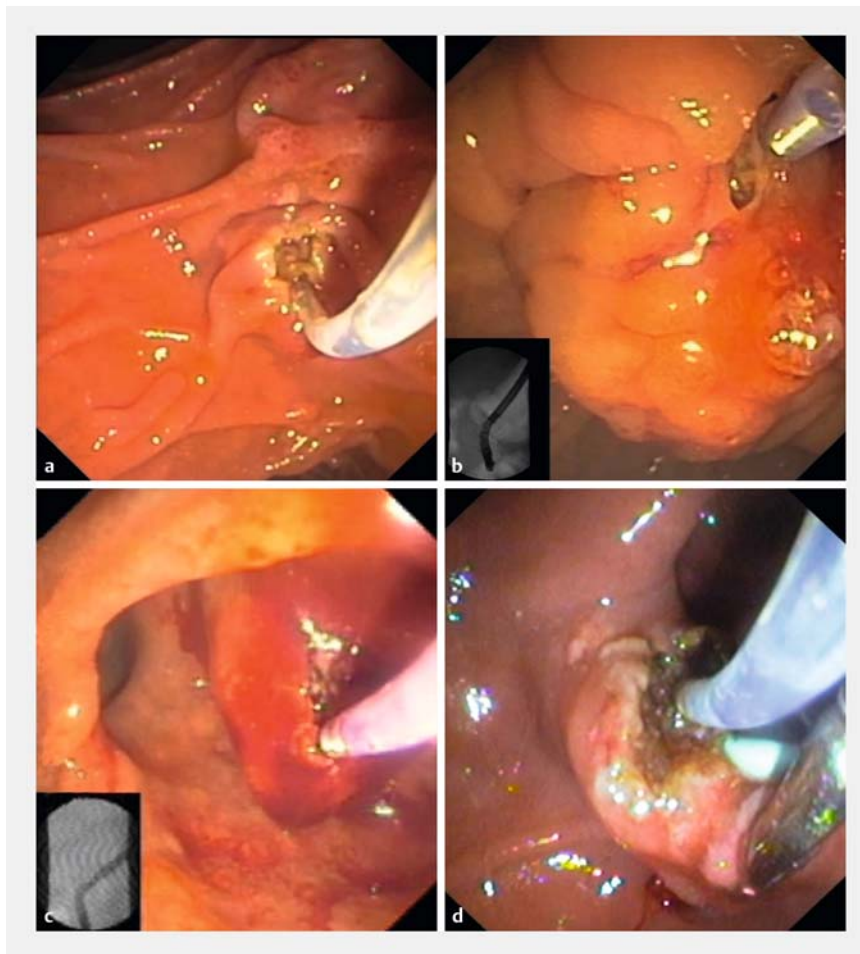
Precut fistulotomy – widening its limits

Selective cannulation of the common bile duct (CBD) is the most important and challenging step in a biliary endoscopic retrograde cholangiopancreatography (ERCP) [1, 2]. However, in the first ERCP, even in experienced hands, biliary cannulation may fail in up to 15%–35% of cases when using standard methods alone [3]. In this subset of patients, additional cannulation techniques are needed to access the CBD in order to continue with the ERCP. Precut is the most common strategy used by experienced endoscopists, when conventional methods have failed [2]. Needle-knife fistulotomy (NKF) and conventional precut are the two most common variants. Recently published guidelines recommend opting for NKF, as evidence suggests a lower risk of adverse events, especially pancreatitis, when used early in the biliary cannulation algorithm [2, 4].

This video report aims to demonstrate basic and advanced NKF maneuvers in challenging and hazardous settings, with an emphasis on the need to adapt to the patients' individual anatomy (► **Fig. 1**, ► **Video 1**). Consequently, even some of the most difficult biliary cannulation cases can have their problems managed by ERCP alone (in the same session), instead of being referred for endoscopic ultrasound or percutaneous biliary drainage.

In each case, the NKF procedure was performed using a needle-knife, in a freehand fashion, making a puncture in the papilla above the orifice, and then cutting on the CBD axis, while maintaining a free distance from the papillary orifice [5]. All procedures were performed by an experienced endoscopist (L.L.).

NKF is probably an obligatory technique to be included in the toolbox of every future advanced ERCP endoscopist. However, given its potential complications and the skills required to be proficient, it



► **Fig. 1** Needle-knife fistulotomy (NKF): basic and advanced maneuvers in challenging settings. **a** NKF performed at a distance from the papilla. **b** NKF performed in a patient with pancreatic cancer infiltrating the ampulla. **c** NKF performed in a patient with cholangitis secondary to limited hemobilia. **d** NKF performed in a patient with an intradiverticular papilla with the papillary orifice not visible from the duodenum, with the assistance of a biopsy forceps.

should probably be reserved for skilled endoscopists in high-volume ERCP centers.

Endoscopy_UCTN_Code_TTT_1AR_2AC

Competing interests

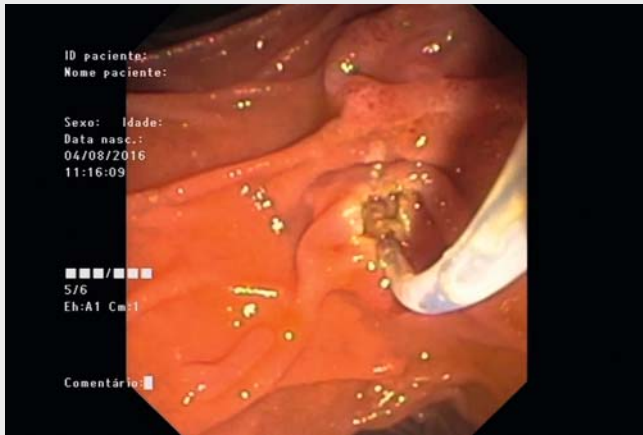
None

The authors

João Fernandes^{1,2}, Diogo Libânio³, Sílvia Giestas¹, José Ramada¹, David Martínez-Ares¹, Jorge Canena⁴, Luís Lopes^{1,5,6}

1 Gastroenterology Department, Hospital Santa Luzia, Viana do Castelo, Portugal

2 Gastroenterology Department, Centro Hospitalar Cova da Beira EPE, Covilhã, Portugal



Video 1 Use of needle-knife fistulotomy in highly challenging and demanding clinical settings.

- 3 Gastroenterology Department, Instituto Português de Oncologia do Porto Francisco Gentil, Porto, Portugal
- 4 Gastroenterology Department, Hospital Cuf Infante Santo, Lisboa, Portugal
- 5 Life and Health Sciences Research Institute (ICVS), School of Medicine, University of Minho, Braga, Portugal
- 6 ICVS/3B's – PT Government Associate Laboratory, Braga/Guimarães, Portugal

Corresponding author

João Fernandes, MD

Department of Gastroenterology, Hospital de Santa Luzia, Unidade Local de Saúde do Alto Minho, Estrada de Santa Luzia, 4901-858, Viana do Castelo, Portugal
Fax: +351-275-751057
Jotillfernandes@hotmail.com

Acknowledgments

The authors gratefully acknowledge the generous assistance of all of the endoscopy unit staff.

References

- [1] Lopes L, Dinis-Ribeiro M, Rolanda C. Safety and efficacy of precut needle-knife fistulotomy. *Scand J Gastroenterol* 2014; 49: 759–765
- [2] Testoni PA, Mariani A, Aabakken L et al. Papillary cannulation and sphincterotomy techniques at ERCP: European Society of Gastrointestinal Endoscopy (ESGE) Clinical Guideline. *Endoscopy* 2016; 48: 657–683
- [3] Testoni PA, Testoni S, Giussani A. Difficult biliary cannulation during ERCP: how to facilitate biliary access and minimize the risk of post-ERCP pancreatitis. *Dig Liver Dis* 2011; 43: 596–603

- [4] Lopes L, Dinis-Ribeiro M, Rolanda C. Early precut fistulotomy for biliary access: time to change the paradigm of “the later, the better”? *Gastrointest Endosc* 2014; 80: 634–641
- [5] DaVee T, Garcia JA, Baron TH. Precut sphincterotomy for selective biliary duct cannulation during endoscopic retrograde cholangiopancreatography. *Ann Gastroenterol* 2012; 25: 291–302

Bibliography

DOI <https://doi.org/10.1055/a-0573-0793>
Published online: 8.3.2018
Endoscopy 2018; 50: E128–E129
© Georg Thieme Verlag KG
Stuttgart · New York
ISSN 0013-726X

ENDOSCOPY E-VIDEOS

<https://eref.thieme.de/e-videos>



Endoscopy E-Videos is a free access online section, reporting on interesting cases and new techniques in gastroenterological endoscopy. All papers include a high quality video and all contributions are freely accessible online.

This section has its own submission website at <https://mc.manuscriptcentral.com/e-videos>