



ID Design Press, Skopje, Republic of Macedonia
 Open Access Macedonian Journal of Medical Sciences. 2019 Jan 30; 7(2):287-290.
Special Issue: Vietnamese Dermatology
<https://doi.org/10.3889/oamjms.2019.096>
 eISSN: 1857-9655
Clinical Science

Successful Treatment of Freckles by Alex Trivantage Laser Wavelength 755 nm in Vietnamese Patients

Sau Nguyen Huu¹, Cap Lam Van², Thuong Nguyen Van¹, Tan Nguyen Manh¹, Phuong Pham Thi Minh¹, Son Nguyen Hong¹, Nghi Dinh Huu¹, Van Tran Cam¹, Kiem Pham Cao¹, Khang Tran Hau¹, Marco Gandolfi³, Francesca Satolli³, Claudio Feliciani³, Michael Tirant^{4,5}, Aleksandra Vojvodic⁶, Torello Lotti⁴

¹National hospital of Dermatology and Venereology, Hanoi, Vietnam; ²Hanoi Dermatology Hospital, Hanoi, Vietnam; ³Unit of Dermatology, University of Parma, Parma, Italy; ⁴University of Rome G. Marconi, Rome, Italy; ⁵Psoriasis Eczema Clinic, Melbourne, Australia; ⁶Department of Dermatology and Venereology, Military Medical Academy of Belgrade, Belgrade, Serbia

Abstract

Citation: Nguyen Huu S, Lam Van C, Van TN, Manh TN, Thi Minh PP, Nguyen Hong S, Dinh Huu N, Tran Cam V, Pham Cao K, Tran Hau K, Gandolfi M, Satolli F, Feliciani C, Tirant M, Vojvodic A, Lotti T. Successful Treatment of Freckles by Alex Trivantage Laser Wavelength 755 nm in Vietnamese Patients. Open Access Maced J Med Sci. 2019 Jan 30; 7(2):287-290. <https://doi.org/10.3889/oamjms.2019.096>

Keywords: Freckle; Pigmentation disorders: QS-alexandrite laser

***Correspondence:** Marco Gandolfi. Unit of Dermatology, University of Parma, Parma, Italy. E-mail: marco.gandolfi5@gmail.com

Received: 02-Jan-2019; **Revised:** 16-Jan-2019; **Accepted:** 17-Jan-2019; **Online first:** 29-Jan-2019

Copyright: © 2019 Sau Nguyen Huu, Cap Lam Van, Thuong Nguyen Van, Tan Nguyen Manh, Phuong Pham Thi Minh, Son Nguyen Hong, Nghi Dinh Huu, Van Tran Cam, Kiem Pham Cao, Khang Tran Hau, Marco Gandolfi, Francesca Satolli, Claudio Feliciani, Michael Tirant, Aleksandra Vojvodic, Torello Lotti. This is an open-access article distributed under the terms of the Creative Commons Attribution-NonCommercial 4.0 International License (CC BY-NC 4.0)

Funding: This research did not receive any financial support

Competing Interests: The authors have declared that no competing interests exist

OBJECTIVES: This study aims to evaluate the effectiveness of Alex Trivantage laser wavelength 755 nm (ATL) in the treatment of freckles at Hanoi Hospital of Dermatology and Venereology, Vietnam.

PATIENTS AND METHODS: A group of 30 patients with freckles were treated by ATL (Alex Trivantage-Candela Co America) with spots size 3 mm, wavelength 755 nm, and energy 5-6 j/cm². All the patients were treated 2 times with 4-weeks interval. The results were evaluated at 4, 8, and 12 weeks after treatment. The colour of the lesions was evaluated by using Von-Luchan's chromatic scale and Visia® complex analysis system. Brown spot index (BSI) was calculated by the VISA complexion analysis system devices. The data was analysed by SPSS 16.0.

RESULTS: After 2 times of treatment, the lesion colour of all of the patients had been improved. The good and very good levels of improvement were noted in 63.3% of patients; there was 26.7% of them had partial improvement. Brown spots index was significantly improved (39.13 ± 20.66 before and 54.23 ± 16.78 after treatment; p < 0.001). Hyperpigmentation was noted in 6.7% of patients.

CONCLUSION: freckles have been improved by treatment with Alex trivantage laser wavelength 755 nm with safety.

Introduction

Vietnamese, as well as the Asian people, belongs to skin types III-V (Fitzpatrick skin type). However, melasma, freckles, and lentigines are the epidermal disorders commonly seen [1].

Freckles are typical pigmentation disorders presenting by hyperpigmentation dark – brown or light – circular brown spots on face, especially on the cheeks. Freckles should be distinguished from

lentigines [2]. Lentigines are well-circumscribed, small, brown spots which appear both on sun-exposed and no exposed areas [3], [4]. Freckles can appear on all types of skin tones [2], [5].

Several treatments effectively diminish the appearance of freckles. Some of the treatments include skin-lightening creams such as hydroquinone, prescription medications containing retinoid, chemical peels that are shown to improve pigmentation irregularities, IPL therapy [6] and others pigment lasers [7], [8], [9]. Alex TriVantage is a q-switched laser which is built upon the proven performance of

755 nm, Q-switched Alexandrite laser with the addition of 1064 nm and 532 nm, Q-switched Nd:YAG wavelengths. With the 755 nm Long-Pulse mode, it is used for treating a wide variety of epidermal and subdermal pigmented lesions safely. The acquirement of freckles treatment is recently increased in Vietnam and many medical facilities in our country in the past few years applied the different pigment lasers in treating pigmentary disorders.

Our study aimed to assess the effectiveness of Alex TriVantage laser on freckles treatment at Hanoi Hospital of Dermatology and Venereology (HHDV).

Patients and Methods

The prospective controlled clinical trial on 30 patients with freckles treated by QS Alexandrite laser at HHDV. Informed consent was obtained from the patients before the laser treatment. Photographs were taken before treatment. The treated areas were numbed with topical anaesthesia using EMLA 5% cream. Eyes of patients were protected with specific protective glasses. In all cases, test spots were done, and the results were checked after 1 month to determine the parameters before performing the laser treatment on the entire area.

The used laser machine was an AlexTriVantage of Candela company – the USA, wavelength 755 nm. The patients have treated 2 sections with power 5.0-6.0 J/cm²; spot size 3 mm, at week 0 and week 4. Ice packs were applied to the treated areas to reduce erythema and oedema.

After these procedures, all patients were asked to avoid unnecessary sun exposure. None combination treatment was indicated after the laser treatment once the scabs had fallen off along with daytime use of sunscreen. The final results were analysed after 4, 8 and 12 weeks after treatment. The colour of the lesion was assessed by using colour to Von Luschan's chromatic scale:

Grade 1: same skin colour with normal skin;

Grade 2: light pigmentation (scale 19-24) ;

Grade 3: medium pigmentation (scale 25-27) ;

Grade 4: hyperpigmentation (scale 28-32) ;

Grade 5: very high pigmentation (scale 33-36).

The results were evaluated based on the improvement of the lesion colour before and at 4, 8 and 12 weeks after treatment with very good improvement, if colour of lesion improved ≥ 3 scales or the lesion, becomes normal skin; good

improvement if colour of lesion improved ≥ 2 scales and no improvement if the colour of lesion improved less than 1 scale.

Table 1: Characteristics of study subjects

	n	%
Sex		
Female	29	96.7
Male	1	3.3
Age		
11- \leq 20	3	10
21- \leq 30	6	20
31- \leq 40	15	50
41- \leq 50	4	13.3
$>$ 50	2	6.7
Skin type		
III	11	36.7
IV	19	63.3
Severity (Basing on the number of lesions)		
$<$ 100	4	13.3
$>$ 100	26	86.7

We also analysed the improvement of the lesion colour by Visia[®] complex analysis system. The Canfield Imaging Systems was used for capturing multi-spectral photos of the face. Brown spot index was calculated and analysed at pre- and post-treatment by digital images technologies (BS-320 facial skin analysis)

The side-effects including hyperpigmentation, hypopigmentation, scars, were reported. The data was collected and analysed by SPSS 16.0.

Results

Thirty female patients were recruited for the study. Almost all of them were female (96.7%). Nine of patients (30%) were less than 30 years old, and 11 (70%) of them were older than 30 years old as shown in Table 1. All of them were finished at 2 sections of treatment, and no patients were needed in the third section. In overalls, the good and very good levels were noted in 63.3% of patients; there was 26.7 % of them had partial improvement. Brown spots index before and after treatment were 39.13 ± 20.66 and 54.23 ± 16.78 ($p < 0.001$; respectively); and after 12-weeks, there were no recurrences as shown in Table 2 and Figure 1.

Table 2: The effectiveness of QS Alexandrite laser on freckles treatment (n = 30)

		Improvement	
		good and very good n (%)	Partial n (%)
Age	$<$ 30	7 (23.3)	2 (6.7)
(years old)	$>$ 30	12 (40.0)	9 (30.0)
Skin Type	III	10 (33.3)	1 (3.3)
(Fitzpatrick classification)	IV	9 (30.1)	10 (33.3)
	Chin	6 (20.0)	1 (3.3)
Location	forehead	2 (6.7)	2 (6.7)
	Check, nose	11 (36.7)	8 (26.6)
Total		19 (63.3)	11 (26.7)

The improvement of lesions on patients with skin type III was higher than that on patients with type

IV skin; however, the statistic was not significant. The result was not also different between the location of the lesions as well as of the age of the patients as shown in Table 2.

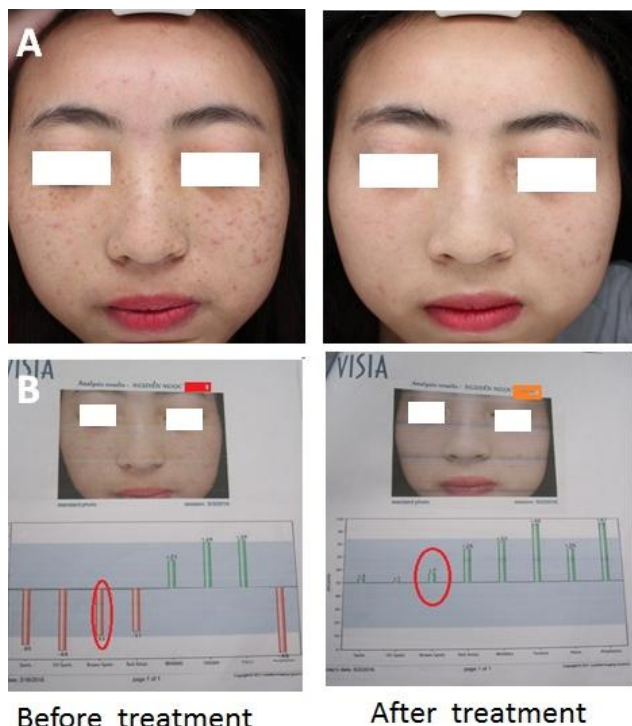


Figure 1: A 19 years old woman before and after 2 sections of treatment by QS Alexandrite A); Brown spots index before was - 35.5 and +7 after treatment B)

The Brown index before and after treatment are 39.13 ± 2066 and $54.23 \pm 16, 78$ ($p < 0,005$; test T student).

Investigating side effects, we noted that 2 patients had hyperpigmentation post laser treatment, accounting for 6.7%. No patients suffered from hypopigmentation and scars as shown in Table 3.

Table 3: The unwanted effects after QS Alexandrite treatment

Unwanted effects	n	%
Hyperpigmentation	2	6.7
Hypopigmentation	0	0
Scars	0	0
No side effects	28	93.3
Total	30	100

Discussion

The associated factors are affecting the efficiency of the QS Alexandrite laser treatment.

Alex TriVantage laser is a Q-switched Alexandrite laser with the addition of 1064, 532 and 755 nm. Composing of 755 nm Long-Pulse mode, Alex TriVantage laser is used for treating a wide

variety of epidermal and subdermal pigmented lesions safely. The Alexandrite allows deep penetrating rays in the skin to destroy melanocytes selectively while limiting post hyperpigmentation.

Freckles are commonly found in skin types I-IV as small, poorly marginated, pale brown macules on sun-exposed skin areas. They are not dangerous for the health, but they cause mainly cosmetic troublesome. Nowadays, many pigmentation lasers have been used for treating freckles such as the 755 nm alexandrite, 694 nm ruby, 532 nm, and 1064 nm neodymium: YAG nanosecond lasers appear to be safe and effective modalities.

In our study, 30 patients with freckles treated 2 sections with power $5.0-6.0 \text{ j/cm}^2$; spot size 3 mm, at week 0 and week 4. Three patients needed only 1 session of treatment for clearing the lesions, and 2/30 patients needed 2 sessions. No patients needed 3 sessions. After 12-weeks, 100% of patients had improvement. After 2 sessions of treatment, the very good and good degree was found with 63.3% as shown in Table 2.

The study of Jang KA *et al.* carried out a study with 197 patients, using the Q-switched alexandrite laser at 8-week intervals with 7.0 J/cm^2 , and they also demonstrated 100% patients had improvement with only 1.5 sections [8]. It elicits that using the lower power with shorter time interval as in our study giving the similar results of Jang group [8].

An alexandrite laser is one that uses an alexandrite crystal as the laser source for producing a specific wavelength of red light (755 nm). Q-switched Alexandrite lasers refer to the technique of making the laser produce a high-intensity beam in very short pulses. Thus alexandrite lasers work by process of photothermolysis for melanin destruction.

Comparing between section 1 and 2, we noted that there was a statistically significant difference in colour's improvement ($p < 0.05$). Although freckles do not have an increased number of the melanin-producing cells or melanocytes, freckles may instead of having melanocytes that overproduce melanin granules (melanosomes) changing the colouration of the outer skin cells (keratinocytes). Some other studies also demonstrated the improving after 1 to 3 lasers sessions in the treatment of pigmentation disorders [10], [11].

We used the VISIA machine to evaluate the efficacy of treatment. Brown Spots index supported us to assess the excessive concentration of melanin in freckle lesions. Brown spots index before and after treatment were 39.13 ± 20.66 and 53.23 ± 16.78 respectively; the difference is statistically significant with $p < 0.05$.

Regarding factors such as age, skin type, our study showed that people less than 30 years old, and early onset before the age of 30 had good improvement with 77.8% and 66.7% respectively. The

improvement is better for young people. Then there was a noticeable reduction in sebum secretion, skin dehydration and pigmentation.

The improvement of lesions located in the chin, nose and forehead area was 87.5%; 50% and 57.9% respectively. In the present study, there were only 2 patients, accounting for 6.7%, with post-inflammatory hyperpigmentation, as a side effect. This is similar to other studies in Asia [8], [9], [12]. Our findings, as well as the results of other investigations, noted that post-inflammatory hyperpigmentation was temporary, resolving within one month, and no long-term complications were noted.

Also, we also founded no patients presented hypopigmentation, keloids, atrophic scars, keloids, atrophic scars and ochronosis. It was noted that there were no recurrences after 12 weeks.

In conclusion, laser QS – Alexandrite had a good device for freckles treatment. All of the patients had improvement in lesion's colour, about 63.3% of patients with a very good and good level of improvement. Only 6.7% of patients had temporally post-inflammatory hyperpigmentation. The Q-switched alexandrite laser is a safe and highly effective modality for removing freckles without scarring or permanent pigmentary changes in Vietnamese skin.

Author contributions

NHS, TCV and LVC designed, performed experiments, collected and analysed data, and collected informed consents. NHS, TCV and LVC interpreted the results. All authors wrote the manuscript. DTC and DHB edited the manuscript. All authors approved the final manuscript.

References

1. Ho SG, Chan HH. The Asian dermatologic patient: review of common pigmentary disorders and cutaneous diseases. *Am J Clin Dermatol*. 2009; 10:153-168. <https://doi.org/10.2165/00128071-200910030-00002> PMID:19354330
2. Ezzedine K, Mauger E, Latreille J, Jdid R, Malvy D, Gruber F, Galan P, Hercberg S, Tschachler E, Guinot C. Freckles and solar lentigines have different risk factors in Caucasian women. *J Eur Acad Dermatol Venereol*. 2013; 27:e345-356. <https://doi.org/10.1111/j.1468-3083.2012.04685.x> PMID:22924836
3. Scarcella G, Dethlefsen MW, Nielsen MCE. Treatment of solar lentigines using a combination of picosecond laser and biophotonic treatment. *Clin Case Rep*. 2018; 6:1868-1870. <https://doi.org/10.1002/ccr3.1749> PMID:30214780 PMID:PMC6132099
4. Fogarty GB, Hong A, Economides A, Guitera P. Experience with Treating Lentigo Maligna with Definitive Radiotherapy. *Dermatol Res Pract*. 2018; 2018:7439807. <https://doi.org/10.1155/2018/7439807> PMID:30105052 PMID:PMC6076978
5. Chan IL, Cohen S, da Cunha MG, Maluf LC. Characteristics and management of Asian skin. *Int J Dermatol*. 2018.
6. Huang YL, Liao YL, Lee SH, Hong HS. Intense pulsed light for the treatment of facial freckles in Asian skin. *Dermatol Surg*. 2002; 28:1007-1012. PMID:12460294
7. Chan HH, Fung WK, Ying SY, Kono T. An in vivo trial comparing the use of different types of 532 nm Nd:YAG lasers in the treatment of facial lentigines in Oriental patients. *Dermatol Surg*. 2000; 26:743-749. <https://doi.org/10.1046/j.1524-4725.2000.00039.x> PMID:10940060
8. Jang KA, Chung EC, Choi JH, Sung KJ, Moon KC, Koh JK. Successful removal of freckles in Asian skin with a Q-switched alexandrite laser. *Dermatol Surg*. 2000; 26:231-234. <https://doi.org/10.1046/j.1524-4725.2000.09243.x> PMID:10759799
9. Chan JC, Shek SY, Kono T, Yeung CK, Chan HH. A retrospective analysis on the management of pigmented lesions using a picosecond 755-nm alexandrite laser in Asians. *Lasers Surg Med*. 2016; 48:23-29. <https://doi.org/10.1002/lsm.22443> PMID:26696500
10. Levin MK, Ng E, Bae YS, Brauer JA, Geronemus RG. Treatment of pigmentary disorders in patients with skin of color with a novel 755 nm picosecond, Q-switched ruby, and Q-switched Nd:YAG nanosecond lasers: A retrospective photographic review. *Lasers Surg Med*. 2016; 48:181-187. <https://doi.org/10.1002/lsm.22454> PMID:26922302
11. Ho SG, Chan NP, Yeung CK, Shek SY, Kono T, Chan HH. A retrospective analysis of the management of freckles and lentigines using four different pigment lasers on Asian skin. *J Cosmet Laser Ther*. 2012; 14:74-80. <https://doi.org/10.3109/14764172.2012.670707> PMID:22372516
12. Wang CC, Sue YM, Yang CH, Chen CK. A comparison of Q-switched alexandrite laser and intense pulsed light for the treatment of freckles and lentigines in Asian persons: a randomized, physician-blinded, split-face comparative trial. *J Am Acad Dermatol*. 2006; 54:804-810. <https://doi.org/10.1016/j.jaad.2006.01.012> PMID:16635661
13. Gianfaldoni S, Tchernev G, Wollina U, et al. An Overview of Laser in Dermatology: The Past, the Present and ... the Future (?). *Open Access Maced J Med Sci*. 2017;5(4):526-530. <https://doi.org/10.3889/oamjms.2017.130> PMID:28785350 PMID:PMC5535675