

# UNIVERSITY OF BIRMINGHAM

## Research at Birmingham

### Minimally invasive vertical vs. conventional tooth extraction: an interrupted time series study

Dietrich, Thomas; Hong, Bosun; Gorecki, Patricia; Bulsara, Yogesh

DOI:

[10.1016/j.adaj.2018.03.022](https://doi.org/10.1016/j.adaj.2018.03.022)

License:

Creative Commons: Attribution-NonCommercial-NoDerivs (CC BY-NC-ND)

*Document Version*

Publisher's PDF, also known as Version of record

*Citation for published version (Harvard):*

Dietrich, T, Hong, B, Gorecki, P & Bulsara, Y 2018, 'Minimally invasive vertical vs. conventional tooth extraction: an interrupted time series study', *Journal of the American Dental Association*.  
<https://doi.org/10.1016/j.adaj.2018.03.022>

[Link to publication on Research at Birmingham portal](#)

#### General rights

Unless a licence is specified above, all rights (including copyright and moral rights) in this document are retained by the authors and/or the copyright holders. The express permission of the copyright holder must be obtained for any use of this material other than for purposes permitted by law.

- Users may freely distribute the URL that is used to identify this publication.
- Users may download and/or print one copy of the publication from the University of Birmingham research portal for the purpose of private study or non-commercial research.
- User may use extracts from the document in line with the concept of 'fair dealing' under the Copyright, Designs and Patents Act 1988 (?)
- Users may not further distribute the material nor use it for the purposes of commercial gain.

Where a licence is displayed above, please note the terms and conditions of the licence govern your use of this document.

When citing, please reference the published version.

#### Take down policy

While the University of Birmingham exercises care and attention in making items available there are rare occasions when an item has been uploaded in error or has been deemed to be commercially or otherwise sensitive.

If you believe that this is the case for this document, please contact [UBIRA@lists.bham.ac.uk](mailto:UBIRA@lists.bham.ac.uk) providing details and we will remove access to the work immediately and investigate.

## Original Contributions

## Minimally invasive vertical versus conventional tooth extraction

## An interrupted time series study

Bosun Hong, BDS; Yogesh Bulsara, BDS, MMedSci; Patricia Gorecki, Dr. Med Dent; Thomas Dietrich, Dr. Med Dent, Dr Med, MPH

## ABSTRACT

**Background.** Minimally invasive vertical tooth extraction techniques have evolved in light of the limitations of conventional tooth extraction techniques and flap surgery in preserving the alveolar bone. The authors conducted a study to obtain data on the performance of a vertical extraction system. This included comparing the need for flap surgery using the vertical extraction system versus conventional tooth extraction techniques for the extraction of anterior teeth and premolars not suitable for forceps extraction.

**Methods.** The authors conducted a prospective observational clinical study of the vertical extraction system versus conventional tooth extraction techniques using an interrupted time series in line with the Idea, Development, Exploration, Assessment, Long-term Follow-up collaboration framework for surgical innovation.

**Results.** Overall, 276 of 323 teeth (85.4%) in 240 patients were successfully extracted using the vertical extraction system. Of the 47 failures in the vertical tooth extraction cohort, 18 required flap surgery, resulting in an overall incidence of flap surgery of 5.6% (95% confidence interval [CI], 3.2% to 8.7%). During the routine care period, of the 94 anterior teeth and premolars in 78 patients, 21 teeth could not be extracted using conventional techniques and required flap surgery, leading to an incidence of flap surgery of 22% (95% CI, 14% to 32%).

**Conclusions.** The results suggest that the vertical extraction system may be used with a high success rate for extraction of severely destroyed teeth, and its use may lead to a marked reduction in the need for flap surgery. Randomized clinical trials are needed to confirm the findings.

**Practical Implications.** The use of a vertical extraction system may lower the incidence of flap surgery.

**Key Words.** Tooth extraction; oral surgical procedures; minimally invasive procedures.

JADA 2018; ■(■):■-■

<https://doi.org/10.1016/j.adaj.2018.03.022>

**T**ooth extraction is associated with loss of alveolar bone, which is thought to occur from both physiological<sup>1-3</sup> and iatrogenic mechanisms as no extraction technique is completely atraumatic.<sup>4-6</sup> The postextraction loss of alveolar bone can compromise the functional and esthetic rehabilitation with removable or fixed prostheses, including dental implants.<sup>4,6,7</sup>

Several possible determinants of the extent of alveolar bone loss have been proposed. These include systemic factors such as a patient's general health and behavior<sup>8,9</sup>; local factors including the tooth type and location (mandible or maxilla); the preoperative condition of the socket; the number, proximity, and type of teeth extracted<sup>10</sup>; and postextraction treatment protocols.<sup>10,11</sup> In addition, the mode of extraction has been reported to influence the extent of alveolar bone resorption.<sup>1,12,13</sup> Conventional tooth extraction techniques involving the use of elevators, luxators, periostomes, and forceps operate on the principle of socket expansion and will, therefore, traumatize the alveolar bone to some extent.<sup>4-6</sup> For teeth not manageable with these instruments, a standard approach would be reflection of a mucoperiosteal flap, often followed by bone removal to facilitate tooth extraction. Although the evidence for bone loss due to reflection of the flap alone may be inconclusive,<sup>14,15</sup> bone removal during flap surgery represents additional alveolar bone loss even

Copyright © 2018  
American Dental  
Association. This is an  
open access article under  
the CC BY-NC-ND license  
(<http://creativecommons.org/licenses/by-nc-nd/4.0/>).

before any bone resorption in the context of socket remodeling commences. In addition, clinical research has implicated flap surgery with increased postoperative pain<sup>16-18</sup> and may hamper soft-tissue esthetics at the rehabilitation stage.<sup>19</sup> Therefore, a reduction in the need for flap surgery would be a desirable feature of any novel extraction technique.

In light of the limitations of conventional tooth extraction techniques and flap surgery in preserving alveolar bone and assuming that minimally invasive methods result in better ridge preservation, a number of novel vertical tooth extraction techniques have evolved.<sup>6,12,13,20</sup> These techniques share the common principle of causing no direct trauma to the socket walls through severance of the periodontal ligament by pulling the tooth in an axial direction from its socket. Evidence regarding the effectiveness of vertical extraction systems is scarce. Timely evaluation of novel surgical techniques is important to prevent widespread adoption without sufficient evidence and, equally, to promote innovation supported by adequate evidence.<sup>21,22</sup> However, evaluation of surgical innovation is challenging for various reasons, including but not limited to the fact that surgical technique and approach, as well as instrumentation, continue to evolve as novel techniques are used in practice. Hence, alternatives to randomized controlled trials play an important role, in particular in the earlier phases of the introduction of novel techniques into clinical practice. The IDEAL Collaboration has proposed a 5-stage framework of surgical innovation, which has been used in many surgical specialties.<sup>21,22-26</sup>

We conducted a proof-of-principle clinical study from November 2010 through March 2011 that evaluated the technical applicability, success rates, learning curve, and limitations of a vertical extraction system (Benex, Helmut Zepf Medizintechnik and Hager & Meisinger).<sup>27</sup> The study suggested that the vertical extraction system was of limited use for the extraction of molars, but it achieved high success rates in anterior teeth and premolar extractions. Importantly, the study suggested that the use of the vertical extraction system may be associated with a marked reduction in the need for flap surgery for extractions of anterior teeth and premolars that were not suitable for standard forceps extraction.

Our aims for conducting this study were to extend our earlier cohort study to provide more robust data on the performance of the vertical extraction system in anterior teeth and premolar extractions and compare the need for flap surgery using the vertical extraction system with conventional tooth extraction techniques for the extraction of anterior teeth and premolars that are not suitable for forceps extraction. To this end, we conducted an interrupted time series study in line with the principles of the IDEAL framework stage 3.<sup>21</sup>

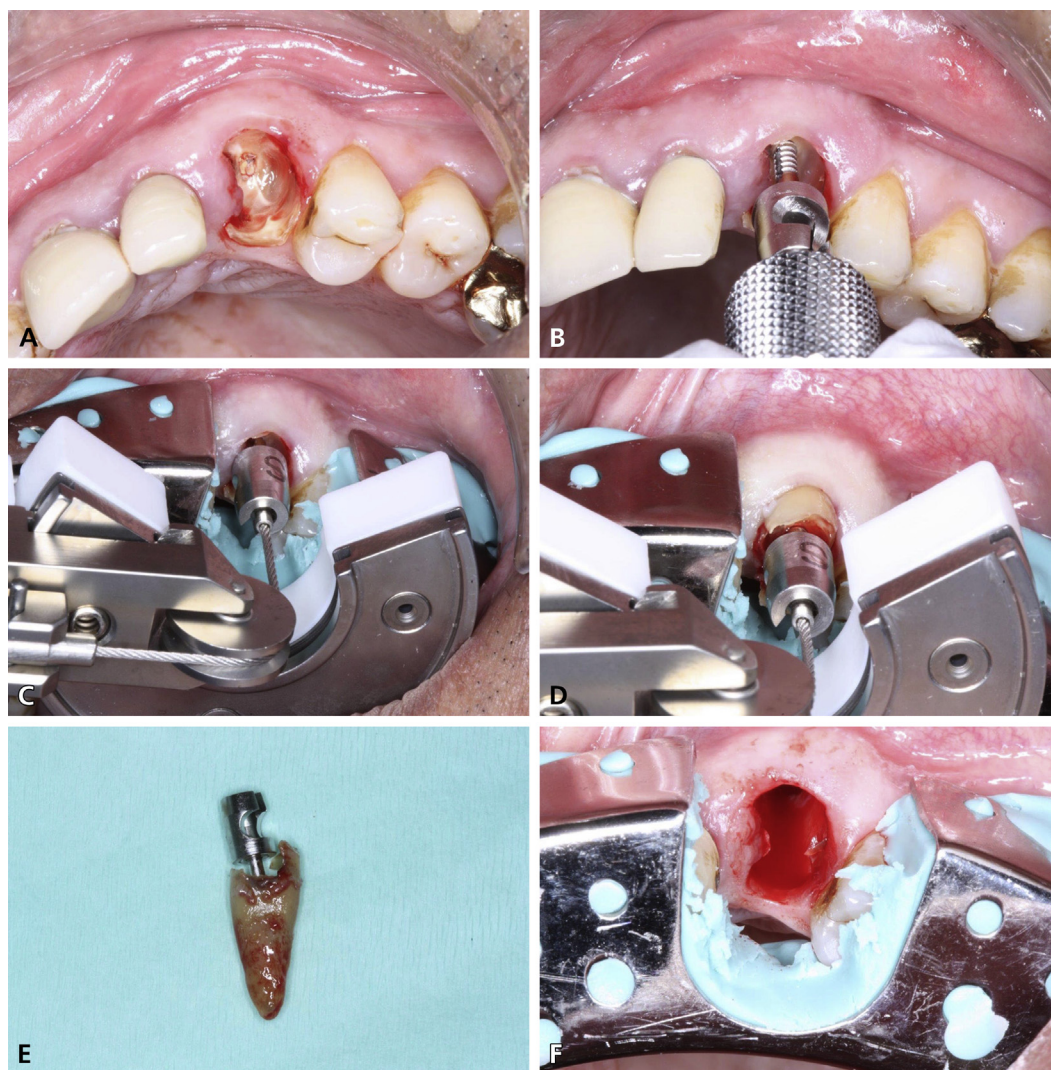
## METHODS

### Study design and participants

We conducted a prospective observational clinical study using the vertical extraction system (hereafter referred to as the vertical extraction cohort) and conventional tooth extractions (hereafter referred to as the conventional cohort) using an interrupted time series.<sup>21</sup> As this study used only anonymized data collected as part of routine clinical care, formal review by a research ethics committee was not required. The study was approved by National Health Service Research and Development (no. BBC RMG 1440). All patients gave informed consent to treatment.

For the purpose of this analysis, we defined conventional tooth extraction techniques as the use of forceps, luxators, elevators, or periostomes for tooth extraction. Flap surgery was defined as reflection of a mucoperiosteal flap (with or without subsequent bone removal with a bur). In the vertical extraction cohort, success was defined as the complete removal of roots by means of the vertical extraction system. After failure using the vertical extraction system, teeth were extracted with conventional tooth extraction techniques or, if necessary, flap surgery.

From November 2010 through April 2014, patients in the vertical extraction cohort underwent extractions of anterior teeth and premolars by 1 of 7 clinicians with 3 or more years of experience in oral surgery, using the vertical extraction system. The vertical extraction system was introduced to the participating clinicians by 2 clinicians with prior experience with the system, using a slide presentation and 1-to-1 practical demonstration. Teeth had to be deemed not suitable for a conventional forceps extraction owing to the limited coronal tooth tissue remaining or to the crown fracturing during a forceps extraction attempt. We excluded primary teeth, molars, impacted teeth, and teeth with greater than first degree mobility. The study extended and included the data reported on in our 2013 report,<sup>27</sup> excluding mandibular molars.



**Figure 1.** Vertical extraction system (Benex, Helmut Zepf Medizintechnik and Hager & Meisinger) in use during extraction of maxillary left canine tooth. **A.** Maxillary left canine root after gross caries removal and pilot hole preparation into the canal. **B.** Placement of screw into the root. **C.** Support tray and assembled vertical tooth extraction system to achieve axial alignment. **D.** Progressive root extrusion in a vertical direction. **E.** Extracted root. **F.** Tooth socket after extraction. *Figure courtesy of Dr. Dietrich.*

Full details of the treatment protocol for the vertical extraction system (Figure 1) have been described elsewhere.<sup>27,28</sup> Briefly, any grossly carious tissue was removed and the diamond bur was used in a straight or contra-angle 1:1 handpiece to prepare a canal for subsequent screw insertion. After insertion of the pull rope into the screw head, the extractor appliance was placed. To achieve axial alignment of the pull rope or provide a stable support for the support disk of the extractor appliance, a sectional impression tray with silicone putty impression material was used when deemed necessary by the dental surgeon. The tooth was then extracted by gradually increasing the traction force using the extractor. If tooth extraction using the vertical extraction system failed for any reason, the tooth was then extracted by the use of elevators, luxators, or flap surgery as appropriate.

Data for the conventional cohort were collected as part of a clinical audit conducted from February 2015 through February 2016 for outpatients undergoing tooth extractions under local anesthesia. During this period, the vertical extraction device was not available to clinicians. Data recorded included all the inclusion and exclusion criteria for the vertical extraction cohort so that appropriate comparisons could be made with the vertical extraction cohort.

We used scannable case report forms to collect data. The forms used for both cohorts included age, sex, race or ethnicity, tooth type, whether the tooth was multirooted (assessed after extraction),

presence of root canal filling (yes or no), history of failed forceps extraction (yes or no), and availability of a radiograph (yes and no).

### Statistical analysis

We scanned and checked the data for validity using a data capture system (KeyPoint 6, Speedwell Software). We then transferred the data to statistical analysis software for analysis (Stata 14, StataCorp). We calculated summary statistics for continuous and categorical variables for both cohorts and for successful and failed vertical extraction, separately. We calculated the proportion (incidence) of success and failure of vertical extractions and the proportion (incidence) of flap surgery for both cohorts. We considered age, sex, race or ethnicity, jaw (mandible versus maxilla), tooth type (multirooted versus single-rooted), history of root filling, availability of a radiograph, and history of failed extractions as potential determinants of successful vertical extractions using the vertical extraction system. We entered these characteristics as independent variables in a generalized linear model with failure and success as the dependent variable to calculate risk ratios for failure of extraction. We used generalized estimating equations with an exchangeable correlation structure to account for clustering of several teeth within patients. We also used generalized estimating equations to produce appropriate confidence intervals (CIs) for estimates of the incidence of flap surgery in the vertical extraction system and conventional cohorts.

### RESULTS

A total of 323 teeth in 240 patients were included in the vertical extraction system cohort. The patients included 151 males with a mean age of 50 years (range, 17-89), and 89 females with a mean age of 50 years (range, 17-91). Most teeth were located in the maxilla (65.9%,  $n = 213$ ) and did not have root canal fillings (74.9%,  $n = 242$ ). Based on postoperative assessments, 33 teeth (10.2%) were multirooted. Five of these were sectioned before applying the vertical extraction system, resulting in a total of 328 roots for which an extraction was attempted with the vertical tooth extraction device. Forty-three teeth (13.3%) were included after a forceps extraction had failed. No radiographs were available for 38 teeth (11.8%) (Table 1).

Overall, 276 of 323 teeth (85.4%) were successfully extracted using the vertical extraction system. The success rate varied between single-rooted teeth (87.2%, 251 of 288 teeth) and multirooted teeth (69.7%, 23 of 33 teeth). Extractions of multirooted teeth were 2.2 times more likely to fail than those of single-rooted teeth (risk ratio, 2.2; 95% CI, 1.3 to 4.0). Teeth with a history of root canal filling were 2.1 times more likely to result in failures (risk ratio, 2.1; 95% CI, 1.3 to 3.6). The lowest success rate (73.9%, 17 of 23 teeth) was observed in maxillary lateral incisors. Of the 47 failures in the vertical extraction system cohort, 18 required flap surgery, resulting in an overall incidence of flap surgery of 5.6% (95% CI, 3.2% to 8.7%) (18 of 323 teeth) in the vertical extraction system cohort (Figure 2).

During the routine care period, 1,719 teeth were extracted (223 anterior teeth, 299 premolars, 1,197 molars) using conventional tooth extraction techniques. Of the 522 anterior teeth and premolars, 94 teeth in 78 patients were deemed not suitable for forceps extraction and, therefore, met the inclusion criteria for this analysis (Table 2). Patients included 41 men with a mean age of 49 years (range, 19-85) and 37 women with a mean age of 54 years (range, 24-86). Most of the teeth were located in the maxilla (71.3%,  $n = 67$ ). Twenty-one teeth required flap surgery; therefore, the incidence of flap surgery was 22% (95% CI, 14 to 32) (Figure 2).

### DISCUSSION

In this interrupted time series study, we evaluated the application of the vertical extraction system for minimally invasive extraction of anterior teeth and premolars unsuitable for forceps extractions. We found a high success rate, as well as a lower incidence of flap surgery required, when using the vertical extraction system compared with conventional tooth extraction techniques. Furthermore, we identified several tooth characteristics—such as multirooted teeth and root canal fillings—as potential determinants of a reduced success rate of the vertical extraction system. These findings extend our previous study results<sup>27</sup> by using a larger sample size and allowing comparison with the conventional tooth extraction techniques.

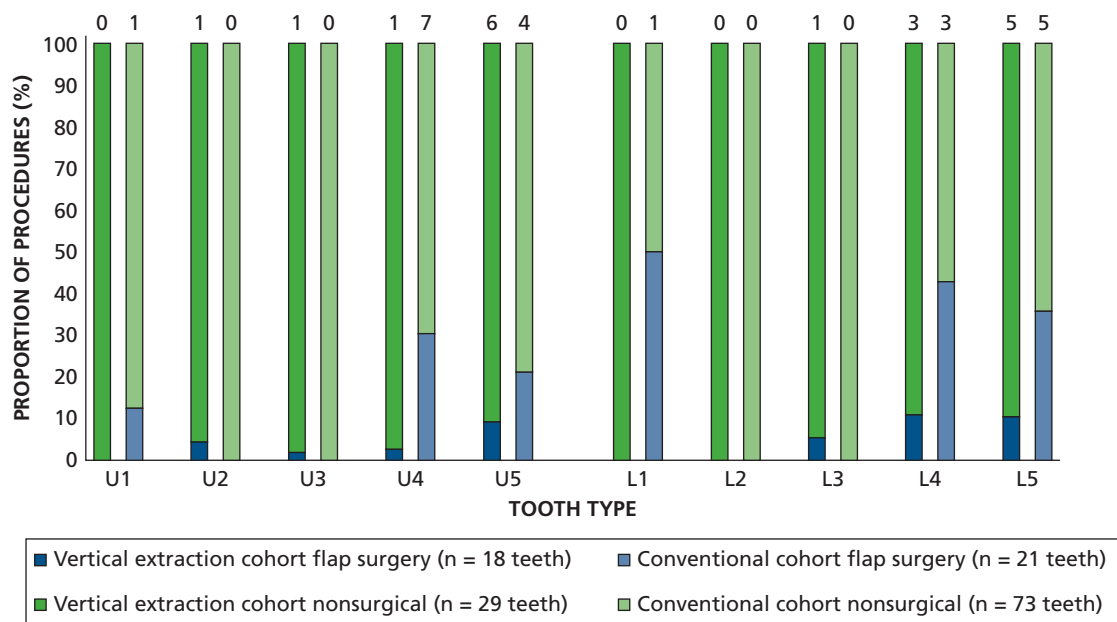
**Table 1.** Patient and tooth characteristics for teeth extracted (n = 323) in the vertical extraction cohort according to success and failure.

PARAMETER	SUCCESS (N = 276)	FAILURE (N = 47)	TOTAL (N = 323)	P VALUE
<b>Age, % (No.)*</b>				.168
≤ 50 y	47 (130)	36 (17)	46 (147)	
> 50 y	53 (146)	64 (30)	54 (176)	
<b>Sex, % (No.)</b>				.995
Male	64 (176)	64 (30)	64 (206)	
Female	36 (100)	36 (17)	36 (117)	
<b>Race or Ethnicity, % (No.)</b>				.165
White	74 (203)	64 (30)	72 (233)	
Other	26 (73)	36 (17)	28 (90)	
<b>Jaw Distribution, % (No.)</b>				.100
Maxilla	64 (177)	77 (36)	66 (213)	
Mandible	36 (99)	23 (11)	34 (110)	
<b>Tooth Type, % (No.)</b>				.005
Single-rooted	92 (251)	79 (37)	90 (288)	
Multirooted	8 (23)	21 (10)	10 (33)	
<b>History of Failed Extractions, % (No.)</b>				.311
Yes	14 (39)	9 (4)	13 (43)	
No	86 (237)	91 (43)	87 (280)	
<b>Radiograph, % (No.)</b>				.817
Yes	88 (244)	87 (41)	88 (285)	
No	12 (32)	13 (6)	12 (38)	
<b>Root Canal Filling, % (No.)</b>				.003
Yes	22 (61)	43 (20)	25 (81)	
No	78 (215)	57 (27)	75 (242)	

\* Number in some cells is smaller than total because of missing values.

The lower success rate of the vertical extraction system in multirooted teeth and teeth with a root canal filling is consistent with the typical failure modes observed with the vertical extraction system.<sup>27</sup> First, the morphology of the roots may be incompatible with an axial removal, particularly in cases of multirooted teeth with divergent roots. Second, root fractures and subsequent loss of screw retention will be more likely to occur in brittle teeth that are root filled or with gracile roots, such as individual roots of multirooted teeth or maxillary lateral incisors. The observed relatively higher failure rates for maxillary lateral incisors and maxillary premolars are also consistent with this explanation. However, whether the increased risk of experiencing fracture in endodontically treated teeth is due to changes in the mechanical properties of root dentine itself<sup>29</sup> or merely the result of loss of structural integrity<sup>30</sup> is controversial.

The literature on the incidence of flap surgery for dental extractions is scarce, but clinical experience and the existing literature indicate that a considerable proportion of dental extractions involve flap surgery. For example, in a study of patients with a history of radiation to the head and neck, 10% of dental extractions required elevation of a flap, and 11% required alveolectomy.<sup>31</sup> In a retrospective analysis of single tooth extractions of nonimpacted teeth, 17% of dental extractions required flap surgery.<sup>32</sup> In our study, we found that flap surgery was required in just over 1 in 5 (22%) anterior teeth and premolars with insufficient coronal tooth structure to allow forceps extraction. In comparison, when extraction was attempted with the vertical extraction system, just over 1 in 20 (6%) teeth required flap surgery. These results indicate that the use of the vertical extraction device may be associated with a marked reduction in the need



**Figure 2.** Incidence of flap surgery (%) and nonsurgical extraction (%) in the vertical tooth extraction system and conventional cohorts according to anterior and premolar maxillary and mandibular tooth type. The number of flap surgeries are shown above the bars. U: Maxillary. L: Mandibular.

to perform flap surgery for the removal of teeth not suitable for forceps extraction. Failure to retrieve a root or roots using a conventional approach—that is, using luxators or elevators—typically occurs when no point of application can be found and, hence, sufficient lateral and extrusive forces cannot be generated. It is, therefore, not surprising that conventional tooth extraction techniques are more likely to fail in the denser and more compact mandible compared with the maxilla<sup>33,34</sup> (Figure 2). The different principle of the vertical extraction system, which does not rely on a point of application and only applies vertical forces, makes these results highly plausible. Furthermore, use of the vertical extraction system is not limited to teeth not suitable

**Table 2.** Patient and tooth characteristics for teeth extracted (n = 323) in the vertical extraction system cohort and conventional cohort (n = 94) according to requirement for flap surgery.

PARAMETER	VERTICAL EXTRACTION SYSTEM COHORT (N = 323)			CONVENTIONAL COHORT (N = 94)		
	Flap Surgery			Flap Surgery		
	Yes	No	P value	Yes	No	P value
<b>Age, % (No.)*</b>			.462			.748
≤ 50 y	39 (7)	46 (140)		38 (8)	49 (36)	
> 50 y	61 (11)	54 (165)		62 (13)	51 (37)	
<b>Sex, % (No.)</b>			.712			.806
Male	67 (12)	64 (194)		52 (11)	52 (38)	
Female	33 (6)	36 (111)		48 (10)	48 (35)	
<b>Tooth Type, % (No.)</b>			.291			.111
Single-rooted	83 (15)	90 (273)		60 (12)	82 (59)	
Multirrooted	17 (3)	10 (30)		40 (8)	18 (13)	
<b>Root Canal Filling, % (No.)</b>			.075			.373
Yes	44 (8)	24 (73)		5 (1)	15 (11)	
No	56 (10)	76 (232)		95 (19)	85 (61)	

\* Number in some cells is smaller than total because of missing values.

for forceps extraction, as it may be desirable to minimize trauma to the bone and associated soft tissues when extracting any tooth.

Our findings show that the vertical extraction system has a high success rate in the anterior tooth and premolar areas, in which ridge preservation is important for both esthetic and functional purposes. However, this study has important limitations. First, like any observational study, this interrupted time series is susceptible to a range of possible biases, including but not limited to selection bias and confounding bias due to operator variability. However, all operators had several years' experience in oral surgery and exodontia and were trained in the application of the vertical extraction system. As the vertical extraction technique was adopted, treatment time decreased in the initial vertical extraction cohort; however, there was no evidence for a change in success rate.<sup>27</sup> Second, the high success rate of the vertical extraction system in itself does not serve as evidence that minimally invasive extractions lead to less postoperative morbidity or reduced postoperative ridge resorption. The results of this interrupted time series are encouraging and plausible. However, adequately powered randomized controlled clinical trials are warranted to confirm or otherwise the efficacy and effectiveness of the vertical extraction system to reduce the need for flap surgery and the degree of bone loss and bone resorption following tooth extraction.

## CONCLUSIONS

The results of this interrupted time series study suggest that the vertical extraction system may be used with a high success rate for extraction of teeth unsuitable for forceps extraction. Vertical tooth extractions are more likely to fail if teeth are multirrooted or have been root filled, and the use of the vertical extraction system may lead to a marked reduction in the need for flap surgery to extract destroyed teeth. Adequately powered randomized clinical trials are needed to confirm the findings of this observational study. ■

Dr. Hong is an academic clinical fellow, Department of Oral Surgery, Birmingham Dental Hospital, Birmingham, United Kingdom.

Dr. Bulsara is a specialty dentist, Department of Oral Surgery, Birmingham Dental Hospital, and a clinical lecturer, Department of Oral Surgery, School of Dentistry, University of Birmingham, Birmingham, United Kingdom.

Dr. Gorecki is a clinical lecturer, Department of Oral Surgery, School of Dentistry, University of Birmingham, Birmingham, United Kingdom.

Dr. Dietrich is professor and head, Department of Oral Surgery, School of Dentistry, University of Birmingham, 5 Mill Pool Way, Birmingham, B5 7EG,

United Kingdom, e-mail [t.dietrich@bham.ac.uk](mailto:t.dietrich@bham.ac.uk). Address correspondence to Dr. Dietrich.

**Disclosure.** None of the authors reported any disclosures.

This study was funded solely by the authors' institutions.

No external funding was obtained. The authors acknowledge Helmut Zepf Medizintechnik, Tuttlingen, Germany, for providing the Benex equipment, and Bien-Air Dental, Bienne, Switzerland, for providing handpieces.

- Schropp L, Wenzel A, Kostopoulos L, Karring T. Bone healing and soft tissue contour changes following single-tooth extraction: a clinical and radiographic 12-month prospective study. *Int J Periodontics Restorative Dent.* 2003;23(4):313-323.
- Van der Weijden F, Dell'Acqua F, Slot DE. Alveolar bone dimensional changes of post-extraction sockets in humans: a systematic review. *J Clin Periodontol.* 2009;36(12):1048-1058.
- Tan WL, Wong TL, Wong MC, Lang NP. A systematic review of post-extraction alveolar hard and soft tissue dimensional changes in humans. *Clin Oral Implants Res.* 2012;23(suppl 5):1-21.
- Chan HL, Lin GH, Fu JH, Wang HL. Alterations in bone quality after socket preservation with grafting materials: a systematic review. *Int J Oral Maxillofac Implants.* 2013;28(3):710-720.
- Babbush CA. A new atraumatic system for tooth removal and immediate implant restoration. *Implant Dent.* 2007;16(2):139-145.
- Quayle AA. Atraumatic removal of teeth and root fragments in dental implantology. *Int J Oral Maxillofac Implants.* 1990;5(3):293-296.
- Mecall RA, Rosenfeld AL. Influence of residual ridge resorption patterns on implant fixture placement and tooth position. *Int J Periodontics Restorative Dent.* 1991;11(1):8-23.
- Saldanha JB, Casati MZ, Neto FH, Sallum EA, Nociti FH Jr. Smoking may affect the alveolar process dimensions and radiographic bone density in maxillary extraction sites: a prospective study in humans. *J Oral Maxillofac Surg.* 2006;64(9):1359-1365.
- Chen ST, Wilson TG Jr, Hämmerle CH. Immediate or early placement of implants following tooth extraction: review of biologic basis, clinical procedures, and outcomes. *Int J Oral Maxillofac Implants.* 2004;(19 suppl):12-25.
- Brägger U, Schild U, Lang NP. Effect of chlorhexidine (0.12%) rinses on periodontal tissue healing after tooth extraction, (II): radiographic parameters. *J Clin Periodontol.* 1994;21(6):422-430.
- Botticelli D, Berglundh T, Lindhe J. Hard-tissue alterations following immediate implant placement in extraction sites. *J Clin Periodontol.* 2004;31(10):820-828.
- Herrera JM, Zöller JE, Steveling H. Alveolar process resorption after tooth extraction with 2 different extraction methods: a comparative study [in German]. *Quintessenz.* 2001;52(9):863-868.
- Oghli AA, Steveling H. Ridge preservation following tooth extraction: a comparison between atraumatic extraction and socket seal surgery. *Quintessenz Int.* 2010;41(7):605-609.
- Araújo MG, Lindhe J. Ridge alterations following tooth extraction with and without flap elevation: an experimental study in the dog. *Clin Oral Implants Res.* 2009;20(6):545-549.
- Fickl S, Zühr O, Wachtel H, Bolz W, Huerzeler M. Tissue alterations after tooth extraction with and without surgical trauma: a volumetric study in the beagle dog. *J Clin Periodontol.* 2008;35(4):356-363.
- Wood DL, Hoag PM, Donnenfeld OW, Rosenfeld LD. Alveolar crest reduction following full and partial thickness flaps. *J Periodontol.* 1972;43(3):141-144.
- Ramfjord SP, Costich ER. Healing after exposure of periodontium on the alveolar process. *J Periodontol.* 1968;39(4):199-207.
- Parmigliani-Izquierdo JM, Sánchez-Pérez A, Cabaña-Muñoz ME. A pilot study of postoperative pain felt after two implant surgery techniques: a randomized blinded prospective clinical study. *Int J Oral Maxillofac Implants.* 2013;28(5):1305-1310.
- Oh TJ, Shotwell J, Billy E, Byun HY, Wang HL. Flapless implant surgery in the esthetic region: advantages and precautions. *Int J Periodontics Restorative Dent.* 2007;27(1):27-33.
- Regev E, Lustmann J, Nashef R. Atraumatic teeth extraction in bisphosphonate-treated patients. *J Oral Maxillofac Surg.* 2008;66(6):1157-1161.
- McCulloch P, Altman DG, Campbell WB, et al. No surgical innovation without evaluation: the IDEAL recommendations. *Lancet.* 2009;374(9695):1105-1112.



22. Ergina PL, Cook JA, Blazeby JM, et al. Challenges in evaluating surgical innovation. *Lancet*. 2009;374(9695):1097-1104.
23. Buffi NM, Lughezzani G, Fossati N, et al. Robot-assisted, single-site, dismembered pyeloplasty for ureteropelvic junction obstruction with the new da Vinci platform: a stage 2a study. *Eur Urol*. 2015;67(1):151-156.
24. Nikkels C, Vervoort AJMW, Mol BW, Hehenkamp WJK, Huirne JAF, Brölmann HAM. IDEAL framework in surgical innovation applied on laparoscopic niche repair. *Eur J Obstet Gynecol Reprod Biol*. 2017;215:247-253.
25. Diez del Val I, Loureiro C, McCulloch P. The IDEAL prospective development study format for reporting surgical innovations: an illustrative case study of robotic oesophagectomy. *Int J Surg*. 2015;19:104-111.
26. Menon M, Abaza R, Sood A, et al. Robotic kidney transplantation with regional hypothermia: evolution of a novel procedure utilizing the IDEAL guidelines (IDEAL phase 0 and 1). *Eur Urol*. 2014;65(5):1001-1009.
27. Muska E, Walter C, Knight A, et al. Atraumatic vertical tooth extraction: a proof of principle clinical study of a novel system. *Oral Surg Oral Med Oral Pathol Oral Radiol*. 2013;116(5):e303-e310.
28. Saund D, Dietrich T. Minimally-invasive tooth extraction: doorknobs and strings revisited! *Dent Update*. 2013;40(3):325-326, 328-330.
29. Sedgley CM, Messer HH. Are endodontically treated teeth more brittle? *J Endod*. 1992;18(7):332-335.
30. Lang H, Korkmaz Y, Schneider K, Raab WH. Impact of endodontic treatments on the rigidity of the root. *J Dent Res*. 2006;85(4):364-368.
31. Sulaiman F, Huryn JM, Zlotolow IM. Dental extractions in the irradiated head and neck patient: a retrospective analysis of Memorial Sloan-Kettering Cancer Center protocols, criteria, and end results. *J Oral Maxillofac Surg*. 2003;61(10):1123-1131.
32. Hong B, Birnie A. A retrospective analysis of episodes of single tooth extraction under general anaesthesia for adults. *Br Dent J*. 2016;220(1):21-24.
33. Lekholm U, Zarb GA. Patient selection and preparation. In: Brånemark PI, Zarb GA, Albrektsson T, eds. *Tissue-Integrated Prosthesis: Osseointegration in Clinical Dentistry*. Chicago, IL: Quintessence; 1985:199-209.
34. Ko YC, Huang HL, Shen YW, Cai JY, Fuh LJ, Hsu JT. Variations in crestal cortical bone thickness at dental implant sites in different regions of the jawbone. *Clin Implant Dent Relat Res*. 2017;19(3):440-446.