

UNIVERSITY OF BIRMINGHAM

Research at Birmingham

Osteomyelitis of the jaw (with pathological fracture) following extraction of an impacted wisdom tooth. A Case Report

González-Navarro, B; Arranz-Obispo, C; Albuquerque, Rui; Jané-Salas, E; López-López, J

DOI:

[10.1016/j.jormas.2017.05.003](https://doi.org/10.1016/j.jormas.2017.05.003)

License:

Creative Commons: Attribution-NonCommercial-NoDerivs (CC BY-NC-ND)

Document Version

Peer reviewed version

Citation for published version (Harvard):

González-Navarro, B, Arranz-Obispo, C, Albuquerque, R, Jané-Salas, E & López-López, J 2017, 'Osteomyelitis of the jaw (with pathological fracture) following extraction of an impacted wisdom tooth. A Case Report', Journal of stomatology, oral and maxillofacial surgery. <https://doi.org/10.1016/j.jormas.2017.05.003>

[Link to publication on Research at Birmingham portal](#)

Publisher Rights Statement:

Checked for eligibility: 07/06/2017

General rights

Unless a licence is specified above, all rights (including copyright and moral rights) in this document are retained by the authors and/or the copyright holders. The express permission of the copyright holder must be obtained for any use of this material other than for purposes permitted by law.

- Users may freely distribute the URL that is used to identify this publication.
- Users may download and/or print one copy of the publication from the University of Birmingham research portal for the purpose of private study or non-commercial research.
- User may use extracts from the document in line with the concept of 'fair dealing' under the Copyright, Designs and Patents Act 1988 (?)
- Users may not further distribute the material nor use it for the purposes of commercial gain.

Where a licence is displayed above, please note the terms and conditions of the licence govern your use of this document.

When citing, please reference the published version.

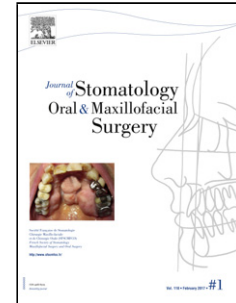
Take down policy

While the University of Birmingham exercises care and attention in making items available there are rare occasions when an item has been uploaded in error or has been deemed to be commercially or otherwise sensitive.

If you believe that this is the case for this document, please contact UBIRA@lists.bham.ac.uk providing details and we will remove access to the work immediately and investigate.

Accepted Manuscript

Title: Osteomyelitis of the jaw (with pathological fracture) following extraction of an impacted wisdom tooth. A Case Report<!--<RunningTitle>Osteomyelitis of the jaw following extraction. A case report</RunningTitle-->



Author: B. González-Navarro C. Arranz-Obispo R. Albuquerque E. Jané-Salas J. López-López

PII: S2468-7855(17)30093-9
DOI: <http://dx.doi.org/doi:10.1016/j.jormas.2017.05.003>
Reference: JORMAS 48

To appear in:

Received date: 17-3-2017
Accepted date: 21-5-2017

Please cite this article as: B. González-Navarro C. Arranz-Obispo R. Albuquerque E. Jané-Salas J. López-López Osteomyelitis of the jaw (with pathological fracture) following extraction of an impacted wisdom tooth. A Case Report<!--<RunningTitle>Osteomyelitis of the jaw following extraction. A case report</RunningTitle--> (2017), <http://dx.doi.org/10.1016/j.jormas.2017.05.003>

This is a PDF file of an unedited manuscript that has been accepted for publication. As a service to our customers we are providing this early version of the manuscript. The manuscript will undergo copyediting, typesetting, and review of the resulting proof before it is published in its final form. Please note that during the production process errors may be discovered which could affect the content, and all legal disclaimers that apply to the journal pertain.

Osteomyelitis of the jaw (with pathological fracture) following extraction of an impacted wisdom tooth. A Case Report.

Short title: Osteomyelitis of the jaw following extraction. A case report.

Authors' affiliations:

B. González-Navarro^a, C. Arranz-Obispo^b, R. Albuquerque^c, E. Jané- Salas^d, J. López-López^{e, *}.

^a DDS. Lecturer of the Master's degree in Oral Implantology, Medicine and Surgery (University of Barcelona). / IDIBELL (Barcelona, Spain) Email: beatrizgonzaleznavarro@gmail.com

^b DDS, MD, Oral and Maxillofacial Surgery Specialist (Bellvitge University Hospital). Lecturer of the Master's degree in Oral Implantology, Medicine and Surgery (University of Barcelona) / IDIBELL (Barcelona., Spain) Email: carranz@bellvitgehospital.cat

^c DDS, MS, PhD. Academic Clinical Lecturer. Birmingham Dental Hospital/ School of Dentistry, University of Birmingham (Birmingham, United Kingdom) Email: R.P.P.D.Albuquerque@bham.ac.uk

^d DDS, PhD, MD, Stomatologist. Lecturer of the Master's degree in Oral Implantology, Medicine and Surgery (University of Barcelona) / IDIBELL (Barcelona., Spain) Email: enjasa19734@gmail.com

^e DDS, PhD, MD, Stomatologist. Lecturer of the Master's degree in Oral Implantology, Medicine and Surgery (University of Barcelona) / IDIBELL (Barcelona., Spain) Email: 18575jll@gmail.com

***Corresponding autor:**

José López-López

Bellvitge University Campus, Department of Odontostomatology

Universitat de Barcelona, Pabellón de Gobierno 2^a Planta

C/ Feixa Llarga s/n 08907 L'Hospitalet de Llobregat, Barcelona (Spain)

18575jll@gmail.com

1
2
3
4
5
6
7
8
9
10
11
12
13
14
15
16
17
18
19
20
21
22
23
24
25
26
27
28
29
30
31
32
33
34
35
36
37
38
39
40
41
42
43
44
45
46
47
48
49
50
51
52
53
54
55
56
57
58
59
60
61
62
63
64
65

Osteomyelitis of the jaw (with pathological fracture) following extraction of an impacted wisdom tooth. A Case Report.

Short Title: Osteomyelitis of the jaw following extraction. A case report.

ABSTRACT

Osteomyelitis is an infection and inflammation associated with the bone structures: bone marrow, cortical bone, periosteum, blood vessels and nerves. Although it does not have a frequent presentation, it can sometimes lead to complications such as pathological fractures or even septicemia. We present a clinical case study, to assess the relationship between osteomyelitis of the jaw and pathological fractures, after the extraction of an impacted wisdom tooth. This case highlights a rare complication following the surgical removal of mandibular third molar; a slow evolution of the pathology following an extraction should lead to close monitoring of the patient both clinically and radiographically, albeit osteomyelitis is a rare complication it should be included as one of the differential diagnosis of persistent post extraction pain.

Keywords: Fracture; Impacted; Molar; Osteomyelitis; Pain

INTRODUCTION

1
2 Osteomyelitis is a rare disease within the dental environment. It involves an infection
3
4 and inflammation of the bone structures when microorganisms invade bones. The most
5
6 frequently found microorganism is *Staphylococcus aureus* (over 60 % of the cases), but
7
8 others include: *streptococci*, *enterococci*, *pseudomonas*, *enterobacter* and some
9
10 anaerobic bacteria (*peptoestreptococci*, *clostridium*, etc.) It can appear as a complication
11
12 of any infection, but there is generally one single infection site [1]. Osteomyelitis can
13
14 develop as a result of three etiologies: bacteria spreading from the adjacent areas, direct
15
16 inoculation of the microorganism (trauma or surgery) and haematogenous spread [2]. A
17
18 serious complication of osteomyelitis is the pathological fracture of the bone due to a
19
20 weakened bone structure. Management of this complication requires setting or reducing
21
22 the fracture and treatment with antibiotics [3].
23
24
25
26
27
28
29
30
31
32
33

CASE REPORT

34
35
36 A 60-year old male presented to the University of Barcelona (UB) Dental Hospital
37
38 (Master's degree in Oral Implantology, Medicine and Surgery, Faculty of Odontology)
39
40 with a primary complaint of discomfort for the last 3 months, located in his lower right
41
42 wisdom tooth. His medical history revealed: hypertension, depression, dyslipidemia and
43
44 prostate cancer diagnosed in 2002 (treated with radiotherapy and hormone therapy until
45
46 2005). He had no known allergies and smoked 6-7 cigars per day. His current
47
48 medication included enalapril, simvastatin, omeprazol and venlafaxine.
49
50
51
52

53 On intraoral examination signs of chronic, advanced and uncontrolled adult periodontal
54
55 disease were seen, also the right mandibular third molar was completely unerupted and
56
57 radiographic evaluation showed that it was impacted (Fig. 1), because of his symptoms
58
59
60
61
62
63
64
65

1 and radiographic evidence, a diagnosis of pericoronitis was made and the treatment
2 decision was to surgically remove the affected tooth. The patient was given prophylactic
3 antibiotic cover (2 g of amoxicillin 1 hour prior to surgery), and then exodontia was
4 performed under local anaesthetic with articaine 4 % (1:100000). The method involved:
5 local anaesthesia, surgical incision, elevation of a mucoperiosteal flap, ostectomy, tooth
6 sectioning, dislocation, avulsion, curettage, irrigation with saline solution and suturing
7 (5 stitches with 3-0 silk).
8
9

10 Having observed the mobility of the right mandibular second molar, an exodontia of
11 that tooth was suggested as part of the same procedure, but the patient preferred to wait
12 and see how the tooth progressed before deciding whether to undergo the extraction.
13
14 Antibiotics and painkillers were prescribed after the surgery: amoxicillin (1 g
15 every 8 hours, over 7 days), ibuprofen (600 mg every 8 hours over 3-5 days),
16 paracetamol (1 g every 8 hours if a breakthrough dose was needed), omeprazol (20 mg
17 once a day for a week, on an empty stomach) and regular mouth rinses with
18 chlorhexidine 0.12 % every 12 hours over 7 days.
19
20
21
22
23
24
25
26
27
28
29
30
31
32
33
34
35
36
37
38

39 One week post operatively, the patient returned for a follow up and reported trismus
40 with a maximum interincisal opening (MIO) of 24 mm and pain (VAS: Visual Analogic
41 Scale: 9/10). The sutures were removed and chlorhexidine 0.12 % was recommended to
42 be used every 12 hours, for a further week. After 2 weeks, the patient's pain (VAS 8/10)
43 and trismus (MIO 28 mm) persisted. Upon clinical inspection, the surgical site had a
44 good appearance without inflammation. A post-extraction control panoramic radiograph
45 was ordered, in which a tooth socket with no alterations was observed (Fig. 2). A
46 tentative diagnosis of dry socket (Alveolitis) was made. We therefore prescribed
47 amoxicillin/ clavulanic acid (Augmentine® 875-125 mg every 8 hours over 1 week),
48
49
50
51
52
53
54
55
56
57
58
59
60
61
62
63
64
65

1
2
3
4
5
6
7
8
9
10
11
12
13
14
15
16
17
18
19
20
21
22
23
24
25
26
27
28
29
30
31
32
33
34
35
36
37
38
39
40
41
42
43
44
45
46
47
48
49
50
51
52
53
54
55
56
57
58
59
60
61
62
63
64
65

diclofenac (50 mg every 8 hours over 7 days) and recommended further mouth rinses with chlorhexidine (same dosage as above). One week later, the pain and trismus symptoms had abated (VAS 3/10 and MIO 35 mm). At five-week review, the surgery site had a good appearance but the patient reported tenderness on the masseter muscle (VAS 6/10). The diagnosis was myositis of the masseter muscle and this was treated with tetrazepam (Myolastan®, 50 mg once a day over 7 days). Five days later, the patient returned for consultation and reported severe pain (VAS 10/10). Given the slow evolution of the case history, the patient was referred to the Maxillofacial Surgery Service at the Bellvitge University Hospital. At hospital admission, the patient reported severe pain. Clinical examination showed no masseteric/temporal contracture or surgical site. When applying pressure on the affected site, a slight seropurulent exudate was observed, with no evidence of bony “step-offs”. Radiographic examination including a panoramic radiograph and a CT scan (computerised tomography); revealed a rarefaction area where the surgery was performed which suggested osteomyelitis also a fracture line in the right angle of the mandible was detected (Fig. 3A and 3B). Based on the clinical case history, surgical treatment was carried out to reduce and fixate the fractured fragments (Figs. 4A and 4B). Curettage of the surgical site was performed and samples were sent to the Microbiology and Anatomical Pathology Service. The patient was prescribed moxifloxacin (400 mg every 24 hours over 8 weeks) and metronidazol (500 mg every 8 hours over 1 month).

The results from the sample showed evidence of bone sequestration, and colonies of *Peptostreptococcus prevotii*, anaerobic cocci, and Gram-positive bacteria. Final diagnosis was osteomyelitis of the mandible with pathological fracture secondary to the extraction of the right mandibular third molar. Four months post-surgery and antibiotic

1 treatment, the patient has made good progress and reported no further signs or
2 symptoms, also new bone formation within the fractured area was evident on CT scan
3
4 (Figs. 5 and 6).
5
6
7
8

9 **DISCUSSION**

10 Extraction of mandibular third molars is one of the most commonly performed
11 procedures by oral and maxillofacial surgeons. Most of these procedures have no
12 intraoperative or postoperative complications, although they may arise in a percentage
13 of cases (4.6 %-30.9 %) [3-5].
14
15
16
17
18
19
20
21
22
23

24 Osteomyelitis of the jaw after the extraction of a tooth in the lower jaw is a rarely
25 described pathology in scientific literature [2,6]. The most common causes of
26 osteomyelitis are trauma (fracture, surgery), pulpal and/or periodontal dentoalveolar
27 infections [7]. The onset of osteomyelitis of the jaw can be due to a periodontal
28 infection within the mandibular right second molar (bacteria spreading from the
29 adjacent areas), or caused by a direct inoculation of the microorganism at the time of
30 surgery [3,4].
31
32
33
34
35
36
37
38
39
40
41
42
43

44 Fracture of the mandible following extraction of a third molar is a very rare event
45 occurring in 0.003% to 0.005% of cases [3,7,8]. In their bibliographic review, Boffano
46 et al.[3] remarked that most of these fractures (74%) occur in the first three weeks of the
47 postoperative period, and 26% occur during surgery. Several risk factors can be
48 associated with these fractures, in particular age, gender, type of impaction, previous
49 infections and the extent of ostectomy [3]. Most texts refer to trauma as the most
50 common cause of fracture of the jaw (2% of all pathological fractures). Gerhards et al.'s
51
52
53
54
55
56
57
58
59
60
61
62
63
64
65

1 study [9] presents 30 pathological fractures, 50% of those fractures had an infectious
2 etiology. Coletti & Ord [10] presented a series of 44 pathological fractures and
3 remarked that 19% were due to osteomyelitis, being this less prevalent than
4 osteoradionecrosis (49%). Wagner et al. [11] presented 17 patients with fractures of the
5 jaw after extractions of third molars. In 82% of the cases (13 cases), the fracture
6 occurred days after surgery and in six of these cases, the fracture was not visible on the
7 X-ray taken during the first control visit. Bormann KH et al.'s [12] review based on 444
8 fractures of the jaw emphasises that 4% were due to pathological fractures. Within this
9 small percentage, 49% occurred after the extraction of a third molar in the lower jaw,
10 and 13% were due to osteomyelitis and other causes.
11
12
13
14
15
16
17
18
19
20
21
22
23
24
25

26 The literature reveals similar cases to the one presented in this article. O'Sullivan et al.
27 [13] presented a case of a 72 -year-old patient with a failed implant in the interforaminal
28 region. Once the implant was removed, osteomyelitis developed and led to a fracture of
29 the jaw. Ogasawara et al. [14] reported a case where a 43 -year-old male suffered from
30 osteomyelitis three months after the extraction of the left mandibular first molar. In
31 regard to the microbiological study of the curettage area, *Peptostreptococcus prevotii* is
32 an anaerobic, Gram-positive bacteria present in patients with generalised periodontal
33 disease which correlates with the characteristics of our patient [15].
34
35
36
37
38
39
40
41
42
43
44
45
46
47
48
49
50
51
52
53
54
55
56
57
58
59
60
61
62
63
64
65

To conclude, one of the most frequent causes of pathological fracture of the jaw is the
presence of osteomyelitis. The most frequent origin of the infection is from bacterial
dissemination from adjacent areas, especially in patients with advanced periodontal
disease. An early diagnosis of osteomyelitis of the jaw is essential to avoid serious
complications. The slow progression of symptoms following the extraction of a third

1 molar must be closely monitored both clinically and radiographically. In this case,
2 based on our assessment, we believe there are two possible pathogenic approaches to
3 the condition. The first one would be the onset of an osteomyelitis of the jaw after the
4 extraction of the right mandibular third molar. This procedure produced an unperceived
5 infection of the tissues that could not be controlled with the prescribed antibiotics,
6 prolonging the duration of the infection subsequently weakening the bone and resulting
7 in a fracture. The second approach would involve a fissured fracture at the time of
8 performing the exodontia of the right mandibular third molar but a fissured fracture
9 would evolve over time into a fracture of the jaw, creating an infection of the
10 surrounding tissue and consequentially cause an osteomyelitis - we believe this second
11 option can be ruled out. Especially since during surgery and on the subsequent
12 panoramic radiograph, no fissured fracture line was detected and the patient did not
13 report a “crack” either during surgery or in the following weeks until being admitted to
14 hospital.

35 **DISCLOSURE OF INTEREST**

36 The authors declare that they have no competing interest.

42 **FUNDING**

43 This research did not receive any specific grant from funding agencies in the public,
44 commercial, or not-for-profit sectors.

52 **REFERENCES**

- 53 [1] Lukošūnas A, Kubilius R, Sabalys G, Keizeris T, Sakavičius D. An analysis of
54 etiological factors for traumatic mandibular osteomyelitis. *Medicina (Kaunas)*
55

- 2011;47:380–5.
- 1
2 [2] Humber CC, Albilia JB, Rittenberg B. Chronic osteomyelitis following an
3
4 uncomplicated dental extraction. *J Can Dent Assoc* 2011;77:b98.
5
6
- 7 [3] Boffano P, Rocchia F, Gallesio C, Berrone S. Pathological mandibular fractures: a
8
9 review of the literature of the last two decades. *Dent Traumatol* 2013;29:185–96.
10
11 doi:10.1111/edt.12028.
12
13
- 14 [4] Bouloux GF, Steed MB, Perciaccante VJ. Complications of Third Molar Surgery.
15
16 *Oral Maxillofac Surg Clin North Am* 2007;19:117–28.
17
18 doi:10.1016/j.coms.2006.11.013.
19
20
- 21 [5] Blondeau F, Daniel NG. Extraction of impacted mandibular third molars:
22
23 postoperative complications and their risk factors. *J Can Dent Assoc*
24
25 2007;73:325.
26
27
- 28 [6] Schoen R, Suarez-Cunqueiro MM, Metzger MC, Schmelzeisen R. Osteomyelitis
29
30 of the mandible following third molar surgery: a regrettable consequence in a
31
32 healthy patient. *Quintessence Int* 2009;40:351–4.
33
34
- 35 [7] Cutilli T, Bourelaki T, Scarsella S, Fabio D Di, Pontecorvi E, Cargini P, et al.
36
37 Pathological (late) fractures of the mandibular angle after lower third molar
38
39 removal: a case series. *J Med Case Rep* 2013;7:121. doi:10.1186/1752-1947-7-
40
41 121.
42
43
- 44 [8] Ethunandan M, Shanahan D, Patel M. Iatrogenic mandibular fractures following
45
46 removal of impacted third molars: an analysis of 130 cases. *BDJ* 2012;212:179–
47
48 84. doi:10.1038/sj.bdj.2012.135.
49
50
- 51 [9] Gerhards F, Kuffner HD, Wagner W. Pathological fractures of the mandible. A
52
53 review of the etiology and treatment. *Int J Oral Maxillofac Surg* 1998;27:186–90.
54
55
- 56 [10] Coletti D, Ord RA. Treatment rationale for pathological fractures of the
57
58
59
60
61
62
63
64
65

mandible: a series of 44 fractures. *Int J Oral Maxillofac Surg* 2008;37:215–22.

doi:10.1016/j.ijom.2007.09.176.

- [11] Wagner KW, Otten J-E, Schoen R, Schmelzeisen R. Pathological mandibular fractures following third molar removal. *Int J Oral Maxillofac Surg* 2005;34:722–6. doi:10.1016/j.ijom.2005.03.003.
- [12] Bormann K-H, Wild S, Gellrich N-C, Kokemüller H, Stühmer C, Schmelzeisen R, et al. Five-Year Retrospective Study of Mandibular Fractures in Freiburg, Germany: Incidence, Etiology, Treatment, and Complications. *J Oral Maxillofac Surg* 2009;67:1251–5. doi:10.1016/j.joms.2008.09.022.
- [13] O’Sullivan D, King P, Jagger D. Osteomyelitis and pathological mandibular fracture related to a late implant failure: a clinical report. *J Prosthet Dent* 2006;95:106–10. doi:10.1016/j.prosdent.2005.10.014.
- [14] Ogasawara T, Sano K, Hatsusegawa C, Miyauchi K, Nakamura M, Matsuura H. Pathological fracture of the mandible resulting from osteomyelitis successfully treated with only intermaxillary elastic guiding. *Int J Oral Maxillofac Surg* 2008;37:581–3. doi:10.1016/j.ijom.2007.11.006.
- [15] Leung WK, Jin LJ, Samaranayake LP, Chiu GK. Subgingival microbiota of shallow periodontal pockets in individuals after head and neck irradiation. *Oral Microbiol Immunol* 1998;13:1–10.

FIGURES

1
2
3
4
5
6
7
8
9
10
11
12
13
14
15
16
17
18
19
20
21
22
23
24
25
26
27
28
29
30
31
32
33
34
35
36
37
38
39
40
41
42
43
44
45
46
47
48
49
50
51
52
53
54
55
56
57
58
59
60
61
62
63
64
65

Fig. 1. Initial panoramic radiograph of the patient, revealing an impacted right lower third molar.

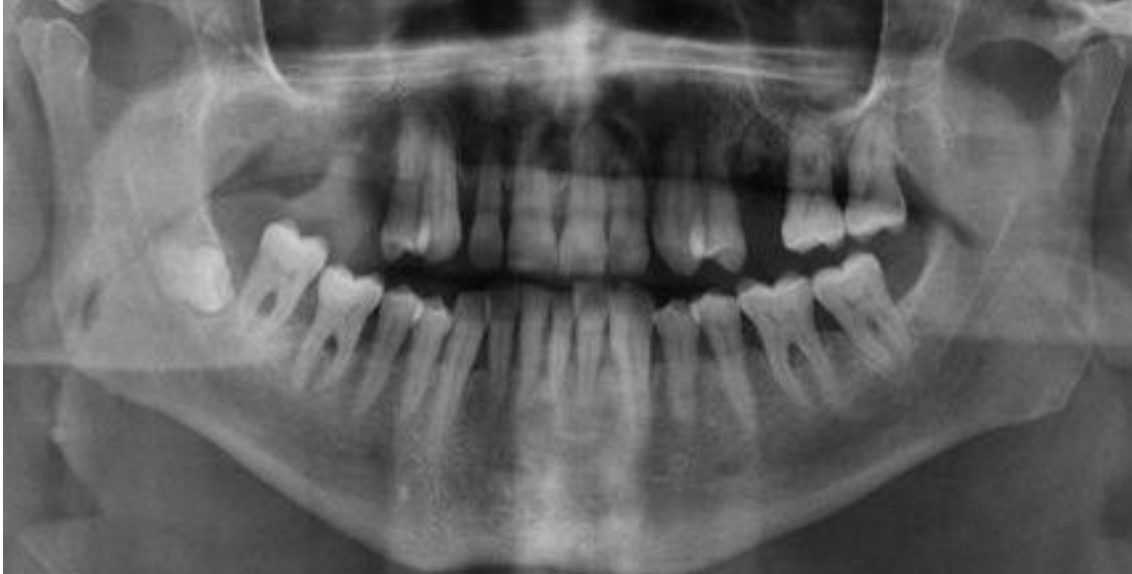
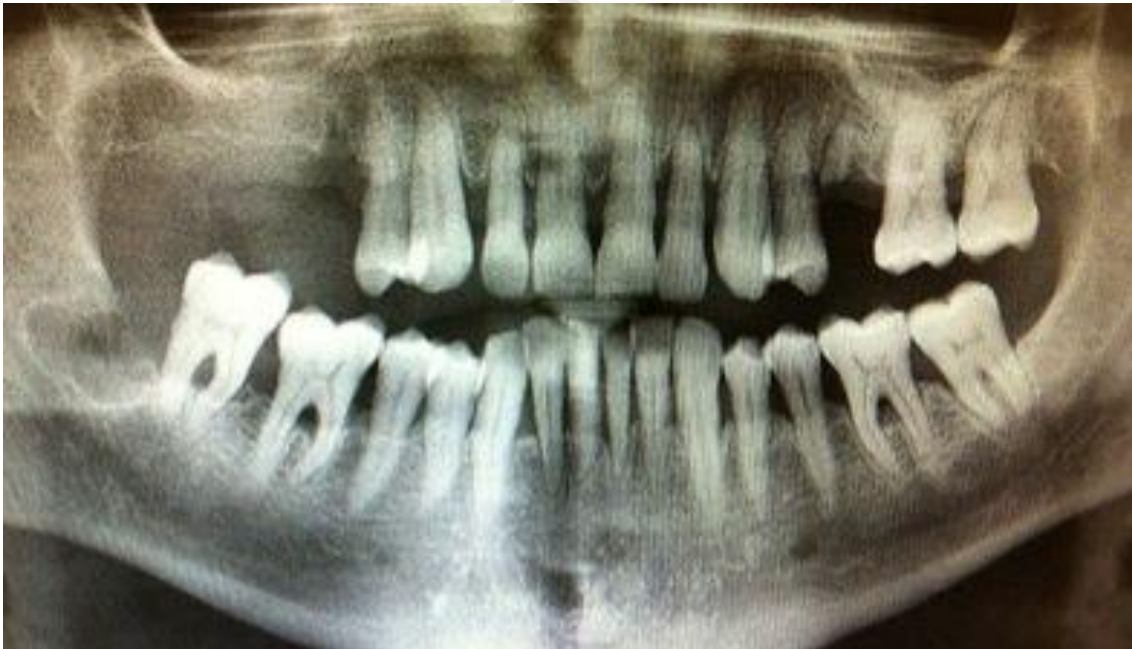
Fig. 2. Panoramic radiograph 2 weeks after the extraction, where no alterations can be observed.



1
2
3
4
5
6
7
8
9
10
11
12
13
14
15
16
17
18
19
20
21
22
23
24
25
26
27
28
29
30
31
32
33
34
35
36
37
38
39
40
41
42
43
44
45
46
47
48
49
50
51
52
53
54
55
56
57
58
59
60
61
62
63
64
65

Fig. 3. Panoramic radiograph where a rarefaction area and a fracture line in the right angle of the jaw can be observed (A). CT where the same rarefaction area and a fracture line can be observed (B).

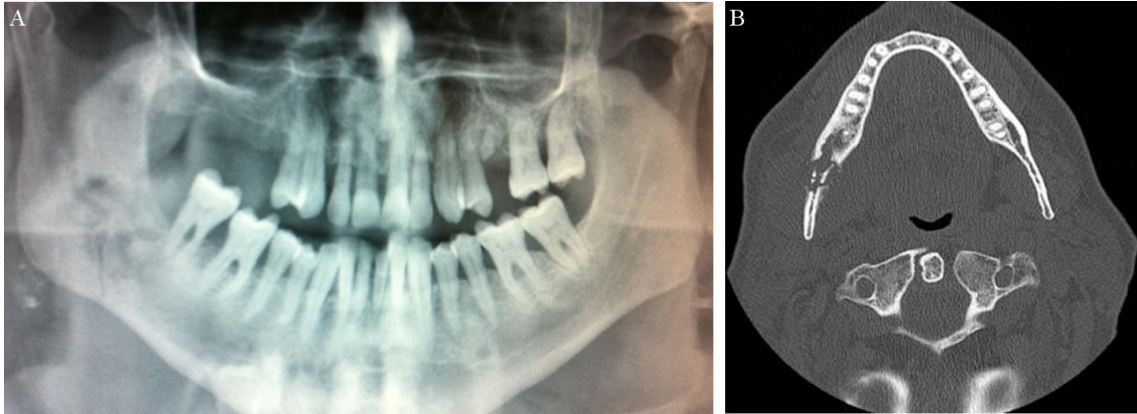
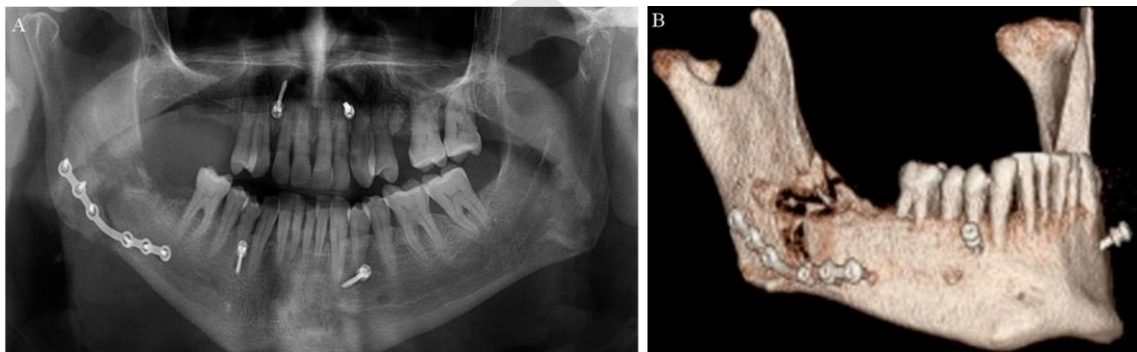


Fig. 4. A control panoramic radiograph performed 2 weeks after surgery (A).
Mandibular reconstruction 2 weeks after surgery (B).



1
2
3
4
5
6
7
8
9
10
11
12
13
14
15
16
17
18
19
20
21
22
23
24
25
26
27
28
29
30
31
32
33
34
35
36
37
38
39
40
41
42
43
44
45
46
47
48
49
50
51
52
53
54
55
56
57
58
59
60
61
62
63
64
65

Fig. 5. CT 4 months after surgery, showing evidence of new bone formation.

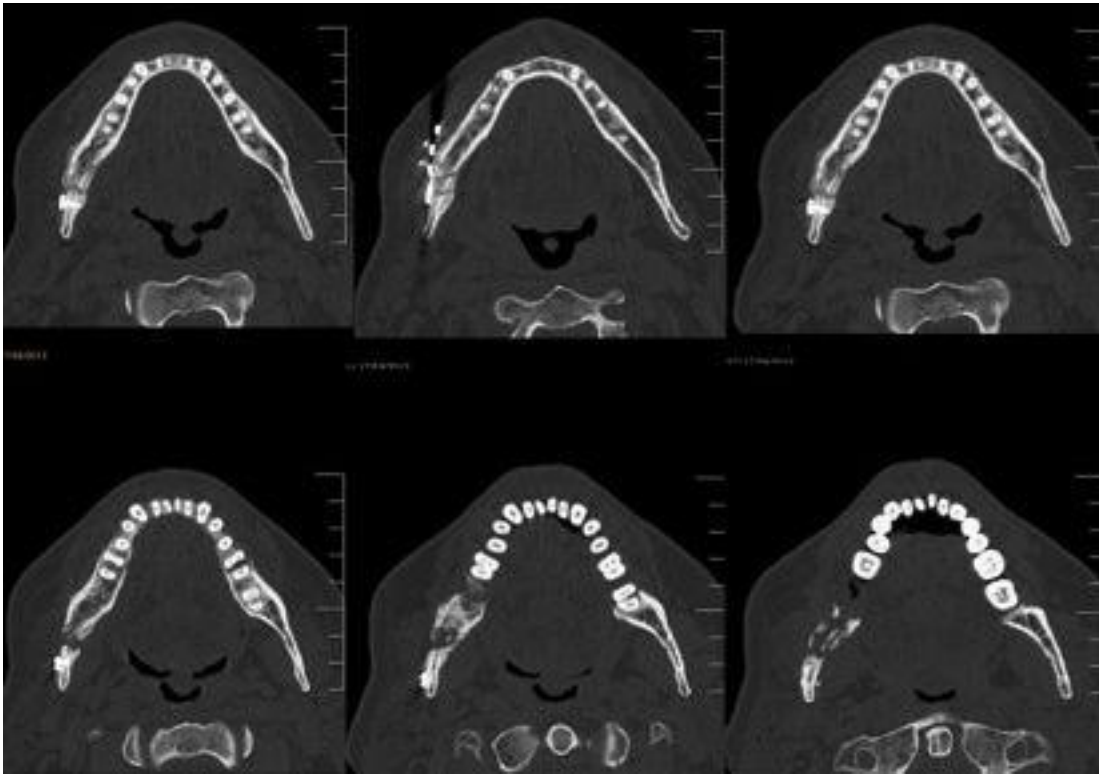


Fig. 6. Mandibular reconstruction 4 months after surgery, showing evidence of new bone formation.

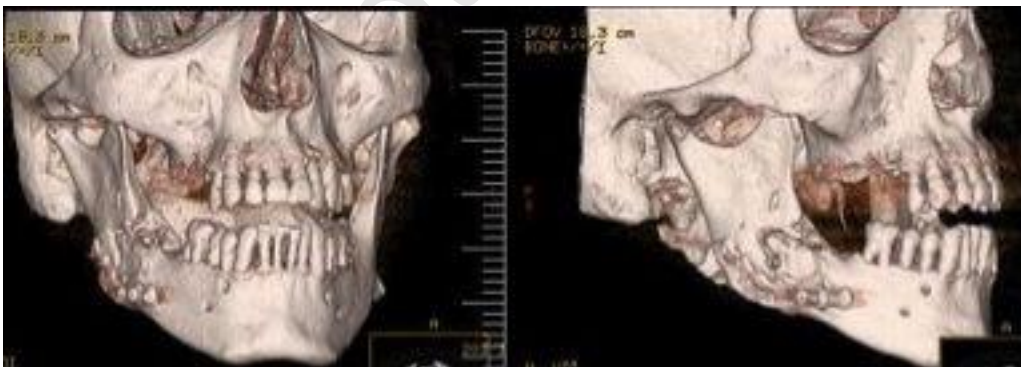

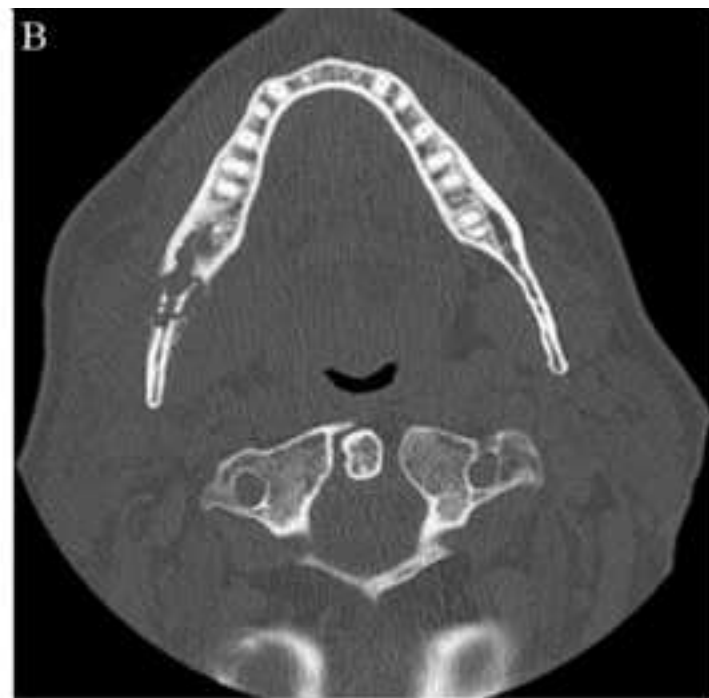
Figure 1
[Click here to download high resolution image](#)

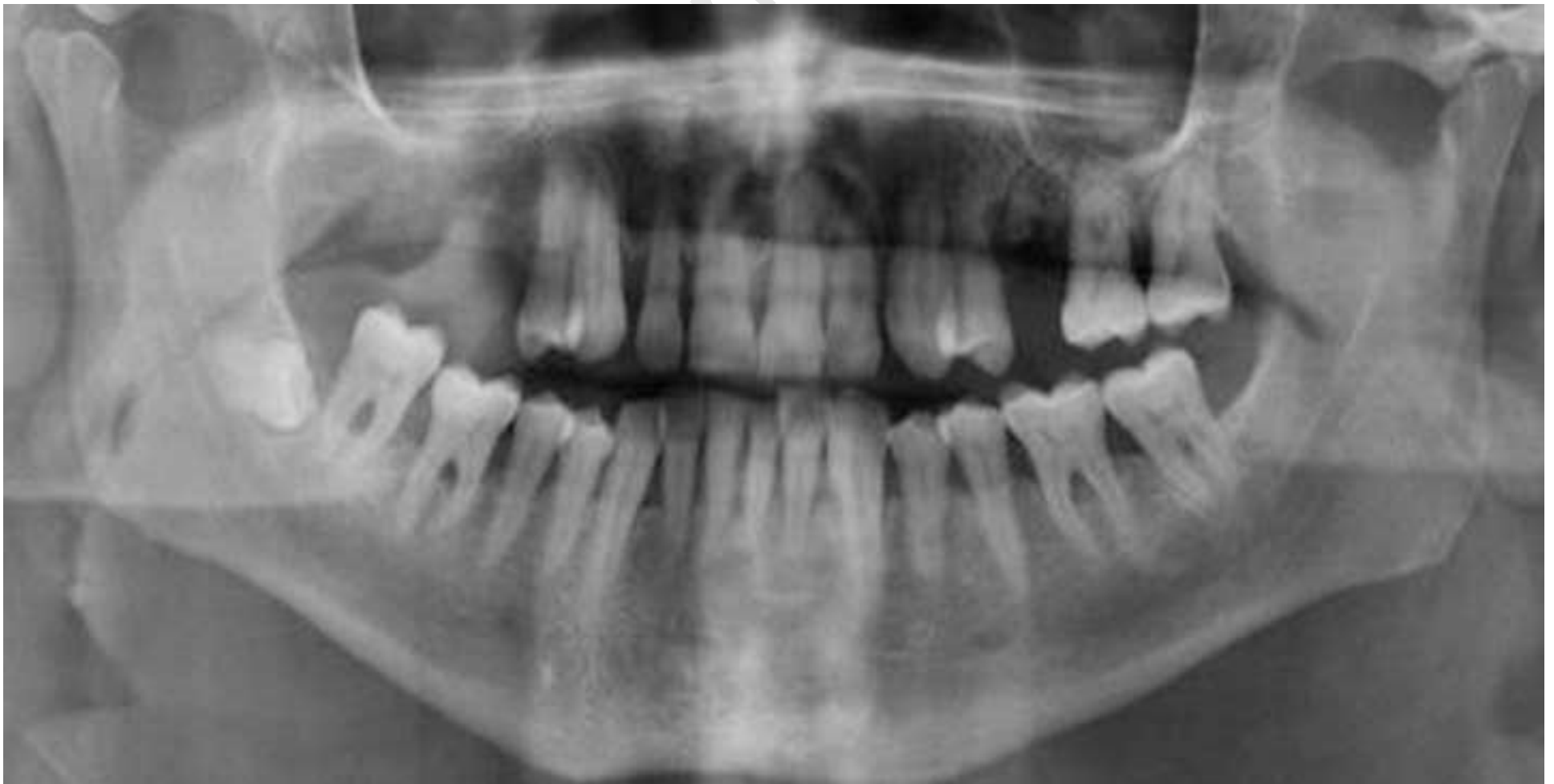
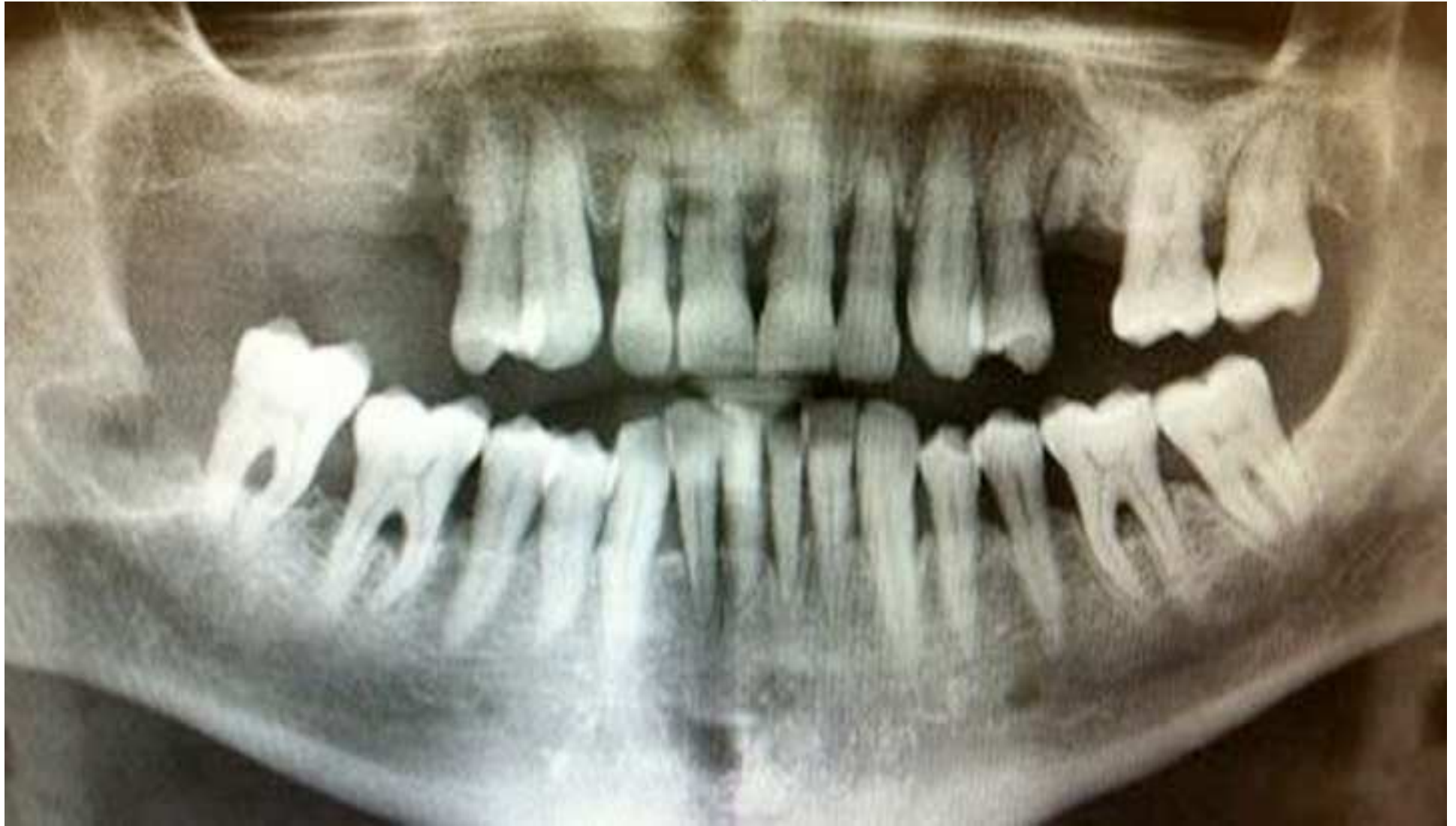
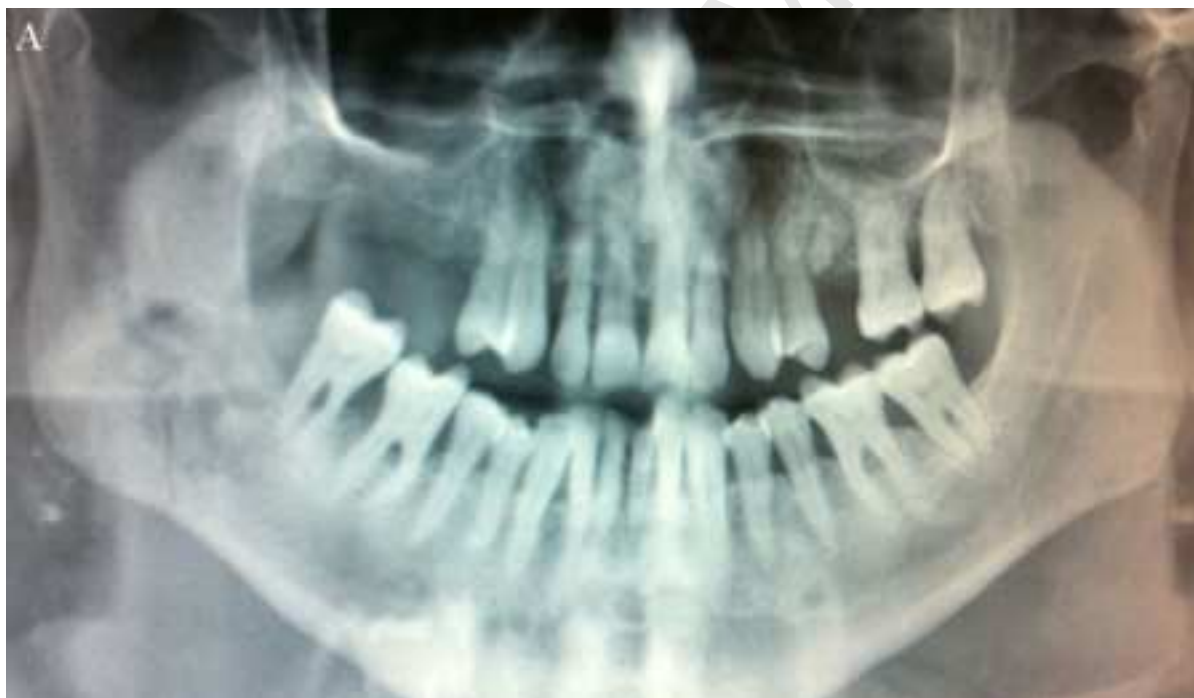Figure 2
[Click here to download high resolution image](#)



Manuscript



Manuscript

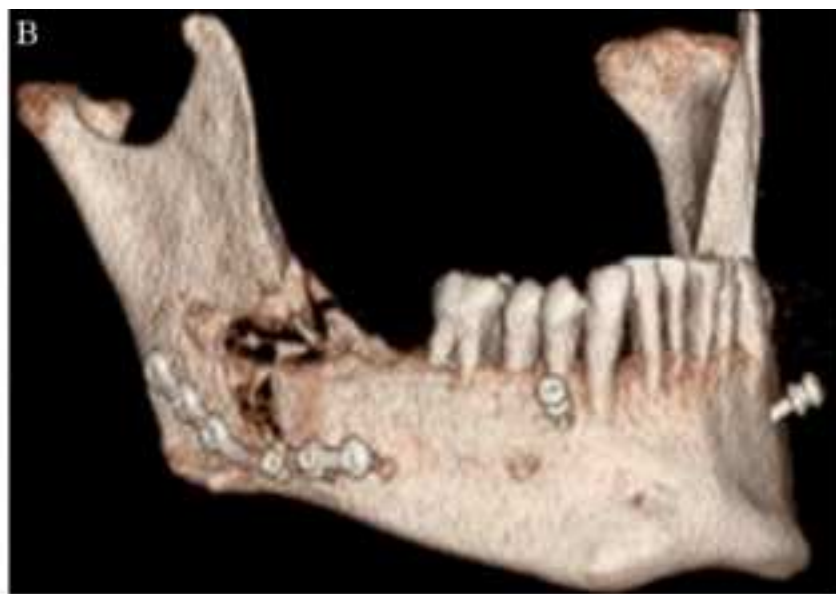
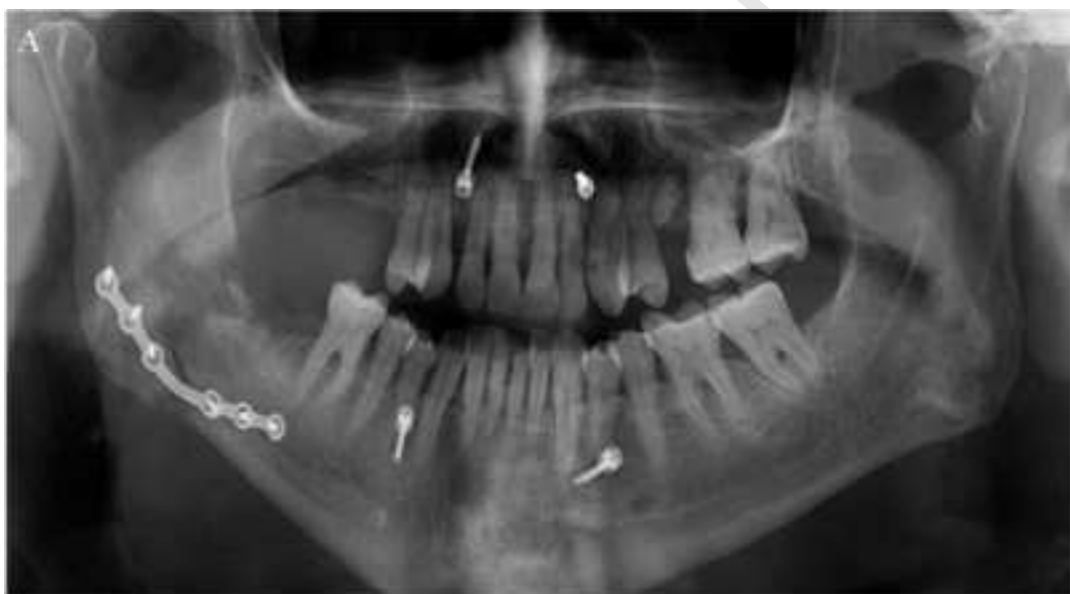
Figure 5
[Click here to download high resolution image](#)

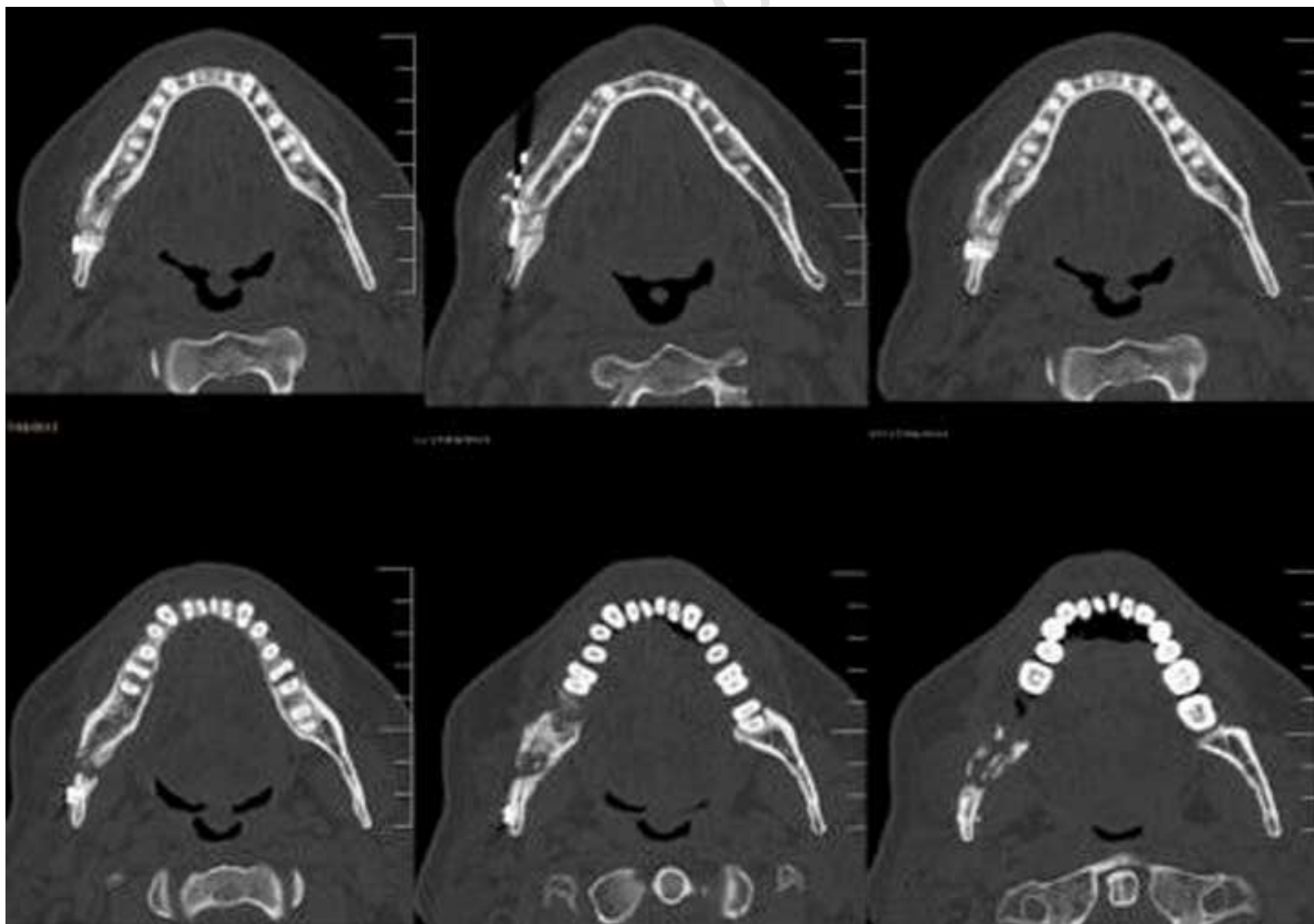


Figure 6
[Click here to download high resolution image](#)

