

UNIVERSITY OF BIRMINGHAM

Research at Birmingham

Atraumatic surgical extrusion to improve tooth restorability

Kelly, Robert; Addison, Owen; Tomson, Phillip; Krastl, Gabriel; Dietrich, Thomas

DOI:

[10.1016/j.prosdent.2015.09.028](https://doi.org/10.1016/j.prosdent.2015.09.028)

License:

Creative Commons: Attribution-NonCommercial-NoDerivs (CC BY-NC-ND)

Document Version

Peer reviewed version

Citation for published version (Harvard):

Kelly, RD, Addison, O, Tomson, PL, Krastl, G & Dietrich, T 2016, 'Atraumatic surgical extrusion to improve tooth restorability: A clinical report', *The Journal of Prosthetic Dentistry*. <https://doi.org/10.1016/j.prosdent.2015.09.028>

[Link to publication on Research at Birmingham portal](#)

Publisher Rights Statement:

Eligibility for repository: Checked on 27/4/2016

General rights

Unless a licence is specified above, all rights (including copyright and moral rights) in this document are retained by the authors and/or the copyright holders. The express permission of the copyright holder must be obtained for any use of this material other than for purposes permitted by law.

- Users may freely distribute the URL that is used to identify this publication.
- Users may download and/or print one copy of the publication from the University of Birmingham research portal for the purpose of private study or non-commercial research.
- User may use extracts from the document in line with the concept of 'fair dealing' under the Copyright, Designs and Patents Act 1988 (?)
- Users may not further distribute the material nor use it for the purposes of commercial gain.

Where a licence is displayed above, please note the terms and conditions of the licence govern your use of this document.

When citing, please reference the published version.

Take down policy

While the University of Birmingham exercises care and attention in making items available there are rare occasions when an item has been uploaded in error or has been deemed to be commercially or otherwise sensitive.

If you believe that this is the case for this document, please contact UBIRA@lists.bham.ac.uk providing details and we will remove access to the work immediately and investigate.

Atraumatic surgical extrusion to improve tooth restorability – a clinical report

Robert D Kelly, BA, B. Dent. Sci, MFDS RCSEd,^a Owen Addison, BDS, PhD, FDS (Rest Dent) RCSEng,^b Philip L Tomson, BDS, PhD, FDS (Rest Dent) RCSEd,^c Gabriel Krastl, Dr. med. dent.,^d Thomas Dietrich, Dr. med., Dr. med. dent., MPH, FDS RCS^e

^aDepartment of Conservative Dentistry, University of Birmingham School of Dentistry, College of Medical and Dental Sciences, St Chad's Queensway, Birmingham, UK.

^bProfessor, Department of Conservative Dentistry, University of Birmingham School of Dentistry, College of Medical and Dental Sciences, St Chad's Queensway, Birmingham, UK.

^cDepartment of Conservative Dentistry, University of Birmingham School of Dentistry, College of Medical and Dental Sciences, St Chad's Queensway, Birmingham, UK.

^dProfessor and Director of the Department of Operative Dentistry and Periodontology, University of Würzburg, Würzburg, Germany.

^eProfessor and Head of Oral Surgery, Department of Oral Surgery, University of Birmingham School of Dentistry, College of Medical and Dental Sciences, St Chad's Queensway, Birmingham, UK.

Corresponding author:

Prof Owen Addison

University of Birmingham School of Dentistry,

College of Medical and Dental Sciences,

St Chad's Queensway,

Birmingham, B4 6NN,

UNITED KINGDOM

Email: o.addison@bham.ac.uk

JPD-15-508

Atraumatic surgical extrusion to improve tooth restorability: A clinical report

ABSTRACT

This clinical report describes the use of an “atraumatic” vertical extraction system to facilitate the restorative treatment of a tooth that would otherwise be considered unrestorable because of subgingival caries. Minimally invasive surgical root extrusion was undertaken using the Benex Extraction system, which can provide controlled tooth extrusion with minimal deformation of the bone socket. A carious endodontically treated mandibular premolar was extruded to provide routine restorative treatment and endodontic retreatment.

INTRODUCTION

Carious lesions extending near the alveolar bone crest may often be unrestorable. When tooth preservation is essential from a strategic point of view or because of patient demands, the clinician must be able to both instrument and adequately restore the diseased and damaged tooth structure. In some instances, this may only be possible after surgical crown-lengthening procedures. Alternatively, tooth extrusion using orthodontic traction can be used to relocate the base of the lesion to, at, or above the gingival level. Orthodontic extrusion to facilitate tooth restoration has been reported using fixed appliances,¹ removable appliances,² and temporary anchorage devices.³ However, these methods have limitations, which include patient acceptance, treatment duration, the availability of appropriate orthodontic anchorage, and the risk of relapse.^{3,4}

Immediate surgical extrusion, involving both hard and soft tissues has been successfully applied,⁵⁻⁷ but may be associated with complications such as root resorption.⁶The surgical extrusion of teeth decreases treatment duration compared with orthodontic extrusion; however, such techniques have been associated with poor predictability so that a lack of clinical confidence remains. Extrusive tooth movement along the root axis has been considered analogous to extrusive luxation injuries after dental trauma, where an incidence of up to 15% root resorption has been reported.^{8,9} Although high quality evidence is scarce, a recent systematic review of various surgical extrusion methods suggests that nonprogressive root resorption is the most common adverse association, with an event rate of up to 30%.¹⁰ However, other complications include progressive root resorption, marginal bone loss, and persistent mobility, leading ultimately to tooth loss.¹⁰

Extrusive techniques which minimize root-surface damage, the disruption of the periodontal ligament, and deformation of the bony socket have been proposed, and these may provide improved and more predictable biological outcomes.⁶ Root extraction studies have reported that using vertical axial traction forces produces significantly less cementoblast loss on root surfaces than extracting teeth with forceps.¹¹The Benex Root Extraction System (Helmut Zepf Medizintechnik, GmbH, Hager & Meisinger GmbH) is designed to remove extensively damaged teeth with no expansion of the socket by delivering an extrusive force vectored along the long axis of the tooth being removed. The system comprises an anchor screw engaged in the root dentin connected to an 'extraction rope' (Fig.1), which is tensioned axially by the extractor device to deliver the extrusive forces. Geometrically matched diamond rotary instruments are used to create a pilot hole to minimize excessive wedging forces on insertion of the anchor screw, which may subsequently lead to root fractures. The extraction rope is incrementally

tensioned, thus applying an extrusive traction force over a period of minutes intended to lead to tooth removal. Vertical traction forces minimize damaging lateral forces on the bone of the alveolar socket but lead to axial movement by shearing the periodontal ligament fibers. The mechanisms underpinning periodontal ligament repair remain poorly understood, but in aseptic conditions healing remodeling occurs rapidly. Apical rupture of the neurovascular supply to the tooth leads to formation of a coagulum apical to the root apex, which subsequently remodels to form a fibrous scaffold with ultimate maturation into cancellous bone.¹² Because of the atraumatic nature of the tooth removal with little expansion of the surrounding alveolar bone, the authors suggest that the extraction system be adopted to deliver controlled tooth repositioning as part of a treatment plan to restore and retain teeth with little or no coronal tooth structure, which would otherwise be unrestorable.

CLINICAL REPORT

A 50-year-old healthy woman attended the Department of Restorative Dentistry at Birmingham Dental Hospital, Birmingham, United Kingdom for comprehensive rehabilitation following a referral from her general dental practitioner. Clinical examination revealed that the mandibular second left premolar was restored with a complete-coverage metal ceramic crown and had distal caries extending subgingivally. Periodontal probing depths were less than 3mm, and radiographic examination revealed a previously endodontically treated tooth with an extensive carious lesion on the distal aspect extending towards the alveolar crest. The endodontic obturation was considered deficient (Fig. 2A). Treatment options included tooth extraction and subsequent prosthetic replacement, periodontal crown lengthening, or tooth extrusion and subsequent restoration; the last option was selected.

Following patient consent, the crown was removed, and the coronal aspect of the root canal was prepared using matched rotary instruments for the Benex Root Extraction System. The corresponding extraction screw was inserted into the coronal root canal, and controlled partial extrusion of the root by 4 mm was performed over a period of 2 minutes. Preliminary caries was removed with stainless steel round burs before extrusion to determine the magnitude of the vertical movement needed to ensure that the definitive restoration margins would be supragingival. In this patient, the tooth was stable in the socket after extrusion and there was minimal associated bleeding. However, in other patients, it can be expected that tooth stability will be sensitive to root anatomy and the required extrusion distance. The tooth was intended to be rigidly splinted to the adjacent teeth out of functional occlusion for 6 to 8 weeks (Fig. 2B). At the 1-week review, the splint had debonded, but as the tooth was immobile, no further splinting was provided.

Seventeen weeks after extrusion (minimum of 12 weeks recommended after extrusion to allow for periodontal healing), endodontic retreatment was undertaken with a 2-stage approach. An inter appointment medicament of non setting calcium hydroxide was placed in the root canal for 3 weeks to obtain an aseptic field and to prevent inflammatory changes of the radicular portion of the tooth. An interim coronal restoration of glass ionomer cement was also placed before the root canal was definitively obturated with a hybrid thermal gutta percha technique (Fig. 2C).^{13,14}

At the 9-month post-extrusion review the patient reported no problems, and the tooth was asymptomatic. Clinical examination revealed no signs of pathology; the tooth was not tender to palpation or percussion and probing depths and mobility were within physiological limits. Radiographic examination revealed early signs of bony healing and a crown-root ratio for

restoration of at least 1:1 (Fig 2D). At this visit, the tooth was prepared to receive a complete coverage, conventional metal ceramic indirect restoration. Subsequent radiographic examination at 20 months after extrusion continued to reveal a normal periapical area (Fig 2E).

DISCUSSION

The Benex extraction system offers several advantages over alternative means of tooth extrusion, particularly in the restoration of compromised teeth. The principal advantage is that it may be considered an atraumatic technique, minimizing the amount of trauma to the surrounding periodontium.¹⁵ Such a system may offer several advantages to both the patient and clinician,¹⁶ including the potential to predictably maintain the stability and integrity of the alveolar socket after extrusion, as the device delivers a vertical shearing extrusive force only. Furthermore, as an axial force is applied to the tooth in question over several minutes, lateral or oblique forces are greatly minimized. This reduces the potential for compressive injuries to the surrounding periodontal ligament and the risk of resorption defects, as a positive correlation seems to exist between mechanical damage of the periodontal complex and ensuing defects.^{11,17}

Contraindications include insufficient root length and/or periodontal attachment, narrow roots at higher risk of fracture during tap insertion, and teeth with poor endodontic prognosis.

Unfortunately, the above system is not without its limitations. Although the Benex system may appear relatively safe and easy to use, a degree of learning and familiarization is associated with the application of the system. Further long-term follow-up and evaluation of teeth extruded by using this system is required. As this instrument was originally designed for the atraumatic extraction of teeth, it remains to be seen whether such teeth will be affected by physiological processes such as external surface resorption or ankylosis. Furthermore, patients

undergoing such treatment should be warned of the risk of root fractures and perforations if a transalveolar approach or indeed an extraction is needed.

SUMMARY

The Benex system can be successfully used as part of the restorative treatment plan in selected situations. The system offers further treatment options of a less invasive nature, which may suit patients with fewer iatrogenic complications given the conservative means of extrusion. As this appears to be the only report of such a treatment, further long-term follow-up may be required to inform the wider community of the stability of such an option.

REFERENCES

1. Addy LD, Durning P, Thomas MB, McLaughlin WS. Orthodontic extrusion: an interdisciplinary approach to patient management. *Dent Update* 2009;36:212-4,217-8
2. Reyes E, Barrow S, McLeod DE. Crown lengthening with removable orthodontics: a combined approach for ideal esthetics. *Gen Dent* 2011;59:362-6
3. Smidt A, Gleitman J, Dekel MS. Forced eruption of a solitary nonrestorable tooth using mini-implants as anchorage: rationale and technique. *Int J Prosthodont* 2009;22:441-6
4. Darby LJ, Garvey TM, O'Connell AC. Orthodontic extrusion in the transitional dentition: a simple technique. *Pediatr Dent* 2009;31:520-2
5. Caliskan MK, Turkun M, Gomel M. Surgical extrusion of crown-root-fractured teeth: a clinical review. *Int Endod J* 1999;32:146-51
6. Kahnberg KE. Surgical extrusion of root-fractured teeth--a follow-up study of two surgical methods. *Endod Dent Traumatol* 1988;4:85-9
7. Tegsjö U, Valerius-Olsson H, Frykholm A, Ölgart K. Clinical evaluation of intra-alveolar transplantation of teeth with cervical root fractures. *Swed Dent J* 1987;11:235-50
8. Andreasen JO. Luxation of permanent teeth due to trauma. A clinical and radiographic follow-up study of 189 injured teeth. *Scand J Dent Res* 1970;78:273-86
9. Hermann NV, Lauridsen E, Ahrensburg SS, Gerds TA, Andreasen JO. Periodontal healing complications following extrusive and lateral luxation in the permanent dentition: a longitudinal cohort study. *Dent Traumatol* 2012;28:394-402

10. Elkhadem A, Mickan S, Richards D. Adverse events of surgical extrusion in treatment for crown-root and cervical root fractures: a systematic review of case series/reports. *Dent Traumatol* 2014;30:1-14
11. Oikarinen KS, Stoltze K, Andreasen JO. Influence of conventional forceps extraction and extraction with an extrusion instrument on cementoblast loss and external root resorption of replanted monkey incisors. *J Periodontal Res* 1996;31:337-44
12. Andreasen JO, Andreasen FM, Andersson L. Textbook and color atlas of traumatic injuries to the teeth. 4th ed. Blackwell Munksgaard;2007. p. 1-44 &411-14
13. Cvek M. Prognosis of luxated non-vital maxillary incisors treated with calcium hydroxide and filled with gutta-percha. A retrospective clinical study. *Endod Dent Traumatol* 1992;8:45-55
14. Caliskan MK, Sen BH. Endodontic treatment of teeth with apical periodontitis using calcium hydroxide: a long-term study. *Endod Dent Traumatol* 1996;12:215-21
15. Muska E, Walter C, Knight A, Taneja P, Bulsara Y, Hahn M, et al. Atraumatic vertical tooth extraction: a proof of principle clinical study of a novel system. *Oral Surg Oral Med Oral Pathol Oral Radiol* 2013;116:e303-10
16. Saund D, Dietrich T. Minimally-invasive tooth extraction: doorknobs and strings revisited! *Dent Update* 2013;40:325-6,328-30
17. Andreasen JO, Kristerson L. The effect of limited drying or removal of the periodontal ligament. Periodontal healing after replantation of mature permanent incisors in monkeys. *Acta Odontol Scand* 1981;39:1-13.

LEGENDS

Fig. 1. Benex Extraction System in use during extraction of maxillary right canine tooth. A, Preoperative view of remaining root with pilot hole prepared in root. B, Placement of screw driver into remaining root. C, Placement and preparation of silicone impression tray to aid support of Benex system during extrusion. D, Impression tray and Benex device assembled to achieve axial alignment. E, Progressive root extrusion in a vertical direction, eventually resulting in tooth extraction. F, Tooth socket following extraction.

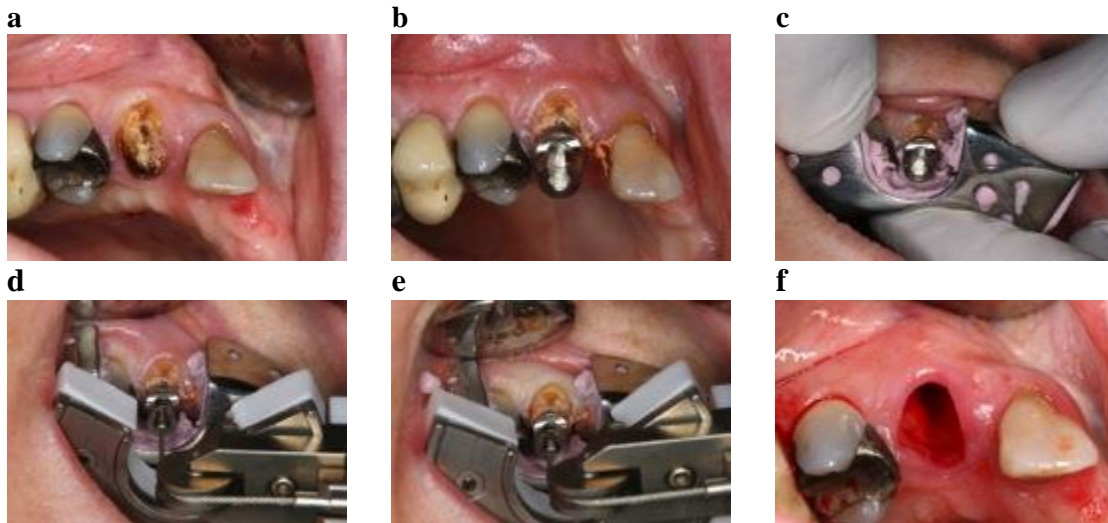
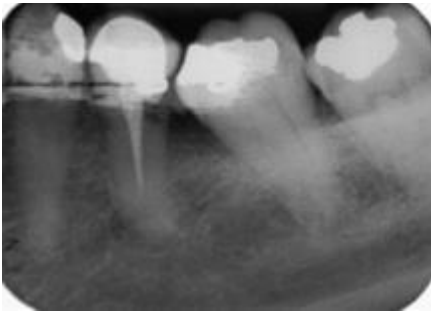
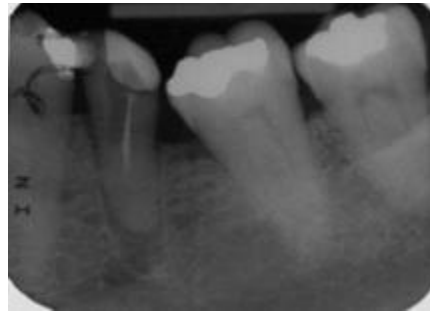
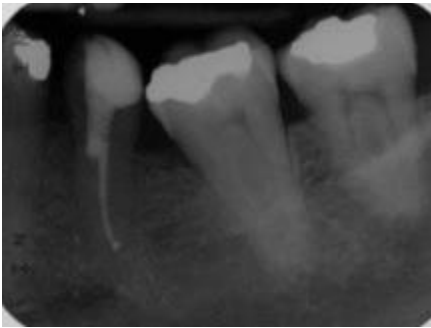
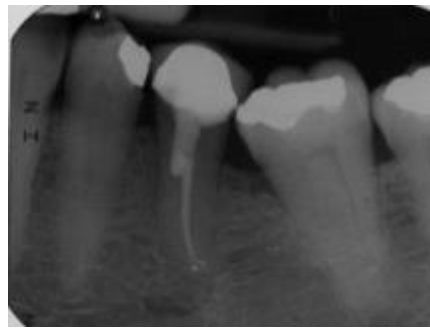


Figure 2. Serial radiographs of patient's mandibular left second premolar tooth. A, Preoperative status. B, Immediately after extrusion. C, Radiograph after endodontic obturation (4 months after extrusion), displaying initial bony infill apically. D, After indirect coronal restoration (9 months after extrusion), displaying stabilization of extruded position with continued bony infill apically. E, Demonstrating continued healing with stability at 20 months after extrusion.

a**b****c****d****e**